High-dose Intravenous Immunoglobulin Monotherapy for Drug-induced Hypersensitivity Syndrome

Yukiko Kito, Taisuke Ito, Yoshiki Tokura and Hideo Hashizume
Department of Dermatology, Hamamatsu University School of Medicine, 1-20-1 Handayama, Higashi-ku, Hamamatsu 431-3192, Japan. E-mail: yukikok@hama-med.ac.jp
Accepted April 15, 2011.

Drug-induced hypersensitivity syndrome (DIHS), also known as drug rash with eosinophilia and systemic symptoms (DRESS), is a severe, multi-organ, adverse reaction characterized by erythema with facial oedema, fever, lymphadenopathy, hepatitis, and leukocytosis with eosinophilia (1–3). In more than 60% of DIHS cases, human herpesvirus (HHV)-6 reactivation is observed and is associated with an unfavourable outcome (4). High-dose corticosteroid therapy is a controversial treatment for DIHS/DRESS because patients may become susceptible to infections (5). We describe here the case of a DIHS/DRESS patient successfully treated with high-dose intravenous immunoglobulin (IVIG) containing a high titre of anti-HHV-6 antibodies.

CASE REPORT

A 49-year-old woman had developed a postoperative infection after radical resection of a pelvic chondrosarcoma. Methicillin-resistant *Staphylococcus aureus*, *Klebsiella pneumoniae* and *Serratia marcescens* were identified in the surgical wound by bacterial culture. Although various antibiotics were sequentially administered, the infection persisted and her body temperature remained higher than 38.5ºC for approximately 3 months. She also experienced neuropathic pain in her right leg due to a nerve injury and was treated with a 3-month course of mexiletine. The drug was discontinued when the neuralgia abated. Three days later, erythema spread over her body and facial oedema appeared. Physical examination revealed cervical and inguinal lymphadenopathy. Maculopapules, with follicular accentuations, were distributed over her body, apart from the areas around the eyes and mouth (Fig. 1A and B). There was no enanthema in her oral cavity. Laboratory investigations showed an elevated white blood cell count (10,400/µl, normal range: 3,600–9,200/µl) with eosinophilia (17%, normal: <5%) and atypical lymphocyte (1%), elevated liver enzymes (aspartate aminotransferase, 125 IU/l, normal: 11–30 IU/l; alanine transaminase, 107 IU/l, normal: 5–42 IU/l), C-reactive protein (2.4 mg/dl, normal: <0.1 mg/dl) and serum anti-human herpesvirus (HHV)-6 IgG titre (1:640), and decreased serum IgG (840 mg/dl, normal: 870–1,700 mg/dl). No increase was observed in the titre of antibodies against Epstein-Barr virus or cytomegalovirus antigens. Skin histology showed mild liquefaction degeneration, a few dyskeratotic cells in the epidermis, and perivascular lymphocytic infiltration in the dermis (Fig. 2). Some lymphocytes were large, with condensed nuclei, resembling lymphoma cells. We diagnosed the patient with "atypical" DIHS based on the diagnostic criteria for DIHS by a Japanese consensus group (the patient's score was 5 points) (3). Patch testing and lymphocyte transformation test with mexiletine after the resolution gave negative results. However, we considered it as the causative drug because there have been accumulating cases of DIHS/DRESS induced by this agent, and the 3-month administration in this case was consistent with the incubation time for this disease. We started IVIG 3 days after the eruption appeared. To avoid any worsening of the pre-existing infection, the patient was treated with high-dose IVIG therapy at 0.4 g/kg/day for 5 successive days instead of the more "conventional" high-dosage corticosteroid therapy. We used batches containing relatively high titres of IgG antibodies against HHV-6 (1:160, as assessed by the fluorescent antibody method) and cytomegalovirus (86.4 U/ml, as assessed by enzyme immunoassay). The body temperature returned to normal in 3 days and the eruption had disappeared completely 7 days after treatment was initiated. The elevated liver enzymes returned to normal levels thereafter. There was no worsening of the surgical wound infection after treatment. The titres of herpes viruses after IVIG are shown in Table SI (available from: http://www.medicaljournals.se/acta/content/?doi=10.2340/00015555-1168).

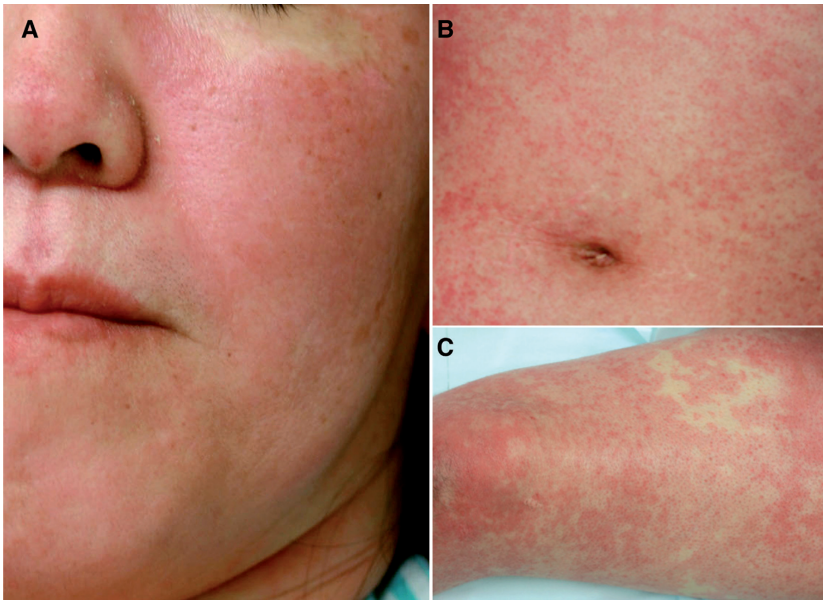

Fig. 1. (A) Maculopapules, sparing the eyes and mouth. Erythema on (B) the trunk and (C) the thigh.

DISCUSSION

Anti-inflammatory agents are usually used for the treatment of severe adverse drug reactions (SADRs) such as Stevens-Johnson syndrome (SJS), toxic epidermal necrolysis (TEN) and DIHS/DRESS, since the simple discontinuation of the culprit drugs does not reduce the inflammatory response in such cases. High-dose corticosteroid therapy has been used empirically in SADRs. However, serious conditions affecting patients with SADRs may

© 2011 The Authors. doi: 10.2340/00015555-1168
Journal Compilation © 2011 Acta Dermato-Venereologica. ISSN 0001-5555

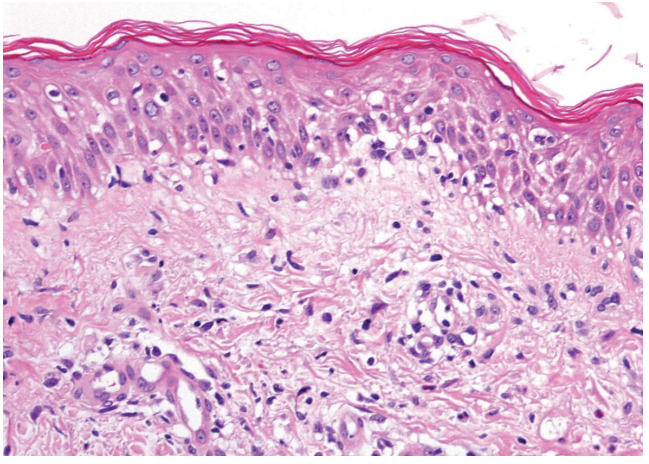

Fig. 2. Mild liquefaction degeneration, a few dyskeratotic cells in the epidermis and perivascular lymphocytic infiltration of the dermis were observed. Haematoxylin and eosin × 200

impose restrictions on the choice of treatment. The present case was induced by mexiletine, one of the more "notorious" culprits, and showed characteristic features of DIHS/DRESS (2–4). However, we hesitated to use high-dosage corticosteroid therapy because the patient also had a severe post-operative infection. We therefore decided to use high-dose IVIG monotherapy to treat this case, although only a few cases of such treatment have been reported (6, 7). This course of treatment rapidly reduced disease activity without causing any worsening of the wound infection. We successfully treated this patient with high-dose IVIG monotherapy.

DIHS is distinct from other SADRs because of the dynamic alterations of immunity observed during the course of the disease. The phenotype of circulating lymphocytes is altered from a CD4+ cell-dominant profile to CD8+ cell-dominant profile that coincides with the time of viral reactivation (8). Regulatory T cells in the circulation and skin initially increase in number, but decrease further thereafter, in parallel with the observed functional impairment (9). The concentration of serum immunoglobulins also decreases during the early phase of DIHS/DRESS (10). These unique immunological phenomena may be associated with immunological defects that cause HHV-6 reactivation, a unique event in DIHS/DRESS, although the precise mechanism remains unknown.

High-dose IVIG therapy for DIHS/DRESS has two immunological effects. First, it compensates for the decreased immunoglobulin concentration and immunological defects for protection of HHV-6 infection. Batches containing high titres of antibodies against the viruses might be particularly effective in preventing HHV-6 reactivation (11). Secondly, high-dose IVIG has a substantial anti-inflammatory effect that regulates the immune response, as seen in the treatment of autoimmune disorders (12). Our experience in this case should encourage clinicians to consider IVIG as a therapeutic option for DIHS/DRESS patients, especially in those patients with a high risk of infection.

REFERENCES

1. Hashimoto K, Yasukawa M, Tohyama M. Human herpesvirus 6 and drug allergy. Curr Opin Allergy Clin Immunol 2003; 3: 255–260.
2. Kardaun SH, Sidoroff A, Valeyrie-Allanore L, Halevy S, Davidovici BB, Mockenhaupt M, et al. Variability in the clinical pattern of cutaneous side-effects of drugs with systemic symptoms: does a DRESS syndrome really exist? Br J Dermatol 2007; 156: 609–611.
3. Shiohara T, Iijima M, Ikezawa Z, Hashimoto K. The diagnosis of a DRESS syndrome has been sufficiently established on the basis of typical clinical features and viral reactivations. Br J Dermatol 2007; 156: 1083–1084.
4. Tohyama M, Hashimoto K, Yasukawa M, Kimura H, Horikawa T, Nakajima K, et al. Association of human herpesvirus 6 reactivation with the flaring and severity of drug-induced hypersensitivity syndrome. Br J Dermatol 2007; 157: 934–940.
5. Tas S, Simonart T. Management of drug rash with eosinophilia and systemic symptoms (DRESS syndrome): an update. Dermatology 2003; 206: 353–356.
6. Fields KS, Petersen MJ, Chiao E, Tristani-Firouzi P. Case reports: treatment of nevirapine-associated dress syndrome with intravenous immune globulin (IVIG). J Drugs Dermatol 2005; 4: 510–513.
7. Santos RP, Ramilo O, Barton T. Nevirapine-associated rash with eosinophilia and systemic symptoms in a child with human immunodeficiency virus infection. Pediatr Infect Dis J 2007; 26: 1053–1056.
8. Hashizume H, Takigawa M. Drug-induced hypersensitivity syndrome associated with cytomegalovirus reactivation: immunological characterization of pathogenic T cells. Acta Derm Venereol 2005; 85: 47–50.
9. Takahashi R, Kano Y, Yamazaki Y, Kimishima M, Mizukawa Y, Shiohara T. Defective regulatory T cells in patients with severe drug eruptions: timing of the dysfunction is associated with the pathological phenotype and outcome. J Immunol 2009; 182: 8071–8079.
10. Kano Y, Inaoka M, Shiohara T. Association between anticonvulsant hypersensitivity syndrome and human herpesvirus 6 reactivation and hypogammaglobulinemia. Arch Dermatol 2004; 140: 183–188.
11. Kano Y, Inaoka M, Sakuma K, Shiohara T. Virus reactivation and intravenous immunoglobulin (IVIG) therapy of drug-induced hypersensitivity syndrome. Toxicology 2005; 209: 165–167.
12. Orange JS, Hossny EM, Weiler CR, Ballow M, Berger M, Bonilla FA, et al. Use of intravenous immunoglobulin in human disease: a review of evidence by members of the Primary Immunodeficiency Committee of the American Academy of Allergy, Asthma and Immunology. J Allergy Clin Immunol 2006; 117: S525–553.

Table SI. *Titres of antibody against herpes viruses during the course treatment with intravenous immunoglobulin*

Day*			–4	3	17	31	59
HHV-6**	IgG		320	640	160	320	640
	IgM		<10	<10	<10	<10	<10
CMV**	IgG		ND	53.0	32.6	32.0	34.9
	IgM		ND	0.46	0.16	0.43	0.50
EBV**	VCA	IgG	ND	160	160	160	160
		IgM	ND	<10	<10	<10	<10
	EADR	IgG	ND	<10	<10	<10	<10
	NA	IgG	ND	80	80	80	80

*Number indicates time (days) after the eruption. The time-point when the eruption initiated was designated day 0. Virus titre of the preserved serum is also indicated in the first column at day –4. **Titres of antibody against HHV-6/EBV and CMV were measured by fluorescent antibody method and enzyme immunoassay (negative, <1.0), respectively.
VCA: virus capsid antigen; EADR: early antigen-diffuse and restrict complex; NA: nuclear antigen. ND: not done. IVIG therapy was started from day 3 for successive 5 days.