Clinical Journal of Gastroenterology
https://doi.org/10.1007/s12328-019-00960-4

CASE REPORT

Eosinophilic esophagitis after total gastrectomy treated with proton pump inhibitors: a case report

Takashi Owaki[1,2] · Hiroki Sato[1,2] · Ryoko Horigome[1] · Satoru Hashimoto[2] · Terasu Honma[1] · Shuji Terai[2]

Received: 26 December 2018 / Accepted: 4 March 2019
© Japanese Society of Gastroenterology 2019

Abstract

Eosinophilic esophagitis (EoE) is a chronic, immune-mediated disorder in the esophagus characterized by symptoms related to esophageal dysfunction and eosinophil-predominant inflammation. EoE and Gastro Esophageal Reflux Disease (GERD) are known not to be mutually exclusive and share a complex relationship. Proton pump inhibitors (PPIs), which are generally used in the treatment of GERD, could be used to treat esophageal eosinophilia in suspected EoE. We report a rare case of EoE after total gastrectomy that responded to PPIs. Our case indicates that the onset of EoE does not necessarily require an acid reflux-induced antigen-mediated drive, and the action of PPIs in patients with active EoE is unrelated to gastric acid suppression.

Keywords Eosinophilic esophagitis · Gastro esophageal reflux disease · Proton pump inhibitor · PPI-responsive esophageal eosinophilia · Gastrectomy

Introduction

Eosinophilic esophagitis (EoE) is a chronic, immune-mediated or antigen-mediated disorder in the esophagus characterized by symptoms related to esophageal dysfunction and eosinophil-predominant inflammation [1]. The history of EoE is rather new [2, 3], and many studies have been performed to determine the pathophysiology.

According to recent studies, nearly 50% of patients with esophageal eosinophilia respond to medical therapy with proton pump inhibitors (PPIs) which are generally used for Gastro Esophageal Reflux Disease (GERD) [4]. A previous guideline supported a "PPI trial" as a diagnostic tool for EoE, and the so-called "PPI-responsive esophageal eosinophilia (PPI-REE)" was excluded before the definite diagnosis of EoE [5]. Thereafter, further studies were performed to identify the differences between EoE and PPI-REE, although no significant difference was found on endoscopy [6], histology [7], or gene expression analysis [8]. Therefore, at present, both EoE and PPI-REE are considered to be in the same category of EoE, and are quite different from GERD [9–11]. Here, we report a suggestive case of EoE in respect to the development of the disorder and PPI response.

Case report

The patient was a 77-year-old man with complaints of dysphagia since 6 months with no known allergies or history of allergic diseases. 15 years prior to presentation, he underwent distal gastrectomy for advanced gastric cancer, followed by total gastrectomy for remnant gastric cancer 13 years prior (Fig. 1). Subsequently, surveillance endoscopy had been performed annually, with no specific findings until last year. Endoscopy performed for the examination of dysphagia and for cancer surveillance revealed decreased vascularity and linear furrows in the esophagus (Fig. 2a, b), supporting a diagnosis of EoE [12]. Several biopsies were subsequently performed, which confirmed esophageal eosinophilia with approximately 90 eosinophils (eos) per high-power field (hpf) (Fig. 2c, d), leading to the diagnosis of EoE. His peripheral blood eosinophil level was normal at 319/μL (5.8%), and his IgE level was high (1350.5 IU/mL).

✉ Hiroki Sato
pyloki-sato@med.niigata-u.ac.jp

1 Department of Gastroenterology, Saiseikai Niigata Daini Hospital, Niigata, Japan

2 Division of Gastroenterology and Hepatology, Niigata University Medical and Dental Hospital, 757-1, Asahimachidori, Chuo-ku, Niigata 951-8510, Japan

Published online: 08 March 2019

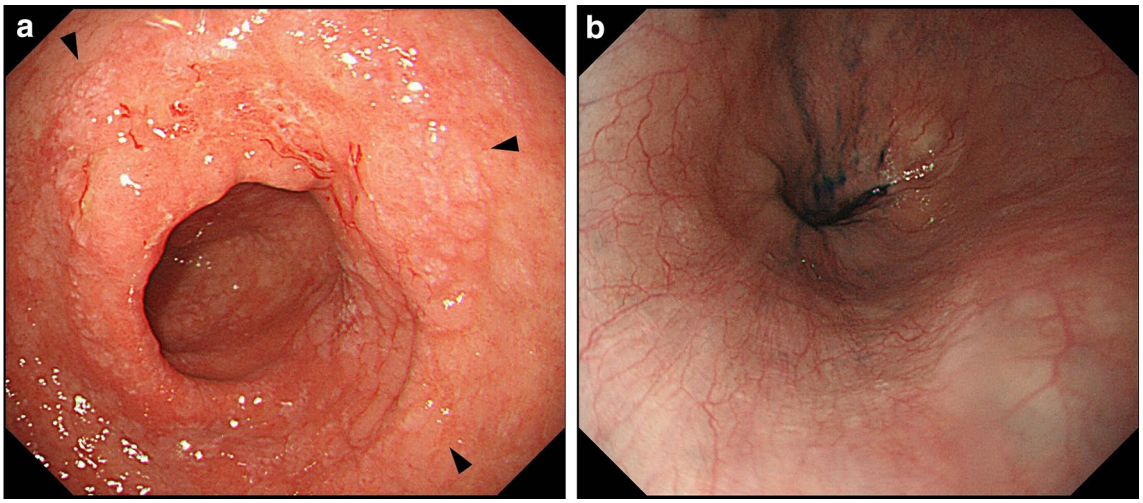

Fig. 1 **a** Advanced gastric cancer (black triangles) is noted in the remnant stomach. The Esophagus does not show any findings supporting EoE (**b** lower esophagus)

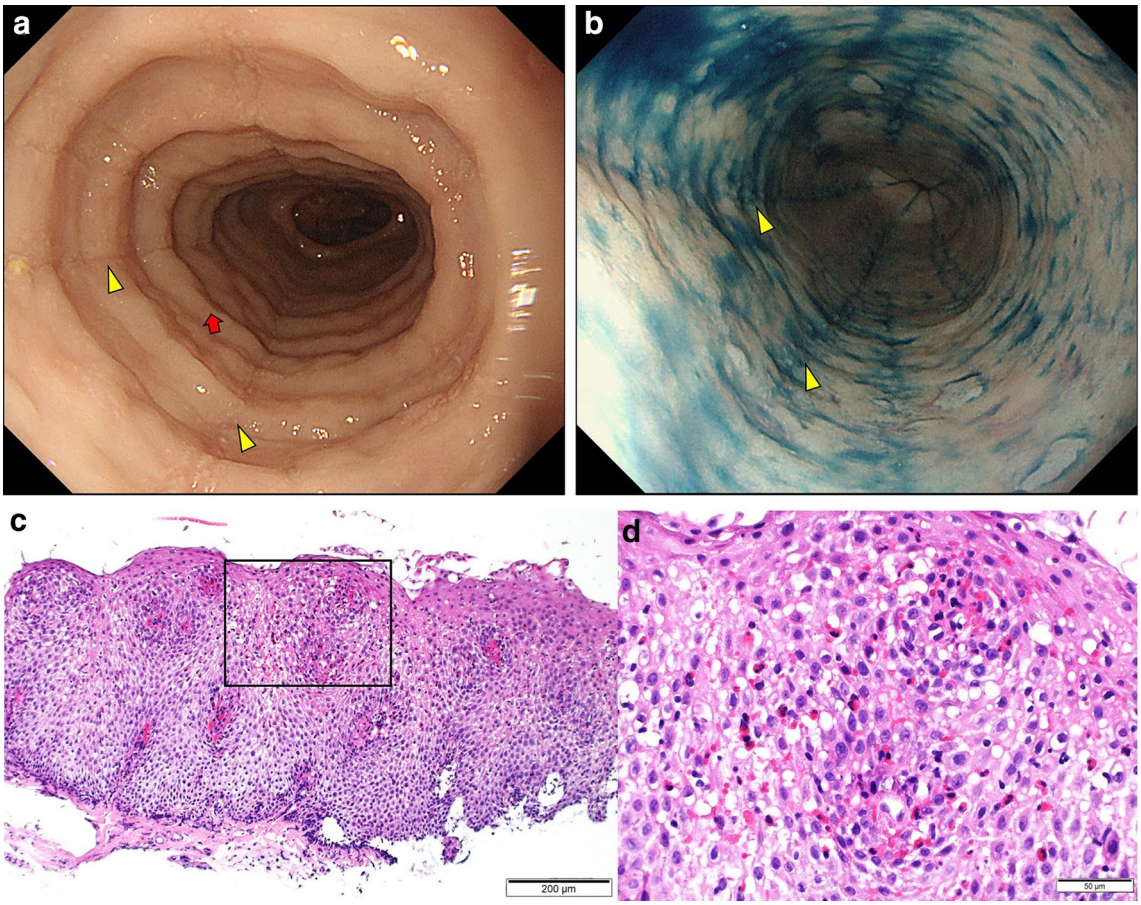

Fig. 2 **a** Endoscopy shows decreased vascularity (red arrow), and linear furrows (yellow triangle) in the lower esophagus close to the anastomotic part of the small intestine. **b** Middle portion of the esophagus with indigocarmine staining. **c, d** Histology confirms esophageal eosinophilia with maximum 90 eosinophils (eos/hpf). The area of the black box (in **c**) is magnified with the hpf view (**d**)

He was initially treated with a PPI (rabeprazole, 20 mg twice daily) for 8 weeks. His dysphagia resolved completely, and on endoscopy, esophageal vascularity increased and linear furrows diminished (Fig. 3a, b) with decreased eosinophils on histology (maximum 19 eos/hpf, defined as partial histological remission [13]) (Fig. 3c, d). Topical steroid therapy (fluticasone, 200 μg twice daily) was subsequently administered for additional 8 weeks, leading to complete remission with histological remission (maximum 0 eos/hpf).

Discussion

The efficacy of PPIs for GERD after gastrectomy has been previously reported, supporting the additional effects of PPIs such as influence on the bile reflux [14, 15], although the detailed mechanism is still unclear. To our knowledge, this is the first case report of EoE developing after total gastrectomy that responded to PPI therapy. Gastric cancer is frequently seen in Japan and is rare in Western countries, although EoE is observed more in Western countries and less in Japan [16, 17]. Total gastrectomy is performed for advanced gastric cancer, particularly in those located in the upper stomach.

According to a previous study stating that PPI is also effective for EoE, gastric acid reflux was suggested to be related with the trigger of EoE. However, based on the findings in this case, the onset and progression of EoE may be independent of the reflux of gastric acid, although reflux of intestinal contents, including bile and pancreatic juice, may trigger eosinophilic inflammation in the presence of a causal antigen. Environmental factors, including food and the microbiome, could have interacted with the esophageal epithelium to activate allergic inflammation during the post-gastrectomy period [18], although our patient had made no environmental changes, including those involving his food habits.

Several theories were proposed regarding the effectiveness of PPI for EoE [19–21], and in this report, the anti-inflammatory mechanism and not gastric acid suppression was strongly supported. In EoE, eosinophils accumulate in the esophagus when allergens induce production of Th2

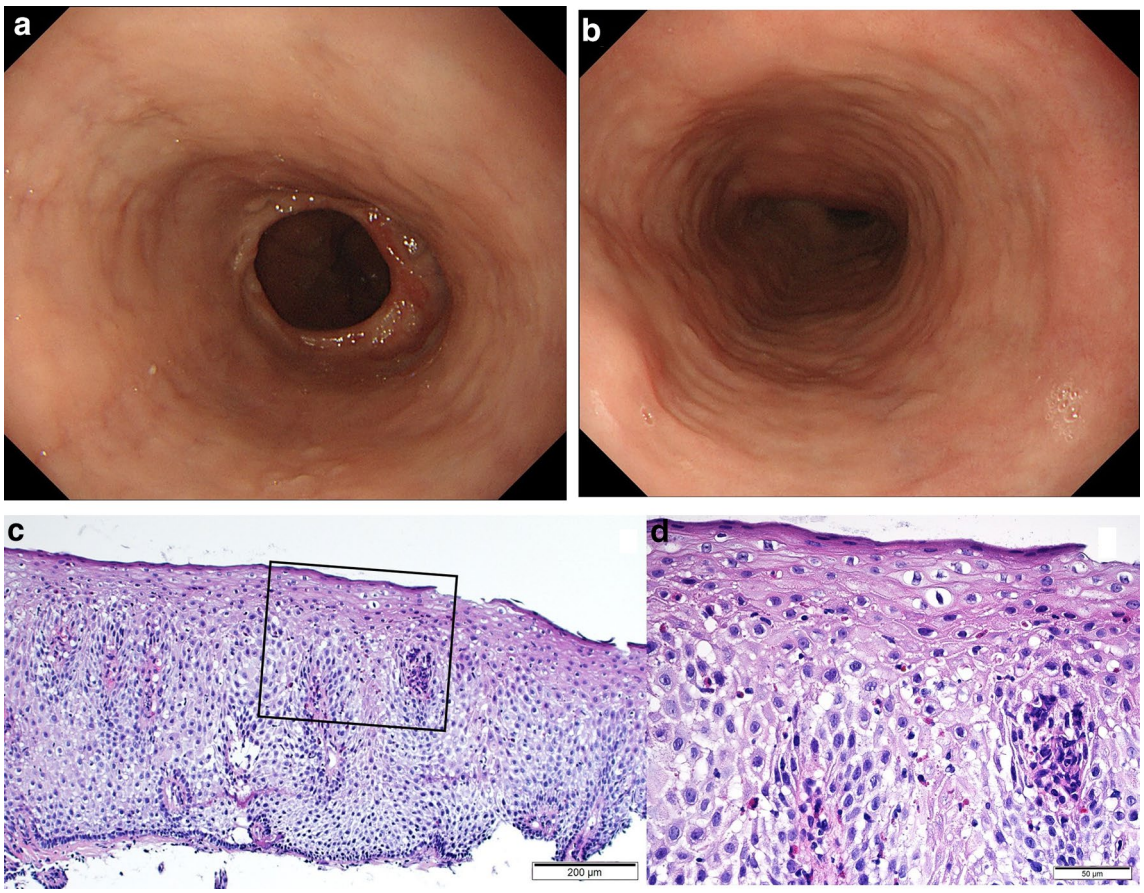

Fig. 3 **a** Endoscopy shows that mucosal vascularity improved and linear furrows diminished with PPI therapy (lower esophagus). **b** Middle esophagus with a similarly improved endoscopic view. **c, d** In the histology, eosinophil infiltration is improved with maximum 19 eos/hpf. The area of the black box (in **c**) is magnified with hpf view (**d**)

cytokines such as IL-4 and IL-13, which stimulate esophageal secretion of eotaxin-3. PPI inhibits Th2 cytokine-stimulated eotaxin-3 secretion in isolated esophageal epithelial cells [22, 23]. In this case, PPI therapy gained a good response after 8 weeks, and longer PPI therapy might lead to further improvement in efficacy. In this case, however, the PPI was switched to topical steroid therapy at the patient's request based on good but not complete remission. Low-dose topical steroid therapy, the dose of which was decided due to the patient's anxiety regarding the side effects of steroid and good response to PPIs, led to complete remission.

In conclusion, EoE may be an esophagus-localized disorder not related to gastric reflux, and the effectiveness of PPI therapy is not through inhibition of the gastric reflux.

Compliance with Ethical Standards

Conflict of interest Takashi Owaki, Hiroki Sato, Ryoko Horigome, Satoru Hashimoto, Terasu Honma, and Shuji Terai declare that they have no conflict of interest.

Human rights All procedures followed have been performed in accordance with the ethical standards laid down in the 1964 Declaration of Helsinki and its later amendments.

Informed consent Informed consent was obtained from all patients for being included in the study.

References

1. Furuta GT, Katzka DA. Eosinophilic esophagitis. N Engl J Med. 2015;373(17):1640–8.
2. Attwood SE, Smyrk TC, Demeester TR, et al. Esophageal eosinophilia with dysphagia. A distinct clinicopathologic syndrome. Dig Dis Sci. 1993;38(1):109–16.
3. Straumann A, Spichtin HP, Bernoulli R, et al. Idiopathische, eosinophile Osophagitis: eine haufig verkannte Krankheit mit typischer Klinik und diskretem endoskopischem Bild [Idiopathic eosinophilic esophagitis: a frequently overlooked disease with typical clinical aspects and discrete endoscopic findings]. Schweiz Med Wochenschr. 1994;124(33):1419–29.
4. Dellon ES, Liacouras CA. Advances in clinical management of eosinophilic esophagitis. Gastroenterology. 2014;147(6):1238–54.
5. Furuta GT, Liacouras CA, Collins MH, et al. Eosinophilic esophagitis in children and adults: a systematic review and consensus recommendations for diagnosis and treatment. Gastroenterology. 2007;133(4):1342–63.
6. Dranove JE, Horn DS, Davis MA, et al. Predictors of response to proton pump inhibitor therapy among children with significant esophageal eosinophilia. J Pediatr. 2009;154(1):96–100.
7. Dellon ES, Speck O, Woodward K, et al. Clinical and endoscopic characteristics do not reliably differentiate PPI-responsive esophageal eosinophilia and eosinophilic esophagitis in patients undergoing upper endoscopy: a prospective cohort study. Am J Gastroenterol. 2013;108(12):1854–60.
8. Wen T, Dellon ES, Moawad FJ, et al. Transcriptome analysis of proton pump inhibitor-responsive esophageal eosinophilia reveals proton pump inhibitor-reversible allergic inflammation. J Allergy Clin Immunol. 2015;135(1):187–97.
9. Lucendo AJ, Molina-Infante J, Arias A, et al. Guidelines on eosinophilic esophagitis: evidence-based statements and recommendations for diagnosis and management in children and adults. United Eur Gastroenterol J. 2017;5(3):335–58.
10. Straumann A, Katzka DA. Diagnosis and treatment of eosinophilic esophagitis. Gastroenterology. 2018;154(2):346–59.
11. Molina-Infante J, Bredenoord AJ, Cheng E, et al. Proton pump inhibitor-responsive oesophageal eosinophilia: an entity challenging current diagnostic criteria for eosinophilic oesophagitis. Gut. 2016;65(3):524–31.
12. Hirano I, Moy N, Heckman MG, et al. Endoscopic assessment of the oesophageal features of eosinophilic oesophagitis: validation of a novel classification and grading system. Gut. 2013;62(4):489–95.
13. Straumann A, Conus S, Degen L, et al. Long-term budesonide maintenance treatment is partially effective for patients with eosinophilic esophagitis. Clin Gastroenterol Hepatol. 2011;9(5):400–9e1.
14. Hashimoto N. Rabeprazole is effective for bile reflux oesophagitis after total gastrectomy in a rat model. World J Gastrointest Pathophysiol. 2015;6(1):23–8.
15. Miner PB Jr. Review article: physiologic and clinical effects of proton pump inhibitors on non-acidic and acidic gastro-oesophageal reflux. Aliment Pharmacol Ther. 2006;23(Suppl 1):25–32.
16. Dellon ES, Hirano I. Epidemiology and natural history of eosinophilic esophagitis. Gastroenterology. 2018;154(2):319–32. e3.
17. Sato H, Honma T, Nozawa Y, et al. Eosinophilic esophagitis in Japanese patients: a mild and slow-progressing disorder. PLoS One. 2018;13(11):e0206621.
18. O'Shea KM, Aceves SS, Dellon ES, et al. Pathophysiology of eosinophilic esophagitis. Gastroenterology. 2018;154(2):333–45.
19. Kedika RR, Souza RF, Spechler SJ. Potential anti-inflammatory effects of proton pump inhibitors: a review and discussion of the clinical implications. Dig Dis Sci. 2009;54(11):2312–7.
20. Cheng E, Souza RF, Spechler SJ. Eosinophilic esophagitis: interactions with gastroesophageal reflux disease. Gastroenterol Clin N Am. 2014;43(2):243–56.
21. Dellon ES, Liacouras CA, Molina-Infante J, et al. Updated international consensus diagnostic criteria for eosinophilic esophagitis: proceedings of the AGREE conference. Gastroenterology. 2018;155(4):1022–33e10.
22. Zhang X, Cheng E, Huo X, et al. Omeprazole blocks STAT6 binding to the eotaxin-3 promoter in eosinophilic esophagitis cells. PLoS One. 2012;7(11):e50037.
23. Cheng E, Zhang X, Huo X, et al. Omeprazole blocks eotaxin-3 expression by oesophageal squamous cells from patients with eosinophilic oesophagitis and GORD. Gut. 2013;62(6):824–32.

Publisher's Note Springer Nature remains neutral with regard to jurisdictional claims in published maps and institutional affiliations.