Eosinophils and tissue remodeling: Relevance to airway disease

Salman Siddiqui, BM, FRCP, PhD,[a] Claus Bachert, MD, PhD,[b,c,d,e] Leif Bjermer, MD, PhD,[f] Kathleen M. Buchheit, MD,[g,h] Mario Castro, MD,[i] Yimin Qin, MD,[j] Hitasha Rupani, MD, PhD,[k] Hironori Sagara, MD, PhD,[l] Peter Howarth, MD, PhD,[m] and Camille Taillé, MD, PhD[n,o] *London, Southampton, and Middlesex, United Kingdom; Münster, Germany; Guangzhou, China; Stockholm and Lund, Sweden; Ghent, Belgium; Boston, Mass; Kansas City, Kan; Research Triangle Park, NC; Tokyo, Japan; and Paris, France*

The ability of human tissue to reorganize and restore its existing structure underlies tissue homeostasis in the healthy airways, but in disease can persist without normal resolution, leading to an altered airway structure. Eosinophils play a cardinal role in airway remodeling both in health and disease, driving epithelial homeostasis and extracellular matrix turnover. Physiological consequences associated with eosinophil-driven remodeling include impaired lung function and reduced bronchodilator reversibility in asthma, and obstructed airflow in chronic rhinosinusitis with nasal polyps. Given the contribution of airway remodeling to the development and persistence of symptoms in airways disease, targeting remodeling is an important therapeutic consideration. Indeed, there is early evidence that eosinophil attenuation may reduce remodeling and disease progression in asthma. This review provides an overview of tissue remodeling in both health and airway disease with a particular focus on eosinophilic asthma and chronic rhinosinusitis with nasal polyps, as well as the role of eosinophils in these processes and the implications for therapeutic interventions. Areas for future research are also noted, to help improve our understanding of the homeostatic and pathological roles of eosinophils in tissue remodeling, which should aid the development of targeted and effective treatments for eosinophilic diseases of the airways. (J Allergy Clin Immunol 2023;■■■:■■■-■■■.)

Key words: *Airway remodeling, eosinophil, asthma, chronic rhinosinusitis with nasal polyps*

Human tissue has an inherent ability to reorganize or restore its existing structure, so-called tissue remodeling, which enables normal development and growth and mediates responses to injury or inflammation. Increasing evidence demonstrates that both the upper and lower airways can respond to injury by repairing and replacing damaged tissue through processes including extracellular matrix (ECM) deposition and degradation and epithelial cell migration.[1] While in healthy tissue this remodeling process contributes to damage repair and growth, airway disease can occur where the same process is exaggerated and persists without normal resolution.[1,2] As the structural changes associated with airway remodeling develop during the course of disease, airway function often declines and the response to standard therapy becomes poor.[2]

Eosinophils are known historically as end-stage effectors in the inflammatory response to infection and in eosinophilic diseases such as eosinophilic asthma.[3] Now, as proposed over 10 years ago by Lee et al[4] with the local immunity and/or remodeling/repair hypothesis, eosinophils are also recognized as essential contributors to tissue homeostasis, repair, and remodeling.[5] Here, we review evidence for the role of eosinophils in tissue repair and remodeling in health and in airway disease. We focus on data from studies in severe eosinophilic asthma and chronic rhinosinusitis with nasal polyps (CRSwNP), 2 of the most studied eosinophilic airway diseases for which biologic treatments have been approved. Data from patients with these conditions, which are associated with substantial morbidity and in some cases an unmet treatment need, have provided valuable insights into the role of eosinophils in human airways, validating earlier murine model data.[6-11]

BIOLOGY OF REPAIR AND REMODELING

Healthy airways

During normal airway tissue development and growth, or in response to injury and/or inflammation, various structural adaptations contribute to repair and regeneration.[12] Tissue repair is driven by epithelial cell migration to the site of damage and deposition of a provisional matrix comprising ECM glycoproteins including fibronectin and vitronectin, as well as basement

From [a]the National Heart and Lung Institute, Imperial College London, London; [b]the Department of Otorhinolaryngology—Head and Neck Surgery, University Hospital of Münster; [c]the First Affiliated Hospital, Sun Yat-Sen University, International Airway Research Center, Guangzhou; [d]the Division of Ear, Nose, and Throat Diseases, Department of Clinical Science, Intervention, and Technology (CLINTEC), Karolinska Institute, Stockholm; [e]the Upper Airways Research Laboratory, Faculty of Medicine, Ghent University; [f]the Department of Clinical Sciences, Respiratory Medicine, and Allergology, Lund University; [g]the Jeff and Penny Vinik Center for Allergic Diseases Research, Brigham and Women's Hospital, and [h]the Department of Medicine, Harvard Medical School, Boston; [i]the Division of Pulmonary, Critical Care Medicine, University of Kansas School of Medicine, Kansas City; [j]the Global Medical Affairs, Global Specialty and Primary Care, GlaxoSmithKline, Research Triangle Park; [k]the Department of Respiratory Medicine, University Hospital Southampton National Health Service Foundation Trust, Southampton; [l]the Department of Medicine, Division of Respiratory Medicine and Allergology, Showa University, School of Medicine, Shinagawa-ku, Tokyo; [m]the Global Medical, Global Specialty and Primary Care, GlaxoSmithKline, Brentford, Middlesex; [n]the Pneumology Department, Reference Center for Rare Pulmonary Diseases, Bichat Hospital, Assistance Publique–Hôpitaux de Paris, and [o]the Institut National de la Santé et de la Recherche Médicale, Unit 1152, University of Paris Cité, Paris.

Received for publication January 6, 2023; revised May 15, 2023; accepted for publication June 2, 2023.

Corresponding author: Prof Salman Siddiqui, BM, FRCP, PhD, National Heart and Lung Institute, Imperial College London, Norfolk Place, London, W2 1PG, UK. E-mail: s.siddiqui@imperial.ac.uk.

0091-6749

© 2023 The Authors. Published by Elsevier Inc. on behalf of the American Academy of Allergy, Asthma & Immunology. This is an open access article under the CC BY license (http://creativecommons.org/licenses/by/4.0/).

https://doi.org/10.1016/j.jaci.2023.06.005

Abbreviations used

CLCs:	Charcot–Leyden crystals
CRSwNP:	Chronic rhinosinusitis with nasal polyps
CT:	Computed tomography
ECM:	Extracellular matrix
ECP:	Eosinophil cationic protein
MBP:	Major basic protein
MMP:	Matrix metalloproteinase

membrane components such as laminin and collagen IV (Fig 1).[12-17] In addition, underlying mesenchymal cells secrete ECM proteins and cytokines that contribute to airway repair and stimulate epithelial cell functions.[18] The spreading, migration, and proliferation of epithelial cells during epithelial repair requires the participation of integrins, which signal through matrix metalloproteinase (MMP)-dependent activation of TGF-β, a multipotent epithelial and mesenchymal cell growth factor.[19-21] Following airway injury, epithelial cells are also regulated by WNT/β-catenin signaling pathways, which play critical roles in the function and behavior of these cells during tissue regeneration.[22-24] Resolution of inflammation and tissue repair in healthy tissue requires the clearance of activated immune cells and production of lipid pro-resolving mediators that contribute to normal tissue restoration.[25]

Airway disease

Pathological airway remodeling is primarily considered a consequence of chronic injury and/or inflammation that leads to persistently altered airway wall structure and function.[26] Some studies (reviewed by Fehrenbach et al[12]) also report that airway features of remodeling in symptomatic children may be evident before a clinical diagnosis of asthma is made, and it is appreciated that mechanical stress, in the absence of inflammation, may promote tissue remodeling.[12] Primarily, the remodeling changes arise from dysregulated repair and regeneration pathways, leading to an exaggerated wound repair response culminating in the accumulation of (myo)fibroblasts and increased ECM deposition (Fig 1).[12-14] In asthma, ECM deposition is increased in the reticular basement membrane region, lamina propria, and submucosa, with deposited proteins including collagen (types I, III, and V), the adhesion proteins fibronectin and tenascin, plus proteoglycans that play roles in the interaction between fibrils and collagen fibrinogenesis, which are considered to be important in the functional consequences of the remodeling process.[27-30] Epithelial-mesenchymal transition, the transformation of epithelial cells into fibroblast-like mesenchymal cells due to loss of epithelial polarity and expression of mesenchymal proteins,[31-35] contributes to accumulation of fibroblast-like cells. Moreover, fibroblast transformation into myofibroblasts further increases ECM deposition.[36,37]

TGF-β mediates epithelial-mesenchymal transition[33] and stimulates fibroblasts to synthesize collagens types I and III, fibronectin, and proteoglycans.[38] TGF-β is activated by integrins, reactive oxygen species, and mechanical stress and stimulates downstream SMAD2/3 and SMAD4 signaling that mediate gene expression.[39] Increased levels of TGF-β are also associated with increased osteopontin, an ECM protein released by eosinophils that is implicated in the modulation of inflammation and fibrosis in diseased airways.[40-45]

ROLE OF EOSINOPHILS IN AIRWAY REPAIR AND REMODELING

Eosinophil biology and its relevance for repair and remodeling

Eosinophils are highly complex cells with a wide range of surface molecules and receptors. Key cell membrane receptors that define the unique biology of eosinophils include CCR3, which binds eotaxins, the lectin (carbohydrate-binding protein) Siglec-8, which can trigger eosinophil cell death when engaged, and IL-5RA.[46,47] Eosinophils also express receptors for multiple other cytokines and growth factors, including IL-4, IL-13, IL-33, thymic stromal lymphopoietin, and TGF-β.[47] They also express integrin adhesion molecules, through which they can interact with endothelial and airway cells.[48]

Eosinophils are equipped to modify their immediate tissue environment; they contain large specific cytoplasmic granules, which possess a crystalloid structure and can be released into target tissues on activation (Fig 1).[15] Granules are released by cytolysis or piecemeal degranulation, during which granule proteins are packaged into secretory vesicles that deliver specific proteins to the extracellular space while leaving intracellular granules intact.[49-51] Eosinophil granules contain 4 cationic proteins: major basic proteins (MBP [MBP1 and PRG2]), eosinophil cationic protein (ECP [RNASE3]), eosinophil-derived neurotoxin (RNASE2), and eosinophil peroxidase (EPO).[15] Eosinophil granules also store numerous cytokines, enzymes, and growth factors that promote airway remodeling and include the major mediator of airway remodeling, TGF-β, and MMPs. Fig 2 provides an overview of the eosinophil proteins involved in airway remodeling.[32-35,40-45,52-85] Activated eosinophils also form extracellular DNA traps (eosinophil extracellular traps) and Charcot–Leyden crystals (CLCs)/galectin (GAL)-10.[86,87] In patients with asthma, eosinophil extracellular traps negatively correlate with lung function and may have a hand in airway epithelial damage,[88,89] while CLCs/GAL-10 have been implicated in mucus production and the tenacity of mucus plug formation.[85] In patients with CRSwNP, eosinophil extracellular traps and CLCs have been strongly associated with disease severity, and their presence could negatively impact olfaction.[90]

Eosinophil recruitment to sites of remodeling in healthy tissue

Under normal physiological conditions, human eosinophils typically reside in the bone marrow, lung, thymus, adipose tissue, and gastrointestinal tract and are thought to spend ~1 day in the circulation, with longer periods at their physiological sites of action, where they assist in normal tissue processes.[91] In health, the eosinophil-specific CCL11, produced by local epithelial cells, endothelial cells, and fibroblasts, contributes to eosinophil recruitment to the airways.[92-94]

Eosinophil maturation is regulated by granulocyte-macrophage colony-stimulating factor (GM-CSF), IL-3, and IL-5.[95] Under normal conditions, GM-CSF is also thought to play a role in priming, activation, and survival of tissue eosinophils,[49] while IL-3 and IL-5 may promote trafficking of eosinophils.[96] Importantly, IL-5 supports eosinophil generation from

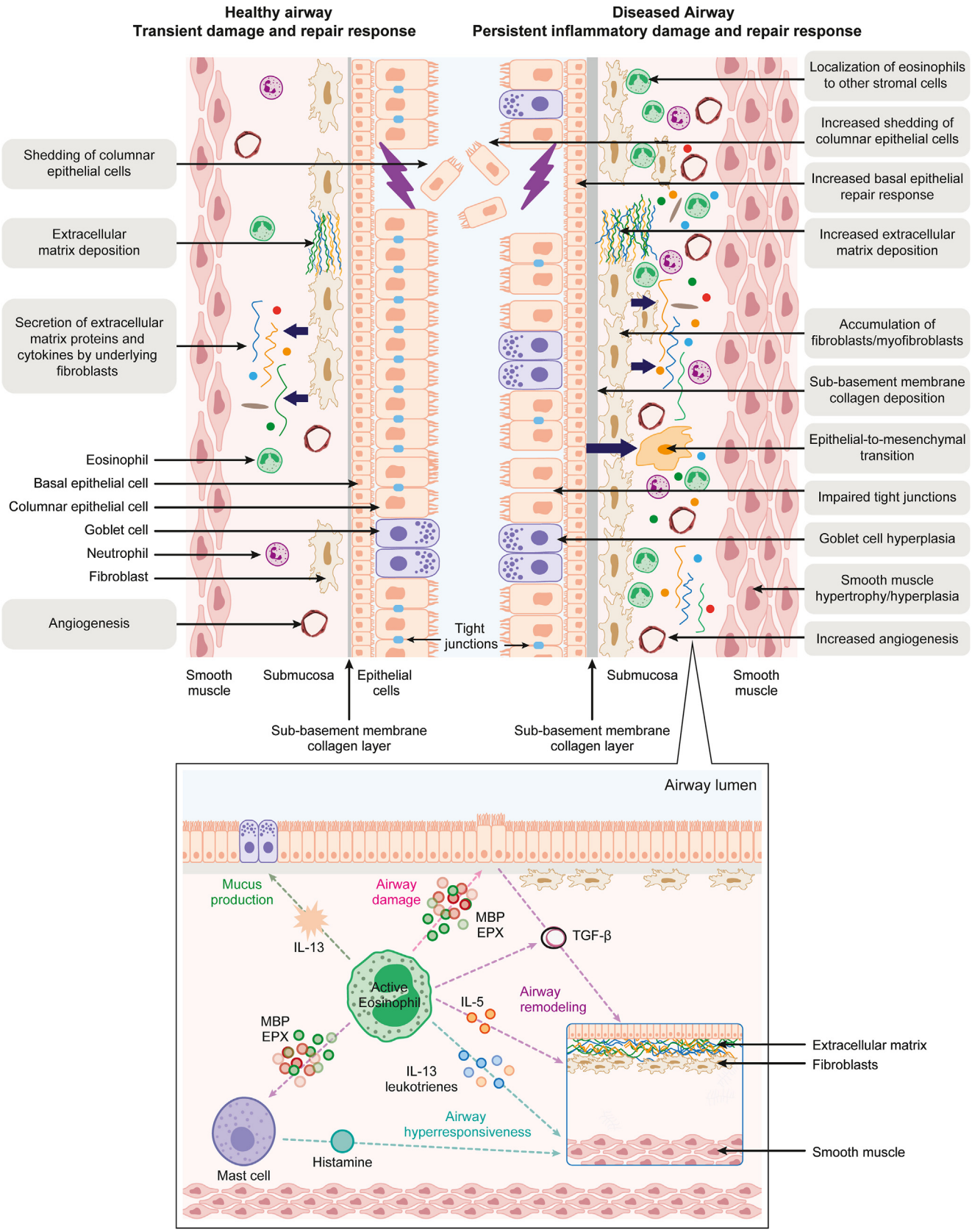

FIG 1. Airway remodeling in health and disease.[12-17] In airway disease, the transient tissue injury and subsequent tissue repair/regeneration seen in the healthy airway (*left*) are exaggerated, leading to persistent inflammation and repair (*right*). Callout panel adapted from Vatrella et al[17] (CC BY) and depicts the role of eosinophils in mediating airway damage, airway remodeling, airway hyperresponsiveness, and mucus production in type 2 asthma.

TGF-β	• Increased levels associated with increased levels of osteopontin, an extracellular matrix protein released by eosinophils that is implicated in the modulation of inflammation and fibrosis in diseased airways	• Induces epithelial-mesenchymal transition in primary airway epithelial cells • Promotes differentiation of fibroblasts to myofibroblasts and triggers their proliferation • Induces the expression of MMPs and TIMPs • Regulates subepithelial fibrosis by signaling through the Smad7 pathway • Induces the transcription and translation of mucin in bronchial epithelial cells • Epithelial/submucosal expression correlates with basement membrane thickness and fibroblast numbers • Induces hypertrophy and increased contractility of airway smooth muscle in vitro • Increased levels associated with increased levels of osteopontin
MMP-9 and TIMP-1		• Sputum MMP-9 and TIMP-1 concentrations are higher in patients with asthma compared with controls; the MMP-9/TIMP-1 ratio is lower in patients with asthma and chronic bronchitis, and positively correlates with FEV_1
VEGF, bFGF and angiogenin		• Bronchial biopsies from patients with asthma exhibit greater immunoreactivity to VEGF, bFGF and angiogenin; immunoreactivity to these factors positively correlates with vascular area
Specific granule proteins		• Damaged airway epithelium produces TGF-β • ECP induces fibroblast migration and inhibits fibroblast-mediated proteoglycan degradation • EDN stimulates MMP-9 in nasal epithelial cells
IL-17		• Fibroblasts isolated from bronchial biopsies produce more IL-6 and IL-11 (profibrotic cytokines) when stimulated by IL-17 • Promotion of airway smooth muscle cell migration • Cross-talk with TGF-β resulting in epithelial-to-mesenchymal transition • Stimulation of inactive fibrocyte maturation to fibroblasts, which deposit collagen within extracellular matrix
IL-13		• In vitro, IL-13 induces human bronchial epithelial cells to release TGF-β • Changes in goblet cell density
HB-EGF	• Recombinant HB-EGF promotes migration of airway smooth muscle cells in vitro	• Recombinant HB-EGF promotes migration of airway smooth muscle cells in vitro
NGF		• NGF causes migration of vascular smooth muscle cells and fibroblasts, and proliferation of epithelial cells and airway smooth muscle cells
Tissue factor	• Reduces airway hyperresponsiveness, airway inflammation and airway remodeling in asthmatic mice	
Thrombin		• Induces secretion of PDGF in nasal and bronchial epithelial cells, sufficient for stimulating proliferation of fibroblast and bronchial smooth muscle cells • Stimulates VEGF production from airway epithelial cells
Galectin	• Galectin 3 inhibition significantly lowered collagen deposition in an allergic lung inflammation mouse model • In a chronic asthmatic mouse model, Gal-3 gene treatment reduced lung collagen • Galectin 3 deficiency associated with decreased airway remodeling following allergen sensitization in mice • Recombinant galectin 10 crystals promote type 2 immunity and mimic features of asthma in naive mice • Anti-galectin 10 antibodies reversed the effects of CLCs and house dust mite challenge in a humanized mouse model, reducing airway inflammation, goblet cell metaplasia, bronchial hyperreactivity and IgE synthesis	• Galectin 1 mRNA concentrations are lower in sputum from children with versus without asthma; in vitro knockdown of Galectin 1 promotes proliferation, migration and phenotypic switching in human airway smooth muscle cells • Galectin 3 predicts remodeling-associated anti-IgE treatment responses in bronchial biopsy samples from patients with severe asthma • Galectin 3 stimulation associated with in vitro MMP-9 release from peripheral blood neutrophils from patients with asthma • Sputum galectin 10 concentrations are higher in patients with asthma compared with healthy individuals; levels significantly correlate with sputum eosinophil counts • High versus low baseline galectin 10 levels do not predict greater improvements in FEV_1 following 32 weeks of anti-IL-5 treatment

FIG 2. Eosinophil proteins and their roles in airway remodeling.[33-35,40-45,52-85] *bFGF*, Basic fibroblast growth factor; *EDN*, eosinophil-derived neurotoxin; *HB-EGF*, heparin-binding epithelial growth factor-like growth factor; *NGF*, nerve growth factor; *PDGF*, platelet-derived growth factor; *TIMP*, tissue inhibitor of metalloproteinases; *VEGF*, vascular endothelial growth factor.

$CD34^+$ bone marrow progenitors, enhancing their sensitivity to eotaxin-1, and sustaining their survival.[97-100] Although the role of type 2 innate lymphoid cells in airway homeostasis has yet to be fully elucidated, in other healthy tissues, they play a cardinal role in maintaining circulating IL-5 levels and, thereby, normal eosinophil levels in circulation and tissues.[101-103] Type 2 innate lymphoid cells are also responsible for eosinophil tissue recruitment in tumor regulation.[104]

Eosinophils potentially contribute to epithelial remodeling by inhibiting cell surface plasmin generation by bronchial epithelial cells, through the local release of TGF-β.[105] Therefore, the accumulation of eosinophils in bronchial walls may directly promote fibrin deposition and bronchial tissue repair/remodeling through this network.[105] Additionally, eosinophils produce key factors contributing to coagulation (tissue factor, thrombin) and fibrinolysis (plasminogen), which are required for wound healing and epithelial remodeling.[106] Fibrinogen, another coagulation and fibrinolysis factor, may be a chemoattractant for eosinophils[107] and is a specific trigger for cytolytic eosinophil degranulation.[108] Notably, eosinophils are frequently present at sites of high epithelial-mesenchymal turnover, during which new layers of differentiated epithelium are created from the mesenchymal unit; eosinophils are engaged by chemokines, growth factors, ECM proteoglycans, and morphogenetic ligands, secreted by mesenchymal cells.[9]

Eosinophils in pathophysiological airway remodeling

Eosinophil recruitment and activation is exaggerated in both lower and upper airway disease.[109-111] There is evidence directly linking the presence of eosinophils to disease-related airway remodeling. This is discussed below specifically for asthma and CRSwNP.

Asthma

Airway remodeling in asthma is caused by changes in the cellular matrix and ECM, which lead to narrowed airways due to thickened airway walls; this is a key pathologic feature of asthma.[27] Eosinophilic inflammation in the airway wall (and in induced sputum) has been related to the extent of reticular basement membrane thickening in asthma and eosinophilic bronchitis.[112,113] Furthermore, airway eosinophils in patients with asthma display hyperadhesiveness toward provisional ECM, interacting with ECM components via expression of specific integrins (CD11c, CD11b, β-5 integrins) and Toll-like receptors.[114-116] Eosinophils are among the major sources of airway TGF-β in asthma,[117] with TGF-β expression localized to eosinophils in the bronchi of patients with severe asthma.[70,118] Aside from eosinophils, TGF-β is also produced by other immune cells in addition to epithelial cells, endothelial cells, vascular and airway smooth muscle cells, and fibroblasts.[119] As we already described, TGF-β promotes myofibroblast transformation and facilitates the transcription of osteopontin.[120,121] This in turn further potentiates airway remodeling,[44] because myofibroblasts have increased synthetic capability for collagen and ECM proteins.[122,123] Osteopontin initiates the migration, adhesion, and proliferation of fibroblasts through cytokine signaling and macrophage activation.[124] TGF-β can also promote epithelial detachment and epithelial-mesenchymal transition,[33] which combined with impaired repair processes could in turn lead to increased ECM deposition. Eosinophil localization to the airway smooth muscle bundle has also been demonstrated in endobronchial biopsies from patients with severe, difficult-to-treat asthma.[113] In contrast, there is no evidence of elevated eosinophil counts in the airway smooth muscle of patients with asthma requiring Global Initiative for Asthma steps 1-4 treatment, patients with eosinophilic bronchitis, or healthy controls.[113]

Coculture of airway smooth muscle cells and pulmonary fibroblasts with peripheral blood eosinophils from patients with asthma (especially those with severe nonallergic eosinophilic asthma), versus healthy controls, alters the gene expression of ECM proteins, MMPs, tissue inhibitors of MMPs, and TGF-β, indicating relevant interactions between activated eosinophils and the structural airways in the remodeling process.[125] Furthermore, bronchial biopsies from patients with asthma show increased eosinophil accumulation, which is associated with poor epithelial integrity[126,127] and increased basement membrane thickness.[112,128,129] Notably, in these studies, eosinophil accumulation was associated with a decline in lung function. The presence of intraepithelial eosinophils in asthma is associated with endogenous airway hyperresponsiveness and *IL-5* expression;[130] high eosinophil numbers in the bronchial submucosa are a marker of an altered mucus-repair phenotype and epithelial damage.[127] Taken together, these results support eosinophil localization in areas of airway remodeling. This notion is strengthened by the findings of Drake et al,[131] who showed that eosinophils colocalized to airway epithelial sensory nerves in endobronchial biopsies from patients with eosinophilic asthma. Eosinophils contributed to substantial structural remodeling in these patients (demonstrated by increased epithelial nerve density); they also increased epithelial innervation and neuronally mediated airway responsiveness in a transgenic mouse model.

Exaggerated eosinophil recruitment and activation has other indirect effects, which include epithelial cell damage; this triggers repair pathway activation and epithelial-to-mesenchymal transition, which underpins airway remodeling.[34,132,133] Secondary effects of this response include increased exacerbation frequency and severity due to progressive airway remodeling, which stems from epithelial cell mechanostimulation during bronchoconstriction.[26,134] Frequent and repeated exacerbations themselves may also result in structural airway remodeling.[135-138] In addition, repeated bronchoconstriction induces goblet cell proliferation, subepithelial thickening, and mucus secretion, which together can lead to further airway obstruction.[26]

CRSwNP

CRS is characterized by inflammation of the paranasal sinuses; common symptoms include nasal congestion, excess mucus, hyposmia or anosmia, and facial pain.[139] Data on upper airway remodeling in CRSwNP are limited versus asthma; however, there are similarities between the remodeling changes observed in both diseases. For example, as with asthma, there is evidence in CRSwNP for extensive epithelial cell disruption,[140] basal cell hyperplasia,[141] goblet cell hyperplasia, and mucin hypersecretion.[142] There is also excess production of ECM components, with increased collagen and fibronectin, elevated numbers of ECM-producing myofibroblasts, and inflammation facilitated by eosinophil-derived CLCs, as well as an increase in ECM remodeling endopeptidases (MMP1, MMP2, MMP7, and

MMP9).[87,143-145] In addition, immunohistochemistry has demonstrated the sinonasal epithelium can transition to a mesenchymal phenotype, which correlates with airway fibrosis and inflammation.[146]

Elevated tissue eosinophil counts in CRSwNP, which may be facilitated by delayed eosinophil apoptosis,[147] have been associated with enhanced epithelial-mesenchymal signaling, with recent evidence suggesting that TGF-β–mediated epithelial-mesenchymal transition may promote nasal polypogenesis.[148] Furthermore, there is significant correlation among the number of epithelial eosinophils, the extent of epithelial damage, subbasement membrane collagen deposition, and the level of epithelial to mesenchymal transition in patients with CRSwNP.[149,150] At the site of epithelial barrier defects, extracellular eosinophilic traps can form in patients with CRSwNP, likely as a protective response against pathogenic bacteria.[86] Furthermore, there is a strong correlation between expression of the eosinophil protein galectin-10 and CRSwNP severity.[151] Some studies have demonstrated correlations between basement membrane thickening and elevated levels of tissue eosinophils in CRSwNP.[146,149] Features of remodeling in CRS have also been associated with tissue eosinophilia and eosinophil activation.[152]

Tissue edema in nasal polyps has been linked to an imbalance between coagulation factor expression and fibrinolytic activity, leading to increased fibrin accumulation, with the resultant fibrin scaffold trapping plasma proteins to enhance edema.[153] Eosinophils are involved in this process through the release of tissue factor[154] (which enhances initiation of the clotting cascade) and MBP/eosinophil peroxidase (EOP) basic proteins. These inhibit thrombomodulin, a potent anticoagulant, thereby impairing fibrin breakdown.[155] Tissue plasminogen activator, which usually plays a role in fibrin degradation, is decreased in CRSwNP.[156] While the fibrinolytic urokinase-type plasminogen activator is increased in CRSwNP (especially in inflammatory cells) and correlates with ECP, excessive urokinase-type plasminogen activator expression might interfere with the normal TGF-β–activated feedback mechanism of urokinase-type plasminogen activator in CRSwNP, resulting in nasal polyp edema.[157]

Role of IL-5 in pathophysiological airway remodeling

Through its well-known effects on eosinophils, IL-5 is likely to contribute to airway remodeling. Via binding to IL-5RA, IL-5 promotes the maturation, activation, proliferation, and migration of eosinophils as well as their survival within the airways.[158] IL-5 also supports eosinophil generation from $CD34^+$ bone marrow progenitors, enhancing their sensitivity to eotaxin-1, and sustaining their survival.[97-100] However, functional IL-5RA is also expressed on basophils, mast cells, plasma cells, and bronchial epithelial cells, as well as airway fibroblasts, with effects on the latter 2 functional cells being of particular relevance to tissue remodeling.[159-162] The enhanced airway collagen synthesis observed in asthma may be driven by the direct activating effect of IL-5 on fibroblasts, with functional IL-5RA upregulated in asthmatic lung fibroblasts versus healthy controls.[162] IL-5 is also associated with increased levels of airway collagen in allergen sensitivity (which is increased in asthma).[163] In addition, the downregulation of epithelial tight junction genes by IL-5 may be a factor that increases the susceptibility of epithelium to eosinophilic damage.[159] As further evidence of the importance of eosinophils and IL-5 to asthma-related airway remodeling, anti–IL-5 biologic therapy is associated with reduced airway eosinophil counts and decreased airway remodeling and proximal airway wall thickness (assessed by ECM deposition and thoracic computed tomography [CT] scanning, respectively), in patients with eosinophilic asthma.[164] In patients with asthma, nasal polyposis, and a confirmed diagnosis of aspirin-exacerbated respiratory disease, IL-5 inhibition with mepolizumab leads to decreased inflammatory eicosanoid production and upregulation of epithelial cell transcripts involved in tight junction pathways and cilium organization,[160] potentially impacting the strength of the epithelial barrier and evidencing the local detrimental effect of IL-5 exposure on epithelial function and integrity (a possible contributor to the susceptibility of epithelial cells to eosinophil-directed damage). Consistent with the importance of eosinophils and IL-5 to the abnormal tissue remodeling that underlies nasal polyp formation, levels of IL-5 and ECP (an eosinophil activation marker) in resected polyp tissue have both been identified as independent predictors of further nasal polyp recurrence.[165] Together, these data support a central role for IL-5 in pathological airway remodeling.

PHYSIOLOGICAL CONSEQUENCES OF EOSINOPHIL-DRIVEN AIRWAY REMODELING

The airway changes described in this review are pathological features of eosinophilic airway disease and contribute to the clinical manifestations seen in patients (Fig 3).[32-35,166-171] In severe eosinophilic asthma, the structural effects of chronic eosinophil-driven airway remodeling (goblet cell hyperplasia, decreased epithelial cell and cartilage integrity, subepithelial collagen deposition with increased thickness of the reticular basement membrane in the bronchial mucosa, increased airway smooth muscle cell mass, mucus plug persistence, and angiogenesis of the airways) have been postulated to explain the persistent airflow obstruction seen in some patients.[128,172-179] While it is acknowledged that bronchial wall thickness measurements using CT scanning can be influenced by reversible factors such as edema, airway secretions, and inflammatory cell infiltration,[129,180] quantitative CT imaging studies, in some cases supported by endobronchial biopsies, have demonstrated proximal airway wall thickness/wall area and structural changes to predict airflow limitation and lung function impairment (measured by reduced FEV_1, postbronchodilator percentage predicted FEV_1, FEV_1/forced vital capacity, and forced expiratory $flow_{25\%-75\%}$), in patients with asthma.[181-183] Several cross-sectional studies in patients with asthma have demonstrated increased odds of worse lung function[184,185] and worse airflow obstruction over time[186] in patients with eosinophilic inflammation. In addition, epidemiologic data have linked elevated blood eosinophils to worse lung function outcomes, irrespective of the diagnosis of asthma.[187,188] Finally, higher blood eosinophil counts in children with untreated asthma are predictive of lower growth in FEV_1 and forced vital capacity during adolescence.[189] Interestingly, lung computational models have demonstrated that (1) small airway narrowing is associated with clinically relevant deterioration in both asthma control and quality of life, and (2) biologics targeting type 2 inflammation could reverse small airway narrowing, suggesting that early intervention could potentially modify the disease course.[190] Altogether these data show that as a result of airway remodeling, patients may experience irreversible airway

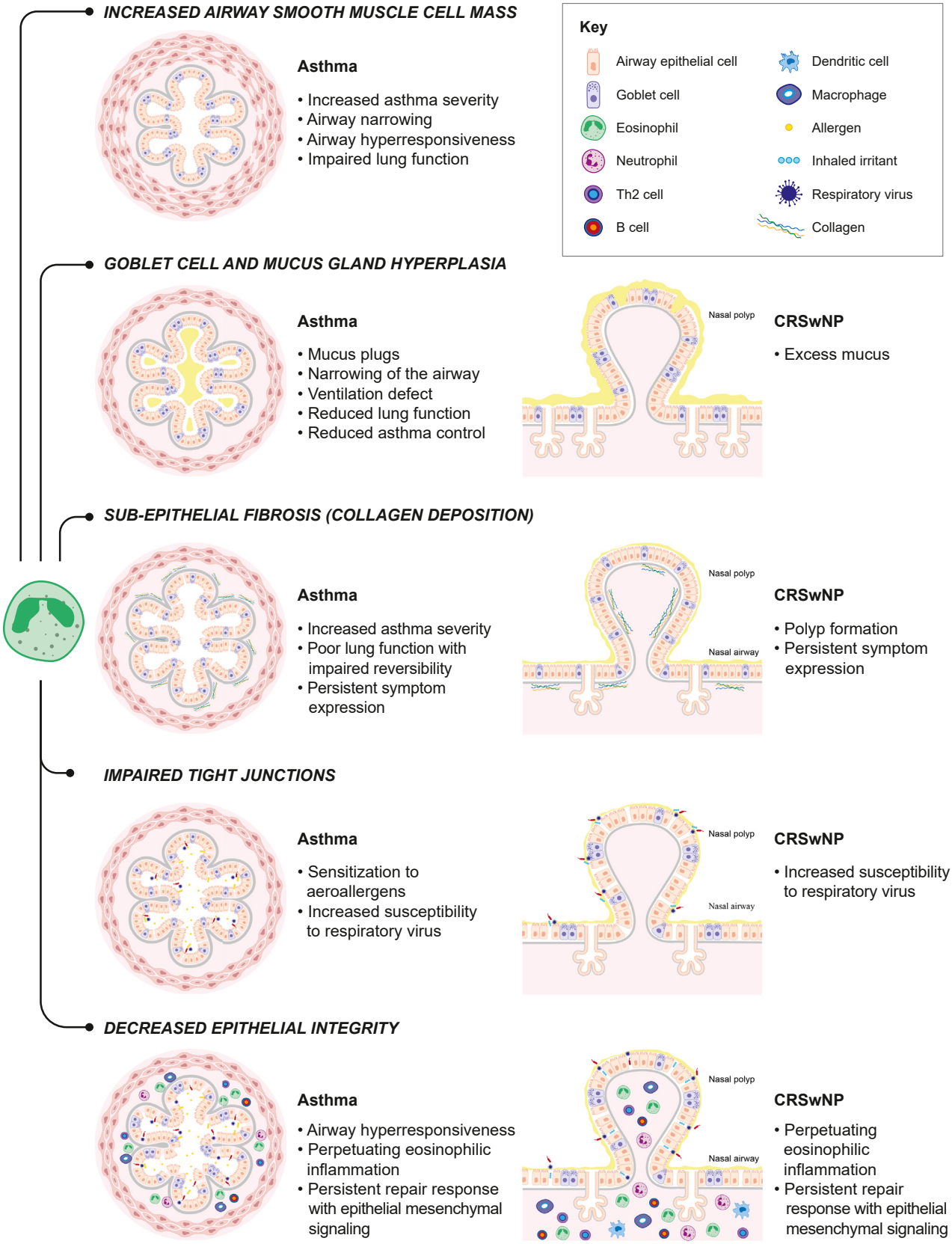

FIG 3. Physiological consequences of eosinophil-driven remodeling.[32-35,166-171] Schematic cross-sections showing the airways in patients with asthma (*left*) and the nasal mucosa in patients with CRSwNP (*right*). These schematic cross-sections illustrate the impact of eosinophilic tissue inflammation in the lower and upper airways and the consequences of this in asthma and CRSwNP.

obstruction leading to worsening of lung function, airway thickening, and air trapping and potentially reduced response to bronchodilators.

In CRSwNP, excess mucus can be explained by goblet cell hyperplasia and mucin hypersecretion,[142] downstream consequences of upper airway remodeling. Furthermore, extracellular connective tissue matrix degradation is likely to be an important pathological component in CRSwNP, contributing to the loosening of tissue architecture, tissue expansion, and pseudocyst formation.[1]

THERAPEUTIC IMPLICATIONS OF EOSINOPHIL-DRIVEN AIRWAY REMODELING

Given the substantial contribution of airway remodeling to symptom development and persistence in patients with airway diseases, targeting the remodeling component of the disease is an important therapeutic consideration. Currently, the only available treatment that directly targets airway remodeling is bronchial thermoplasty, a bronchoscopy procedure that reduces airway smooth muscle cell mass through the local delivery of controlled radiofrequency energy. While histopathological effects are distinct in different disease endotypes/phenotypes, bronchial thermoplasty helps control asthma in patients with severe disease, thus demonstrating the therapeutic value in targeting several components of bronchial remodeling in this population.[191-195]

There is evidence that suppressing eosinophilic inflammation may reduce airway remodeling and disease progression among patients with airway disease. For example, *in vitro* blocking of eosinophil arginyl-glycyl-aspartic acid–binding integrins significantly reduces eosinophil adhesion to airway smooth muscle cells, resulting in reduced eosinophil-mediated *TGFB1, WNT5A*, and ECM protein gene expression and reduced proliferation in airway smooth muscle cells.[196] In animal model studies, eosinophil-deficient mice showed attenuation of airway remodeling,[7,197] with similar results demonstrated in IL-5 knockout mice.[8] In humans with asthma, reduced eosinophil numbers are significantly associated with greater improvements in airway hyperresponsiveness, when tested with methacholine treatment.[198] Of note, in patients with asthma and rhinitis, house dust mite sublingual immunotherapy in addition to pharmacotherapy reduced eosinophilic airway inflammation while improving symptoms and pulmonary function.[199] Finally, in a phase II study of patients with eosinophilic asthma, the eosinophil-depleting drug dexpramipexole improved lung function and reduced airway eosinophil granule proteins cognate with the magnitude of reduction in blood eosinophils.[200] Together, these studies demonstrate that eosinophils are a critical factor driving airway remodeling in asthma and may be an important therapeutic target.

Biologic intervention

Biologics currently used in the treatment of severe asthma and CRSwNP have the potential to reverse or reduce the impact of airway remodeling through their effects on eosinophils. While work to determine whether these agents can reduce or reverse remodeling is still in its infancy, there are some key studies that support their role in reversing airway remodeling (Table I).[87,160,164,168,201-218] Several asthma studies show that the humanized mAb mepolizumab, which targets IL-5 (the primary cytokine responsible for differentiation, activation, and survival of eosinophils, which is also of relevance to airway remodeling through its direct noneosinophilic effects on structural airway cells),[12,219] reduces airway eosinophil numbers and ECM/inflammatory mediator expression as well as reducing airway wall thickness and wall area and lowering rates of FEV_1 decline.[160,164,207,209,214] In addition, the anti-IL-5RA antibody, benralizumab, can reduce eosinophil counts and numbers of tissue myofibroblasts, as well as improve hyperinflation, airway dysfunction, and peripheral resistance in patients with asthma.[168,204,213] The anti-IL-4/IL-13 antibody, dupilumab, improves epidermal remodeling and inflammation in lesional and healthy skin among patients with severe atopic dermatitis (detected by dynamic optical coherence tomography), suggesting that broader targeting of type 2 inflammatory cytokines may have anti-remodeling effects.[212] However, dupilumab did not modify airway tissue eosinophil numbers in a recent randomized, placebo-controlled study in patients with persistent asthma (EXPEDITION [Evaluation of Dupliumab's Effects on Airway Inflammation in Patients With Asthma]; NCT02573233), and there are no published studies demonstrating an effect in modifying airway remodeling in asthma.[205] Finally, the mAb tezepelumab, which blocks thymic stromal lymphopoietin, partially reduces airway tissue eosinophil numbers in asthma, but evidence to date does not support a significant impact on airway remodeling changes, although there was evidence of reduced airway hyperresponsiveness and reduced mucus plugging.[206,215,220] Studies in patients with CRSwNP have demonstrated reductions in polyp size following treatment with omalizumab, mepolizumab, benralizumab, or dupilumab,[201-203,208,210,216,217,221] suggesting an effect of anti-IgE, anti–type 2 cytokine, and eosinophil-targeting biologics on nasal/sinus mucosa remodeling. In contrast, near-complete elimination of eosinophils in nasal polyp tissue was achieved with dexpramipexole in CRSwNP, without any reduction in polyp size.[211] However, dexpramipexole has been shown in asthma to reduce airway eosinophil granule proteins cognate with the magnitude of reduction in blood eosinophils and to improve lung function,[200] a physiological feature that was also evident in the dexpramipexole EXHALE (Dexpramipexole Dose-Ranging Biomarker Study in Subjects With Eosinophilic Asthma; NCT04046939) trial.[222] This suggests that the failure of dexpramipexole to improve symptoms in CRSwNP is not a failure of the drug but that modifying eosinophilic inflammation alone in CRSwNP may be insufficient to deliver clinical benefit. Notably, in the SYNAPSE (Effect of Mepolizumab in Severe Bilateral Nasal Polyps; NCT03085797) study, which demonstrated significant reductions in polyp size with mepolizumab treatment overall, 49.5% of patients did not experience a ≥1-point improvement in total endoscopic nasal polyp score.[210] This indicates there is heterogeneity in response to targeting IL-5 in patients with severe, recurrent nasal polyps requiring further surgery. A *post hoc* analysis of SYNAPSE found no clear differences in baseline clinical characteristics between patients considered to be mepolizumab responders versus nonresponders, highlighting a need for further investigation of the underlying endophenotypic characteristics that may predict treatment response.[223] With further research, the effects of biologic therapies on airway remodeling may provide specific clues as to the underlying mechanisms of this process. In addition, CRSwNP pathobiology may change at different stages of the disease, with potential differences in the factors that drive nasal

TABLE I. Effects of eosinophil-targeting therapies on tissue remodeling

Treatment	Study	No. patients	Patient characteristics	Treatment arms/schedule	Method of measuring remodeling/end points of interest	Results summary (study drug vs placebo/no study drug)
Asthma						
Mepolizumab	Biopsy study[207]	24	Mild atopic asthma Treated only with β_2 agonists	Mepolizumab 750 mg IV or placebo	Thickness and density of markers of airway remodeling: tenascin, lumican, and procollagen III in the reticular basement membrane	Significantly decreased expression of tenascin, lumican, and procollagen III in bronchial reticular basement membrane Reduced percentage and number of eosinophils expressing TGF-β
	Randomized, double-blind, placebo-controlled, parallel-group study[164]	61	Refractory eosinophilic asthma History of recurrent severe exacerbations	Mepolizumab 750 mg IV or placebo every 4 weeks for 12 infusions	CT assessment of airway wall geometry	Reduced eosinophil counts in bronchial biopsy specimens (2.1-fold), bronchoalveolar-lavage specimens (8.2-fold), and bronchial-wash specimens (16.0-fold) Significantly reduced airway wall area (between-group difference in change from baseline: 1.1 mm^2) and total wall area (between-group difference in change from baseline: 1.5 mm^2)
	Real-world, longitudinal analysis[209]	318	Severe asthma	Mepolizumab 100 mg SC vs no mepolizumab	Lung function decline	Significant reduction in FEV_1 decline (0.6% vs –11.1% predicted/year)
	Single-visit study[160]	36	Aspirin-exacerbated respiratory disease with asthma and nasal polyposis	Mepolizumab 100 mg SC for ≥3 months vs matched controls not receiving mepolizumab	Circulating granulocytes, nasal scraping transcripts, eosinophilic cationic protein, tryptase and antibody levels, and urinary and nasal eicosanoid levels	Decreased production of inflammatory eicosanoids Upregulated tight junction proteins (likely due to decreased IL-5 signaling on tissue mast cells, eosinophils, and epithelial cells)
	Longitudinal study[214]	15	Severe eosinophilic asthma	1 year of mepolizumab treatment, pre- vs posttreatment	Chest high-resolution CT and endobronchial ultrasound	Significant reduction in bronchial wall thickness (1.30 vs 1.26 mm) and its layers (0.186–0.2 vs 0.015–0.88 mm) Reduction in bronchial wall area, significant in patients with longer asthma duration and lower baseline FEV_1 (70.08% vs 62.27%)
Benralizumab	Biopsy study[204]	25	Eosinophilic asthma	Single benralizumab 1 mg/kg IV infusion or placebo, benralizumab 100 mg or 20 mg SC every 4 weeks for 3 months or placebo[218]	Airway smooth muscle mass in bronchial biopsies (using α-smooth muscle actin immuno-staining)	Significant reduction in eosinophil count in airway lamina propria (between-group difference in percentage reduction: 88%) Nonsignificant reduction in airway smooth muscle mass (between-group difference in change from baseline: −2.6%) Nonsignificant reduction in number of tissue myofibroblasts (between-group difference in change from baseline: −21.7)
	Multicenter, randomized, double-blind, parallel-group, placebo-controlled, phase IIIb study[213]	233 (40 in the plethysmography substudy)	Severe eosinophilic asthma	Benralizumab 30 mg SC or placebo on days 0, 28, and 56	Whole-body plethysmography assessment of lung capacity parameters	Early nonstatistically significant improvements in whole-body plethysmography assessment of hyperinflation (change from baseline at day 84 in residual volume: −415 vs −208 mL; inspiratory capacity: 119 mL vs −268 mL)
	Single-dose study[168]	29	Poorly controlled asthma (as defined by GINA	Benralizumab 30 mg on day 0 and day 28, pre- vs posttreatment	Airway dysfunction (VDP) and peripheral resistance ($R_{5\text{-}19\ Hz}$)	Significantly improved mean VDP on day 28 Significantly improved $R_{5\text{-}19\ Hz}$ on day 28
	Randomized, phase II study[205]	42	Persistent asthma	Dupilumab 300 mg SC (with a 600-mg loading dose) or placebo every 2 weeks for 12 weeks	Eosinophil, mast cell, and lymphocyte levels in the bronchial mucosa	Nonsignificant change from baseline in eosinophil count in the bronchial mucosa (−6.04 vs 5.80 cells/mm^2 at week 12)

(Continued)

TABLE I. *(Continued)*

Treatment	Study	No. patients	Patient characteristics	Treatment arms/schedule	Method of measuring remodeling/end points of interest	Results summary (study drug vs placebo/no study drug)
Tezepelumab	Double-blind, randomized, placebo-controlled, parallel-group, phase II study[206]	99	Uncontrolled, moderate-to-severe asthma	Tezepelumab 210 mg or placebo every 4 weeks for 28 weeks (extended up to 52 weeks if necessary due to COVID-19–related disruption)	Reticular basement membrane thickness and epithelial integrity (proportions of denuded, damaged, and intact epithelium)	Reduced airway submucosal eosinophils (89% vs 25% at end of treatment) No significant impact on reticular basement membrane thickness (between-group difference in change from baseline: −0.16 μm at end of treatment) or epithelial integrity (between-group difference in change from baseline: −2.20% at end of treatment) Significantly reduced airway hyperresponsiveness in an exploratory analysis (between-group difference in PD_{15} of mannitol: 138.8 mg at end of treatment)
	Double-blind, randomized, placebo-controlled, phase II study[215]	40	Asthma and airway hyperresponsiveness	Tezepelumab 700 mg or placebo IV every 4 weeks for 12 weeks	Change in airway hyperresponsiveness and inflammation	Nonsignificant increase in change in PD_{15} from baseline to week 12 (1.9 vs 1.0) Significantly reduced airway tissue (74% reduction vs 28% increase from baseline) and bronchoalveolar lavage eosinophils (75% vs 7% reduction from baseline)
CRSwNP						
Omalizumab	Two double-blind, randomized, placebo-controlled studies[87]	138 and 127	CRSwNP inadequately controlled with intranasal corticosteroids	Omalizumab 75-600 mg SC or placebo every 2 or 4 weeks for 24 weeks	Total endoscopic NP score	Significantly improved total endoscopic NP score (−1.08 vs +0.06 and −0.90 vs −0.31)
Omalizumab	Prospective, real-world study in tertiary care center[217]	22	Difficult-to-treat CRSwNP	Omalizumab SC injections every 4 weeks for 24 weeks, pre- vs posttreatment	Total endoscopic NP score	Significantly improved total endoscopic NP score (1.00)
Mepolizumab	Double-blind, randomized, placebo-controlled study[208]	30	CRS with primary or recurrent NP who had failed standard of care treatment	Two single IV injections (28 days apart) of mepolizumab 750 mg or placebo	Total endoscopic NP score Blood eosinophil counts	Significantly improved total endoscopic NP score (between-group difference: −1.30 at week 8) Significant reduction in blood eosinophil count
	Double-blind, randomized, placebo-controlled, phase III study[203,210]	407	Recurrent, refractory, severe, bilateral CRSwNP	Mepolizumab 100 mg SC or placebo plus standard of care every 4 weeks for 52 weeks	Total endoscopic NP score based on centrally read endoscopies Baseline blood eosinophil count	Significantly improved total endoscopic NP score (between-group difference: −0.73) Significant reductions in blood eosinophil counts (between-group ratio: 0.19) More patients with baseline blood eosinophil counts ≥150 or ≥300 cells/μL had ≥1-point improvement from baseline in total endoscopic NP score (49.5% vs 28.1% and 50.4% vs 28.1%) and ≥3-point improvement from baseline in nasal obstruction VAS score (59.1% vs 34.1% and 59.0% vs 32.4%) with mepolizumab vs placebo at week 52
Benralizumab	Randomized, placebo-controlled, phase III study[202]	413	Severe CRSwNP	Benralizumab 30 mg or placebo every 4 weeks for the first 3 doses and every 8 weeks thereafter	Total endoscopic NP score Blood eosinophil counts	Significant improvement in total endoscopic NP score (between-group difference: −0.570 at week 20) Some evidence (non-significant) of differential effects of blood eosinophil counts on total endoscopic scores (data not shown)

(Continued)

TABLE I. *(Continued)*

Treatment	Study	No. patients	Patient characteristics	Treatment arms/schedule	Method of measuring remodeling/end points of interest	Results summary (study drug vs placebo/no study drug)
	Double-blind, randomized, placebo-controlled, phase II study[216]	24	Severe NP	Benralizumab 30 mg or placebo	Total endoscopic NP score and CT scan Blood eosinophil count	Significantly improved total endoscopic NP score (−0.9 at week 20) and CT polyp score (−4.2 at week 20) vs baseline Significant reduction (97%) in blood eosinophil count vs baseline Blood eosinophil count/positive allergen skin prick test ratio significantly predicts reductions in total endoscopic NP score and CT scan polyp score
Dupilumab	Two double-blind, randomized, placebo-controlled, phase III studies[201]	276	Severe uncontrolled CRSwNP	Dupilumab 300 mg every 2 weeks or placebo for 24 weeks (SINUS-24) Dupilumab 300 mg every 2 weeks for 52 weeks, placebo for 52 weeks, or dupilumab every 2 weeks for 24 weeks followed by every 4 weeks for the remaining 28 weeks	Total endoscopic NP score Blood eosinophil count	Significantly improved total endoscopic NP score (treatment difference: −1.89 at week 24, −1.80 at week 52) Transient, nonsignificant increase in blood eosinophil count with dupilumab (change from baseline: 0.02 to 0.15 gL at week 24)
Dexpramipexole	Prospective, open-label study[211]	16	CRSwNP	Dexpramipexole 150 mg twice daily, pre-vs posttreatment	Total endoscopic NP score Blood eosinophil count Eosinophil levels in NP biopsies	No significant change in total endoscopic NP score (0.07 at month 6) Significant reduction (94%) in blood eosinophil count Significant reduction (97%) in NP eosinophilia

COVID-19, Coronavirus disease 2019; *GINA*, Global Initiative for Asthma; *IV*, intravenous; PD_{15}, 15th percentile lung density; *SC*, subcutaneous; *SINUS-24*, A Controlled Clinical Study of Dupilumab in Patients With Bilateral Nasal Polyps; *VAS*, visual analog scale; *VDP*, ventilation defect percentage.

polyp formation versus those that maintain the edematous polyp state. Accordingly, further work is needed to fully explore and understand the impact of eosinophil-targeting therapies on remodeling in airway disease and whether alterations in eosinophil activation (rather than eosinophil numbers) or the effects of IL-5 inhibition that extend beyond eosinophils themselves, are mechanisms contributing to clinical impact.

FUTURE DIRECTIONS AND UNANSWERED QUESTIONS

While our understanding of the role of eosinophils in airway remodeling in health and disease is improving, there are still many unanswered questions. A key objective will be to further understand the relationship between reductions in tissue eosinophil numbers, eosinophil activation status, and airway remodeling in airway diseases, as well as evaluating the relevance of the eosinophil-independent local effects of IL-5 on airway structural biology. Fully characterizing the differences between eosinophils involved in homeostasis and those involved in disease, observed in both mouse and human studies,[224,225] will also be important. To this end, data on the phenotype and function of airway-resident eosinophils versus those in other tissues will be useful. Assessing genetic and inflammatory interactions and overcoming technical barriers to performing single-cell sequencing of eosinophils (eg, eosinophil RNases) will be integral to addressing this. In particular, studies using mass cytometry techniques such as cytometry by time of flight and tissue imaging mass cytometry can produce multidimensional data to help characterize subgroups of eosinophils with different expression profiles (and identify their presence in different disease phenotypes), in addition to establishing eosinophil-stromal cell interactions in the tissue microenvironment.[111,226,227] There is also a need to understand airway changes during clinical remission, particularly remission induced by eosinophil-targeting biologics. Furthermore, the inclusion of end points more relevant to airway remodeling in clinical trials will help determine whether currently available eosinophil-targeting therapies can reduce the clinical effects of remodeling. Indeed, it will be important to determine whether airway remodeling becomes irreversible and, if so, what the contributors to and markers of irreversible remodeling are. Further characterization of the molecular signaling pathways involved in eosinophil migration and activation that initiate airway remodeling will also be useful in identifying novel molecular targets for therapy. For example, RAC1 has recently been identified as a target that has the potential to simultaneously reduce airway smooth muscle hyperplasia, airway hyperresponsiveness, and inflammation.[228]

Although data on eosinophil-driven remodeling in CRSwNP are beginning to emerge, they are sparser than in asthma. As such, further information on the etiologic role of eosinophils and downstream signaling pathways in the pathophysiology of tissue remodeling in patients with CRSwNP is needed. It will be important to further determine what effect the reduction of eosinophil levels has on tissue remodeling and whether any of the effects of anti–IL-5 biologic therapy are related to inhibitory effects on structural cells expressing IL5R, additional to those resulting from modification of local tissue eosinophilic inflammation.

CONCLUSION

There is growing evidence that tissue remodeling contributes to both upper and lower airway disease. While evidence for remodeling in upper airway disease does not yet fully correspond with that seen in the lower airways, there are aspects consistent to both, such as epithelial cell disruption and excess ECM production. Furthermore, there is now evidence that eosinophil localization is important in upper airway remodeling, a notion already established in the lower airways. Our knowledge of eosinophils in tissue homeostasis and remodeling in health and eosinophil-mediated diseases is improving and has highlighted further therapeutic possibilities. Nonetheless, there is a need to further characterize the roles of eosinophils in the tissue remodeling that contributes to eosinophil-mediated disease and to help develop therapeutic interventions that attenuate and even reverse the effects of remodeling and thereby improve clinical outcomes and symptoms. Such evidence is needed to understand whether disease modification and prevention of disease progression are realistic outcomes of targeted therapy, especially in asthma, as the ability to fundamentally alter the biology underlying exaggerated airway remodeling processes is a key goal of disease-modifying asthma therapy.

DISCLOSURE STATEMENT

Editorial support was funded by GSK. This manuscript was also supported by the NIHR Imperial Biomedical Research Centre (BRC), in the form of time contribution from a BRC Principle Investigator. The views expressed are those of the authors and not necessarily those of the NIHR or the Department of Health and Social Care.

Disclosure of potential conflict of interest: S. Siddiqui has received speaker fees from GSK, AstraZeneca, Chiesi, Boehringer Ingelheim, and Novartis; participates on advisory boards for GSK, AstraZeneca, Chiesi, Boehringer Ingelheim, Novartis, Knopp Biotech, Munipharma, ERT Medical, and Owlstone Medical; is a member of the European Respiratory Society Science Council and the UK Medical Research Council; and is a cofounder of Eupnoos Ltd. C. Bachert is an advisory board member and speaker for Novartis, GSK, AstraZeneca, Sanofi, ALK-Abelló, and Mylan. L. Bjermer reports lecture fees from AstraZeneca, Boehringer Ingelheim, Chiesi Pharma AB, GSK, Novartis, and Sanofi Genzyme. K. M. Buchheit reports serving on advisory boards for GSK, AstraZeneca, Sanofi, and Regeneron; and speaking for GSK. M. Castro reports grants/research support from the National Institutes of Health, American Laryngological Association, Patient-Centered Outcomes Research Institute, AstraZeneca, Gala Therapeutics, Genentech, GSK, Novartis, Pulmatrix, Sanofi-Aventis, Shionogi, and Theravance; consulting fees/honoraria from Allakos, Amgen, Arrowhead, AstraZeneca, Genentech, Merck, Novartis, OM Pharma, Regeneron, Sanofi, Teva, Pfizer, and Pioneering Medicines; and royalties from Aer Therapeutics and Elsevier. Y. Qin and P. Howarth are employees of GSK and own stocks/shares. H. Rupani reports speaker fees and investigator-led grant funding from GSK and AstraZeneca; and support for meeting attendance/travel from AstraZeneca. H. Sagara reports lecture fees from GSK, AstraZeneca, Sanofi, Novartis, and Boehringer Ingelheim. C. Taillé reports lecture or advisory board fees and grants from AstraZeneca, Sanofi, GSK, Chiesi, and Novartis.

Laura Gardner, PhD, CMPP, at Fishawack Indicia Ltd, UK, part of Fishawack Health, provided editorial support (in the form of writing assistance, including development of the initial draft from the author discussions, assembling tables and figures, collating authors comments, grammatical editing, and referencing).

REFERENCES

1. Samitas K, Carter A, Kariyawasam HH, Xanthou G. Upper and lower airway remodelling mechanisms in asthma, allergic rhinitis and chronic rhinosinusitis: the one airway concept revisited. Allergy 2018;73:993-1002.
2. Chung KF, Godard P, Adelroth E, Ayres J, Barnes N, Barnes P, et al. Difficult/therapy-resistant asthma: the need for an integrated approach to define clinical phenotypes, evaluate risk factors, understand pathophysiology and find novel therapies. ERS Task Force on Difficult/Therapy-Resistant Asthma. European Respiratory Society. Eur Respir J 1999;13:1198-208.
3. Long H, Liao W, Wang L, Lu Q. A player and coordinator: the versatile roles of eosinophils in the immune system. Transfus Med Hemother 2016;43:96-108.
4. Lee JJ, Jacobsen EA, McGarry MP, Schleimer RP, Lee NA. Eosinophils in health and disease: the LIAR hypothesis. Clin Exp Allergy 2010;40:563-75.
5. Chusid MJ. Eosinophils: friends or foes? J Allergy Clin Immunol Pract 2018;6:1439-44.
6. Lee JJ, Jacobsen EA, Ochkur SI, McGarry MP, Condjella RM, Doyle AD, et al. Human versus mouse eosinophils: "that which we call an eosinophil, by any other name would stain as red". J Allergy Clin Immunol 2012;130:572-84.
7. Lee JJ, Dimina D, Macias MP, Ochkur SI, McGarry MP, O'Neill KR, et al. Defining a link with asthma in mice congenitally deficient in eosinophils. Science 2004;305:1773-6.
8. Tanaka H, Komai M, Nagao K, Ishizaki M, Kajiwara D, Takatsu K, et al. Role of interleukin-5 and eosinophils in allergen-induced airway remodeling in mice. Am J Respir Cell Mol Biol 2004;31:62-8.
9. Abdala-Valencia H, Coden ME, Chiarella SE, Jacobsen EA, Bochner BS, Lee JJ, et al. Shaping eosinophil identity in the tissue contexts of development, homeostasis, and disease. J Leukoc Biol 2018;104:95-108.
10. Khan A, Huynh TMT, Vandeplas G, Joish VN, Mannent LP, Tomassen P, et al. The GALEN rhinosinusitis cohort: chronic rhinosinusitis with nasal polyps affects health-related quality of life. Rhinology 2019;57:343-51.
11. Busse WW, Kraft M. Current unmet needs and potential solutions to uncontrolled asthma. Eur Respir Rev 2022;31:210176.
12. Fehrenbach H, Wagner C, Wegmann M. Airway remodeling in asthma: what really matters. Cell Tissue Res 2017;367:551-69.
13. Reeves SR, Kolstad T, Lien TY, Elliott M, Ziegler SF, Wight TN, et al. Asthmatic airway epithelial cells differentially regulate fibroblast expression of extracellular matrix components. J Allergy Clin Immunol 2014;134:663-70.e1.
14. Fang CL, Yin LJ, Sharma S, Kierstein S, Wu HF, Eid G, et al. Resistin-like molecule-beta (RELM-beta) targets airways fibroblasts to effect remodelling in asthma: from mouse to man. Clin Exp Allergy 2015;45:940-52.
15. Acharya KR, Ackerman SJ. Eosinophil granule proteins: form and function. J Biol Chem 2014;289:17406-15.
16. Barker TH, Engler AJ. The provisional matrix: setting the stage for tissue repair outcomes. Matrix Biol 2017;60-61:1-4.
17. Vatrella A, Maglio A, Pelaia C, Ciampo L, Pelaia G, Vitale C. Eosinophilic inflammation: an appealing target for pharmacologic treatments in severe asthma. Biomedicines 2022;10:2181.
18. Sacco O, Silvestri M, Sabatini F, Sale R, Defilippi AC, Rossi GA. Epithelial cells and fibroblasts: structural repair and remodelling in the airways. Paediatr Respir Rev 2004;5(Suppl A):S35-40.
19. Legrand C, Gilles C, Zahm JM, Polette M, Buisson AC, Kaplan H, et al. Airway epithelial cell migration dynamics. MMP-9 role in cell-extracellular matrix remodeling. J Cell Biol 1999;146:517-29.
20. Crosby LM, Waters CM. Epithelial repair mechanisms in the lung. Am J Physiol Lung Cell Mol Physiol 2010;298:L715-31.
21. Neurohr C, Nishimura SL, Sheppard D. Activation of transforming growth factor-beta by the integrin alphavbeta8 delays epithelial wound closure. Am J Respir Cell Mol Biol 2006;35:252-9.
22. Hachim MY, Elemam NM, Ramakrishnan RK, Bajbouj K, Olivenstein R, Hachim IY, et al. Wnt signaling is deranged in asthmatic bronchial epithelium and fibroblasts. Front Cell Dev Biol 2021;9:641404.
23. Kim HT, Yin W, Nakamichi Y, Panza P, Grohmann B, Buettner C, et al. WNT/RYK signaling restricts goblet cell differentiation during lung development and repair. Proc Natl Acad Sci U S A 2019;116:25697-706.
24. Song J, Zhu XM, Wei QY. MSCs reduce airway remodeling in the lungs of asthmatic rats through the Wnt/beta-catenin signaling pathway. Eur Rev Med Pharmacol Sci 2020;24:11199-211.

25. Sugimoto MA, Sousa LP, Pinho V, Perretti M, Teixeira MM. Resolution of inflammation: what controls its onset? Front Immunol 2016;7:160.
26. Grainge CL, Lau LC, Ward JA, Dulay V, Lahiff G, Wilson S, et al. Effect of bronchoconstriction on airway remodeling in asthma. N Engl J Med 2011;364:2006-15.
27. Hough KP, Curtiss ML, Blain TJ, Liu RM, Trevor J, Deshane JS, et al. Airway remodeling in asthma. Front Med (Lausanne) 2020;7:191.
28. Roche WR, Beasley R, Williams JH, Holgate ST. Subepithelial fibrosis in the bronchi of asthmatics. Lancet 1989;1:520-4.
29. Royce SG, Cheng V, Samuel CS, Tang ML. The regulation of fibrosis in airway remodeling in asthma. Mol Cell Endocrinol 2012;351:167-75.
30. Ito JT, Lourenco JD, Righetti RF, Tiberio I, Prado CM, Lopes F. Extracellular matrix component remodeling in respiratory diseases: what has been found in clinical and experimental studies? Cells 2019;8:342.
31. Pain M, Bermudez O, Lacoste P, Royer PJ, Botturi K, Tissot A, et al. Tissue remodelling in chronic bronchial diseases: from the epithelial to mesenchymal phenotype. Eur Respir Rev 2014;23:118-30.
32. Ozdamar B, Bose R, Barrios-Rodiles M, Wang HR, Zhang Y, Wrana JL. Regulation of the polarity protein Par6 by TGFbeta receptors controls epithelial cell plasticity. Science 2005;307:1603-9.
33. Hackett TL, Warner SM, Stefanowicz D, Shaheen F, Pechkovsky DV, Murray LA, et al. Induction of epithelial-mesenchymal transition in primary airway epithelial cells from patients with asthma by transforming growth factor-beta1. Am J Respir Crit Care Med 2009;180:122-33.
34. Sun Z, Ji N, Ma Q, Zhu R, Chen Z, Wang Z, et al. Epithelial-mesenchymal transition in asthma airway remodeling is regulated by the IL-33/CD146 axis. Front Immunol 2020;11:1598.
35. Chiarella E, Lombardo N, Lobello N, Aloisio A, Aragona T, Pelaia C, et al. Nasal polyposis: insights in epithelial-mesenchymal transition and differentiation of polyp mesenchymal stem cells. Int J Mol Sci 2020;21:6878.
36. Larsen K, Tufvesson E, Malmstrom J, Morgelin M, Wildt M, Andersson A, et al. Presence of activated mobile fibroblasts in bronchoalveolar lavage from patients with mild asthma. Am J Respir Crit Care Med 2004;170:1049-56.
37. Michalik M, Wojcik-Pszczola K, Paw M, Wnuk D, Koczurkiewicz P, Sanak M, et al. Fibroblast-to-myofibroblast transition in bronchial asthma. Cell Mol Life Sci 2018;75:3943-61.
38. Burgess JK, Mauad T, Tjin G, Karlsson JC, Westergren-Thorsson G. The extracellular matrix—the under-recognized element in lung disease? J Pathol 2016;240:397-409.
39. Ojiaku CA, Yoo EJ, Panettieri RA Jr. Transforming growth factor beta1 function in airway remodeling and hyperresponsiveness. The missing link? Am J Respir Cell Mol Biol 2017;56:432-42.
40. Arjomandi M, Frelinger J, Donde A, Wong H, Yellamilli A, Raymond W. Secreted osteopontin is highly polymerized in human airways and fragmented in asthmatic airway secretions. PLoS One 2011;6:e25678.
41. Delimpoura V, Bakakos P, Tseliou E, Bessa V, Hillas G, Simoes DC, et al. Increased levels of osteopontin in sputum supernatant in severe refractory asthma. Thorax 2010;65:782-6.
42. Kaartinen MT, Pirhonen A, Linnala-Kankkunen A, Maenpaa PH. Cross-linking of osteopontin by tissue transglutaminase increases its collagen binding properties. J Biol Chem 1999;274:1729-35.
43. Kohan M, Bader R, Puxeddu I, Levi-Schaffer F, Breuer R, Berkman N. Enhanced osteopontin expression in a murine model of allergen-induced airway remodelling. Clin Exp Allergy 2007;37:1444-54.
44. Kohan M, Breuer R, Berkman N. Osteopontin induces airway remodeling and lung fibroblast activation in a murine model of asthma. Am J Respir Cell Mol Biol 2009;41:290-6.
45. Trinh HKT, Nguyen TVT, Kim SH, Cao TBT, Luu QQ, Kim SH, et al. Osteopontin contributes to late-onset asthma phenotypes in adult asthma patients. Exp Mol Med 2020;52:253-65.
46. Legrand F, Cao Y, Wechsler JB, Zhu X, Zimmermann N, Rampertaap S, et al. Sialic acid-binding immunoglobulin-like lectin (Siglec) 8 in patients with eosinophilic disorders: receptor expression and targeting using chimeric antibodies. J Allergy Clin Immunol 2019;143:2227-37.e10.
47. Rosenberg HF, Dyer KD, Foster PS. Eosinophils: changing perspectives in health and disease. Nat Rev Immunol 2013;13:9-22.
48. Barthel SR, Johansson MW, McNamee DM, Mosher DF. Roles of integrin activation in eosinophil function and the eosinophilic inflammation of asthma. J Leukoc Biol 2008;83:1-12.
49. Weller PF, Spencer LA. Functions of tissue-resident eosinophils. Nat Rev Immunol 2017;17:746-60.
50. Spencer LA, Bonjour K, Melo RC, Weller PF. Eosinophil secretion of granule-derived cytokines. Front Immunol 2014;5:496.
51. Melo RC, Weller PF. Piecemeal degranulation in human eosinophils: a distinct secretion mechanism underlying inflammatory responses. Histol Histopathol 2010;25:1341-54.
52. McBrien CN, Menzies-Gow A. The biology of eosinophils and their role in asthma. Front Med (Lausanne) 2017;4:93.
53. Al-Alwan LA, Chang Y, Baglole CJ, Risse PA, Halayko AJ, Martin JG, et al. Autocrine-regulated airway smooth muscle cell migration is dependent on IL-17-induced growth-related oncogenes. J Allergy Clin Immunol 2012;130:977-85.e6.
54. Atherton HC, Jones G, Danahay H. IL-13-induced changes in the goblet cell density of human bronchial epithelial cell cultures: MAP kinase and phosphatidylinositol 3-kinase regulation. Am J Physiol Lung Cell Mol Physiol 2003;285:L730-9.
55. Chu HW, Balzar S, Seedorf GJ, Westcott JY, Trudeau JB, Silkoff P, et al. Transforming growth factor-beta2 induces bronchial epithelial mucin expression in asthma. Am J Pathol 2004;165:1097-106.
56. Frossard N, Freund V, Advenier C. Nerve growth factor and its receptors in asthma and inflammation. Eur J Pharmacol 2004;500:453-65.
57. Goldsmith AM, Bentley JK, Zhou L, Jia Y, Bitar KN, Fingar DC, et al. Transforming growth factor-beta induces airway smooth muscle hypertrophy. Am J Respir Cell Mol Biol 2006;34:247-54.
58. Hayashi H, Kawakita A, Okazaki S, Yasutomi M, Murai H, Ohshima Y. IL-17A/F modulates fibrocyte functions in cooperation with CD40-mediated signaling. Inflammation 2013;36:830-8.
59. Hernnas J, Sarnstrand B, Lindroth P, Peterson CG, Venge P, Malmstrom A. Eosinophil cationic protein alters proteoglycan metabolism in human lung fibroblast cultures. Eur J Cell Biol 1992;59:352-63.
60. Hoshino M, Takahashi M, Aoike N. Expression of vascular endothelial growth factor, basic fibroblast growth factor, and angiogenin immunoreactivity in asthmatic airways and its relationship to angiogenesis. J Allergy Clin Immunol 2001;107:295-301.
61. Ito I, Fixman ED, Asai K, Yoshida M, Gounni AS, Martin JG, et al. Platelet-derived growth factor and transforming growth factor-beta modulate the expression of matrix metalloproteinases and migratory function of human airway smooth muscle cells. Clin Exp Allergy 2009;39:1370-80.
62. Malavia NK, Mih JD, Raub CB, Dinh BT, George SC. IL-13 induces a bronchial epithelial phenotype that is profibrotic. Respir Res 2008;9:27.
63. Michalik M, Pierzchalska M, Legutko A, Ura M, Ostaszewska A, Soja J, et al. Asthmatic bronchial fibroblasts demonstrate enhanced potential to differentiate into myofibroblasts in culture. Med Sci Monit 2009;15:BR194-201.
64. Molet S, Hamid Q, Davoine F, Nutku E, Taha R, Page N, et al. IL-17 is increased in asthmatic airways and induces human bronchial fibroblasts to produce cytokines. J Allergy Clin Immunol 2001;108:430-8.
65. Nakao A, Sagara H, Setoguchi Y, Okada T, Okumura K, Ogawa H, et al. Expression of Smad7 in bronchial epithelial cells is inversely correlated to basement membrane thickness and airway hyperresponsiveness in patients with asthma. J Allergy Clin Immunol 2002;110:873-8.
66. Shimizu S, Gabazza EC, Hayashi T, Ido M, Adachi Y, Suzuki K. Thrombin stimulates the expression of PDGF in lung epithelial cells. Am J Physiol Lung Cell Mol Physiol 2000;279:L503-10.
67. Shimizu S, Gabazza EC, Ogawa T, Tojima I, Hoshi E, Kouzaki H, et al. Role of thrombin in chronic rhinosinusitis-associated tissue remodeling. Am J Rhinol Allergy 2011;25:7-11.
68. Thompson HG, Mih JD, Krasieva TB, Tromberg BJ, George SC. Epithelial-derived TGF-beta2 modulates basal and wound-healing subepithelial matrix homeostasis. Am J Physiol Lung Cell Mol Physiol 2006;291:L1277-85.
69. Tsuda T, Maeda Y, Nishide M, Koyama S, Hayama Y, Nojima S, et al. Eosinophil-derived neurotoxin enhances airway remodeling in eosinophilic chronic rhinosinusitis and correlates with disease severity. Int Immunol 2019;31:33-40.
70. Vignola AM, Chanez P, Chiappara G, Merendino A, Pace E, Rizzo A, et al. Transforming growth factor-beta expression in mucosal biopsies in asthma and chronic bronchitis. Am J Respir Crit Care Med 1997;156:591-9.
71. Vignola AM, Riccobono L, Mirabella A, Profita M, Chanez P, Bellia V, et al. Sputum metalloproteinase-9/tissue inhibitor of metalloproteinase-1 ratio correlates with airflow obstruction in asthma and chronic bronchitis. Am J Respir Crit Care Med 1998;158:1945-50.
72. Vittal R, Fan L, Greenspan DS, Mickler EA, Gopalakrishnan B, Gu H, et al. IL-17 induces type V collagen overexpression and EMT via TGF-beta-dependent pathways in obliterative bronchiolitis. Am J Physiol Lung Cell Mol Physiol 2013;304:L401-14.
73. Wang Q, Li H, Yao Y, Lu G, Wang Y, Xia D, et al. HB-EGF-promoted airway smooth muscle cells and their progenitor migration contribute to airway smooth muscle remodeling in asthmatic mouse. J Immunol 2016;196:2361-7.
74. Zagai U, Lundahl J, Klominek J, Venge P, Skold CM. Eosinophil cationic protein stimulates migration of human lung fibroblasts in vitro. Scand J Immunol 2009;69:381-6.
75. Zhao J, Jiang T, Li P, Dai L, Shi G, Jing X, et al. Tissue factor promotes airway pathological features through epithelial-mesenchymal transition of bronchial

epithelial cells in mice with house dust mite-induced asthma. Int Immunopharmacol 2021;97:107690.
76. Kobayashi K, Nagase H, Sugimoto N, Yamamoto S, Tanaka A, Fukunaga K, et al. Mepolizumab decreased the levels of serum galectin-10 and eosinophil cationic protein in asthma. Asia Pacific Allergy 2021;11:e31.
77. Chua JC, Douglass JA, Gillman A, O'Hehir RE, Meeusen EN. Galectin-10, a potential biomarker of eosinophilic airway inflammation. PLoS One 2012;7:e42549.
78. Ge XN, Bahaie NS, Kang BN, Hosseinkhani MR, Ha SG, Frenzel EM, et al. Allergen-induced airway remodeling is impaired in galectin-3-deficient mice. J Immunol 2010;185:1205-14.
79. López E, del Pozo V, Miguel T, Sastre B, Seoane C, Civantos E, et al. Inhibition of chronic airway inflammation and remodeling by galectin-3 gene therapy in a murine model. J Immunol 2006;176:1943-50.
80. Mauri P, Riccio AM, Rossi R, Di Silvestre D, Benazzi L, De Ferrari L, et al. Proteomics of bronchial biopsies: galectin-3 as a predictive biomarker of airway remodelling modulation in omalizumab-treated severe asthma patients. Immunol Lett 2014;162:2-10.
81. Pang X, Qiao J. Galectin-1 inhibits PDGF-BB-induced proliferation and migration of airway smooth muscle cells through the inactivation of PI3K/Akt signaling pathway. Biosci Rep 2020;40:BSR20193899.
82. Riccio AM, Mauri P, De Ferrari L, Rossi R, Di Silvestre D, Benazzi L, et al. Galectin-3: an early predictive biomarker of modulation of airway remodeling in patients with severe asthma treated with omalizumab for 36 months. Clin Transl Allergy 2017;7:6.
83. Ventura I, Vega A, Chacón P, Chamorro C, Aroca R, Gómez E, et al. Neutrophils from allergic asthmatic patients produce and release metalloproteinase-9 upon direct exposure to allergens. Allergy 2014;69:898-905.
84. Draijer C, Robbe P, Boorsma CE, Hylkema MN, Melgert BN. Dual role of YM1+ M2 macrophages in allergic lung inflammation. Sci Rep 2018;8:5105.
85. Persson EK, Verstraete K, Heyndrickx I, Gevaert E, Aegerter H, Percier J-M, et al. Protein crystallization promotes type 2 immunity and is reversible by antibody treatment. Science 2019;364:738.
86. Gevaert E, Zhang N, Krysko O, Lan F, Holtappels G, De Ruyck N, et al. Extracellular eosinophilic traps in association with *Staphylococcus aureus* at the site of epithelial barrier defects in patients with severe airway inflammation. J Allergy Clin Immunol 2017;139:1849-60.e6.
87. Gevaert E, Delemarre T, De Volder J, Zhang N, Holtappels G, De Ruyck N, et al. Charcot-Leyden crystals promote neutrophilic inflammation in patients with nasal polyposis. J Allergy Clin Immunol 2020;145:427-30.e4.
88. Abdo M, Uddin M, Goldmann T, Marwitz S, Bahmer T, Holz O, et al. Raised sputum extracellular DNA confers lung function impairment and poor symptom control in an exacerbation-susceptible phenotype of neutrophilic asthma. Respir Res 2021;22:167.
89. Simon D, Simon HU, Yousefi S. Extracellular DNA traps in allergic, infectious, and autoimmune diseases. Allergy 2013;68:409-16.
90. Gevaert P, Han JK, Smith SG, Sousa AR, Howarth PH, Yancey SW, et al. The roles of eosinophils and interleukin-5 in the pathophysiology of chronic rhinosinusitis with nasal polyps. Int Forum Allergy Rhinol 2022;12:1413-23.
91. Marichal T, Mesnil C, Bureau F. Homeostatic eosinophils: characteristics and functions. Front Med (Lausanne) 2017;4:101; https://doi.org/10.3389/fmed.2017.00101.
92. Mochizuki M, Bartels J, Mallet AI, Christophers E, Schroder JM. IL-4 induces eotaxin: a possible mechanism of selective eosinophil recruitment in helminth infection and atopy. J Immunol 1998;160:60-8.
93. Pease JE, Williams TJ. Eotaxin and asthma. Curr Opin Pharmacol 2001;1:248-53.
94. Rothenberg ME. Eotaxin. An essential mediator of eosinophil trafficking into mucosal tissues. Am J Respir Cell Mol Biol 1999;21:291-5.
95. Dougan M, Dranoff G, Dougan SK. GM-CSF, IL-3, and IL-5 family of cytokines: regulators of inflammation. Immunity 2019;50:796-811.
96. Travers J, Rothenberg ME. Eosinophils in mucosal immune responses. Mucosal Immunol 2015;8:464-75.
97. Yamaguchi Y, Hayashi Y, Sugama Y, Miura Y, Kasahara T, Kitamura S, et al. Highly purified murine interleukin 5 (IL-5) stimulates eosinophil function and prolongs in vitro survival. IL-5 as an eosinophil chemotactic factor. J Exp Med 1988;167:1737-42.
98. Clutterbuck EJ, Hirst EM, Sanderson CJ. Human interleukin-5 (IL-5) regulates the production of eosinophils in human bone marrow cultures: comparison and interaction with IL-1, IL-3, IL-6, and GMCSF. Blood 1989;73:1504-12.
99. Mould AW, Matthaei KI, Young IG, Foster PS. Relationship between interleukin-5 and eotaxin in regulating blood and tissue eosinophilia in mice. J Clin Invest 1997;99:1064-71.
100. Shalit M, Sekhsaria S, Malech HL. Modulation of growth and differentiation of eosinophils from human peripheral blood CD34+ cells by IL5 and other growth factors. Cell Immunol 1995;160:50-7.
101. Mindt BC, Fritz JH, Duerr CU. Group 2 innate lymphoid cells in pulmonary immunity and tissue homeostasis. Front Immunol 2018;9:840.
102. Molofsky AB, Nussbaum JC, Liang HE, Van Dyken SJ, Cheng LE, Mohapatra A, et al. Innate lymphoid type 2 cells sustain visceral adipose tissue eosinophils and alternatively activated macrophages. J Exp Med 2013;210:535-49.
103. Nussbaum JC, Van Dyken SJ, von Moltke J, Cheng LE, Mohapatra A, Molofsky AB, et al. Type 2 innate lymphoid cells control eosinophil homeostasis. Nature 2013;502:245-8.
104. Maggi E, Veneziani I, Moretta L, Cosmi L, Annunziato F. Group 2 innate lymphoid cells: a double-edged sword in cancer? Cancers (Basel) 2020;12:3452.
105. Hara K, Hasegawa T, Ooi H, Koya T, Tanabe Y, Tsukada H, et al. Inhibitory role of eosinophils on cell surface plasmin generation by bronchial epithelial cells: inhibitory effects of transforming growth factor beta. Lung 2001;179:9-20.
106. Coden ME, Berdnikovs S. Eosinophils in wound healing and epithelial remodeling: is coagulation a missing link? J Leukoc Biol 2020;108:93-103.
107. Riddle JM, Barnhart MI. The eosinophil as a source for profibrinolysin in acute inflammation. Blood 1965;25:776-94.
108. Coden ME, Loffredo LF, Walker MT, Jeong BM, Nam K, Bochner BS, et al. Fibrinogen is a specific trigger for cytolytic eosinophil degranulation. J Immunol 2020;204:438-48.
109. Ramirez GA, Yacoub MR, Ripa M, Mannina D, Cariddi A, Saporiti N, et al. Eosinophils from physiology to disease: a comprehensive review. Biomed Res Int 2018;2018:9095275.
110. Matucci A, Nencini F, Maggiore G, Chiccoli F, Accinno M, Vivarelli E, et al. High proportion of inflammatory CD62L(low) eosinophils in blood and nasal polyps of severe asthma patients. Clin Exp Allergy 2022;53:78-87.
111. Stewart E, Wang X, Chupp GL, Montgomery RR. Profiling cellular heterogeneity in asthma with single cell multiparameter CyTOF. J Leukoc Biol 2020;108:1555-64.
112. Broekema M, Volbeda F, Timens W, Dijkstra A, Lee NA, Lee JJ, et al. Airway eosinophilia in remission and progression of asthma: accumulation with a fast decline of FEV(1). Respir Med 2010;104:1254-62.
113. Siddiqui S, Mistry V, Doe C, Roach K, Morgan A, Wardlaw A, et al. Airway hyperresponsiveness is dissociated from airway wall structural remodeling. J Allergy Clin Immunol 2008;122:335-41.e3.
114. Barthel SR, Jarjour NN, Mosher DF, Johansson MW. Dissection of the hyperadhesive phenotype of airway eosinophils in asthma. Am J Respir Cell Mol Biol 2006;35:378-86.
115. Giblin SP, Midwood KS. Tenascin-C: Form versus function. Cell Adh Migr 2015;9:48-82.
116. Wong CK, Cheung PF, Ip WK, Lam CW. Intracellular signaling mechanisms regulating toll-like receptor-mediated activation of eosinophils. Am J Respir Cell Mol Biol 2007;37:85-96.
117. Minshall EM, Leung DY, Martin RJ, Song YL, Cameron L, Ernst P, et al. Eosinophil-associated TGF-beta1 mRNA expression and airways fibrosis in bronchial asthma. Am J Respir Cell Mol Biol 1997;17:326-33.
118. Balzar S, Chu HW, Silkoff P, Cundall M, Trudeau JB, Strand M, et al. Increased TGF-beta2 in severe asthma with eosinophilia. J Allergy Clin Immunol 2005;115:110-7.
119. Halwani R, Al-Muhsen S, Al-Jahdali H, Hamid Q. Role of transforming growth factor–β in airway remodeling in asthma. Am J Respir Cell Mol Biol 2011;44:127-33.
120. Boxall C, Holgate ST, Davies DE. The contribution of transforming growth factor-beta and epidermal growth factor signalling to airway remodelling in chronic asthma. Eur Respir J 2006;27:208-29.
121. Hullinger TG, Pan Q, Viswanathan HL, Somerman MJ. TGFbeta and BMP-2 activation of the OPN promoter: roles of smad- and hox-binding elements. Exp Cell Res 2001;262:69-74.
122. Gibb AA, Lazaropoulos MP, Elrod JW. Myofibroblasts and fibrosis: mitochondrial and metabolic control of cellular differentiation. Circ Res 2020;127:427-47.
123. Torr EE, Ngam CR, Bernau K, Tomasini-Johansson B, Acton B, Sandbo N. Myofibroblasts exhibit enhanced fibronectin assembly that is intrinsic to their contractile phenotype. J Biol Chem 2015;290:6951-61.
124. Takahashi F, Takahashi K, Okazaki T, Maeda K, Ienaga H, Maeda M, et al. Role of osteopontin in the pathogenesis of bleomycin-induced pulmonary fibrosis. Am J Respir Cell Mol Biol 2001;24:264-71.
125. Janulaityte I, Januskevicius A, Rimkunas A, Palacionyte J, Vitkauskiene A, Malakauskas K. Asthmatic eosinophils alter the gene expression of extracellular matrix proteins in airway smooth muscle cells and pulmonary fibroblasts. Int J Mol Sci 2022;23:4086.
126. Amin K, Ludviksdottir D, Janson C, Nettelbladt O, Bjornsson E, Roomans GM, et al. Inflammation and structural changes in the airways of patients with atopic and nonatopic asthma. BHR Group. Am J Respir Crit Care Med 2000;162:2295-301.

127. Wilson SJ, Rigden HM, Ward JA, Laviolette M, Jarjour NN, Djukanovic R. The relationship between eosinophilia and airway remodelling in mild asthma. Clin Exp Allergy 2013;43:1342-50.
128. Wenzel SE, Schwartz LB, Langmack EL, Halliday JL, Trudeau JB, Gibbs RL, et al. Evidence that severe asthma can be divided pathologically into two inflammatory subtypes with distinct physiologic and clinical characteristics. Am J Respir Crit Care Med 1999;160:1001-8.
129. Phillips-Houlbracq M, Debray MP, Guyard A, Khoury R, Dombret MC, Le Brun M, et al. Multifocal bronchial stenosis and extensive lobar atelectasis as a rare radiologic feature of severe eosinophilic asthma. J Allergy Clin Immunol Pract 2023;11:341-3.e1.
130. Al-Shaikhly T, Murphy RC, Parker A, Lai Y, Altman MC, Larmore M, et al. Location of eosinophils in the airway wall is critical for specific features of airway hyperresponsiveness and T2 inflammation in asthma. Eur Respir J 2022;60:2101865.
131. Drake MG, Scott GD, Blum ED, Lebold KM, Nie Z, Lee JJ, et al. Eosinophils increase airway sensory nerve density in mice and in human asthma. Sci Transl Med 2018;10:eaar8477.
132. Liu T, Liu Y, Miller M, Cao L, Zhao J, Wu J, et al. Autophagy plays a role in FSTL1-induced epithelial mesenchymal transition and airway remodeling in asthma. Am J Physiol Lung Cell Mol Physiol 2017;313:L27-40.
133. Yang ZC, Qu ZH, Yi MJ, Shan YC, Ran N, Xu L, et al. MiR-448-5p inhibits TGF-beta1-induced epithelial-mesenchymal transition and pulmonary fibrosis by targeting Six1 in asthma. J Cell Physiol 2019;234:8804-14.
134. Ressler B, Lee RT, Randell SH, Drazen JM, Kamm RD. Molecular responses of rat tracheal epithelial cells to transmembrane pressure. Am J Physiol Lung Cell Mol Physiol 2000;278:L1264-72.
135. Calhoun WJ, Haselkorn T, Miller DP, Omachi TA. Asthma exacerbations and lung function in patients with severe or difficult-to-treat asthma. J Allergy Clin Immunol 2015;136:1125-7.e4.
136. Denlinger LC, Phillips BR, Ramratnam S, Ross K, Bhakta NR, Cardet JC, et al. Inflammatory and comorbid features of patients with severe asthma and frequent exacerbations. Am J Respir Crit Care Med 2017;195:302-13.
137. Denlinger LC, Phillips BR, Sorkness RL, Bleecker ER, Castro M, DeBoer MD, et al. Responsiveness to parenteral corticosteroids and lung function trajectory in adults with moderate-to-severe asthma. Am J Respir Crit Care Med 2021;203:841-52.
138. Levy BD, Noel PJ, Freemer MM, Cloutier MM, Georas SN, Jarjour NN, et al. Future research directions in asthma: an NHLBI Working Group Report. Am J Respir Crit Care Med 2015;192:1366-72.
139. Fokkens WJ, Lund VJ, Hopkins C, Hellings PW, Kern R, Reitsma S, et al. European position paper on rhinosinusitis and nasal polyps 2020. Rhinology 2020;58:1-464.
140. Meng J, Zhou P, Liu Y, Liu F, Yi X, Liu S, et al. The development of nasal polyp disease involves early nasal mucosal inflammation and remodelling. PLoS One 2013;8:e82373.
141. Ordovas-Montanes J, Dwyer DF, Nyquist SK, Buchheit KM, Vukovic M, Deb C, et al. Allergic inflammatory memory in human respiratory epithelial progenitor cells. Nature 2018;560:649-54.
142. Martinez-Anton A, Debolos C, Garrido M, Roca-Ferrer J, Barranco C, Alobid I, et al. Mucin genes have different expression patterns in healthy and diseased upper airway mucosa. Clin Exp Allergy 2006;36:448-57.
143. de Borja Callejas F, Picado C, Martinez-Anton A, Alobid I, Pujols L, Valero A, et al. Differential expression of remodeling markers by tissue structure in nasal polyposis. Am J Rhinol Allergy 2013;27:e69-74.
144. Erbek SS, Erinanc H, Erbek S, Topal O, Kiyici H. Expression of a disintegrin and metalloproteinase 33 protein in nasal polyposis: an immunohistochemical study. Am J Rhinol Allergy 2010;24:79-82.
145. Wang LF, Chien CY, Chiang FY, Chai CY, Tai CF. Corelationship between matrix metalloproteinase 2 and 9 expression and severity of chronic rhinosinusitis with nasal polyposis. Am J Rhinol Allergy 2012;26:e1-4.
146. Hupin C, Gohy S, Bouzin C, Lecocq M, Polette M, Pilette C. Features of mesenchymal transition in the airway epithelium from chronic rhinosinusitis. Allergy 2014;69:1540-9.
147. Simon HU, Yousefi S, Schranz C, Schapowal A, Bachert C, Blaser K. Direct demonstration of delayed eosinophil apoptosis as a mechanism causing tissue eosinophilia. J Immunol 1997;158:3902-8.
148. Jiang W, Zhou C, Ma C, Cao Y, Hu G, Li H. TGF-beta1 induces epithelial-to-mesenchymal transition in chronic rhinosinusitis with nasal polyps through microRNA-182. Asian Pac J Allergy Immunol Epub 2021 Dec 26.
149. Saitoh T, Kusunoli T, Yao T, Kawano K, Kojima Y, Miyahara K, et al. Relationship between epithelial damage or basement membrane thickness and eosinophilic infiltration in nasal polyps with chronic rhinosinusitis. Rhinology 2009;47:275-9.
150. Wang M, Sun Y, Li C, Qu J, Zhou B. Eosinophils correlate with epithelial-mesenchymal transition in chronic rhinosinusitis with nasal polyps. ORL J Otorhinolaryngol Relat Spec 2022;84:70-80.
151. Gelardi M, Netti GS, Giancaspro R, Spadaccino F, Pennella A, Fiore V, et al. Chronic rhinosinusitis with nasal polyposis (CRSwNP): the correlation between expression of galectin-10 and clinical-cytological grading (CCG). Am J Rhinol Allergy 2022;36:229-37.
152. Barham HP, Osborn JL, Snidvongs K, Mrad N, Sacks R, Harvey RJ. Remodeling changes of the upper airway with chronic rhinosinusitis. Int Forum Allergy Rhinol 2015;5:565-72.
153. Kim DY, Cho SH, Takabayashi T, Schleimer RP. Chronic rhinosinusitis and the coagulation system. Allergy Asthma Immunol Res 2015;7:421-30.
154. Moosbauer C, Morgenstern E, Cuvelier SL, Manukyan D, Bidzhekov K, Albrecht S, et al. Eosinophils are a major intravascular location for tissue factor storage and exposure. Blood 2007;109:995-1002.
155. Slungaard A, Vercellotti GM, Tran T, Gleich GJ, Key NS. Eosinophil cationic granule proteins impair thrombomodulin function: a potential mechanism for thromboembolism in hypereosinophilic heart disease. J Clin Invest 1993;91:1721-30.
156. Takabayashi T, Kato A, Peters AT, Hulse KE, Suh LA, Carter R, et al. Increased expression of factor XIII-A in patients with chronic rhinosinusitis with nasal polyps. J Allergy Clin Immunol 2013;132:584-92.e4.
157. Sejima T, Holtappels G, Bachert C. The expression of fibrinolytic components in chronic paranasal sinus disease. Am J Rhinol Allergy 2011;25:1-6.
158. Pelaia C, Paoletti G, Puggioni F, Racca F, Pelaia G, Canonica GW, et al. Interleukin-5 in the pathophysiology of severe asthma. Front Physiol 2019;10:1514.
159. Barretto KT, Brockman-Schneider RA, Kuipers I, Basnet S, Bochkov YA, Altman MC, et al. Human airway epithelial cells express a functional IL-5 receptor. Allergy 2020;75:2127-30.
160. Buchheit KM, Lewis E, Gakpo D, Hacker J, Sohail A, Taliaferro F, et al. Mepolizumab targets multiple immune cells in aspirin-exacerbated respiratory disease. J Allergy Clin Immunol 2021;148:574-84.
161. Ochi H, De Jesus NH, Hsieh FH, Austen KF, Boyce JA. IL-4 and -5 prime human mast cells for different profiles of IgE-dependent cytokine production. Proc Natl Acad Sci U S A 2000;97:10509-13.
162. Bajbouj K, AbuJabal R, Sahnoon L, Olivenstein R, Mahboub B, Hamid Q. IL-5 receptor expression in lung fibroblasts: potential role in airway remodeling in asthma. Allergy 2023;78:882-5.
163. Cho JY, Miller M, Baek KJ, Han JW, Nayar J, Lee SY, et al. Inhibition of airway remodeling in IL-5–deficient mice. J Clin Invest 2004;113:551-60.
164. Haldar P, Brightling CE, Hargadon B, Gupta S, Monteiro W, Sousa A, et al. Mepolizumab and exacerbations of refractory eosinophilic asthma. N Engl J Med 2009;360:973-84.
165. Bai J, Huang JH, Price CP, Schauer JM, Suh LA, Harmon R, et al. Prognostic factors for polyp recurrence in chronic rhinosinusitis with nasal polyps. J Allergy Clin Immunol 2022;150:352-61.e7.
166. Delgado-Dolset MI, Obeso D, Sánchez-Solares J, Mera-Berriatua L, Fernández P, Barbas C, et al. Understanding systemic and local inflammation induced by nasal polyposis: role of the allergic phenotype. Front Mol Biosci 2021;8:662792.
167. Laulajainen-Hongisto A, Toppila-Salmi SK, Luukkainen A, Kern R. Airway epithelial dynamics in allergy and related chronic inflammatory airway diseases. Front Cell Dev Biol 2020;8:204.
168. McIntosh MJ, Kooner HK, Eddy RL, Jeimy S, Licskai C, Mackenzie CA, et al. Asthma control, airway mucus, and (129)Xe MRI ventilation after a single benralizumab dose. Chest 2022;162:520-33.
169. Stevens WW, Schleimer RP, Kern RC. Chronic rhinosinusitis with nasal polyps. J Allergy Clin Immunol Pract 2016;4:565-72.
170. Heijink IH, Kuchibhotla VN, Roffel MP, Maes T, Knight DA, Sayers I, et al. Epithelial cell dysfunction, a major driver of asthma development. Allergy 2020;75:1902-17.
171. Berair R, Saunders R, Brightling CE. Origins of increased airway smooth muscle mass in asthma. BMC Med 2013;11:145.
172. Tai A, Tran H, Roberts M, Clarke N, Wilson J, Robertson CF. The association between childhood asthma and adult chronic obstructive pulmonary disease. Thorax 2014;69:805-10.
173. Liesker JJ, Ten Hacken NH, Zeinstra-Smith M, Rutgers SR, Postma DS, Timens W. Reticular basement membrane in asthma and COPD: similar thickness, yet different composition. Int J Chron Obstruct Pulmon Dis 2009;4:127-35.
174. Bourdin A, Neveu D, Vachier I, Paganin F, Godard P, Chanez P. Specificity of basement membrane thickening in severe asthma. J Allergy Clin Immunol 2007;119:1367-74.
175. Joubert P, Hamid Q. Role of airway smooth muscle in airway remodeling. J Allergy Clin Immunol 2005;116:713-6.

176. McDonald DM. Angiogenesis and remodeling of airway vasculature in chronic inflammation. Am J Respir Crit Care Med 2001;164:S39-45.
177. Benayoun L, Druilhe A, Dombret MC, Aubier M, Pretolani M. Airway structural alterations selectively associated with severe asthma. Am J Respir Crit Care Med 2003;167:1360-8.
178. Chakir J, Shannon J, Molet S, Fukakusa M, Elias J, Laviolette M, et al. Airway remodeling-associated mediators in moderate to severe asthma: effect of steroids on TGF-beta, IL-11, IL-17, and type I and type III collagen expression. J Allergy Clin Immunol 2003;111:1293-8.
179. Tang M, Elicker BM, Henry T, Gierada DS, Schiebler ML, Huang BK, et al. Mucus plugs persist in asthma and changes in mucus plugs associate with changes in airflow over time. Am J Respir Crit Care Med 2022;205:1036-45.
180. Little S, Sproule M, Cowan M, Macleod K, Robertson M, Love J, et al. High resolution computed tomographic assessment of airway wall thickness in chronic asthma: reproducibility and relationship with lung function and severity. Thorax 2002;57:247-53.
181. Hartley RA, Barker BL, Newby C, Pakkal M, Baldi S, Kajekar R, et al. Relationship between lung function and quantitative computed tomographic parameters of airway remodeling, air trapping, and emphysema in patients with asthma and chronic obstructive pulmonary disease: a single-center study. J Allergy Clin Immunol 2016;137:1413-22.e12.
182. Niimi A, Matsumoto H, Amitani R, Nakano Y, Mishima M, Minakuchi M, et al. Airway wall thickness in asthma assessed by computed tomography: relation to clinical indices. Am J Respir Crit Care Med 2000;162:1518-23.
183. Montaudon M, Lederlin M, Reich S, Begueret H, Tunon-de-Lara JM, Marthan R, et al. Bronchial measurements in patients with asthma: comparison of quantitative thin-section CT findings with those in healthy subjects and correlation with pathologic findings. Radiology 2009;253:844-53.
184. Bumbacea D, Campbell D, Nguyen L, Carr D, Barnes PJ, Robinson D, et al. Parameters associated with persistent airflow obstruction in chronic severe asthma. Eur Respir J 2004;24:122-8.
185. ten Brinke A, Zwinderman AH, Sterk PJ, Rabe KF, Bel EH. Factors associated with persistent airflow limitation in severe asthma. Am J Respir Crit Care Med 2001;164:744-8.
186. Azim A, Newell C, Barber C, Harvey M, Knight D, Freeman A, et al. Clinical evaluation of type 2 disease status in a real-world population of difficult to manage asthma using historic electronic healthcare records of blood eosinophil counts. Clin Exp Allergy 2021;51:811-20.
187. Hancox RJ, Pavord ID, Sears MR. Associations between blood eosinophils and decline in lung function among adults with and without asthma. Eur Respir J 2018;51:1702536.
188. Park HY, Chang Y, Kang D, Hong YS, Zhao D, Ahn J, et al. Blood eosinophil counts and the development of obstructive lung disease: the Kangbuk Samsung Health Study. Eur Respir J 2021;58:2003823.
189. Koefoed HJL, Gehring U, Vonk JM, Koppelman GH. Blood eosinophils associate with reduced lung function growth in adolescent asthmatics. Clin Exp Allergy 2021;51:556-63.
190. Foy BH, Soares M, Bordas R, Richardson M, Bell A, Singapuri A, et al. Lung computational models and the role of the small airways in asthma. Am J Respir Crit Care Med 2019;200:982-91.
191. Castro M, Rubin A, Laviolette M, Hanania NA, Armstrong B, Cox G, et al. Persistence of effectiveness of bronchial thermoplasty in patients with severe asthma. Ann Allergy Asthma Immunol 2011;107:65-70.
192. Castro M, Rubin AS, Laviolette M, Fiterman J, De Andrade Lima M, Shah PL, et al. Effectiveness and safety of bronchial thermoplasty in the treatment of severe asthma: a multicenter, randomized, double-blind, sham-controlled clinical trial. Am J Respir Crit Care Med 2010;181:116-24.
193. Thomson NC, Rubin AS, Niven RM, Corris PA, Siersted HC, Olivenstein R, et al. Long-term (5 year) safety of bronchial thermoplasty: Asthma Intervention Research (AIR) trial. BMC Pulm Med 2011;11:8.
194. Papakonstantinou E, Koletsa T, Zhou L, Fang L, Roth M, Karakioulaki M, et al. Bronchial thermoplasty in asthma: an exploratory histopathological evaluation in distinct asthma endotypes/phenotypes. Respir Res 2021;22:186.
195. Pretolani M, Bergqvist A, Thabut G, Dombret MC, Knapp D, Hamidi F, et al. Effectiveness of bronchial thermoplasty in patients with severe refractory asthma: clinical and histopathologic correlations. J Allergy Clin Immunol 2017;139:1176-85.
196. Januskevicius A, Gosens R, Sakalauskas R, Vaitkiene S, Janulaityte I, Halayko AJ, et al. Suppression of eosinophil integrins prevents remodeling of airway smooth muscle in asthma. Front Physiol 2016;7:680.
197. Humbles AA, Lloyd CM, McMillan SJ, Friend DS, Xanthou G, McKenna EE, et al. A critical role for eosinophils in allergic airways remodeling. Science 2004;305:1776-9.
198. Sont JK, Willems LN, Bel EH, van Krieken JH, Vandenbroucke JP, Sterk PJ. Clinical control and histopathologic outcome of asthma when using airway hyperresponsiveness as an additional guide to long-term treatment. The AMPUL Study Group. Am J Respir Crit Care Med 1999;159:1043-51.
199. Hoshino M, Akitsu K, Kubota K. Effect of sublingual immunotherapy on airway inflammation and airway wall thickness in allergic asthma. J Allergy Clin Immunol Pract 2019;7:2804-11.
200. Siddiqui S, Bozik ME, Archibald D, Dworetzky SI, Mather J, Killingsworth R, et al. Phase 2 trial evaluating the effects of dexpramipexole on blood eosinophils, lung function, and airway biomarkers in eosinophilic asthma [abstract]. Eur Respir J 2021;58:RCT2900.
201. Bachert C, Han JK, Desrosiers M, Hellings PW, Amin N, Lee SE, et al. Efficacy and safety of dupilumab in patients with severe chronic rhinosinusitis with nasal polyps (LIBERTY NP SINUS-24 and LIBERTY NP SINUS-52): results from two multicentre, randomised, double-blind, placebo-controlled, parallel-group phase 3 trials. Lancet 2019;394:1638-50.
202. Bachert C, Han JK, Desrosiers MY, Gevaert P, Heffler E, Hopkins C, et al. Efficacy and safety of benralizumab in chronic rhinosinusitis with nasal polyps: a randomized, placebo-controlled trial. J Allergy Clin Immunol 2022;149:1309-17.e12.
203. Bachert C, Sousa AR, Han JK, Schlosser RJ, Sowerby LJ, Hopkins C, et al. Mepolizumab for chronic rhinosinusitis with nasal polyps: treatment efficacy by comorbidity and blood eosinophil count. J Allergy Clin Immunol 2022;149:1711-21.e6.
204. Chachi L, Diver S, Kaul H, Rebelatto MC, Boutrin A, Nisa P, et al. Computational modelling prediction and clinical validation of impact of benralizumab on airway smooth muscle mass in asthma. Eur Respir J 2019;54:1900930.
205. Evaluation of dupilumab's effects on airway inflammation in patients with asthma (EXPEDITION). Available at: https://clinicaltrials.gov/ct2/show/NCT02573233. Accessed April 2022.
206. Diver S, Khalfaoui L, Emson C, Wenzel SE, Menzies-Gow A, Wechsler ME, et al. Effect of tezepelumab on airway inflammatory cells, remodelling, and hyperresponsiveness in patients with moderate-to-severe uncontrolled asthma (CASCADE): a double-blind, randomised, placebo-controlled, phase 2 trial. Lancet Respir Med 2021;9:1299-312.
207. Flood-Page P, Menzies-Gow A, Phipps S, Ying S, Wangoo A, Ludwig MS, et al. Anti-IL-5 treatment reduces deposition of ECM proteins in the bronchial subepithelial basement membrane of mild atopic asthmatics. J Clin Invest 2003;112:1029-36.
208. Gevaert P, Van Bruaene N, Cattaert T, Van Steen K, Van Zele T, Acke F, et al. Mepolizumab, a humanized anti-IL-5 mAb, as a treatment option for severe nasal polyposis. J Allergy Clin Immunol 2011;128:989-95.e1-8.
209. Graff S, Brusselle G, Hanon S, Sohy C, Dupont L, Peche R, et al. Anti-interleukin-5 therapy is associated with attenuated lung function decline in severe eosinophilic asthma patients from the Belgian Severe Asthma Registry. J Allergy Clin Immunol Pract 2022;10:467-77.
210. Han JK, Bachert C, Fokkens W, Desrosiers M, Wagenmann M, Lee SE, et al. Mepolizumab for chronic rhinosinusitis with nasal polyps (SYNAPSE): a randomised, double-blind, placebo-controlled, phase 3 trial. Lancet Respir Med 2021;9:1141-53.
211. Laidlaw TM, Prussin C, Panettieri RA, Lee S, Ferguson BJ, Adappa ND, et al. Dexpramipexole depletes blood and tissue eosinophils in nasal polyps with no change in polyp size. Laryngoscope 2019;129:E61-6.
212. Manfredini M, Liberati S, Ciardo S, Bonzano L, Guanti M, Chester J, et al. Microscopic and functional changes observed with dynamic optical coherence tomography for severe refractory atopic dermatitis treated with dupilumab. Skin Res Technol 2020;26:779-87.
213. Panettieri RA Jr, Welte T, Shenoy KV, Korn S, Jandl M, Kerwin EM, et al. Onset of effect, changes in airflow obstruction and lung volume, and health-related quality of life improvements with benralizumab for patients with severe eosinophilic asthma: phase IIIb randomized, controlled trial (SOLANA). J Asthma Allergy 2020;13:115-26.
214. Przybyszowski M, Gross-Sondej I, Zarychta J, Bazan-Socha S, Bochenek G, Soja J, et al. The impact of treatment with mepolizumab on airway remodeling in patients with severe eosinophilic asthma. Eur Respir J 2021;58:PA894.
215. Sverrild A, Hansen S, Hvidtfeldt M, Clausson C, Cozzolino O, Cerps S, et al. The effect of tezepelumab on airway hyperresponsiveness to mannitol in asthma (UPSTREAM). Eur Respir J 2021;59:2101296.
216. Tversky J, Lane AP, Azar A. Benralizumab effect on severe chronic rhinosinusitis with nasal polyps (CRSwNP): a randomized double-blind placebo-controlled trial. Clin Exp Allergy 2021;51:836-44.
217. Zheng M, Sima Y, Liu C, Zhao J, Shao S, Wang X, et al. Clinical effectiveness and potential predictability of omalizumab in patients with difficult-to-treat chronic rhinosinusitis with nasal polyps and asthma based on the noninvasive markers—a real-life prospective study. World Allergy Organ J 2022;15:100702.
218. Laviolette M, Gossage DL, Gauvreau G, Leigh R, Olivenstein R, Katial R, et al. Effects of benralizumab on airway eosinophils in asthmatic patients with sputum eosinophilia. J Allergy Clin Immunol 2013;132:1086-96.e5.

219. Menzella F, Lusuardi M, Galeone C, Taddei S, Zucchi L. Profile of anti-IL-5 mAb mepolizumab in the treatment of severe refractory asthma and hypereosinophilic diseases. J Asthma Allergy 2015;8:105-14.
220. Nordenmark L, Emson C, Hellqvist Å, Johnston J, Greberg H, Griffiths J, et al. S46 Tezepelumab reduces mucus plugging in patients with uncontrolled, moderate-to-severe asthma: the phase 2 CASCADE study [abstract]. Thorax 2022;77(suppl 1):A32.
221. Gevaert P, Omachi TA, Corren J, Mullol J, Han J, Lee SE, et al. Efficacy and safety of omalizumab in nasal polyposis: 2 randomized phase 3 trials. J Allergy Clin Immunol 2020;146:595-605.
222. Siddiqui S, Wenzel SE, Bozik ME, Archibald DG, Dworetzky SI, Mather JL, et al. Safety and efficacy of dexpramipexole in eosinophilic asthma (EXHALE): a randomized controlled trial. J Allergy Clin Immunol Epub 2023 Jun 3.
223. Hopkins C, Han JK, Lund VJ, Bachert C, Fokkens WJ, Diamant Z, et al. Evaluating treatment response to mepolizumab in patients with severe CRSwNP. Rhinology 2023;61:108-17.
224. Januskevicius A, Jurkeviciute E, Janulaityte I, Kalinauskaite-Zukauske V, Miliauskas S, Malakauskas K. Blood eosinophils subtypes and their survivability in asthma patients. Cells 2020;9:1248.
225. Mesnil C, Raulier S, Paulissen G, Xiao X, Birrell MA, Pirottin D, et al. Lung-resident eosinophils represent a distinct regulatory eosinophil subset. J Clin Invest 2016;126:3279-95.
226. van Maldegem F, Valand K, Cole M, Patel H, Angelova M, Rana S, et al. Characterisation of tumour microenvironment remodelling following oncogene inhibition in preclinical studies with imaging mass cytometry. Nat Commun 2021;12:5906.
227. Wilson G, Liu Q, Knight J, Visness C, Villarreal M, Gill M, et al. Exploring the effect of anti-IL-5 therapy on sputum eosinophils in children with asthma. Am J Respir Crit Care Med 2022;205:A4833.
228. Dilasser F, Rose L, Hassoun D, Klein M, Rousselle M, Brosseau C, et al. Essential role of smooth muscle Rac1 in severe asthma-associated airway remodelling. Thorax 2021;76:326-34.