Case Report
Allergy Asthma Immunol Res. 2012 Forthcoming.
Posted online 2012 October 16
pISSN 2092-7355 • eISSN 2092-7363

AAIR
Allergy, Asthma & Immunology Research

Successful Treatment of Steroid-Dependent Eosinophilic Cellulitis With Cyclosporine

Su Hee Kim,[1] Ji Eun Kwon,[2] Hyo-Bin Kim[1]*

[1]Department of Pediatrics, Inje University Sanggye Paik Hospital, Seoul, Korea
[2]Department of Pathology, Ajou University College of Medicine, Suwon, Korea

This is an Open Access article distributed under the terms of the Creative Commons Attribution Non-Commercial License (http://creativecommons.org/licenses/by-nc/3.0/) which permits unrestricted non-commercial use, distribution, and reproduction in any medium, provided the original work is properly cited.

Eosinophilic cellulitis (EC) is a rare idiopathic disorder, first described as a "recurrent granulomatous dermatitis with eosinophilia", that mimics cellulitis of infectious origin. We describe here a previously healthy 11-year-old girl who experienced fever and tender erythematous patch lesions after trauma to her knees. Because of the relapsing cellulitis-like skin lesions, skin biopsies were taken, resulting in a diagnosis of EC. The patient responded well to oral prednisolone but experienced side effects and relapse during dose tapering. She was switched from prednisolone to cyclosporine. Her EC remained under control, and she showed no evidence of relapse after discontinuation of cyclosporine.

Key Words: Eosinophilic cellulitis; cyclosporine; prednisolone

INTRODUCTION

Eosinophilic cellulitis (EC) is a rare idiopathic disorder, first described by Wells in 1971 as a "recurrent granulomatous dermatitis with eosinophilia" and it is also reported as Wells syndrome. EC is more frequently observed in adults than in children without racial or gender predilection.[1,2] Although its etiology and pathogenesis are currently unknown, EC is characterized by hypersensitivity responses to different endogenous and exogenous stimuli such as arthropod bites, cutaneous viral, fungal and parasitic infections, medications, vaccinations, eczema, autoimmune disease, carcinoma, leukemia, and myeloproliferative disorders.[1-4] EC is diagnosed by its clinical appearance and course, and by characteristic histopathological findings. The site and appearance of cutaneous lesions vary, but they usually affect the extremities.[2] Treatment consists of systemic or topical corticosteroid or cyclosporine, but patients with EC show variable responses.[2,3,5] We describe here an 11-year-old girl with EC who showed a good response to steroid treatment but developed side effects and relapsed as steroids were tapered, but was then successfully treated with cyclosporine.

CASE REPORT

A healthy 11-year-old girl fell on her knees 9 days before admission. Bruises developed on both tibial tuberosity areas, but soon subsided. One day before admission, she developed erythematous painful swelling lesions on both tibial tuberosity areas accompanied by fever (38°C). She was initially admitted to the orthopedic department with a diagnosis of bacterial cellulitis. There was no history of recent travel or insect bite. Physical examination revealed tender, erythematous plaques on both knees (Fig. 1A), her left arm and her right ankle area. There were no signs of ulceration, bullae, skin breakdown, streaking, or lymphadenitis.

Initial laboratory studies revealed a mildly elevated white blood cell count of 10,760/mm^3 (78.8% neutrophils, 4.2% eosinophils), an erythrocyte sedimentation rate (ESR) of 8 mm/hr and a C-reactive protein (CRP) of less than 0.3 mg/dL. Her creatine kinase and myoglobin concentrations were 76 U/L and 25 ng/mL, respectively, both within normal limits. Despite treatment with intravenous cefazolin, her fever and painful erythematous rash continued and her peripheral blood eosinophils increased from 9.1% to 35.5%. She was transferred to the pediatric department on the 5th day after admission. Her total IgE concentration was 1418.5 IU/mL (normal value: 0-170 IU/mL) and she was positive for specific IgE to house dust mites. Her stool was

Correspondence to: Hyo-Bin Kim, MD, Department of Pediatrics, Inje University Sanggye Paik Hospital, 1342 Dongil-ro, Nowon-gu, Seoul 139-707, Korea.
Tel: +82-2-950-8852; Fax: +82-2-950-8883; E-mail: hbkim@paik.ac.kr
Received: July 3, 2012; Accepted: August 16, 2012
• There are no financial or other issues that might lead to conflict of interest.

© Copyright The Korean Academy of Asthma, Allergy and Clinical Immunology • The Korean Academy of Pediatric Allergy and Respiratory Disease

Fig. 1. Skin lesions of our patient with eosinophilic cellulitis. (A) Development of tender edematous erythematous skin lesions on tuberosity areas of both knees and improvements in these lesions after treatment with oral prednisolone. (B) Development of newly swollen erythematous skin lesions on the left foot after tapering of prednisolone.

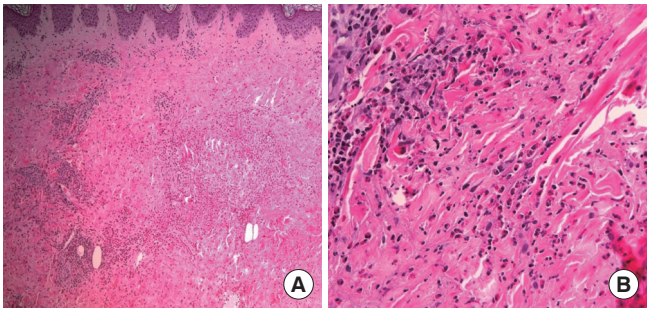

Fig. 2. Histologic examination of a skin biopsy of an erythematous lesion on the left leg of the patient, showing diffuse heavy infiltration of eosinophils in the entire dermis (hematoxylin and eosin; (A) original magnification ×100, (B) ×400.

negative for parasites, and her antinuclear antibody, ANCA (anti-neutrophil cytoplasmic antibody) and anti-double-stranded DNA antibody were all within normal limits. A skin biopsy was taken from an erythematous skin lesion of her left leg, with histologic examination revealing diffuse heavy infiltration of eosinophils in the entire dermis, a finding consistent with EC (Fig. 2). She responded well to oral prednisolone for 3 days and was discharged without medication. Four days later, however, a new erythematous painful plaque appeared on her left foot (Fig. 1B) and blood hypereosinophilia (28.4%) recurred. Due to the relapse after tapering prednisolone several times, she was continued on oral prednisolone for 11 weeks. Because of her steroid dependency and increased intraocular pressure, she was switched from prednisolone to cyclosporine (5 mg/kg/day) for 2 months. Her skin lesions improved and there was no evidence of relapse after cessation of treatment for 6 months.

DISCUSSION

The manifestations of EC are difficult to differentiate from those of bacterial cellulitis, making EC easy to misdiagnose.[1,6] Differential diagnoses also include contact dermatitis, envenomations, and drug reactions, as well as less common entities such as erysipelas, eosinophilic fasciitis, hypereosinophilic syndrome, chronic urticaria, granuloma annulare, and Churg-Strauss syndrome.[7] Bacterial and fungal cellulitis rapidly expanded within the first 24 hours and a break in the skin barrier can be detected.[8] In contrast, EC lesions begin as itching or a tender burning sensation, followed by cellulitis-like eruptions, well demarcated nodules or plaques, and the development of vesicles or bullae.[1,2] Our patient was initially suspected of having bacterial cellulitis because her symptoms developed after trauma and erythematous tendered swollen skin lesions were accompanied by fever. However, her symptom developed 8 days after trauma, there was no break in the skin and she was unresponsive to antimicrobial therapy.

Clinical evolution in EC is paralleled by histological changes and correlated with the immunobiology of eosinophils, not only in blood but in bone marrow and tissues.[2,3,5,9] During the acute stage, there is marked dermal edema and a predominantly eosinophilic infiltrate in the upper and mid epidermis without signs of vasculitis.[3] If edema is pronounced, the epidermis may be spongiotic, and subepidermal bullae may develop. In the subacute granulomatous phase, the eosinophils degenerate and deposit eosinophil major cationic protein and nuclear debris onto collagen fibers, producing flame figures within 1-3 weeks. These 'flame' figures consist of collagen coated with eosinophilic material and surrounded by histiocytes and multinucleated giant cells. During the regressive phase, eosinophils gradually disappear, although histiocytes persist and giant cells are present around the collagen deposits, forming microgranulomas. In addition, hypereosinophilia of the peripheral blood may occur during the active phase of the disease. Eosinophil levels have been found to fluctuate during the course of the disease, returning to the reference range on clinical remission.[9] The eosinophil count in the peripheral blood of our patient was as high as 35.5%, decreasing during therapy. The hypereosinophilia of her peripheral blood and the presence of infiltrating eosinophils in subcutaneous fat without epidermal involvement suggest that our patient was in the acute stage of EC at initial presentation.

Although EC lesions can heal without medication, treatment with systemic corticosteroids has been shown to decrease symptom duration.[2] The standard treatment for patients with Wells' syndrome is oral steroids, although topical steroids, antihistamines, dapsone, cyclosporine, azathioprine, griseofulvin, doxycycline, minocycline and interferon-α2 have been reported effective, either alone or in combination.[2,5] We initially treated our patient with oral prednisolone because she could not walk due to pain in the lesion, which was effective. However, the development of side effects led to a switch to cyclosporine. Similarly, two patients refractory to corticosteroids were treated successfully with cyclosporine.[10] Cyclosporine acts primarily on helper T cells, decreasing their activation, proliferation, and cy-

tokine production.[11] In addition, cyclosporine has effects on eosinophils and basophils in cutaneous inflammation and suppresses blood eosinophil counts and the production of IL-5.[12] Cyclosporine treatment of our patient led to complete remission. She did not experience any adverse effects of cyclosporine, such as hypertension or nephrotoxicity.

In summary, we have described a patient initially diagnosed with bacterial cellulitis but confirmed to have EC by skin biopsy. Cyclosporine can be effective in patients who are dependent on or experience side effects with corticosteroids.

REFERENCES

1. Wells GC, Smith NP. Eosinophilic cellulitis. Br J Dermatol 1979;100:101-9.
2. Moossavi M, Mehregan DR. Wells' syndrome: a clinical and histopathologic review of seven cases. Int J Dermatol 2003;42:62-7.
3. Ladoyanni E, Vlachou C, Thushara R, Snead D. A patient with Wells' syndrome. Clin Exp Dermatol 2010;35:e3-4.
4. Kim HS, Kang MJ, Kim HO, Park YM. Eosinophilic cellulitis in a patient with gastric cancer. Acta Derm Venereol 2009;89:644-5.
5. Moon HS, Park K, Lee JH, Son SJ. Eosinophilic cellulitis in an infant. Int J Dermatol 2010;49:592-3.
6. Gandhi RK, Coloe J, Peters S, Zirwas M, Darabi K. Wells syndrome (eosinophilic cellulitis): a clinical imitator of bacterial cellulitis. J Clin Aesthet Dermatol 2011;4:55-7.
7. Weiss G, Shemer A, Confino Y, Kaplan B, Trau H. Wells' syndrome: report of a case and review of the literature. Int J Dermatol 2001;40:148-52.
8. Swartz MN. Clinical practice. Cellulitis. N Engl J Med 2004;350:904-12.
9. España A, Sanz ML, Sola J, Gil P. Wells' syndrome (eosinophilic cellulitis): correlation between clinical activity, eosinophil levels, eosinophil cation protein and interleukin-5. Br J Dermatol 1999;140:127-30.
10. Herr H, Koh JK. Eosinophilic cellulitis (Wells' syndrome) successfully treated with low-dose cyclosporine. J Korean Med Sci 2001;16:664-8.
11. Hess AD, Esa AH, Colombani PM. Mechanisms of action of cyclosporine: effect on cells of the immune system and on subcellular events in T cell activation. Transplant Proc 1988;20:29-40.
12. Teixeira MM, Williams TJ, Hellewell PG. Effects of dexamethasone and cyclosporin A on the accumulation of eosinophils in acute cutaneous inflammation in the guinea-pig. Br J Pharmacol 1996;118:317-24.