Respiratory Medicine Case Reports 21 (2017) 124–128

Contents lists available at ScienceDirect

Respiratory Medicine Case Reports

journal homepage: www.elsevier.com/locate/rmcr

Multiple cavities with halo sign in a case of invasive pulmonary aspergillosis during therapy for drug-induced hypersensitivity syndrome

Tomoo Ikari [a], Katsura Nagai [a, *], Masashi Ohe [b], Toshiyuki Harada [a], Yasushi Akiyama [a]

[a] Department of Respiratory Medicine, Center for Respiratory Diseases, JCHO Hokkaido Hospital, Japan
[b] Department of Connective Tissue Disease, JCHO Hokkaido Hospital, Japan

ARTICLE INFO

Article history:
Received 13 February 2017
Received in revised form
10 April 2017
Accepted 18 April 2017

Keywords:
Invasive pulmonary aspergillosis
Drug-induced hypersensitivity syndrome
Human herpes virus 6 (HHV-6)
Chronic obstructive pulmonary disease (COPD)
Halo sign

ABSTRACT

A 67-year-old female with rheumatoid arthritis and asthma-chronic obstructive pulmonary disease overlap syndrome was admitted for drug-induced hypersensitivity syndrome (DIHS) caused by salazosulfapyridine. Human herpes virus 6 (HHV-6) variant B was strongly positive on peripheral blood. Multiple cavities with ground grass opacities rapidly emerged predominantly in the upper and middle lobes. She was diagnosed with invasive pulmonary aspergillosis (IPA), and was treated successfully with antifungal agents. Therapeutic systemic corticosteroids, emphysematous change in the lungs, and the worsening of the patient's general condition due to DIHS were considered major contributing factor leading to IPA. HHV-6 reactivation could have an effect on clinical course of IPA. Cavities with halo sign would provide an early clue to IPA in non-neutropenic and immunosuppressive patients.

© 2017 The Authors. Published by Elsevier Ltd. This is an open access article under the CC BY-NC-ND license (http://creativecommons.org/licenses/by-nc-nd/4.0/).

1. Introduction

Invasive pulmonary aspergillosis (IPA) predominantly affects severely immunocompromised patients, particularly those with prolonged neutropenia or organ transplantation [1]. IPA is increasingly being recognized as an emerging disease in non-neutropenic patients such as COPD, connective tissue diseases requiring corticosteroid therapy [2].

Drug-induced hypersensitivity syndrome (DIHS) or drug reaction with eosinophilia and systemic syndrome (DRESS) presents clinically as an extensive mucocutaneous rash, accompanied by fever, lymphadenopathy, hepatitis, hematologic abnormalities with eosinophilia and atypical lymphocytes, and may involve other organs with resultant damage in several systems [3]. An immune response against the drug with secondary viral reactivation related to a cytokine storm, and early viral reactivation responsible for most of the manifestations of DIHS [4]. It has a relapsing-remitting course despite withdrawal of causative drugs. Herpes viruses such as HHV-6/HHV-7, Epstein-Barr virus and cytomegalovirus can be reactivated during the course of DRESS/DIHS [3]. The treatment of DIHS was based on systemic glucocorticoids.

This patient has a lot of risk factors in non-neutropenic IPA including asthma-chronic obstructive pulmonary disease overlap syndrome, systemic corticosteroids use, and duration of antibiotic treatment longer than 10 days. In addition to these factors, HHV-6 reactivation may have some effect on the clinical course of IPA. This case showed unique imaging findings on computed tomography (CT) scan at the early phase of IPA.

2. Case report

A 67-year-old woman admitted for a febrile skin rash that progressed erythroderma for a week. One month earlier, she had diagnosed with rheumatoid arthritis and received anti-rheumatic drugs for predonisolone:PSL 5 mg/day, salazosulfapyridine:SASP 0.5 g/day. She is well controlled asthmatic patient with inhaled

Abbreviation: BAL, bronchoalveolar lavage; BG, 1,3-β-glucan; CMV, cytomegalovirus; COPD, chronic obstructive pulmonary disease; CT, computed tomography; DIHS, drug-induced hypersensitivity syndrome; DRESS, drug reaction with eosinophilia and systemic syndrome; GGO, ground grass opacity; GM, galactomannan antigenemia; HHV-6, Human herpes virus 6; IPA, invasive pulmonary aspergillosis; LAA, low attenuation area; MCFG, micafungin; VRCZ, voriconazole.

* Corresponding author. Japan Community Health Care Organization (JCHO), Hokkaido Hospital, 1-8, Nakanoshima, Toyohira-ku, Sapporo, 062-8618 Hokkaido, Japan.
E-mail address: katnagai@kme.biglobe.ne.jp (K. Nagai).

http://dx.doi.org/10.1016/j.rmcr.2017.04.017
2213-0071/© 2017 The Authors. Published by Elsevier Ltd. This is an open access article under the CC BY-NC-ND license (http://creativecommons.org/licenses/by-nc-nd/4.0/).

fluticasone furoate 200 μg/vilanterol 25 μg. Her past medical history included chronic obstructive pulmonary disease (COPD). She was an ex-smoker (40 pack years of smoking).

The physical findings on admission consisted of erythroderma, erosion of the lips, persistent high fever, superficial lymphadenopathy at neck, purpura over the extremities, and hypovolemic shock. Laboratory tests showed neutrophilic leukocytosis with mild eosinophilia (WBC: 13130/μl, neu: 75%, and eos: 13%), (AST: 16 IU/L, ALT: 20 IU/L, LDH 359 IU/L, total bilirubin:0.4 mg/dL, C-reactive protein 10.7 mg/dL, BUN 41.6 mg/dl and serum creatinine 1.29 mg/dl, RA 17 U/ml, anti-SS-A/Ro Ab 46.2 U/ml). Blood cultures resulted normal. The *aspergillus* galactomannan antigenemia (GM) and anti-Aspergillus IgG antibodies were negative, but Aspergillus precipitationg antibody was positive on admission. The level of 1,3-β-glucan (BG) was within normal limits as 5.0 pg/ml. A chest X-ray showed infiltration in middle lesions of both lungs (Fig. 1a). A chest CT scan showed low attenuation area (LAA) throughout in upper lobe and small thin–walled cavities surrounded by GGO (Fig. 1b). Pulmonary function test performed on day 47 showed an obstructive pattern with no reversibility: FEV_1/FVC 63.8%, pre bronchodilator FEV_1 1.55L (89.1%), post bronchodilator FEV_1 1.58L (+1.9%).

The course of treatment was shown in Fig. 2. SASP was discontinued on admission, an antibiotic treatment and an increase in corticosteroid dose by 5 mg–25 mg/day showed a small effect on erythroderma and erosion of the lips. The temperature has gone down to normal. Skin biopsy revealed that the superficial infiltration of inflammatory cells at junction of the epidermis and dermis, perivascular inflammation. Nine days after admission, her clinical condition (erythroderma, erosion of the lips, and high fever) exacerbated again. The IgG titer against human herpes virus-6 (HHV-6) increased from × 80 to × 160. The PCR test for HHV-6 variant B was strongly positive on peripheral blood (8000 copies/ml). DIHS was diagnosed based on the presence of a skin rash developing more than 3 weeks after SASP initiation, clinical symptoms persisting more than 2 weeks after stopping SASP, fever >38 °C, leukocytosis, kidney dysfunction, lymphadenopathy, HHV-6 reactivation [4]. High dose methylprednisolone (500 mg/day) was administrated on day 11–13. However, multiple cavities rapidly emerged predominantly in the upper and middle lobes on day 12 (Fig. 3a and b), when positive conversion of GM test was identified. Because she refused to undergo bronchoscopic examination at first, micafungin (MCFG) 150 mg/day was administrated for clinically diagnosed invasive pulmonary aspergillosis. PCR tests were positive for cytomegalovirus (CMV) and negative for the Epstein-Barr virus on day 21, however they were both negative on admission. Treatment of Ganciclovir 500 mg/day was started on day 26 for two weeks. Multiple cavities persisted despite antifungal treatment, she decided to have bronchoscopic examination on 26 days after admission. The culture of bronchoalveolar lavage (BAL) fluid performed at left B^3 was positive for *Aspergillus fumigatus*. The total cell count in BAL fluids was significantly increased (78×10^4/ml) and the inflammatory cell profile showed the increased percentage of neutrophils (macrophages 31%, neutrophils 65%, lymphocytes 4%, eosinophils 0%). Transbronchial lung biopsy specimen obtained from left B^3 showed inflammatory cell infiltration, necrotic tissue destruction and bleeding, but acid first bacilli and fungus were undetected. A dose of 200 mg voriconazole (VRCZ) (400 mg for starting dose) was concurrently administrated on day 29. Severe cough disappeared and cavity walls became thinner afterward. She left the hospital on day 52. Multiple cavities disappeared on CT scan one year after discharge from the hospital (Fig. 4).

3. Discussion

It has been reported that IPA may be identified by chest CT at an early stage of disease.

The lesion of CT images as having a 'halo sign' (i.e., GGO surrounding a nodule or mass), 'hypodense sign' (i.e., hypodensity or low attenuation within the mass or nodule), or cavitation were commonly observed in IPA [5]. The halo sign has been pathophysiologically characterized as a discrete nodule of angioinvasive aspergillosis with infarction and coagulative necrosis surrounded by alveolar hemorrhage. This sign is seen only in the first 10 days of angioinvasion [6]. Typical chest CT scan findings include multiple nodules and the halo sign is seen in neutropenic patients with IPA early in the course of infection. Halo sign can be also seen in Bronchiolitis Obliterans with Organizing Pneumonia, granulomatosis with polyangiitis, metastatic angiosarcoma and focal lung injury. In this case, pathological findings consistent with the

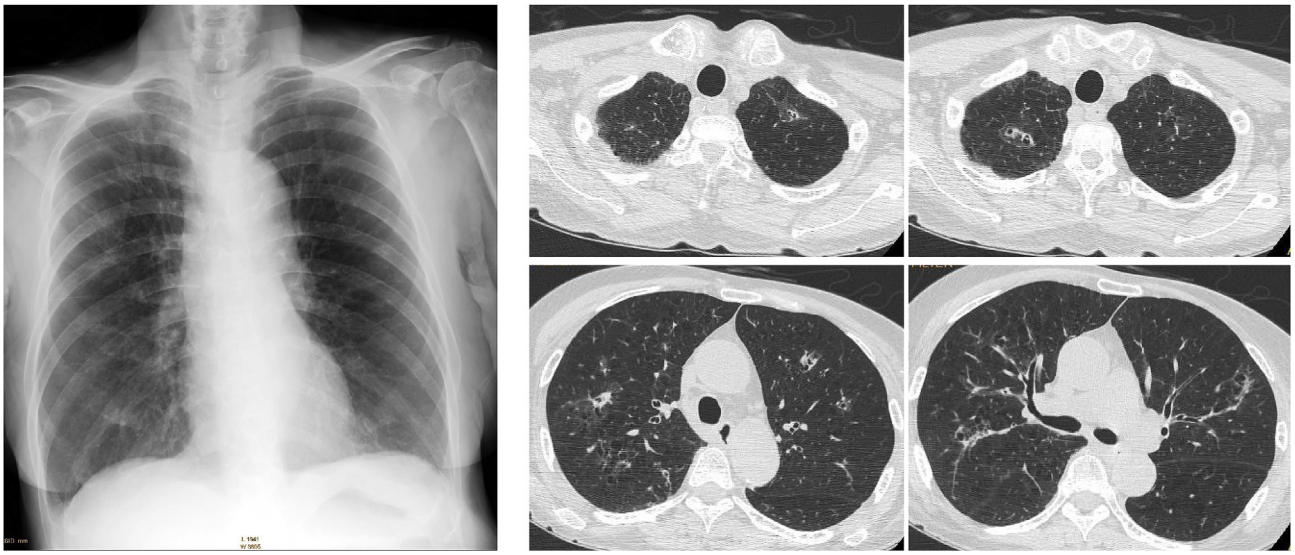

Fig. 1. a: A chest X-ray showed infiltration in middle and lower lesions of both lungs on admission. b: Chest CT images showed low attenuation area (LAA) throughout in upper lobe and small thin–walled cavities surrounded by GGO on admission.

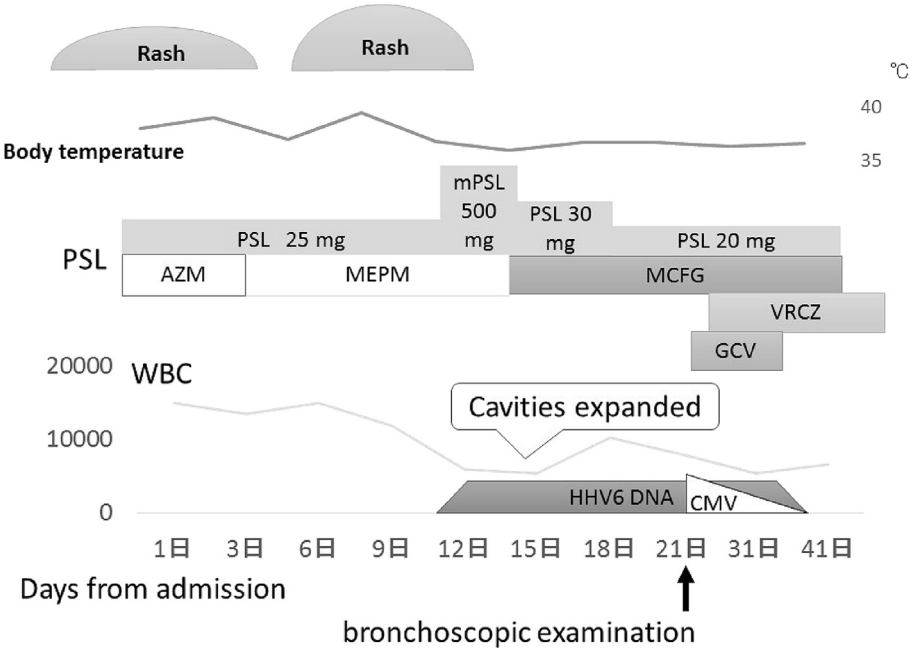

Fig. 2. The course of the hospitalized. High dose methylprednisolone (500 mg/day) was administrated on day 11–13, and gradual decrease after day 14. After treatment, HHV-6 DNA decreased but CMV-antigen increased on day 26. PSL: predonisolone, mPSL: methylprednisolone, AZM:azithromycin, MEPM: meropenem, MCFG: micafungin, VRCZ: voriconazole, GCV: ganciclovir, HHV-6: Human herpes virus 6, CMV: cytomegalovirus.

Fig. 3. a: A chest X-ray showed the cavity in the left lung on day 12. b: Chest CT images showed multiple cavities rapidly emerged predominantly in the upper and middle lobes on day 12.

halo sign of IPA. However, the diagnosis of IPA in non-neutropenic critically ill patients as well as in the COPD patients is usually difficult because signs and symptoms are non-specific [7]. A halo sign on a CT scan has been reported to be the first reliable sign of infection, with a high specificity but a low sensitivity [8,9]. A lower sensitivity (5–24%) of the halo sign and the air crescent sign in non-neutropenic patients has been reported in the literature [9–11] as well as COPD [2,12,13]. The radiological abnormalities of IPA in COPD patients based on CT scan were cavity lesions in 20% and solitary or multiple nodules in 6% [14]. In non-neutropenic patients, the histologic pattern is characterized by central liquefaction necrosis and prominent neutrophilic infiltration. Both the crescent sign and cavitation are the result of WBC recovery with release of proteases that lead to resorption of necrotic tissue at the periphery of lesions [15]. Therefore, the finding of a halo sign at baseline was strongly associated with improved responses to treatment and better survival [16].

This case was finally diagnosed with “probable invasive aspergillosis” according to the presence of a positive culture for Aspergillus species from lower respiratory tract sample together with one major criterion on CT scan [17,18]. Steroids are believed to play a role in the emergence of IPA in COPD patients. The accumulated doses of corticosteroids (>700 mg) received during the 3 months prior to admission significantly increased the risk of IPA in COPD patients [2]. In a separate report, a total daily dose ≥20 mg prednisone more than 3 weeks or equivalent dose met the criteria for

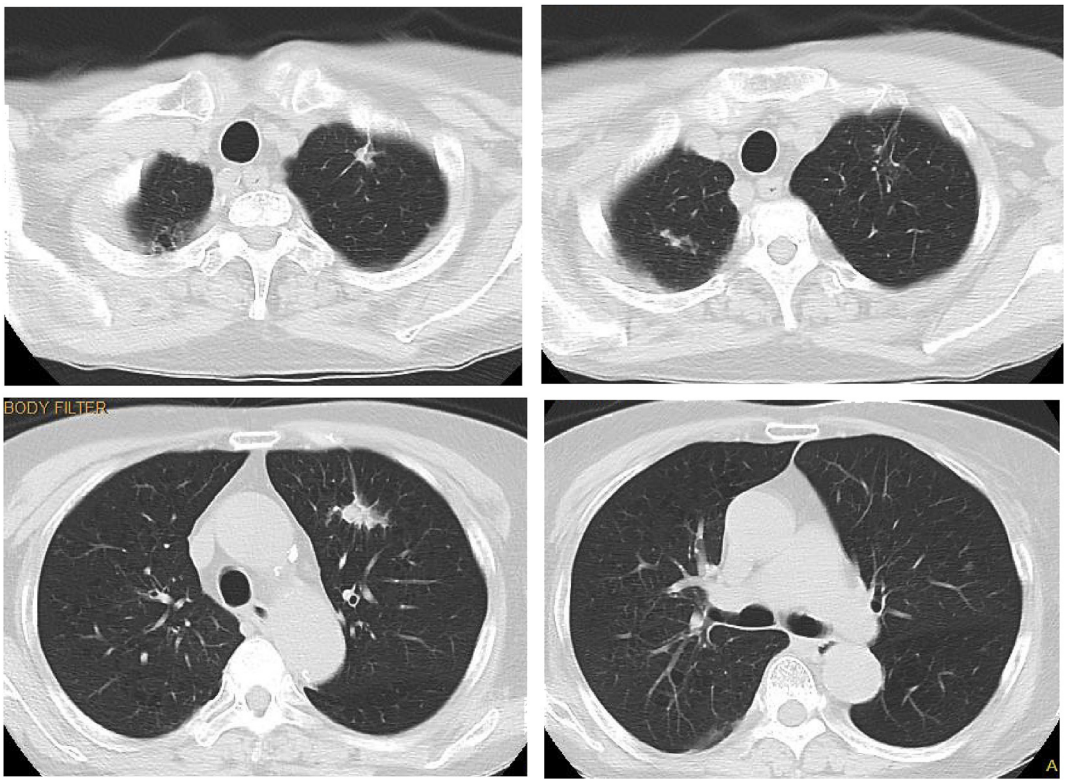

Fig. 4. Chest CT images showed multiple nodules without cavities one year after discharge from the hospital.

defining cases of IPA in COPD patients [19]. This patient received 5mg daily PSL for a month prior to admission. Aspergillus species might be colonized in the lungs.

DIHS is some of the most life-threatening severe cutaneous adverse reactions [4,20]. The demonstration of HHV reactivation may be a useful marker for the diagnosis of DIHS, and has been added to the DIHS-scoring criteria in Japan [21]. The incidence of viral reactivation was significantly higher after treatment with systemic steroids [22]. HHV-6 is considered to be an immunomodulatory virus that may facilitate superinfections with fungal or other opportunistic infections [23]. Flamand reported that Infection of T cells by HHV-6 results in immune suppression characterized by a downregulation of IL-2 mRNA and protein synthesis accompanied by diminished cellular proliferation [24]. HHV-6 has been associated with various indirect effects, including a high rate of cytomegalovirus (CMV) disease, opportunistic infection such as invasive fungal disease [23,25,26]. HHV-6 reactivated during the course of DIHS may promote IPA as well as the use of systemic steroids in this case. IPA manifests within 10–14 days of the trigger of immunosuppression. In addition to these risk factors, there is an evidence that CMV infection in these patients increases the risk of IPA [27]. The hazard ratio for IPA in the setting of CMV disease increases 13.3-fold [28].

Taken together, in this case, GGO surrounding a cavity on a CT scan may be considered as a feature of IPA in patients with immunosuppression caused by systemic steroids and DIHS at early stage.

The sensitivity of GM was 87.5% for cases of proven and probable IPA in intensive care unit [29] or 42.4% for probable IPA in patients with COPD [2]. GM test results were positive at the time that the greatest pathological change was revealed by CT scan [30]. In this case, positive conversion of GM test was on day 12 when the multiple cavities rapidly emerged in the lungs.

Although micafungin showed a trend towards a decreased incidence of *Aspergillus* infection, VRCZ is recommended for the primary treatment of invasive aspergillosis in most patients [31]. After diagnosis with IPA, the patients are successfully treated with VRCZ in this case. Clinicians should consider the possibility of IPA in cases of immunosuppressive clinical condition and find early signs on CT scan with cavities surrounded by GGO in addition to the existing typical signs before getting positive results of GM tests or fungal culture.

The authors state that they have no Conflicts of Interest (COI).

This research did not receive any specific grant from funding agencies in the public, commercial, or not-for-profit sectors.

References

[1] J. Turc, A. Lamblin, T. Vitry, et al., Clinical diagnosis of invasive pulmonary aspergillosis in a non-neutropenic critically ill patient, Respir. Care 59 (9) (2014) e137–e139, http://dx.doi.org/10.4187/respcare.02579.

[2] J. Guinea, M. Torres-Narbona, P. Gijon, et al., Pulmonary aspergillosis in patients with chronic obstructive pulmonary disease: incidence, risk factors, and outcome, Clin. Microbiol. Infect. Off. Publ. Eur. Soc. Clin. Microbiol. Infect. Dis. 16 (7) (2010) 870–877, http://dx.doi.org/10.1111/j.1469-0691.2009.03015.x [published Online First: 2009/11/13].

[3] P.R. Criado, J. Avancini, C.G. Santi, et al., Drug reaction with eosinophilia and systemic symptoms (DRESS): a complex interaction of drugs, viruses and the immune system, Israel Med. Assoc. J. IMAJ 14 (9) (2012) 577–582 [published Online First: 2012/10/30].

[4] V. Descamps, S. Ranger-Rogez, DRESS syndrome, Jt. Bone, Spine Rev. Rhum. 81 (1) (2014) 15–21, http://dx.doi.org/10.1016/j.jbspin.2013.05.002 [published Online First: 2013/07/03].

[5] M.A. Milito, D.P. Kontoyiannis, R.E. Lewis, et al., Influence of host immunosuppression on CT findings in invasive pulmonary aspergillosis, Med. Mycol. 48 (6) (2010) 817–823, http://dx.doi.org/10.3109/13693780903514872 [published Online First: 2010/01/30].

[6] A. Prasad, K. Agarwal, D. Deepak, et al., Pulmonary aspergillosis: what CT can offer before it is too late!, J. Clinical Diagn. Res. JCDR 10 (4) (2016) Te01–Te05, http://dx.doi.org/10.7860/jcdr/2016/17141.7684 [published Online First: 2016/05/18].

[7] M. Bassetti, E. Righi, G. De Pascale, et al., How to manage aspergillosis in non-

neutropenic intensive care unit patients, Crit. Care London, Engl. 18 (4) (2014) 458, http://dx.doi.org/10.1186/s13054-014-0458-4 [published Online First: 2014/08/30].

[8] J. Maertens, J. Van Eldere, J. Verhaegen, et al., Use of circulating galactomannan screening for early diagnosis of invasive aspergillosis in allogeneic stem cell transplant recipients, J. Infect. Dis. 186 (9) (2002) 1297–1306, http://dx.doi.org/10.1086/343804.

[9] W. Meersseman, S.J. Vandecasteele, A. Wilmer, et al., Invasive aspergillosis in critically ill patients without malignancy, Am. J. Respir. Crit. Care Med. 170 (6) (2004) 621–625, http://dx.doi.org/10.1164/rccm.200401-093OC [published Online First: 2004/07/02].

[10] R.J. Trof, A. Beishuizen, Y.J. Debets-Ossenkopp, et al., Management of invasive pulmonary aspergillosis in non-neutropenic critically ill patients, Intensive Care Med. 33 (10) (2007) 1694–1703, http://dx.doi.org/10.1007/s00134-007-0791-z [published Online First: 2007/07/25].

[11] J. Barberan, F. Sanz, J.L. Hernandez, et al., Clinical features of invasive pulmonary aspergillosis vs. colonization in COPD patients distributed by gold stage, J. Infect. 65 (5) (2012) 447–452, http://dx.doi.org/10.1016/j.jinf.2012.07.006 [published Online First: 2012/08/07].

[12] L. Huang, H. He, Y. Ding, et al., Values of radiological examinations for the diagnosis and prognosis of invasive bronchial-pulmonary aspergillosis in critically ill patients with chronic obstructive pulmonary diseases, Clin. Respir. J. (2016), http://dx.doi.org/10.1111/crj.12551 [published Online First: 2016/09/11].

[13] H. He, L. Ding, F. Li, et al., Clinical features of invasive bronchial-pulmonary aspergillosis in critically ill patients with chronic obstructive respiratory diseases: a prospective study, Crit. Care London, Engl. 15 (1) (2011) R5, http://dx.doi.org/10.1186/cc9402 [published Online First: 2011/01/08].

[14] P. Samarakoon, A. Soubani, Invasive pulmonary aspergillosis in patients with COPD: a report of five cases and systematic review of the literature, Chron. Respir. Dis. 5 (1) (2008) 19–27, http://dx.doi.org/10.1177/1479972307085637 [published Online First: 2008/02/28].

[15] H. Brodoefel, M. Vogel, H. Hebart, et al., Long-term CT follow-up in 40 non-HIV immunocompromised patients with invasive pulmonary aspergillosis: kinetics of CT morphology and correlation with clinical findings and outcome, AJR Am. J. Roentgenol. 187 (2) (2006) 404–413, http://dx.doi.org/10.2214/ajr.05.0513 [published Online First: 2006/07/25].

[16] R.E. Greene, H.T. Schlamm, J.W. Oestmann, et al., Imaging findings in acute invasive pulmonary aspergillosis: clinical significance of the halo sign, Clin. Infect. Dis. 44 (3) (2007) 373–379, http://dx.doi.org/10.1086/509917 [published Online First: 2007/01/06].

[17] B. De Pauw, T.J. Walsh, J.P. Donnelly, et al., Revised definitions of invasive fungal disease from the European organization for research and treatment of cancer/invasive fungal infections cooperative group and the national institute of allergy and infectious diseases mycoses study group (EORTC/MSG) consensus group, Clin. Infect. Dis. 46 (12) (2008) 1813–1821, http://dx.doi.org/10.1086/588660.

[18] S. Ascioglu, J.H. Rex, B. de Pauw, et al., Defining opportunistic invasive fungal infections in immunocompromised patients with cancer and hematopoietic stem cell transplants: an international consensus, Clin. Infect. Dis. 34 (1) (2002) 7–14, http://dx.doi.org/10.1086/323335.

[19] J. Garnacho-Montero, R. Amaya-Villar, C. Ortiz-Leyba, et al., Isolation of Aspergillus spp. from the respiratory tract in critically ill patients: risk factors, clinical presentation and outcome, Crit. Care London, Engl. 9 (3) (2005) R191–R199, http://dx.doi.org/10.1186/cc3488 [published Online First: 2005/07/01].

[20] R. Schrijvers, L. Gilissen, A.M. Chiriac, et al., Pathogenesis and diagnosis of delayed-type drug hypersensitivity reactions, from bedside to bench and back, Clin. Transl. Allergy 5 (2015) 31, http://dx.doi.org/10.1186/s13601-015-0073-8 [published Online First: 2015/09/05].

[21] T. Shiohara, M. Inaoka, Y. Kano, Drug-induced hypersensitivity syndrome (DIHS): a reaction induced by a complex interplay among herpesviruses and antiviral and antidrug immune responses, Allergol. Int. 55 (1) (2006) 1–8, http://dx.doi.org/10.2332/allergolint.55.1 [published Online First: 2006/11/01].

[22] E. Funck-Brentano, T.A. Duong, S. Bouvresse, et al., Therapeutic management of DRESS: a retrospective study of 38 cases, J. Am. Acad. Dermatol. 72 (2) (2015) 246–252, http://dx.doi.org/10.1016/j.jaad.2014.10.032 [published Online First: 2015/01/17].

[23] I. Lautenschlager, R.R. Razonable, Human herpesvirus-6 infections in kidney, liver, lung, and heart transplantation: review, Transpl. Int. 25 (5) (2012) 493–502, http://dx.doi.org/10.1111/j.1432-2277.2012.01443.x [published Online First: 2012/02/24].

[24] L. Flamand, J. Gosselin, I. Stefanescu, et al., Immunosuppressive effect of human herpesvirus 6 on T-cell functions: suppression of interleukin-2 synthesis and cell proliferation, Blood 85 (5) (1995) 1263–1271 [published Online First: 1995/03/01].

[25] J. Rogers, S. Rohal, D.R. Carrigan, et al., Human herpesvirus-6 in liver transplant recipients: role in pathogenesis of fungal infections, neurologic complications, and outcome, Transplantation 69 (12) (2000) 2566–2573 [published Online First: 2000/07/26].

[26] N. Singh, D.R. Carrigan, T. Gayowski, et al., Human herpesvirus-6 infection in liver transplant recipients: documentation of pathogenicity, Transplantation 64 (5) (1997) 674–678 [published Online First: 1997/10/06].

[27] K.A. Marr, R.A. Carter, M. Boeckh, et al., Invasive aspergillosis in allogeneic stem cell transplant recipients: changes in epidemiology and risk factors, Blood 100 (13) (2002) 4358–4366, http://dx.doi.org/10.1182/blood-2002-05-1496 [published Online First: 2002/10/24].

[28] T. Fukuda, M. Boeckh, R.A. Carter, et al., Risks and outcomes of invasive fungal infections in recipients of allogeneic hematopoietic stem cell transplants after nonmyeloablative conditioning, Blood 102 (3) (2003) 827–833, http://dx.doi.org/10.1182/blood-2003-02-0456 [published Online First: 2003/04/12].

[29] A. Cornillet, C. Camus, S. Nimubona, et al., Comparison of epidemiological, clinical, and biological features of invasive aspergillosis in neutropenic and nonneutropenic patients: a 6-year survey, Clin. Infect. Dis. 43 (5) (2006) 577–584, http://dx.doi.org/10.1086/505870 [published Online First: 2006/08/04].

[30] M. Weisser, C. Rausch, A. Droll, et al., Galactomannan does not precede major signs on a pulmonary computerized tomographic scan suggestive of invasive aspergillosis in patients with hematological malignancies, Clin. Infect. Dis. 41 (8) (2005) 1143–1149, http://dx.doi.org/10.1086/444462 [published Online First: 2005/09/16].

[31] T.J. Walsh, E.J. Anaissie, D.W. Denning, et al., Treatment of aspergillosis: clinical practice guidelines of the Infectious Diseases Society of America, Clin. Infect. Dis. 46 (3) (2008) 327–360, http://dx.doi.org/10.1086/525258.