Oral Science International 11 (2014) 37–39

Contents lists available at ScienceDirect

Oral Science International

journal homepage: www.elsevier.com/locate/osi

Case Report

A case of mucositis due to the allergy to self-curing resin☆

Ken-ichiro Hashimoto*, Kaori Naganuma, Yoshihiro Yamashita, Tetsuro Ikebe, Satoru Ozeki

Department of Oral & Maxillofacial Surgery, Fukuoka Dental College, Fukuoka, Japan

ARTICLE INFO

Article history:
Received 8 August 2013
Received in revised form 10 October 2013
Accepted 18 October 2013

Keywords:
Resin allergy
Self-curing resin
Delayed allergy
Methyl methacrylate

ABSTRACT

A 59-year-old woman noticed a swelling and redness in the buccal and palatal mucosa 12 h after setting of a temporary crown (TEK) made of self-curing resin at a dental clinic. When she came to our hospital, the edema and redness in the buccal and palatal mucosa around the right upper molar were seen. The TEK had already been removed at the clinic. We suspected an allergy to TEK, and performed a patch test to the chemicals of the resin. The only liquid component of resin showed a positive reaction. Topical glucocorticoid ointment was applied, and the symptoms almost subsided 3 days later.

© 2013 Japanese Stomatological Society. Published by Elsevier Ltd. All rights reserved.

1. Introduction

Many materials and chemicals have been used in dental treatment. These dental materials occasionally induce allergic reactions locally as well systemically. The systemic allergy includes anaphylactic shock and palmoplantar pustulosis, while the local allergic reaction causes oral mucositis and lichenoid lesions [1,2]. Previous reports showed most allergic cases occurred against dental metals such as chromium and nickel [1–3]. Not only metals but also the agents for local anesthesia and root canal therapy also lead to allergies [1,4]. However, there have been few reports about allergy to dental resins [1,5]. As highly qualified dental resins are developed and used in various dental treatments, allergies to the components of dental resins may increase in the future.

In the present case report, we report a case of allergic oral mucositis after setting of a temporary crown (TEK) made of self-curing resin.

2. Case report

A 59-year-old woman underwent a setting of a TEK made of self-curing resin (UNIFAST II®, GC Corporation, Tokyo, Japan) to the abutment of the right upper first molar with a temporary cement (HY-BOND TEMPORARY CEMENT®, Shofu Inc., Kyoto, Japan) at a general dental clinic. Twelve hours later, she noticed a swelling and redness at the right buccal and palatal mucosa, and went back to the clinic. Then, 1 h later, she was referred to our hospital for these symptoms.

Her consciousness was clear. The body temperature was 36.8° centigrade, blood pressure was 130/80 mm Hg, and pulse rate was 65 beats per minute. No dyspnea was seen, and SpO_2 was 99%. The extraoral examination revealed a normal skin color, no itching, no swelling, and no edema on the face. The intraoral examination showed a swelling and redness around a right buccal and soft palate mucosa (Fig. 1A and B). Spontaneous pain was slight, whereas the tenderness was severe. The swelling region was edematous by palpation, no hemorrhage and Nikolsky phenomenon were observed. The TEK had been already removed at the dental clinic before coming to our hospital. Her medical history was noncontributory. Because of the location, where the right upper first molar was adjacent to, the timing, and when the symptoms occurred soon after the TEK setting, we suspected a resin allergy to the TEK components. The laboratory examination revealed no abnormal data including non-specific IgE (31.7 IU/ml) and eosinophils (3%). Since the TEK, the putative allergen, had already been removed, we applied a glucocorticoid ointment on the lesion.

In order to search for the allergen, we examined a skin patch test. The components, powder (polymer) and liquid (monomer), of UNIFAST II® resin as well as the components of HY-BOND TEMPORARY CEMENT® were applied onto her left shoulder (Fig. 2A). The results were evaluated according to the standard of International Contact Dermatitis Research Group. Forty-eight hours later, erythema and papula were seen only on the region of liquid of UNIFAST II® and judged as a positive reaction (Fig. 2B and C). The responses to the other components were negative. We regarded the liquid of UNIFAST II® as an allergen.

☆ A part of the contents of this article was firstly reported in the Japanese-written magazine named DENTAL DIAMOND (2012;37:145–6).

* Corresponding author at: 2-15-1 Tamura, Sawara-ku, Fukuoka 814-0193, Japan. Tel.: +81 92 801 0411; fax: +81 92 801 1288.
E-mail address: hashiken@college.fdcnet.ac.jp (K.-i. Hashimoto).

1348-8643/$ – see front matter © 2013 Japanese Stomatological Society. Published by Elsevier Ltd. All rights reserved.
http://dx.doi.org/10.1016/S1348-8643(13)00027-X

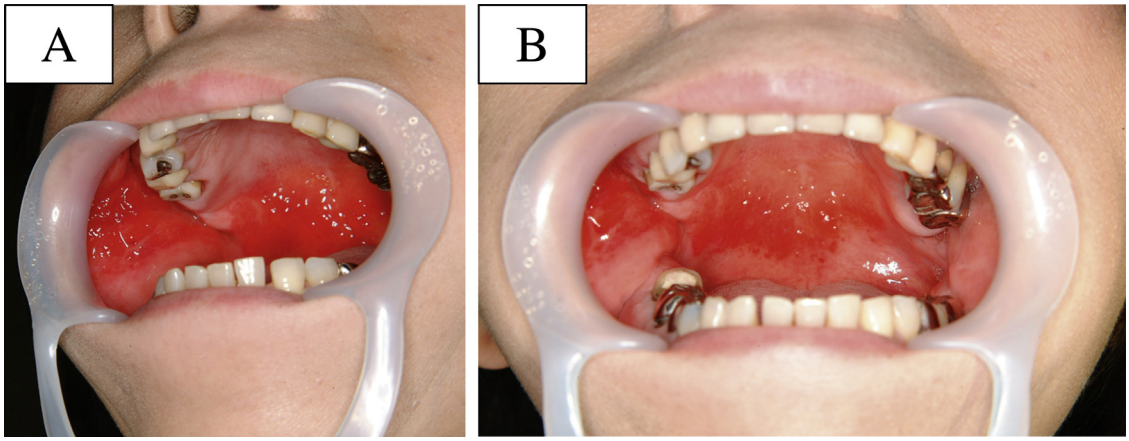

Fig. 1. Intraoral findings of the case at the initial consultation. Well-circumscribed edematous swelling and redness were observed from the right buccal mucosa to soft palate.

The swelling and redness gradually decreased, and only remained as a partial erosion after 3 days (Fig. 3A and B). All symptoms disappeared one week later. As a final prosthesis, a metal crown was set to her abutment tooth. Then, no allergy appeared. We finally diagnosed this case as a delayed allergy (allergic mucositis) caused by self-curing resin monomer.

3. Discussion

Various dental treatments require a number of materials and chemicals, some of which are reported to induce allergic reactions [6,7]. Although most of the dental allergens are metallic materials, a resin allergy is rare. We recognized 15 reports of oral allergic mucositis caused by resin from 1990 to 2006 [5,8–17]. However, the number of case reports about resin allergy appears to decrease year by year. Even after reviewing 15 reports, the sensitization to acrylic monomer occurring in oral mucosa after TEK treatment appears to be rare. Mucosal involvement in sensitization to acrylic monomer in a dental patient is rare. It is important for dentists to be aware of resin allergy. However, the occasions to use dental resins are increasing [15]. Self-curing resin is frequently used for TEK, restoration of caries, denture repair, individual trays for impression, and so on. The polymerization of resin is induced by mixing powder and liquid which are

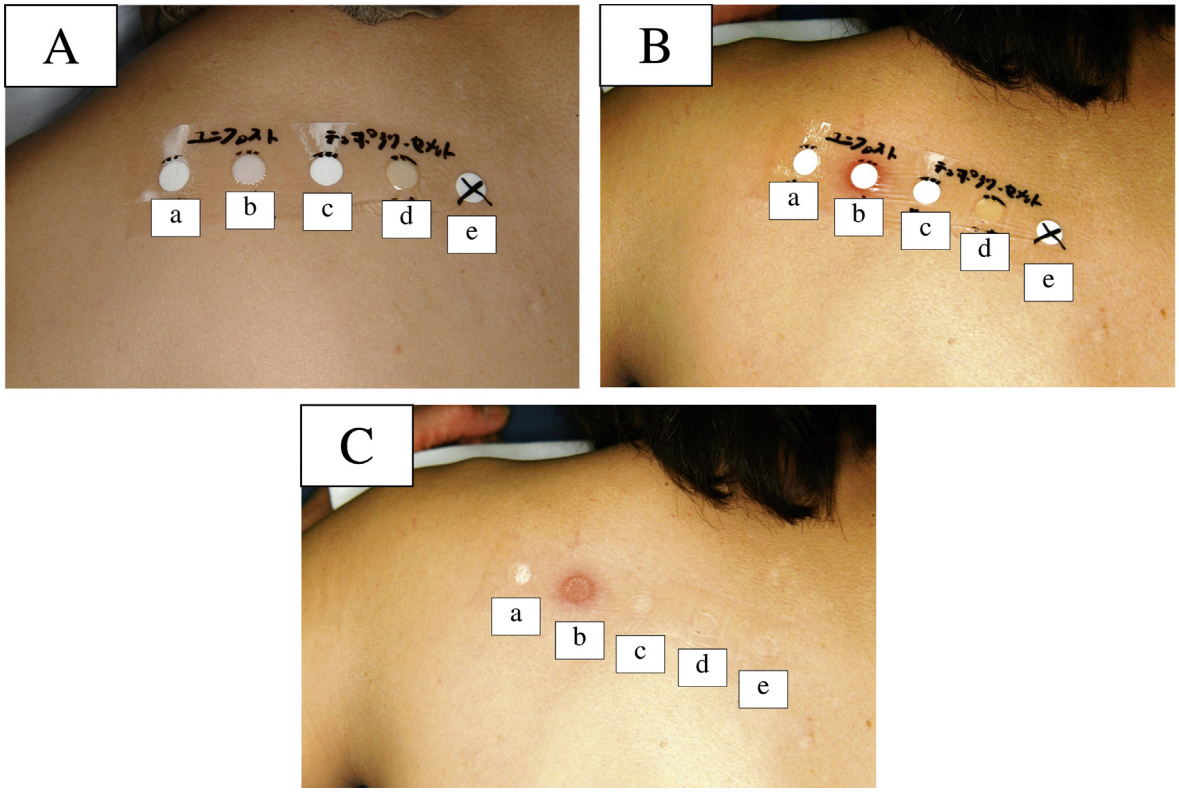

Fig. 2. Skin patch test. (A) Start of patch test. Powder and liquid of UNIFAST II®, and powder and liquid of HY-BOND TEMPORARY CEMENT® were patched on to the right back shoulder region. (B and C) Forty-eight hours after patching. Only the liquid of UNIFAST® region indicated a positive reaction (erythema and papula). The powder of UNIFAST II® and HY-BOND TEMPORARY CEMENT® components were judged as a negative. (a) Powder of UNIFAST II®; (b) liquid of UNIFAST II®; (c) powder of HY-BOND TEMPORARY CEMENT®; (d) liquid of HY-BOND TEMPORARY CEMENT®; and (e) control.

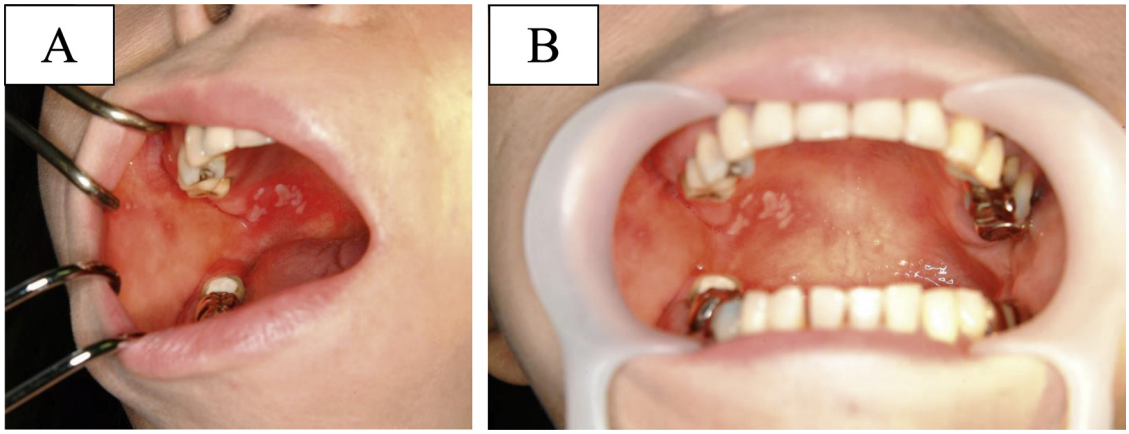

Fig. 3. Intraoral findings 3 days after removal of a temporary crown (TEK). Mucous swelling and redness range reduced, and some erosion remained, but the pain disappeared.

composed primarily of a polymethyl methacrylate (PMMA) and methyl methacrylate (MMA), respectively. The symptoms of this case are thought to be caused by allergy to MMA which is a main constituent of the liquid of self-curing resin, because a redness and swelling occurred soon after the fitting of the TEK and disappeared after removal a few days later. Moreover, a patch test indicated a positive reaction to the liquid of resin, but not powder. The powder and liquid for the cement, which is used for TEK setting, were negative in a patch test. Since the mucosal symptoms developed at least 12 h after TEK setting, this allergic reaction was considered to be due to type IV allergy (contact allergy).

It was suspected that a direct stimulation by the liquid of the resin caused a non-specific dermatitis in the patch test. However, dermatitis did not occur in some healthy volunteers with the same patch test. There are some reports of an allergy caused by MMA [5]. Most resin allergies in the previous reports were due to hydroxyethyl methacrylate (HEMA) [18,19]. However, HEMA was not included in the self-curing resin which was used in this case. However, the possibility of other small components (tertiary amine and so on), which are included in the liquid as an antigen is not excluded.

More attention will be necessary on the occasion of resin usage because TEK is often made in an oral cavity by brush-on technique, where the liquid component of resin may directly attach to oral mucosa and easily induce allergic reactions. Therefore, it would be preferable to avoid manufacturing a TEK directly in the oral cavity. In addition, when a resin polymerization is incomplete, the monomer remains in the TEK and is eluted into the mouth. Other authors have widely studied the allergic influence of residual monomer in the oral cavity [20,21]. For that reason, TEK should be polymerized completely according to the instructions by proper method and technique. Considering the increased use of resin in future, we should pay attention to the allergy to resin.

Conflict of interest

This report has no conflict of interest.

References

[1] Hutchinson I. Hypersensitivity to an orthodontic bonding agent. *Br J Orthod* 1994;21:331–3.
[2] Moore MM, Burke FJ, Felix DH. Allergy to a common component of resin-bonding systems: a case report. *Dent Update* 2000;27:432–4.
[3] Natsuaki M. Results of patch testing with standard allergens of the Japanese Society for Contact Dermatitis and topical nonsteroidal anti-inflammatory preparations in 1998. *Environ Dermatol* 2000;7:1–5.
[4] Mittermuller P, Szeimies RM, Landthaler M, et al. A rare allergy to polyether dental impression material. *Clin Oral Invest* 2012;16:1111–6.
[5] Daecke C, Schaller J, Goos M. Acrylates as potent allergens in occupational and domestic exposure. *Contact Dermatitis* 1994;30:190–1.
[6] Jacobsen N, Hensten-Pettersen A. Occupational health problems and adverse patient reactions in periodontics. *J Clin Periodontol* 1989;11:254–64.
[7] Rustemeyer T, Frosch PJ. Occupational skin diseases in dental laboratory technicians. *Contact Dermatitis* 1996;34:125–33.
[8] Guerra L, Vincenzi C, Peluso AM, et al. Role of contact sensitizers in the burning mouth syndrome. *Am J Contact Dermatitis* 1993;4:154–7.
[9] Olveti E. Contact dermatitis from an acrylic-metal dental prosthesis. *Contact Dermatitis* 1991;24:57.
[10] Corazza M, Virgili A, Martina S. Allergic contact stomatitis from methyl methacrylate in a dental prosthesis, with a persistent patch test reaction. *Contact Dermatitis* 1992;26:210–1.
[11] Agner T, Menné T. Sensitization to acrylates in a dental patient. *Contact Dermatitis* 1994;30:249–50.
[12] Kobayashi T, Sakuraoka K, Hasegawa Y, et al. Contact dermatitis due to an acrylic dental prosthesis. *Contact Dermatitis* 1996;35:370–1.
[13] Koch P, Baum HP, John S. Purpuric patch test reaction and venulitis due to methyl methacrylate in a dental prosthesis. *Contact Dermatitis* 1996;34:213–5.
[14] Kanerva L, Alanko K. Stomatitis and perioral dermatitis caused by epoxy diacrylates in dental composite resins. *J Am Acad Dermatol* 1998;38:116–20.
[15] Gonçalves TS, Morganti MA, Campos LC, et al. Allergy to auto-polymerized acrylic resin in an orthodontic patient. *Am J Orthod Dentofacial Orthop* 2006;129:431–5.
[16] Ruiz-Genao DP, Moreno de Vega MJ, Sánchez Pérez J, et al. Labial edema due to an acrylic dental prosthesis. *Contact Dermatitis* 2003;48:273–4.
[17] Koutis D, Freeman S. Allergic contact stomatitis caused by acrylic monomer in a denture. *Australas J Dermatol* 2001;42:203–6.
[18] Katsuno K, Manabe A, Hasegawa T, et al. Possibility of allergic reaction to dentin primer – application to the skin of guinea pigs. *Dent Mater J* 1992;11:77–82.
[19] Kanerva L, Estlander T, Jolanki R, et al. Occupational allergic contact dermatitis caused by exposure to acrylates during work with dental prosthesis. *Contact Dermatitis* 1993;28:268–75.
[20] Stafford GD, Brooks SC. The loss of residual monomer from acrylic orthodontic resins. *Dent Mater* 1985;1:135–8.
[21] Harrison A, Huggett R. Effect of the curing cycle on residual monomer levels of acrylic resin denture base polymers. *J Dent* 1992;20:370–4.