J. Comp. Path. ▮▮▮▮, Vol. ▮, ▮▮▮–▮▮▮

Available online at www.sciencedirect.com

ScienceDirect

ELSEVIER

www.elsevier.com/locate/jcpa

Characterization of Inflammatory Cell Infiltration in Feline Allergic Skin Disease

K. Taglinger[*], M. J. Day[†] and A. P. Foster[‡]

[*] *Buchenstr. 12, A-4861 Schoerfling, Austria,* [†] *School of Clinical Veterinary Science, University of Bristol, Langford House, Langford, Bristol BS40 5DU, and* [‡] *Veterinary Laboratories Agency, Shrewsbury, Kendal Road, Harlescott, Shrewsbury SY1 4HD, UK*

Summary

Sixteen cats with allergic dermatitis and six control cats with no skin disease were examined. Lymphoid and histiocytic cells in skin sections were examined immunohistochemically and mast cells were identified by toluidine blue staining. The 16 allergic cats showed one or more of several features (alopecia, eosinophilic plaques or granulomas, papulocrusting lesions), and histopathological findings were diverse. In control cats there were no cells that expressed IgM or MAC387, a few that were immunolabelled for IgG, IgA or CD3, and moderate numbers of mast cells. In allergic cats, positively labelled inflammatory cells were generally more numerous in lesional than in non-lesional skin sections, and were particularly associated with the superficial dermis and perifollicular areas. There were low numbers of plasma cells expressing cytoplasmic immunoglobulin; moderate numbers of MHC II-, MAC387- and CD3-positive cells; and moderate to numerous mast cells. MHC class II expression was associated with inflammatory cells morphologically consistent with dermal dendritic cells and macrophages, and epidermal Langerhans cells. Dendritic cells expressing MHC class II were usually associated with an infiltrate of CD3 lymphocytes, suggesting that these cells participate in maintenance of the local immune response by presenting antigen to T lymphocytes. These findings confirm that feline allergic skin disease is characterized by infiltration of activated antigen-presenting cells and T lymphocytes in addition to increased numbers of dermal mast cells. This pattern mimics the dermal inflammation that occurs in the chronic phase of both canine and human atopic dermatitis.

© 2007 Elsevier Ltd. All rights reserved.

Keywords: allergy; cat; eosinophil; skin

Introduction

Atopic dermatitis, a chronic, inflammatory, pruritic skin disease affects both human beings and companion animals, especially dogs (Leung, 1995; Scott *et al.*, 2001). Many clinical and histopathological features of atopic dermatitis in dogs are similar to those found in man (Soter, 1989; Leung, 2000; Olivry and Hill, 2001; Marsella and Olivry, 2003). In cats, recurrent pruritic skin disease showing certain clinical similarities to human atopic dermatitis has been recognized for many years. As a consequence of pruritus, self-induced alopecia with or without primary lesions is a frequent presentation of feline atopic dermatitis. The feline disease is particularly diverse, however, and may present in various clinical forms, including symmetrical alopecia, "miliary" papulo-crusting dermatitis and eosinophilic granuloma complex lesions, which are distinct from the clinical features of atopic human patients and dogs (Marsella and Olivry, 2003; Foster and Roosje, 2005). This diversity of clinical presentation means that it is difficult to make an accurate clinical diagnosis of atopic dermatitis in cats. This problem is further complicated by the fact that the same cutaneous reaction patterns may accompany flea- or food-hypersensitivity. Indeed, cats may have environmental, flea and food allergies concurrently (Halliwell, 1997). It is also widely accepted that skin biopsy samples from cats with allergic skin disease are not diagnostic for the type of hypersensitivity, and that the pathological changes observed

Correspondence to: A.P. Foster (e-mail: a.foster@vla.defra.gsi.gov.uk).

0021-9975/$ - see front matter
doi:10.1016/j.jcpa.2007.07.001

© 2007 Elsevier Ltd. All rights reserved.

Please cite this article as: Taglinger, K., et al. Characterization of Inflammatory Cell Infiltration in Feline Allergic Skin Disease. *Journal of Comparative Pathology.* (2007), doi:10.1016/j.jcpa.2007.07.001

may vary depending on the clinical lesions sampled (Yager and Wilcock, 1994; Scott *et al.*, 2001; Gross *et al.*, 2005).

Skin biopsy samples from lesional skin of human patients with atopic dermatitis have increased numbers of Langerhans cells (LCs) and dermal dendritic cells. These cells act as potent antigen-capturing and -presenting cells and play a major role in the pathogenesis of the disease (Leung *et al.*, 1987; Allam and Novak, 2006). Moreover, reports implicating the importance of dendritic cells in canine atopy have also been published (Day, 1996; Olivry *et al.*, 1997). The quantitative distribution of epidermal LCs has been evaluated in normal cats (Saint-Andre Marchal *et al.*, 1997b) and these cells have been phenotypically characterized as expressing CD18, MHC class II, CD1a and CD4 (Saint-Andre Marchal *et al.*, 1997a). Roosje *et al.* (1997) reported significantly greater numbers of CD1a-positive and MHC class II-positive dendritic cells in lesional skin from atopic cats than in the skin of healthy control cats; however, the authors did not describe the clinical features or the types of lesion sampled. In cats with recurrent "miliary" papulo-crusting dermatitis a significant total increase in dermal T-cell numbers was reported (Roosje *et al.*, 1998). Subsequently, significantly more IL-4-positive cells were found in lesional and non-lesional skin from allergic cats than in healthy controls (Roosje *et al.*, 2002). These results are consistent with studies of immune-cell infiltrates in human and canine atopic skin (Van der Heijden *et al.*, 1991; Sinke *et al.*, 1997).

Mast cell numbers in normal feline skin may vary depending on location (Foster, 1994; Beadleston *et al.*, 1997). Toluidine blue staining revealed no significant differences in median mast cell density between skin from control dogs and skin (lesional or non-lesional) from atopic dogs. However, a double-enzyme labelling technique (labelling of the mast cell-specific proteases tryptase and chymase) demonstrated that the median mast cell density was significantly lower in lesional and non-lesional skin from atopic dogs than in the skin of controls (Welle *et al.*, 1999). Similarly, differences in mast cell numbers were found in feline allergic skin, depending on the staining method used (Roosje *et al.*, 2004a), but the biopsy site did not appear to affect the number of mast cells (and eosinophils). This was in contrast to earlier reports of these parameters in normal feline skin (Foster, 1994; Beadleston *et al.*, 1997).

The aim of the present study was to throw further light on the nature and distribution of the immune cell populations that infiltrate the skin of cats suffering from allergic dermatitis. To this end, the distribution of T lymphocytes, IgG-, IgA- and IgM-producing plasma cells, macrophages/monocytes, mast cells and MHC class II antigen was analysed in skin biopsy samples from normal cats and cats with allergic skin disease.

Materials and Methods

Biopsy Material From Normal Control Cats

Skin tissue samples from six cats used as normal controls in a previous study (Foster, 1994) were examined. These samples, obtained from the lateral thorax, were formalin-fixed and paraffin wax-embedded. The cats from which they were obtained had a variety of diseases that did not affect the skin, either macroscopically or histopathologically; the clinical details are described in Table 1. The mean age of the control cats was 5.5 years (range 2–14 years).

Biopsy Material From Cats with Allergic Skin Disease

Skin samples were taken from 16 cats presented at the School of Clinical Veterinary Science, University of Bristol. All of the following procedures formed part of the routine diagnostic investigation of suspected allergic skin disease. This group consisted of 14 domestic shorthairs, one Bengal and one Ocicat, and there were seven neutered males, eight neutered females and one entire female. The mean age was 4 years (range 1–8 years). Details of these animals, together with the location of the skin lesions and the type of the lesions sampled, are given in Table 2. Cats were included in the study if they showed chronic or recurrent pruritus or dermatitis, or both. Pruritus due to ectoparasite infestation was ruled out by investigation of the coat, hair plucks and skin scrapings, in addition to appropriate ectoparasiticidal treatment. Dermatophyte infection was excluded by negative fungal culture. To rule out dietary hypersensitivity as a cause of pruritus, owners were requested to feed their cats a home-prepared diet for 6–8 weeks. Unfortunately, due to lack of compliance, only four cats finished this dietary trial, but none of these showed any clinical improvement. For the other 12 cats, an elimination diet was recommended at the time of consultation, but as owner and animal

Table 1
Six control (C) cats

Cat	*Age (years)*	*Sex*	*Breed*	*Disease status*
1	3	FN	Siamese	Lymphadenopathy
2	7	FN	Burmese	Hyperadrenocorticism
3	1.5	FE	DSH	FIV-positive
4	2	MN	DSH	FIV-positive+*Chlamydia*
5	6	MN	DSH	Hyperadrenocorticism
6	14	MN	DSH	Hyperthyroidism

DSH, domestic short hair; MN, neutered male; FN, neutered female; FE, entire female; FIV, feline immunodeficiency virus.

Please cite this article as: Taglinger, K., et al. Characterization of Inflammatory Cell Infiltration in Feline Allergic Skin Disease. *Journal of Comparative Pathology.* (2007), doi:10.1016/j.jcpa.2007.07.001

Table 2
Details of 16 cats with allergic skin disease

Case number	*Breed*	*Age (years)*	*Gender*	*Body site*	*Skin lesion type/non-lesional*	*Skin sample site*
1	DSH	3	MN	6	Plaque	Preauricular
2	Bengal	2	FN	7	Plaque	Neck
3	Ocicat	1	FE	5	Non-lesional	Lateral thigh
				4	Alopecia	Medial thigh
4	DSH	5	FN	2	Non-lesional	Ventral abdomen
				1	Non-lesional	Lateral thorax
				6	Non-lesional	Preauricular
				3	Non-lesional	Dorsum
5	DSH	4	FN	5	Plaque	Lateral thigh
				2	Alopecia/papules	Ventral abdomen
				2	Alopecia	Ventral abdomen
				1	Non-lesional	Lateral thorax
6	DSH	6	MN	2	Plaque	Ventral abdomen
				1	Non-lesional	Lateral thorax
7	DSH	7	FN	1	Non-lesional	Lateral thorax
				6	Plaque	Preauricular
8	DSH	8	MN	3	Alopecia	Dorsum
				1	Non-lesional	Lateral thorax
9	DSH	3	MN	6	Papules/crusts	Preauricular
				1	Non-lesional	Lateral thorax
				2	Alopecia/plaque	Ventral abdomen
10	DSH	3	FN	1	Non-lesional	Lateral thorax
				4	Alopecia	Medial thigh
11	DSH	1.3	MN	1	Non-lesional	Lateral thorax
				5	Eos. granuloma	Lateral thigh
12	DSH	6	MN	1	Non-lesional	Lateral thorax
				6	Alopecia	Preauricular
				2	Alopecia	Ventral abdomen
13	DSH	5	FN	1	Non-lesional	Lateral thorax
				7	Plaque	Neck
				2	Alopecia	Ventral abdomen
14	DSH	4	FN	1	Non-lesional	Lateral thorax
				2	Alopecia	Ventral abdomen
15	DSH	3	MN	1	Non-lesional	Lateral thorax
				8	Plaque	Axilla
				8	Alopecia	Cranial shoulder
				2	Alopecia	Ventral abdomen
16	DSH	2.6	FN	1	Non-lesional	Lateral thorax
				7	Crusts	Neck
				7	Ulceration	Neck

The types of skin sampled included non-lesional (i.e. unaffected) skin, alopecia, plaques, eosinophilic granuloma, papules, crusts and ulcers.
The lesion sites were numbered 1–8 (1 = lateral thorax, 2 = ventral abdomen, 3 = tail base/lumbar area/dorsum, 4 = medial thigh, 5 = lateral thigh, 6 = preauricular area, 7 = lateral cheek/neck, 8 = other).
Samples were taken from all the lesions present in each animal (1–4 per cat).
Because cat 4 showed pruritus without skin lesions, non-lesional skin was sampled from several pruritic areas.
DSH, domestic short hair; MN, neutered male; FN,neutered female; FE, entire female; eos. granuloma, eosinophilic granuloma.

compliance were poor, and follow-up was not always possible, no results of this procedure are available.

Sampling

All cats were anaesthetized with a mixture of medetomidine (Domitor™; Pfizer Ltd, Surrey, UK) 0.025 μg/kg and butorphanol (Torbugesic™; Fort Dodge Animal Health, Southampton, UK) 0.1 mg/kg by intramuscular injection. Lesional biopsy tissue was taken from each cat ($n = 26$, one to four skin sites being sampled per cat). One sample of non-lesional skin was collected from the left lateral thorax of each cat, this site being routinely shaved for intradermal testing ($n = 13$). Alternatively, non-lesional skin from the side opposite to that of the lesional area was sampled ($n = 1$). The macroscopical features of skin lesions sampled included alopecia, eosinophilic granuloma, plaques, papules, crusts and ulcers. The location of these biopsy sites in the normal cats was assigned a number from 1 to 7 (1 = lateral

thorax, 2 = ventral abdomen, 3 = tail base/lumbar area/dorsum, 4 = medial thigh, 5 = lateral thigh, 6 = preauricular area, 7 = lateral cheek/neck). Lesions from anatomical locations that differed from these standard sites were placed in a separate group (8). Anaesthesia was reversed with an intramuscular injection of atipamezole (Antisedan™; Pfizer).

Histopathology

One-half of a punch-biopsy skin sample (6 mm) from cats with allergic skin disease was fixed in 10% neutral-buffered formalin and embedded in paraffin wax. Sections (5 μm) were stained with haematoxylin and eosin (HE) or toluidine blue (TB). The other half of the sample was stored at −70 °C for RNA studies reported previously (Taglinger *et al.*, 2004).

Immunohistochemistry (IHC)

Serial unstained sections (5 μm) from all tissue samples were prepared and mounted on 4-spot microscope slides (Multispot Microscopic Slides, Hendley Ltd, Loughton, UK) coated with 3-aminopropyltriethoxysilane (Sigma-Aldrich, Poole, UK).

Cells present in the skin biopsy samples were labelled with a panel of monoclonal and polyclonal antibodies (Table 3). Antisera recognizing feline IgG γ chain, IgM μ chain, IgA α chain (expressed primarily within the cytoplasm of plasma cells), CD3 (expressed by T lymphocytes), MAC387 antigen (expressed by cells of the monocyte-macrophage and granulocytic lineages) and MHC class II (expressed primarily by dendritic cells, activated macrophages and B lymphocytes) were used. This panel of antisera had been previously validated and widely applied to studies of feline tissue in our laboratory (Waly *et al.*, 2001, 2005; Harley *et al.*, 2003).

Sections were de-waxed in Histo-Clear (National Diagnostics, Hessle, UK) for 7 min. They were rehydrated through a series of graded alcohols (twice for 3 min in ethanol 100%, then 3 min in ethanol 70%) and washed in running tap water for 3 min before being placed in phosphate-buffered saline (PBS; pH 7.4, 0.01 M) for 10 min. PBS was also used to wash slides between incubations. All procedures were performed at room temperature unless otherwise stated.

After dewaxing and rehydration, antigen retrieval was performed either by trypsin digestion or by heating in citrate buffer. For labelling of IgG, IgA, IgM, MAC387 and CD3, sections were incubated in calcium trypsin solution (trypsin 0.1% and calcium chloride 0.1% in distilled water, pH 7.8; both from Sigma-Aldrich) at 37 °C for 25 min. For demonstration of MHC class II antigen, slides were incubated in citrate buffer (0.01 M, pH 6.0), placed in a microwave oven, heated until the solution boiled, left to simmer for a further 10 min, and then cooled at room temperature for 10 min. Following the appropriate pre-treatment, sections were washed in PBS for 10 min. Endogenous peroxidase activity was blocked by incubating the slides for 30 min in an equal mixture of methanol and PBS containing hydrogen peroxide 0.6%. Then, non-specific binding was blocked by incubation with either rabbit serum 10% (Sigma-Aldrich) in PBS (for IgG, IgA, IgM, MAC387 and MHC class II) or goat serum 20% (Sigma-Aldrich) and normal cat serum 2.5% in PBS (for CD3) for 30 min. Subsequently, sections were incubated for 90 min (IgG, IgA, IgM, CD3) or overnight at 4 °C (MAC387 and MHC class II) with primary antisera (Table 3), followed by application of secondary antibodies for 30 min (Table 3).

Antibodies were diluted in PBS, except for the primary and secondary antisera for CD3 labelling, which

Table 3
Primary and secondary antibodies used for immunohistochemical labelling of formalin-fixed tissue

Specificity	*Primary antibody*			*Secondary antibody*	
	Description	*Isotype*	*Dilution*	*Description*	*Dilution*
IgG	Goat anti-cat IgG (Fc)★	Pc	1 in 500	Rabbit anti-goat IgG-HRP‡	1 in 500
IgA	Goat anti-cat IgA (Fc)†	Pc	1 in 400		
IgM	Goat anti-cat IgM (Fc)†	Pc	1 in 400		
CD3	Rabbit-anti human CD3‡	Pc	1 in 200	Goat anti-rabbit IgG-biotinylated§	1 in 800
MAC 387	Mouse anti-human MAC387‡	IgG1	1 in 1000	Rabbit anti-mouse Ig-biotinylated‡	1 in 500
MHC class II	Mouse anti-human HLA-DR‡	IgG1	1 in 25		1 in 100

HRP, horseradish peroxidase conjugated; Pc, polyclonal.
★Jackson ImmunoResearch Laboratories, West Grove, Pennsylvania, USA.
†Nordic Immunochemical Laboratories, Tilberg, the Netherlands.
‡DakoCytomation, Glostrup, Denmark.
§Sigma-Aldrich, Poole, Dorset, UK.

Please cite this article as: Taglinger, K., et al. Characterization of Inflammatory Cell Infiltration in Feline Allergic Skin Disease. *Journal of Comparative Pathology.* (2007), doi:10.1016/j.jcpa.2007.07.001

were diluted in PBS containing cat serum 2.5%. After primary and secondary incubations, avidin-biotin-horseradish peroxidase complex (ABC/HRP; DakoCytomation; Glostrup, Denmark) was applied to all sections for 30 min. Sections were then incubated with TrisHCl (0.05 M, pH 7.6) containing 3,3′-diaminobenzidine 0.05% (DAB Chromogen; DakoCytomation) and hydrogen peroxide 0.02% (H_2O_2 30% [w/w]; Sigma-Aldrich). Gradual development of slides was monitored under a microscope set at low-power and the process was stopped by washing in distilled water as soon as optimal staining with minimal background was achieved. Sections were counterstained with Mayer's haematoxylin 10% for 1 min and washed under running tap water for 3 min, before being dehydrated through graded alcohols and Histo-Clear for 3 min and mounted under DPX (DPX Mounting Medium, Raymond Lamb, Eastbourne, UK). Sections of feline lymph node were routinely included in each experiment as positive controls. Isotype-matched antibodies of irrelevant specificities for *Aspergillus niger* glucose oxidase (Mouse IgG1; DakoCytomation) were used as negative controls in place of specific monoclonal antisera (MAC387 and MHC class II). As a negative control for the polyclonal antibodies, normal serum from the same species was used at a dilution equal to that of the antibody.

Histopathological Grouping of HE-stained Sections

All the slides were examined "blind" by one of the authors (MJD) on a single occasion. Sections were evaluated for pathological changes in four skin compartments including the epidermis and dermis, and for the distribution, type and severity of the cellular infiltration. Cats were grouped according to the histopathological nature of their skin lesions.

Scoring of Immunohistochemically labelled and Toluidine Blue-stained Sections

Immunolabelled sections and toluidine blue-stained sections were individually scored with a subjective scoring system (Robinson *et al.*, 2002). The entire skin section was examined under medium- and high-power magnification. The four skin compartments consisted of the epidermis and interface area, hair follicles and perifollicular area, superficial dermis, and the deep dermis, each being examined and scored separately. The score was based on the number of positively labelled cells in these four different locations in fields examined with the $\times 40$ objective. The scoring system was as follows: 0 = no cells, 1 = <10 cells per field (low), 2 = 10–50 cells per field (moderate), and 3 = >50 cells per field (many). Adding the four individual scores gave a cumulative score.

Results

Clinical Features

Ventral abdominal alopecia was the most common clinical finding in nine of the 16 cats in this study (Table 2). Eosinophilic plaques/granuloma, also frequently seen ($n = 9$), occurred mostly around the head and neck but also on other parts of the body. Three cats showed papular-crusting lesions, which usually accompanied alopecia or eosinophilic plaque lesions, or both. Papular-crusting lesions were sampled only if they represented the most prominent type of lesion; this was the case in two cats. Only one cat showed pruritus without skin lesions.

Histopathological Patterns

The histopathological findings in the 16 skin samples from the allergic cats were diverse. Consequently, it was not possible to use a scoring system to grade the biopsies on the basis of the intensity of cellular infiltrate or to classify them as acute versus chronic lesions. However, six distinct histopathological patterns were recognized in the samples examined, with two subgroups for pattern 1 and three subgroups for pattern 3. The first pattern included samples consisting of granulation tissue in moderate (subgroup 1a; $n = 2$) or more extensive form (subgroup 1b; $n = 1$). Sections in subgroup 1a were characterized by a light scattering mainly of neutrophils and macrophages, while the subgroup 1b samples showed a more intense cellular infiltration that was largely perivascular and consisted of neutrophils, plasma cells and macrophages.

The second pattern ($n = 2$) was characterized by an early collagenolytic granuloma lesion, with hyaline collagen fibres in the dermis and mixed inflammatory cells, including eosinophils and mast cells.

Pattern 3 displayed microscopical features consistent with a true "hypersensitivity dermatitis". A subgroup 3a ($n = 2$) represented a mild form of this process with superficial dermal infiltration of mast cells and eosinophils (Fig. 1). Subgroup 3b ($n = 2$) showed moderate and more widespread change, with a higher proportion of chronic inflammatory cells (neutrophils, macrophages, mast cells and a few eosinophils). Subgroup 3c ($n = 1$) showed a marked infiltration mainly of mast cells.

Pattern 4 ($n = 1$) was characterized by perifolliculitis. A mild cellular infiltrate consisting of macrophages, eosinophils and neutrophils was seen around follicles and in the superficial and deep dermis.

Pattern 5 ($n = 1$) consisted of a necrotizing furunculosis with a severe neutrophilic inflammatory infiltration within which were observed degenerate collagen

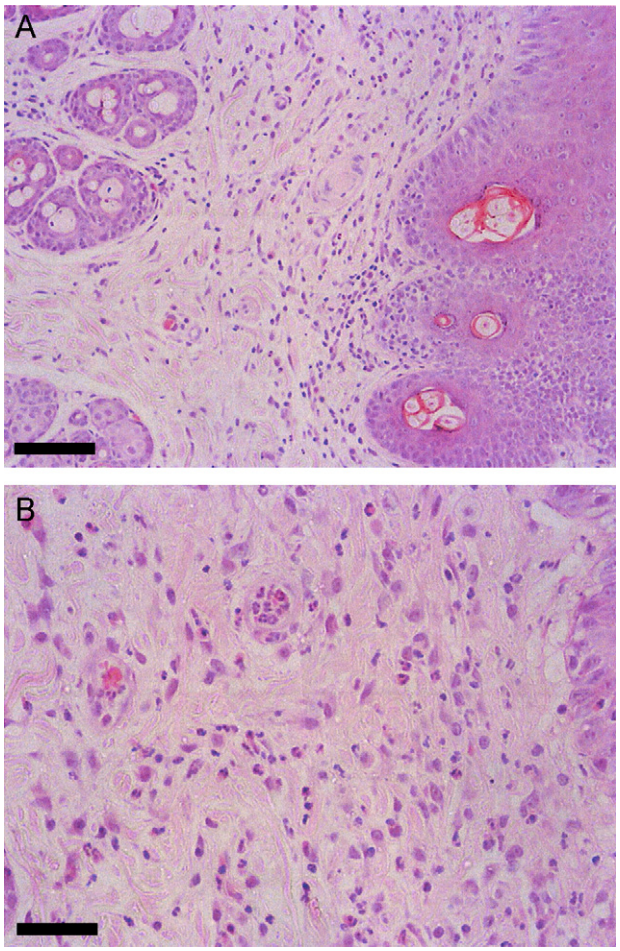

Fig. 1A, B. Representative section of skin biopsy sample from cat with allergic skin disease. Note superficial perivascular dermatitis with evidence of perifolliculitis and mild infiltration consisting mainly of mast cells and eosinophils. HE. Bars, 150 μm (A) and 75 μm (B).

bundles and areas of dermal necrosis. Scattered naked hair shafts were present.

Pattern 6 ($n = 4$) referred to normal histology, similar to that seen in non-lesional samples taken from the lateral thorax of each feline patient. Statistical analysis was not possible because of the low number of cats for each pattern.

Immunolabelled and Toluidine Blue-stained Sections

Biopsy samples were analysed and given a cumulative marker score only if all four skin compartments could be examined. If this was not possible (due to faults in processing or missing areas of the sections), the sample was excluded from descriptive analysis. Consequently, 30 samples from allergic cats were available for analysis of IgG, 33 for IgA, 32 for IgM, 30 for CD3 and 30 for MAC387. Due to the total or partial loss of tissue during the process of epitope retrieval for labelling of sections with MHC class II antiserum, only 17 such sections from allergic cats were available.

Mast cells were identified by their characteristic morphology and the presence of metachromatic granules in toluidine blue-stained sections. Altogether, 29 sections were available for evaluation of mast cells. A summary of the cumulative scores of skin sections from control cats is given in Table 4 and that for cats with allergic skin disease in Table 5. Statistical analysis of cumulative scores was not possible due to the low number of cats for each pattern.

Normal cats. In control cat skin samples, there was no positive labelling for IgM or MAC387, but small to moderate numbers of cells were labelled by anti-IgG or anti-IgA; there were occasional $CD3^+$ cells (Fig. 2). Moderate numbers of mast cells were present.

Allergic cats. In all sections, the number of positive cells for each marker was generally higher in lesional than non-lesional skin. There were, however, more positively labelled cells in non-lesional allergic cat skin than in normal skin.

The antibody for CD3 labelled cells in all four compartments. In samples from lesional skin, moderate numbers of $CD3^+$ cells were found lightly scattered throughout the superficial dermis or in aggregates in and around the hair follicles. In contrast, $CD3^+$ cells appeared in smaller numbers in non-lesional samples, as well as in microscopically normal samples (pattern 6). In all of the samples $CD3^+$ cells were rarely observed in the epidermis.

The MAC387 antibody showed immunoreactivity with only low numbers of monocytes, neutrophils and reactive tissue macrophages; eosinophils, however, were often positively labelled (Fig. 3). In allergic skin samples, MAC387-positive cells occurred generally in all four compartments, with the majority in the superficial dermis and perifollicular area. Overall, there were more $MAC387^+$ cells in lesional than in non-lesional skin, but such cells were rare in sections showing pattern 6.

The antiserum for MHC class II labelled cells in all four compartments. MHC class II^+ cells were primarily located in the superficial dermis and follicular epithelium (Fig. 4). MHC class II^+ cells were generally closely associated with infiltrating $CD3^+$ cells. Few MHC class II^+ cells were seen in the epidermis and deep dermis.

In all of the sections, antibodies for IgG, IgA and IgM labelled occasional plasma cells in the dermis. These were mainly found in the superficial dermis with a perivascular distribution (Figs 5B–D).

Mast cells were present in all of the sections examined. They occurred in moderate to high numbers in all four skin compartments in samples from the cats with allergic skin disease but were not present in the

Table 4
Cumulative scores (immunolabelled cells and toluidine-stained mast cells) in skin sections from six control (C) cats without skin disease

Cat no.	*Cumulative scores for*						
	IgG plasma cells	*IgA plasma cells*	*IgM plasma cells*	*CD3 T-lymphocytes*	*MAC 387*	*MHC class II*	*mast cells*
C1	0	0	0	2	0	ND	3
C2	1	0	0	0	0	ND	2
C3	0	0	0	0	0	ND	4
C4	0	0	0	1	0	ND	5
C5	0	2	0	0	0	ND	3
C6	0	0	0	0	0	ND	4

ND, not determined.

Table 5
Sixteen cats with allergic skin disease: histopathological groups, type of lesion and cumulative scores

Histopathological group	*Cat no.*	*Skin lesion*	*Cumulative scores of*						
			IgG plasma cells	*IgA plasma cells*	*IgM plasma cells*	*CD3 T-lymphocytes*	*MAC 387*	*MHC class II*	*mast cells*
1a	1	Plaque	ND	0	0	6	7	9	3
	16	Non-lesional	1	0	1	3	1	ND	5
		Crusts	ND	0	0	0	11	8	3
1b	6	Plaque	ND	6	6	ND	ND	ND	ND
		Non-lesional	0	3	1	7	1	10	4
2	11	Non-lesional	0	0	0	0	0	ND	3
		Eos. granuloma	0	1	0	5	5	6	7
	2	Plaque	2	1	ND	6	1	ND	6
		Plaque	2	3	0	5	8	10	7
3a	3	Alopecia	0	1	1	4	5	6	4
		Non-lesional	0	1	1	3	1	4	4
	14	Non-lesional	0	0	0	3	0	ND	4
		Alopecia	3	2	2	4	2	8	7
3b	9	Papules/crusts	0	1	0	3	8	10	7
		Non-lesional	0	1	0	1	9	ND	2
		Alopecia/plaque	1	3	0	3	7	8	7
	15	Non-lesional	0	2	1	0	2	5	6
		Plaque	0	2	0	4	11	ND	ND
		Alopecia	2	0	0	6	4	6	9
3c	5	Plaque	4	4	1	ND	ND	ND	ND
4	7	Non-lesional	1	0	0	1	6	3	4
		Plaque	0	0	0	0	1	ND	3
5	13	Non-lesional	0	0	0	1	1	ND	4
		Plaque	0	0	0	ND	ND	ND	ND
		Alopecia	0	1	0	1	0	ND	4
6	4	Non-lesional	0	2	0	0	0	2	4
		Alopecia	0	1	0	0	0	ND	2
	8	Alopecia	0	2	0	2	0	ND	4
		Non-lesional	0	0	0	2	0	ND	4
	10	Alopecia	1	0	0	5	1	3	4
		Non-lesional	0	0	0	2	0	ND	4
	12	Non-lesional	0	1	0	2	1	0	4
		Alopecia	0	0	0	2	2	3	3

ND, not determined; Eos. granuloma, eosinophilic granuloma.

epidermis of normal skin (Fig. 5A). Higher numbers of mast cells were present in lesional than in non-lesional skin, and more such cells were evident in sections classified as pattern 6 than in non-lesional tissue sections.

Discussion

The work described here characterizes the clinical, histopathological and immunohistochemical features of

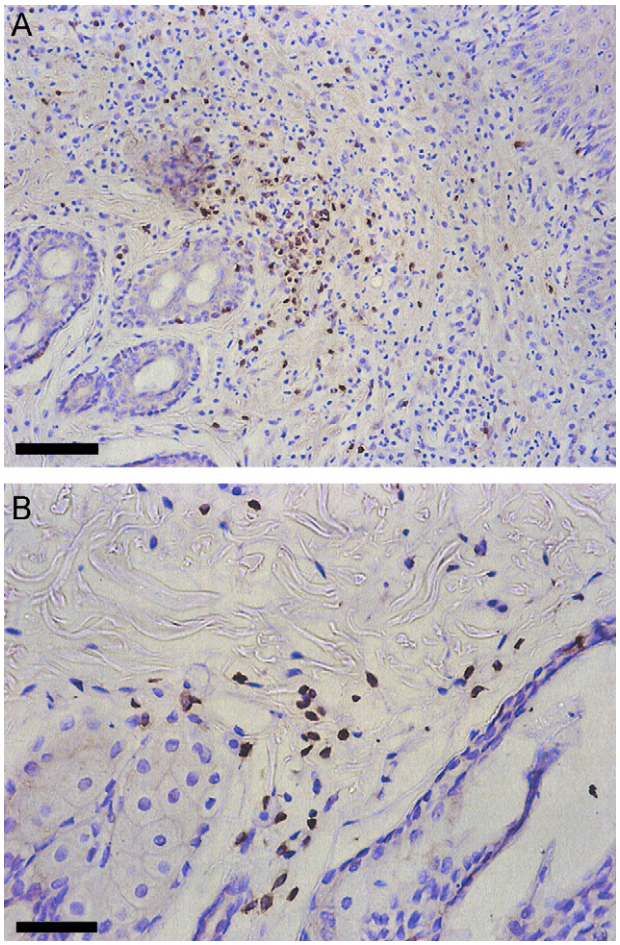

Fig. 2A, B. Allergic skin disease. This skin section shows a few small T lymphocytes in the superficial dermis and perifollicular clusters of T lymphocytes expressing membrane CD3. IHC. Bars, 150 μm (A) and 75 μm (B).

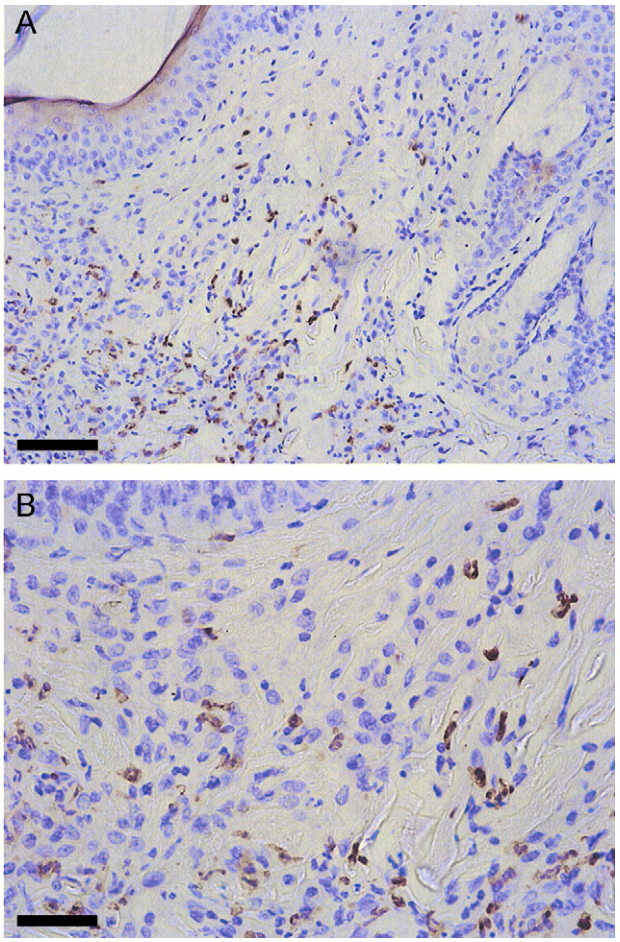

Fig. 3A, B. Allergic skin disease. This skin section shows a diffuse dermal infiltrate of MAC387-positive monocytes and eosinophils. IHC. Bars, 150 μm (A) and 75 μm (B).

16 cats with allergic skin disease. The spectrum of clinical features observed was in keeping with previous descriptions of feline allergic skin disease or feline atopy (Scott *et al.*, 2001).

The histopathological features described in the lesional skin biopsy samples also resembled those previous described in feline atopic dermatitis. Samples from cats with focal non-inflammatory alopecia had a microscopical appearance consistent with published descriptions of a normal to mildly hyperplastic epidermis with superficial perivascular dermatitis (Scott, 1984; Scott *et al.*, 2001). Inflammatory facial or papulo-crusting lesions showed epidermal hyperplasia, spongiosis, crusts, erosions and ulceration, as well as superficial or deep perivascular dermatitis. The cellular infiltrate consisted of a mixture of eosinophils and mast cells with lymphocytes, either scattered throughout or aggregated in clusters. These findings accord with those described in feline allergic skin lesions by Yager and Wilcock (1994). Histologically, these lesions represent a spectrum of tissue reaction patterns. For example, the microscopical appearance of the lesions of "miliary" dermatitis are reported to merge with that of eosinophilic plaque. Similarly, although interstitial rather than perivascular dermatitis may be particularly prominent in eosinophilic plaque lesions, these changes cannot be reliably distinguished from those that occur with papulo-crusting "miliary" dermatitis (Gross *et al.*, 1986, 2005). Reports of studies assessing histopathological features of cats with eosinophilic granuloma complex lesions have described "flame figures", made up of normally stained collagen fibres surrounded by eosinophil debris (Fondati *et al.*, 2001; Bardagi *et al.*, 2003).

Taken together, the histopathological features of feline allergic skin disease appear to be just as varied as the clinical features. Hence, it is impossible to grade reliably and to analyse acute versus chronic skin lesions, a process frequently undertaken in studies of human and canine atopy (Leung, 1995; Werfel *et al.*, 1996; Olivry

Please cite this article as: Taglinger, K., et al. Characterization of Inflammatory Cell Infiltration in Feline Allergic Skin Disease. *Journal of Comparative Pathology.* (2007), doi:10.1016/j.jcpa.2007.07.001

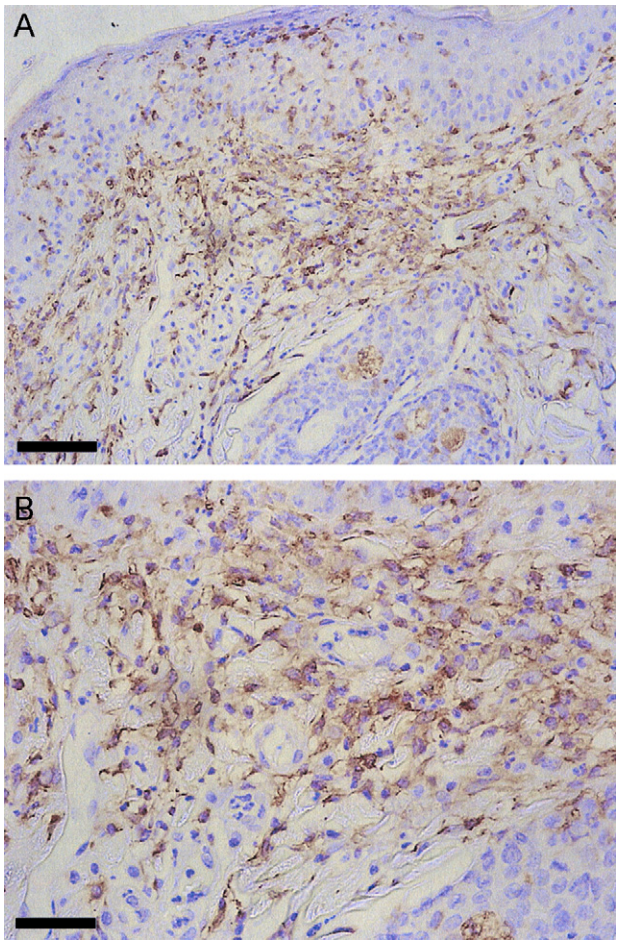

Fig. 4A, B. Allergic skin disease. This skin section shows expression of MHC class II on individual cells in the epidermis, on clusters of cells in the superficial dermis, and on cells associated with hair follicles. IHC. Bars, 150 μm (A) and 75 μm (B).

et al., 1999). Moreover, in future studies, larger numbers of cats will be required to enable statistical comparison to be made between histopathological patterns.

Roosje *et al.* (1997) reported that MHC class II$^+$ epidermal dendritic cells were also CD1a$^+$ in normal feline skin. Quantitative analysis revealed that lesional skin in allergic cats contained significantly more CD1a$^+$ and MHC class II$^+$ dendritic cells in the epidermis and dermis, as compared with the skin of healthy control animals. These results clearly indicated that Langerhans cells, dendritic cells and other MHC class II$^+$ cells are active participants in feline allergic skin disease. In the present study, MHC class II expression was associated with inflammatory cells morphologically resembling dermal dendritic cells and macrophages, and epidermal Langerhans cells. This is consistent with an earlier report, which described feline MHC class II expression by B cells, monocytes, macrophages, T cells and Langerhans cells (Rideout *et al.*, 1990). In the sections analysed in the present study, MHC class II expression was evident in lesional and non-lesional skin from cats with allergic skin disease, regardless of the type of clinical lesion. The fact that dendritic cells expressing MHC class II were usually associated with an infiltrate of CD3 lymphocytes echoed earlier reports suggesting that these cells participate in maintenance of the local immune response by presenting antigen to T lymphocytes. This emphasizes their potential role in the mechanism of lesion formation in feline allergic skin disease.

The T cells present in the skin of cats with allergic skin disease have received only limited study (Roosje *et al.*, 1998, 2002). A predominant increase of CD4$^+$ T cells and a CD4$^+$/CD8$^+$ ratio of 3.9 was found in "miliary" (papulo-crusting) dermatitis lesions of allergic cats (Roosje *et al.*, 1998). In non-lesional skin a significant increase in CD4$^+$ T-cells was found, while in the skin of healthy control cats only one or two CD4$^+$ T-cells and no CD8$^+$ cells were found. These results are in keeping with both human and canine studies (Bos *et al.*, 1987; Thepen *et al.*, 1996; Sinke *et al.*, 1997). The use of the human CD3 polyclonal antibody as a pan T lymphocyte marker has been described in numerous feline studies (Perez *et al.*, 1999; Waly *et al.*, 2001, 2005; Robinson *et al.*, 2002; Harley *et al.*, 2003; Day *et al.*, 2004). The present study confirmed that the lymphocytic infiltrate in the superficial dermis and in and around the hair follicles consisted of CD3$^+$ T cells. In lesional skin samples from all types of clinical lesion, moderate numbers of CD3$^+$ cells were found. It was noteworthy that only a few CD3$^+$ cells were present in sections of both ventral alopecic lesions and non-lesional samples. Very few CD3$^+$ lymphocytes were identified in normal healthy skin. This was in keeping with a study by Harley *et al.* (2003), who described only a sparse cellular infiltrate of CD3$^+$ T cells, either as occasional isolated cells or as subepithelial clusters in close proximity to MHC class II$^+$ cells, in the oral mucosal tissue of healthy cats. As ventral alopecic lesions closely resembled normal feline skin, it could be speculated that these either represented an early stage in the allergic skin disease or that they formed part of an altogether different clinical syndrome.

Mast cell numbers in the caudal aspect of the feline pinna were reported to be significantly higher than in other body sites of normal cats (Foster, 1994). Beadleston *et al.* (1997) confirmed this observation but found that mast cells in normal feline skin appeared to be significantly less numerous when stained with toluidine blue than with either tryptase or chymase enzymatic stain.

Roosje *et al.* (2004a) reported that significantly fewer mast cells labelled for tryptase expression in lesional and non-lesional feline skin compared with chymase

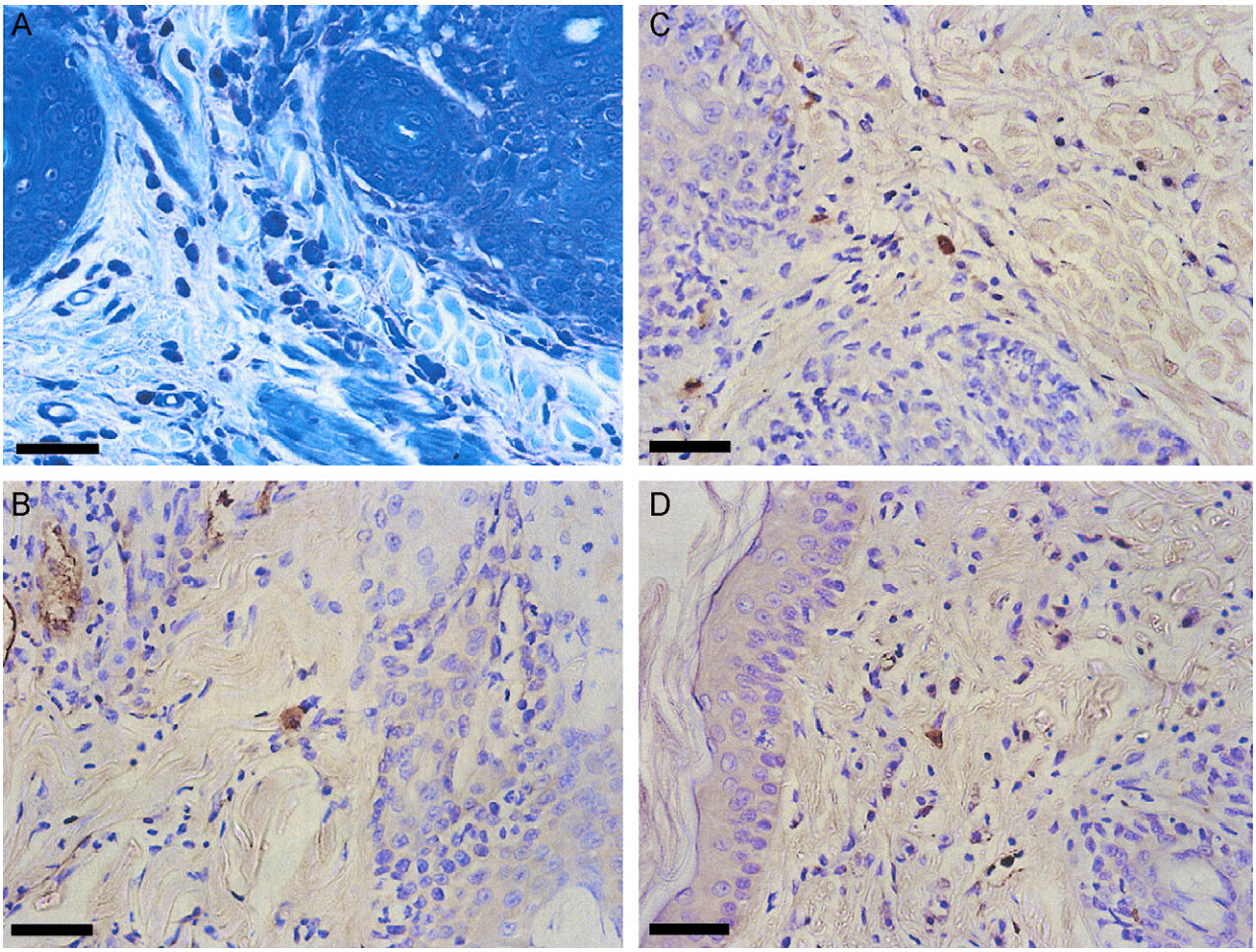

Fig. 5A–D. Allergic skin disease. (A) Skin section showing cell infiltrate in the superficial dermis and perifollicular area. Mast cells are identified by their characteristic morphology and the presence of dark purple-staining granules. Toluidine blue. Bar, 75 μm. (B) Skin section showing evidence of folliculitis and perifolliculitis with a few immunoreactive IgG-bearing plasma cells. IHC. Bar, 75 μm. (C) Skin section showing perifollicular cell infiltrate with individual immunoreactive IgA-bearing plasma cells. IHC. Bar, 75 μm. (D) Skin section showing diffuse cell infiltrate in the superficial dermis and perifollicular area with individual immunoreactive IgM-bearing plasma cells. IHC. Bar, 75 μm.

expression. In the same study quantification of mast cell numbers by means of astra blue staining revealed significantly higher numbers in lesional skin of cats with allergic miliary dermatitis than in control cats. The biopsy site in that study did not appear to affect numbers of mast cells (and eosinophils). This was in contrast to previous reports of normal feline skin tissue (Foster, 1994; Beadleston *et al.*, 1997). It would appear that mast cell proteases can modulate inflammation, but their role in the pathogenesis of human atopic dermatitis remains to be clarified (reviewed by Welle, 1997). Unfortunately, because both enzyme-immunohistochemistry and double labelling were beyond the scope of the present study, feline mast cell subtypes were not determined. The toluidine blue staining method, although producing only different degrees of contrast, gave a useful general impression of the mast cell distribution in the different skin compartments studied. Statistical analysis was not possible due to the small sample size for each pattern; mast cells appeared to be present in similar numbers in healthy and allergic feline skin samples, regardless of the type of clinical lesion sampled. In the epidermis of allergic skin, however, only occasional mast cells were seen, while these cells were completely absent from the epidermis of normal skin, thus confirming previous findings (Scott, 1990). It would seem clear that mast cells are prominent in normal feline skin and in the cellular infiltrate of feline allergic dermatitis.

The antibody recognizing the myelo-monocytic marker MAC387 labelled only a few monocytes and macrophages in the four skin compartments. This antibody reacts with calprotectin, which is expressed by circulating neutrophils, monocytes, reactive tissue macrophages and tissue eosinophils (Brandtzaeg *et al.*, 1992). Robinson *et al.* (2002) reported that calprotectin

was strongly expressed in the epidermis and follicular epithelium in skin biopsy samples from cats infected experimentally with *Microsporum canis*, but was not found in healthy feline skin. This finding was confirmed by the present study, in which no MAC387$^+$ cells were found in normal skin tissue. Calprotectin is also expressed by reactive epidermis, as occasionally noted in lesional tissues in the present study. In contrast, eosinophils were frequently immunolabelled for calprotectin in lesional skin; this accords with previous reports, in which eosinophils were consistently demonstrated in cats with allergic dermatitis but not in the skin of healthy control cats (Roosje *et al.*, 2004a).

In this work, an attempt was made to assess the entire tissue area available in each skin biopsy sample. Although each immunohistochemical marker was assessed in four separate skin compartments, the scoring system employed was limited by its subjectivity. This could have been improved by actually counting the numbers of each cell type, but in any event the low number of cases for each histopathological pattern precluded statistical analysis. The definition of these areas for counting in non-homogeneous tissue such as skin is problematic, and may have been further complicated by the variety of clinical lesions present in cats with allergic skin disease. The lesions vary less in human atopic dermatitis, being generally defined by only two stages, acute and chronic (Hamid *et al.*, 1994; Leung, 1995; Toda *et al.*, 2003). In dogs, slightly more variation occurs; for instance, one report classified lesions as acute, subacute or chronic (Olivry *et al.*, 1999), while another distinguished only a lesional and non-lesional group (Nuttall *et al.*, 2002). In cats, a standardized method of classifying biopsy samples from skin lesions in allergic skin disease has yet to be determined. Roosje *et al.* (2004b) adapted for use in cats the atopy patch test methodology, which has been successfully used in human and canine models (Thepen *et al.*, 1996; Marsella *et al.*, 2006; Olivry *et al.*, 2006). Macroscopically positive patch test reactions were induced; these showed cellular infiltration similar to that described in the skin of cats with spontaneously arising atopic disease.

In conclusion, the present study supported previous observations that both T cells and antigen-presenting cells are important in the immunopathogenesis of feline allergic skin disease. Further studies will be required to extend these observations and provide more detailed phenotypic analysis of these infiltrating cells. At present it is difficult to propose that feline atopic dermatitis has an immunopathogenesis based on the production of allergen-specific IgE as regulated by the Th2 subset of CD4$^+$ T cells. Atopic cats do not have significantly higher concentrations of allergen-specific IgE than normal cats (Taglinger *et al.*, 2005) and there is no skewed Th2-associated cytokine gene expression within the lesional skin of atopic cats (Taglinger *et al.*, 2004). It will require concerted effort to unravel the immunological mechanisms underlying this enigmatic feline skin disease.

Acknowledgments

Normal cat serum was kindly donated by Professor T.J. Gruffydd-Jones. The Histopathology Laboratory of the Division of Veterinary Pathology, Infection and Immunity, of the University of Bristol is acknowledged for preparation of skin sections for routine staining and immunohistochemistry. This study was supported in part by the RCVS Trust Fund West Scholarship, the Kalis Bequest from the University of Bristol, and the Pet Plan Charitable Trust.

References

Allam, J. P. and Novak, N. (2006). The pathophysiology of atopic eczema. *Clinical and Experimental Dermatology*, **31**, 89–93.

Bardagi, M., Fondati, A., Fondevila, D. and Ferrer, L. (2003). Ultrastructural study of cutaneous lesions in feline eosinophilic granuloma complex. *Veterinary Dermatology*, **14**, 297–303.

Beadleston, D. L., Roosje, P. J. and Goldschmidt, M. H. (1997). Chymase and tryptase staining of normal feline skin and of feline cutaneous mast cell tumors. *Veterinary Allergy and Clinical Immunology*, **5**, 54–58.

Bos, J. D., Zonneveld, I., Das, P. K., Krieg, S. R., Vanderloos, C. M. and Kapsenberg, M. L. (1987). The skin immune system (Sis)—distribution and immunophenotype of lymphocyte subpopulations in normal human skin. *Journal of Investigative Dermatology*, **88**, 569–573.

Brandtzaeg, P., Dale, I. and Gabrielson, T. O. (1992). The leukocyte protein-L1 (Calprotectin)—usefulness as an immunohistochemical marker antigen and putative biological function. *Histopathology*, **21**, 191–196.

Day, M. J. (1996). Expression of major histocompatibility complex class II molecules by dermal inflammatory cells, epidermal Langerhans cells and keratinocytes in canine dermatological disease. *Journal of Comparative Pathology*, **115**, 317–326.

Day, M. J., Henderson, S. M., Belshaw, Z. and Bacon, N. J. (2004). An immunohistochemical investigation of 18 cases of feline nasal lymphoma. *Journal of Comparative Pathology*, **130**, 152–161.

Fondati, A., Fondevila, D. and Ferrer, L. (2001). Histopathological study of feline eosinophilic dermatoses. *Veterinary Dermatology*, **12**, 333–338.

Foster, A. P. (1994). A study of the number and distribution of cutaneous mast cells in cats with diseases not affecting the skin. *Veterinary Dermatology*, **5**, 17–20.

Foster, A.P. and Roosje, P.J. (2005). Update on feline immunoglobulin E (IgE) and diagnostic recommendations for atopy. In: *Consultations in Feline Internal Medicine*, Vol. 5, J.R. August, Ed., Elsevier Saunders, St Louis, pp. 229–238.

Gross, T.L., Ihrke, P.J., Walder, E.J. and Affolter, V.K. (2005). *Skin Diseases of the Dog and Cat, Clinical and Histopathologic Diagnosis*, 2nd Edit., Blackwell Publishing, Oxford, pp. 109–111; 118–121; 352–358.

Gross, T. L., Kwochka, K. W. and Kunkle, G. A. (1986). Correlation of histologic and immunologic findings in cats with miliary dermatitis. *Journal of the American Veterinary Medical Association*, **189**, 1322–1325.

Halliwell, R. E. W. (1997). Efficacy of hyposensitization in feline allergic diseases based upon results of in vitro testing for allergen-specific immunoglobulin E. *Journal of the American Animal Hospital Association*, **33**, 282–288.

Hamid, Q., Boguniewicz, M. and Leung, D. Y. (1994). Differential in situ cytokine gene expression in acute versus chronic atopic dermatitis. *Journal of Clinical Investigation*, **94**, 870–876.

Harley, R., Gruffydd-Jones, T. J. and Day, M. J. (2003). Characterization of immune cell populations in oral mucosal tissue of healthy adult cats. *Journal of Comparative Pathology*, **128**, 146–155.

Leung, D. Y. (2000). Atopic dermatitis: new insights and opportunities for therapeutic intervention. *Journal of Allergy and Clinical Immunology*, **105**, 860–876.

Leung, D. Y., Schneeberger, E. E., Siraganian, R. P., Geha, R. S. and Bhan, A. K. (1987). The presence of IgE on macrophages and dendritic cells infiltrating into the skin lesion of atopic dermatitis. *Clinical Immunology and Immunopathology*, **42**, 328–337.

Leung, D. Y. M. (1995). Atopic dermatitis—the skin as a window into the pathogenesis of chronic allergic diseases. *Journal of Allergy and Clinical Immunology*, **96**, 302–318.

Marsella, R. and Olivry, T. (2003). Animal models of atopic dermatitis. *Clinics in Dermatology*, **21**, 122–133.

Marsella, R., Olivry, T. and Maeda, S. (2006). Cellular and cytokine kinetics after epicutaneous allergen challenge (atopy patch testing) with house dust mites in high-IgE beagles. *Veterinary Dermatology*, **17**, 111–120.

Nuttall, T. J., Knight, P. A., McAleese, S. M., Lamb, J. R. and Hill, P. B. (2002). Expression of Th1, Th2 and immunosuppressive cytokine gene transcripts in canine atopic dermatitis. *Clinical and Experimental Allergy*, **32**, 789–795.

Olivry, T., Dean, G. A., Tompkins, M. B., Dow, J. L. and Moore, P. F. (1999). Toward a canine model of atopic dermatitis: amplification of cytokine-gene transcripts in the skin of atopic dogs. *Experimental Dermatology*, **8**, 204–211.

Olivry, T., Deangelo, K. B., Dunston, S. M., Clarke, K. B. and McCall, C. A. (2006). Patch testing of experimentally sensitized beagle dogs: development of a model for skin lesions of atopic dermatitis. *Veterinary Dermatology*, **17**, 95–102.

Olivry, T. and Hill, P. B. (2001). The ACVD Taskforce on canine atopic dermatitis (XVIII): histopathology of skin lesions. *Veterinary Immunology and Immunopathology*, **81**, 305–309.

Olivry, T., Naydan, D. K. and Moore, P. F. (1997). Characterization of the cutaneous inflammatory infiltrate in canine atopic dermatitis. *American Journal of Dermatopathology*, **19**, 477–486.

Perez, J., Day, M. J., Matrin, M. P., Gonzalez, S. and Mozos, E. (1999). Immunohistochemical study of the inflammatory infiltrate associated with feline cutaneous squamous cell carcinomas and precancerous lesions (actinic keratosis). *Veterinary Immunology and Immunopathology*, **69**, 33–46.

Rideout, B. A., Moore, P. F. and Pedersen, N. C. (1990). Distribution of MHC class II antigens in feline tissues and peripheral blood. *Tissue Antigens*, **36**, 221–227.

Robinson, A., Sparkes, A.H. and Day, M.J. (2002). Local cell recruitment and cytokine production following intradermal injection with *Microsporum canis* antigen in cats. In: *Advances in Veterinary Dermatology*, Vol. 4, K.L. Thoday, C.S. Foil and R. Bond, Eds, Blackwell Science, Oxford, pp. 100–108.

Roosje, P. J., Dean, G. A., Willemse, T., Rutten, V. and Thepen, T. (2002). Interleukin 4-producing CD4+ T cells in the skin of cats with allergic dermatitis. *Veterinary Pathology*, **39**, 228–233.

Roosje, P. J., Koeman, J. P., Thepen, T. and Willemse, T. (2004a). Mast cells and eosinophils in feline allergic dermatitis: a qualitative and quantitative analysis. *Journal of Comparative Pathology*, **131**, 61–69.

Roosje, P. J., Thepen, T., Rutten, V. P., Van Den Brom, W. E., Bruijnzeel-Koomen, C. A. and Willemse, T. (2004b). Immunophenotyping of the cutaneous cellular infiltrate after atopy patch testing in cats with atopic dermatitis. *Veterinary Immunology and Immunopathology*, **101**, 143–151.

Roosje, P. J., van Kooten, P. J., Thepen, T., Bihari, I. C., Rutten, V. P., Koeman, P. J. and Willemse, T. (1998). Increased numbers of CD4+ and CD8+ T cells in lesional skin of cats with allergic dermatitis. *Veterinary Pathology*, **35**, 268–273.

Roosje, P. J., Whitaker-Menezes, D., Goldschmidt, M. H., Moore, P. F., Willemse, T. and Murphy, G. F. (1997). Feline atopic dermatitis. A model for Langerhans cell participation in disease pathogenesis. *American Journal of Pathology*, **151**, 927–932.

Saint-Andre Marchal, I., Dezutter-Dambuyant, C., Martin, J. P., Woo, J. C., Moore, P. F., Magnol, J. P., Schmitt, D. and Marchal, T. (1997a). Quantitative assessment of feline epidermal Langerhans cells. *British Journal of Dermatology*, **136**, 961–965.

Saint-Andre Marchal, I., Dezutter-Dambuyant, C., Willett, B. J., Woo, J. C., Moore, P. F., Magnol, J. P., Schmitt, D. and Marchal, T. (1997b). Immunophenotypic characterization of feline Langerhans cells. *Veterinary Immunology and Immunopathology*, **58**, 1–16.

Scott, D. W. (1984). Feline dermatology 1979–1982—introspective retrospections. *Journal of the American Animal Hospital Association*, **20**, 537–564.

Scott, D. W. (1990). Epidermal mast cells in the cat. *Veterinary Dermatology*, **1**, 65–69.

Scott, D.W., Miller, W.H. and Griffin, C.E. (2001). Skin immune system and allergic diseases. In: *Muller and Kirk's Small Animal Dermatology*, 6th Edit., W.B. Saunders, Philadelphia, pp. 543–666.

Sinke, J. D., Thepen, T., Bihari, I. C., Rutten, V. P. M. G. and Willemse, T. (1997). Immunophenotyping of skin-infiltrating

T-cell subsets in dogs with atopic dermatitis. *Veterinary Immunology and Immunopathology*, **57**, 13–23.

Soter, N. A. (1989). Morphology of atopic eczema. *Allergy*, **44** (Suppl. 9), 16–19.

Taglinger, K., Helps, C. R., Day, M. J. and Foster, A. P. (2005). Measurement of serum IgE (IgE) specific for house dust mite antigens in normal cats and cats with allergic skin disease. *Veterinary Immunology and Immunopathology*, **105**, 85–93.

Taglinger, K., Nguyen van, N., Helps, C.R., Day, M.J. and Foster, A.P. (2004). Quantitative real-time RT-PCR for the measurement of feline cytokine mRNA expression in skin of normal cats and cats with allergic skin disease. *Veterinary Dermatology*, **15** (Suppl. 1), Abstract, 31.

Thepen, T., Langeveld-Wildschut, E. G., Bihari, I. C., van Wichen, D. F., van Reijsen, F. C., Mudde, G. C. and Bruijnzeel-Koomen, C. A. (1996). Biphasic response against aeroallergen in atopic dermatitis showing a switch from an initial TH2 response to a TH1 response in situ: an immunocytochemical study. *Journal of Allergy and Clinical Immunology*, **97**, 828–837.

Toda, M., Leung, D. Y., Molet, S., Boguniewicz, M., Taha, R., Christodoulopoulos, P., Fukuda, T., Elias, J. A. and Hamid, Q. A. (2003). Polarized in vivo expression of IL-11 and IL-17 between acute and chronic skin lesions. *Journal of Allergy and Clinical Immunology*, **111**, 875–881.

Van der Heijden, F. L., Wierenga, E. A., Bos, J. D. and Kapsenberg, M. L. (1991). High frequency of IL-4-producing CD4+ allergen-specific T lymphocytes in atopic dermatitis lesional skin. *Journal of Investigative Dermatology*, **97**, 389–394.

Waly, N., Gruffydd-Jones, T. J., Stokes, C. R. and Day, M. J. (2001). The distribution of leucocyte subsets in the small intestine of healthy cats. *Journal of Comparative Pathology*, **124**, 172–182.

Waly, N. E., Gruffydd-Jones, T. J., Stokes, C. R. and Day, M. J. (2005). Immunohistochemical diagnosis of alimentary lymphomas and severe intestinal inflammation in cats. *Journal of Comparative Pathology*, **133**, 253–260.

Welle, M. (1997). Development, significance, and heterogeneity of mast cells with particular regard to the mast cell-specific proteases, chymase and tryptase. *Journal of Leukocyte Biology*, **61**, 233–245.

Welle, M. M., Olivry, T., Grimm, S. and Suter, M. (1999). Mast cell density and subtypes in the skin of dogs with atopic dermatitis. *Journal of Comparative Pathology*, **120**, 187–197.

Werfel, T., Morita, A., Grewe, M., Renz, H., Wahn, U., Krutmann, J. and Kapp, A. (1996). Allergen specificity of skin-infiltrating T cells is not restricted to a type-2 cytokine pattern in chronic skin lesions of atopic dermatitis. *Journal of Investigative Dermatology*, **107**, 871–876.

Yager, J.A. and Wilcock, B.P. (1994). *Color Atlas and Text of Surgical Pathology of the Dog and Cat: Dermatopathology and Skin Tumors*, Vol. 1, Wolfe Publishing, London, p. 148.

[*Received, March 15th, 2007*
Accepted, July 16th, 2007]

Please cite this article as: Taglinger, K., et al. Characterization of Inflammatory Cell Infiltration in Feline Allergic Skin Disease. *Journal of Comparative Pathology*. (2007), doi:10.1016/j.jcpa.2007.07.001