Photoallergic Erythroderma due to Doxycycline Therapy of Erythema Chronicum Migrans

Alexander Vasilevic Kuznetsov[1,2,3], Peter Weisenseel[1,4], Michael Josef Flaig[1], Thomas Ruzicka[1] and Joerg Christoph Prinz[1]
Departments of Dermatology and Allergology, [1]Ludwig-Maximilian University, Munich, [2]Bayreuth Teaching Hospital, Fridrich-Alexander University, Bayreuth, Germany, [3]Cancer Research UK Cambridge Research Institute, University of Cambridge, Robinson Way, Cambridge CB2 0RE, UK, [4]Therapeutic Area Internal Medicine & Pain, Janssen-Cilag GmbH, Neuss, Germany. E-mail: alexander.kuznetsov@med.uni-muenchen.de
Accepted February 12, 2011.

Acute phototoxic dermatitis and phototoxic onycholysis on sun exposure are well-known side-effects of doxycycline administration (1, 2). In contrast, little information has been published about photoallergic skin reactions due to doxycycline, and they are not mentioned in recent literature reviews (3, 4) on drug photosensitivity. A single case report, describing a patient who developed photoallergic eczema only on sun-exposed skin areas 3 days after initiation of doxycycline therapy for acne vulgaris, was published (5).

To the best of our knowledge we describe here for the first time an erythrodermic photoallergic drug reaction due to doxycycline administration for erythema chronicum migrans (ECM).

CASE REPORT

A 70-year-old female patient (skin phototype III) presented with clinical and histopathological picture of ECM (superficial perivascular lymphocytic infiltrate and plasma cells; negative PCR amplification of *B. burgdorferi p66* gene fragment (6)), slowly growing (~12 months) on the medial part of the right breast. IgM and IgG *B. burgdorferi* ELISA was repetitively negative, no signs of neurological, cardiac or musculoskeletal involvements related to borreliosis were found.

Doxycycline HCl 100 mg twice daily was prescribed for 20 days (7), and UV-protection was explained in detail to the patient before onset of the therapy. Doxycycline had been used by the patient approximately one year previously with no adverse events. The patients' daily medication at that time included lisinopril plus hydrochlorothiazide (30 mg/12.5 mg), amlodipine (5 mg), bisoprolol (5 mg), moxonidin HCl (0.2 mg), acetylsalicylic acid (100 mg), simvastatin (10 mg), and metformin (1000 mg). This regimen had not changed for the last 3 years, and was well tolerated.

The weather in Munich at start of doxycycline therapy was spring sunshine. Five days after therapy onset, erythema and itching of the skin on the trunk, upper and lower limbs occurred. On examination, the skin showed relatively sharply demarked palpable erythemata, which were accentuated in previously un-tanned skin areas, e.g. on the proximal and medial parts of the upper and lower limbs, and on the trunk (excluding the skin areas covered by the bra and pants) (Fig. 1A). Previously tanned areas (face, neck and dorsal parts of hands and forearms) and the skin covered by the bra and pants, did not show any reaction. Because of this distribution, we assumed that the patient had been sun-exposed in a swimsuit, but she denied this. She showed us the light summer clothes (shirts with short sleeves and light grey trousers) that she had worn when the skin reaction had developed. The clothes were made of thin polyester cloth, and were obviously not able to sufficiently prevent UV radiation reaching the skin.

Doxycycline therapy was discontinued and replaced by cefuroxime 250 mg (twice daily) (7), for 20 days. Prednicarbate cream (twice daily), and dimethindene maleate 4 mg (once daily), were prescribed to alleviate the skin inflammation and reduce itching. Strict avoidance of sunlight, and protection with highly effective sun creams with SPF 50 were recommended.

Nevertheless, the skin reaction progressed, becoming confluent, and scaling within the following week, affecting the breast and buttocks, neck, face, and the distal parts of the upper extremities (Fig. 1B). Approximately 80% of the body surface area was finally affected, forming a clinical picture of developing erythroderma.

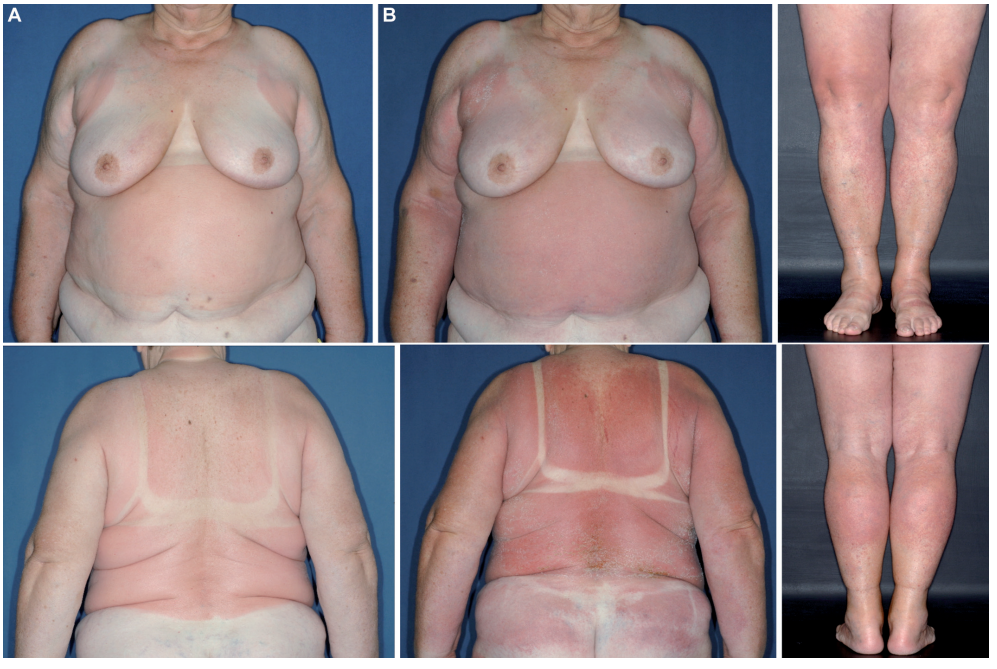

Fig. 1. Development of erythroderma. (A) Five days after onset of doxycycline treatment and sun exposure: previously tanned (upper neck, dorsal areas of hands and forearms), and dressed (bra, pants) skin parts did not show any reaction. (B) Seven days after cessation of doxycycline treatment approximately 80% of the body surface area was affected.

© 2011 The Authors. doi: 10.2340/00015555-1161
Journal Compilation © 2011 Acta Dermato-Venereologica. ISSN 0001-5555

Anti-inflammatory and anti-pruritic therapies were changed to high-potency corticosteroid, diflucortolone-21-valerate cream (twice daily), and fexofenadine HCl 120 mg (twice daily). Systemic corticosteroid treatment was avoided as a first-line option, because patient had hypertension and diabetes mellitus.

A skin biopsy from the back taken during 24 h after onset of the reaction revealed the histological pattern of acute allergic contact dermatitis: epidermal parakeratosis, partial serum emplacement, and discrete spongiosis. Perivascular and diffuse lymphohistiocytic infiltration with many eosinophilic granulocytes and few neutrophils were found in the dermis; periodic acid-Schiff (PAS) staining was not informative (Fig. 2).

After 10 days of intensive treatment, the ECM and erythrodermic skin reaction healed without hyperpigmentation. The photosensitivity test with UVA (320–400 nm, Waldman UV test, Germany), and UVB (290–320 nm) performed on the 20th day after complete healing of the skin rash showed normal photosensitivity in the UVA spectrum after 24 h (minimal tanning dose (MTD)=14 J/cm^2), but increased photosensitivity in the UVB spectrum, with a minimal erythematic dose (MED)=0.2 J/cm^2), which normally corresponds to 0.3 J/cm^2 in skin phototype II–III (8) and according to internal normal range of skin UVA/UVB sensitivity of the Department of Dermatology, University of Munich. The photopatch test with 8 mm Finn chambers (9) with doxycycline HCl in dilution (50 mg/ml, 10 mg/ml, 1.0 mg/ml in petrolatum) followed by UVA irradiation (5 J/cm^2) after 24 h of test substance occlusion revealed a delayed positive reaction forming very small (1 mm) erythematous papules after 168 h (7 days) in the tested areas of 50 mg/ml and 10 mg/ml doxycycline HCl. The area with 1.0 mg/ml doxycycline HCl stayed negative. The patch test was positive with bufexamac and colophonium after 48 h. Three doxycycline non-exposed and two exposed non-allergic volunteers were tested using the same procedure, after obtaining informed consent, with no skin reactions during 7 days of follow-up.

DISCUSSION

The diagnosis of photoallergic erythroderma due to doxycycline HCl was made according to the follow criteria (4, 10): delayed onset of skin reaction after 5 days of drug administration (usually hours or days); "crescendo" development of eczematous skin reaction; spreading of the skin inflammation over the non-UV-exposed skin of breast and gluteal regions; histopathological picture of an acute contact dermatitis; absence of a post-inflammatory hyperpigmentation after healing; substance dose-independent and delayed positive photopatch test with doxycycline in dilution compared with 5 photopatch test negative control individuals.

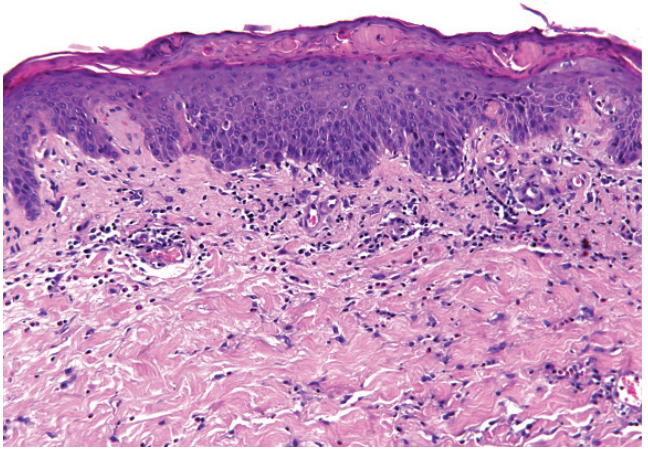

Fig. 2. Histopathology of a skin biopsy from the back: acute contact dermatitis with a serocrust, parakeratosis, spongiosis, perivascular and interstitial lymphohistiocytic infiltration with many eosinophilic granulocytes.

The precise mechanism of doxycycline photoallergy is not fully understood. The photosensitization (phototoxicity or photoallergy) is usually caused by UVA radiation, because UVA penetrates deeper into the skin and most of the offending drugs absorb UV radiation in the UVA spectrum of 320–400 nm, e.g. tetracycline at 289–342 nm (11). Following UV irradiation and photon absorption, drug molecules in an excited energy state cause chemical reactions when they return to their energetic base level, resulting in the synthesis of photoproducts that act as a haptens or antigens, generating an allergic reaction (10). The fact that tanned skin blocks or absorbs part of the UV irradiation, or is immunologically suppressed, could explain the preliminary failure of an inflammatory skin reaction in the tanned areas of skin in our patient.

The UVB photosensitivity in our patient can be explained by her medication, i.e. hydrochlorothiazide, simvastatin and lisinopril, which are potential photosensitizers, usually in phototoxic reactions (3, 4). Because they were well tolerated for many years, and no reaction occurred after UV sensitivity and photopatch tests under continuous drug use, it is unlikely that they are causative for the erythroderma. The negative photopatch test with 1.0 mg/ml diluted doxycycline might be caused by a too low concentration or an altered epidermal penetration during the test (12).

If *B. burgdorferi* skin infection manifests as an ECM it is possible that the clinical diagnosis cannot be confirmed by laboratory tests such as ELISA (negative in early ECM in 51–67%) or *B. burgdorferi* PCR in skin lesions of ECM (median sensitivity in meta-analysis 73%) (13). Histopathological examination of the lesion with detection of a superficial perivascular lymphocytic infiltrate with variable numbers of plasma cells can be helpful, but is by far not pathognomonic.

The differential diagnosis of photoallergic vs. phototoxic skin reactions is not always easy, but is enormously important for a patient because the potency of allergic reaction is *dose-independent*. Taking a low amount of the drug and being sensitized, even weak UV irradiation may be sufficient to cause a severe generalized or erythrodermic skin reaction.

ACKNOWLEDGEMENTS

The authors thank Dr Annett Walker, MD, and Ms Dagmar Dick, for photopatch testing. This case was presented at the 45th Meeting of the German Dermatologic Society (DDG) in Dresden, Germany, April 29th – May 2nd, 2009 (Abstract FV09/07).

REFERENCES

1. Frost P, Weinstein GD, Gomez EC. Phototoxic potential of minocycline and doxycycline. Arch Dermatol 1972; 105: 681–683.
2. Frank SB, Cohen HJ, Minkin W. Photo-onycholysis due to tetracycline hydrochloride and doxycycline. Arch Dermatol 1971; 103: 520–521.
3. Moore DE. Drug-induced cutaneous photosensitivity: incidence, mechanism, prevention and management. Drug Safety 2002; 25: 345–372.
4. Stein KR, Scheinfeld NS. Drug-induced photoallergic and phototoxic reactions. Expert Opin Drug Saf 2007; 6: 1–13.
5. Tanaka N, Kawada A, Ohnishi Y, Hiruma M, Tajima S, Akiyama M, et al. Photosensitivity due to doxycycline hydrochloride with an unusual flare. Contact Dermatitis 1997; 37: 93–94.
6. Wienecke R, Neubert U, Volkenandt M. Molecular detection of Borrelia burgdorferi in formalin-fixed, paraffin-embedded lesions of Lyme disease. J Cutan Pathol 1993; 20: 385–388.
7. Wormser GP, Dattwyler RJ, Shapiro ED, Halperin JJ, Steere AC, Klempner MS, et al. The clinical assessment, treatment, and prevention of Lyme disease, human granulocytic anaplasmosis, and babesiosis: clinical practice guidelines by the Infectious Diseases Society of America. Clin Infect Dis 2006; 43: 1089–1134.
8. Rietschel RL, Fowler JF. Photocontact dermatitis. In: Fisher's contact dermatitis. 5th edn, Lippincott Williams & Wilkins, Philadelphia, 2001: p. 397–411.
9. Bruynzeel DP, Ferguson J, Andersen K, Goncalo M, English J, Goossens A, et al. European Task-force for Photopatch Testing. Photopatch testing: a consensus methodology for Europe. J Eur Acad Dermatol Venereol 2004; 18: 679–682.
10. Palmer RY, White IR. Phototoxic and photoallergic reactions. In: Frosch PJ, Menne T, Lepoittevin J-P, editors. Contact dermatitis. 4th edn. Berlin: Springer Verlag, 2006: p. 309–317.
11. Ping-Kai H, Wai-Kwong F. Identification of tetracyclines by second-derivate ultraviolet spectrophotometry. Analyst 1991; 116: 751–752.
12. Wahlberg JE, Lindberg M. Patch testing. In: Frosch PJ, Menne T, Lepoittevin J-P, editors. Contact dermatitis. 4th edn. Berlin: Springer Verlag, 2006: p. 366–390.
13. Aguero-Rosenfeld M, Wang G, Schwartz I, Wormser GP. Diagnosis of Lyme borreliosis. Clin Microbiol Rev 2005; 18: 485–509.