Inflammation (© 2019)
DOI: 10.1007/s10753-019-01069-z

ORIGINAL ARTICLE

Liposomal Amphotericin B Fosters the Corticosteroids' Anti-inflammatory Effect on Murine Allergic Bronchopulmonary Aspergillosis Model Airways

Chizu Fukushima,[1,2] Hiroto Matsuse,[3] Yasushi Obase,[1,4] Susumu Fukahori,[1] Tomoko Tsuchida,[1] Tetsuya Kawano,[1] Shigeru Kohno,[1] and Hiroshi Mukae[1]

Abstract—Fungus is an antigen for bronchial asthma causing allergic bronchopulmonary mycosis (ABPM). As a therapy other than corticosteroids, itraconazole (ITCZ) is known to suppress the allergic inflammation induced by *Aspergillus fumigatus* (Af). However, the efficacy of liposomal amphotericin B (LAMB) with/without corticosteroid on ABPM is unknown. Mice sensitized to *Dermatophagoides farinae* (Df) allergen were intranasally infected with Af (DfAf group). After the infection, corticosteroid (dexamethasone (Dex)) was administered for 5 days (DfAf/Dex group). The effects of ITCZ or LAMB with/without Dex were also evaluated. Pathologically, Dex and LAMB combination treatment decreased the allergic inflammation evidently. The bronchoalveolar lavage fluid (BALF) concentrations of IL-5, IL-13, and MIP-2 were significantly elevated in DfAf mice compared with control mice ($p < 0.05$, each). In DfAf mice, ITCZ and LAMB significantly decreased the elevation of MIP-2 ($p < 0.05$ *vs* the DfAf group). The addition of both Dex and LAMB suppressed the MIP-2 elevation in DfAf mice ($p < 0.05$ *vs* the Df/Af/Dex/LAMB group), but the addition of Dex and ITCZ did not (DfAf/Dex/ITCZ group). None of Dex, ITCZ, or LAMB decreased pulmonary IL-13 concentration. It was suggested that combination of antifungal drugs and corticosteroid enhanced the suppressing effect of airway inflammations. This finding will give a hope for the treatment of severe fungus-related asthma.

KEY WORDS: allergic bronchopulmonary aspergillosis (ABPA); murine asthma model; *Dermatophagoides farinae* (Df); itraconazole (ITCZ); liposomal amphotericin B (LAMB).

INTRODUCTION

Allergic bronchopulmonary aspergillosis (ABPA) occurs in patients with asthma (1 to 5%) or cystic fibrosis (1 to 9%) [1, 2]. Typically, in atopic asthmatic patients who have sensitized with *Dermatophagoides farinae* (Df), *etc.* in advance, fungi (*e.g.*, *Aspergillus fumigatus* (Af)) infection and sensitization worsen their asthma [3, 4]. Af colonization in the airways of the asthmatic patients leads to IgE- and IgG-mediated immune responses and changes the disease milieu. Proteolytic enzymes and mycotoxins

[1] Department of Respiratory Medicine, Nagasaki University Graduate School of Biomedical Sciences, 1-7-1 Sakamoto, Nagasaki, 852-8501, Japan
[2] Clinical Research Center, Nagasaki University Hospital, Nagasaki, Japan
[3] Division of Respiratory Medicine, Department of Internal Medicine, Toho University Ohashi Medical Center, Tokyo, Japan
[4] To whom correspondence should be addressed at Department of Respiratory Medicine, Nagasaki University Graduate School of Biomedical Sciences, 1-7-1 Sakamoto, Nagasaki, 852-8501, Japan. E-mail: obaseya@nagasaki-u.ac.jp

0360-3997/19/0000-0001/0 © 2019 Springer Science+Business Media, LLC, part of Springer Nature

Published online: 08 August 2019

released by Af are reported to cause the Th2-mediated eosinophilic inflammations and/or IL-8-mediated neutrophilic inflammations [5] and result in recurrent respiratory symptoms (sputum plug, cough, *etc.*) and bronchial damages (central bronchiectasis, *etc.*). ABPA is the most common type of allergic bronchopulmonary mycosis (ABPM) caused by any fungi including *Candida*, *Penicillium*, and *Schizophyllum* species [6, 7]. Treatment of ABPA is aimed at controlling the bronchial inflammations and at preventing the irreversible bronchial injury. Systemic glucocorticoids are the main treatment of ABPA currently [8–11]. The benefit of oral itraconazole (ITCZ) has been shown in patients with ABPA [12, 13], and the additional ITCZ on glucocorticoids was also reported as useful for the disease control [14–16].

Our previous ABPA murine model had shown that Df allergen sensitization and Af infection induced both Th1-like and Th2-like responses [17]. This model also had shown that dexamethasone (Dex) decreased mainly IL-5 and IL-13 and ITCZ decreased MIP-2 in the BAL fluid [18]. Many of ABPM patients have adrenal insufficiency as a complication of systemic steroid [19, 20]. The 2016 Infectious Diseases Society of America (IDSA) guidelines on the treatment of aspergillosis recommend that therapy of ABPA should consist of a combination of glucocorticoids and ITCZ [21]. If any antifungal medications with few side effects are effective, it would be very helpful for the ABPA strategy [22, 23].

Liposomal amphotericin B (LAMB) has a drug delivery system (DDS) formulation and keeps the efficacy the same as amphotericin B with less side effects [24, 25]. If LAMB is useful for the treatment of ABPA compared with ITCZ, it can be a great alternative idea to control ABPM [26]. Utilizing our ABPA murine model, the present study compared the additional effects of LAMB and ITCZ on corticosteroids in Af-enhanced Df-sensitized allergic airway inflammation.

METHODS

Mice Preparation for Group Setting

Seven groups of mice ($n = 10$ to 15 for each group) were prepared (control, DfAf, DfAf/Dex, DfAf/ITCZ, DfAf/LAMB, DfAf/Dex/ITCZ, and DfAf/Dex/LAMB groups, as below; Fig. 1). Four-week-old female BALB/c mice (Charles River Japan Inc., Yokohama, Japan) were immunized twice intraperitoneally on days 1 and 14 with 0.5 mg of Df per mouse (LG-5339; Cosmo Bio, Tokyo, Japan) precipitated in aluminum hydroxide (Imject® Alum, Thermo Scientific Inc., IL). These mice were then challenged intranasally (i.n.) with 50 mcg/50 ml Df allergen on days 14, 16, and 18 (all groups except the control group) [27]. Following that, 5×10^6 of Af conidia were administered i.n. on days 19, 21, and 23 (as follows). 0.02 mg of dexamethasone (Sigma, St. Louis, Mo.) was injected subcutaneously from days 21 to 25 (DfAf/Dex, DfAf/Dex/ITCZ, and DfAf/Dex/LAMB groups). 0.1 mg of itraconazole (Itrizole®, Janssen Pharmaceutical K.K., Tokyo, Japan) was orally administered (DfAf/Dex/ITCZ and DfAf/ITCZ groups) or 7.2 mg of amphotericin B (AmBisome®, Sigma, St. Louis, MO) was aerosolized and inhaled (DfAf/LAMB, DfAf/Dex/LAMB groups) from days 21 to 25 (with or without Dex); on day 26, all mice were sacrificed. Bronchoalveolar lavage (BAL) fluid (BALF) and lung tissues were obtained from each group. BAL was conducted utilizing 1 ml of PBS in the immediate postmortem period, and the cytokine concentrations in homogenized lungs were measured as follows. The procedures were reviewed and approved by the Nagasaki University School of Medicine Committee on Animal Research (No. 0307170304).

Preparation of Af Conidia

Af was isolated from sputum of a patient with pulmonary aspergilloma and was subcultured on Sabouraud Dextrose Agar® (Becton Dickinson Inc., Cockeysville, MD) at 30 °C for 7 days. The conidia were then harvested with sterile saline containing 0.02% Tween 80® (Wako Pure Chemical Industries, Tokyo, Japan), counted in a hemocytometer, and diluted with phosphate-buffered saline (PBS) for intranasal challenge [17].

The Cell Differentiation in BALF, Lung Pathology, and the Cytokine Concentrations in Homogenized Lungs

Differential cell counts were performed using cytocentrifuged BALF stained with May-Grünwald-Giemsa. Formaldehyde fixative was gently infused through the lavage catheter set in the trachea. Resected lungs were fixed for an additional 24 h and embedded in paraffin. Sections (4 μm) were stained with hematoxylin and eosin (HE). Lung homogenates were prepared by homogenizing a freshly excised lung. Concentrations of IL-5, IL-13, and MIP-2 (murine cytokine corresponding to human IL-8) in the lung homogenate samples were measured using enzyme-

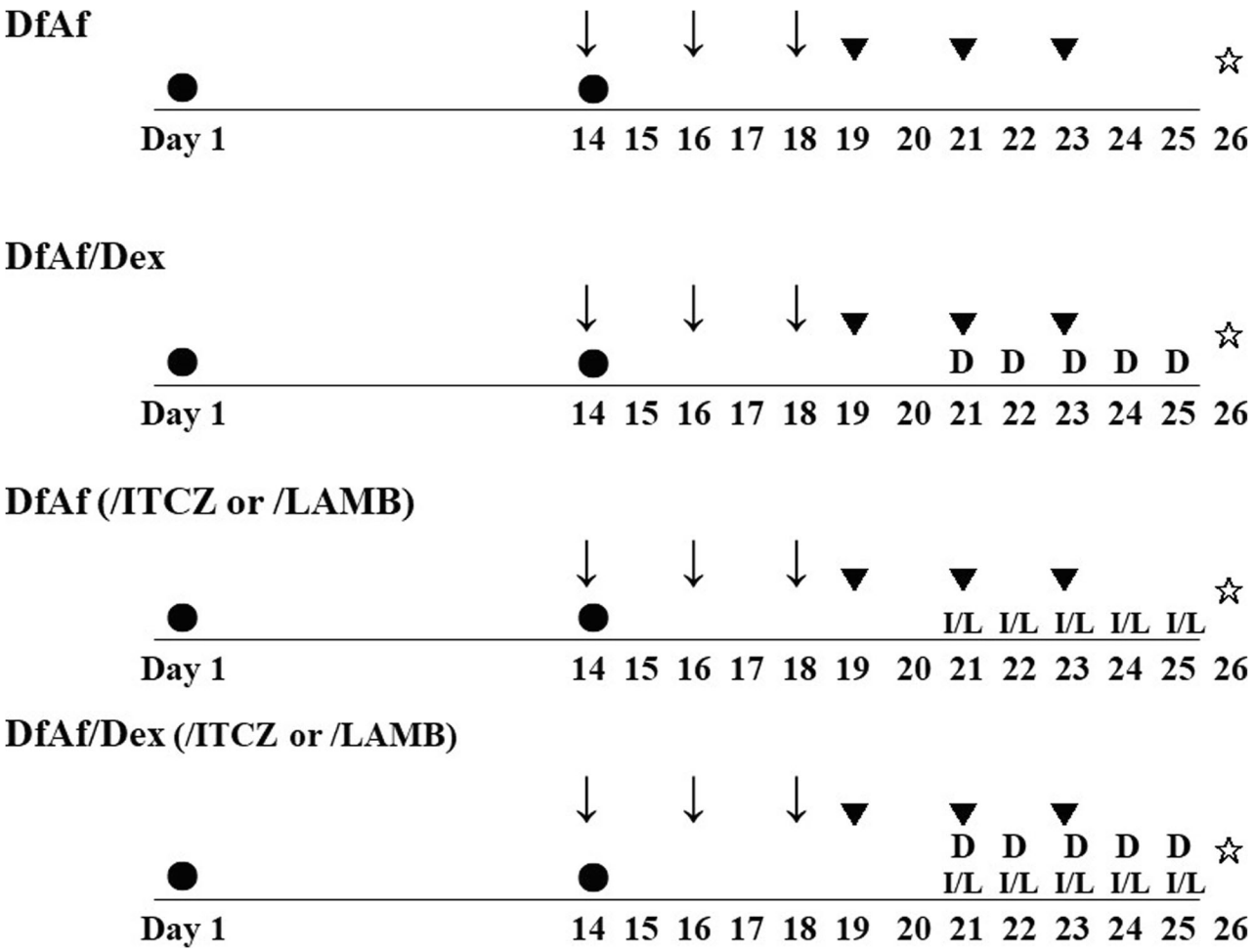

Fig. 1. All mice were immunized twice intraperitoneally on days 1 and 14 with 0.5 mg per mouse of Df precipitated in aluminum hydroxide (black circles), then challenged with 50 mcg/50 ml Df allergen (crude extract of the mite) intranasally (i.n.) on days 14, 16, and 18 (down arrows). Following that, 5×10^6 of Af conidia were administered i.n. on days 19, 21, and 23 (down arrowheads). Various drugs (Dex and ITCZ or LAMB) were administered from days 21 to 25 and ten groups of mice were prepared as follows: DfAf, no drug was administered; DfAf/Dex, 0.02 mg of dexamethasone (Sigma, St. Louis, Mo.; shown as D) was injected subcutaneously (s.c.); DfAf/ITCZ, 0.1 mg of itraconazole (Itrizole®, Janssen Pharmaceutical K.K., Tokyo, Japan) was orally administered (p.o.); DfAf/LAMB, 7.2 mg of amphotericin B (AmBisome®, Sigma, St. Louis, MO) was aerosolized and inhaled; DfAf/Dex/ITCZ, with Dex and ITCZ; DfAf/Dex/LAMB, with Dex and LAMB; and on day 26, all mice were sacrificed (white star). Bronchoalveolar lavage fluid (BALF) and lung tissues were obtained from each group.

linked immunosorbent assay using the methods described by the manufacturer (Endogen Inc., Woburn, MA.). Detection limits for IL-5, IL-13, and MIP-2 were 5 pg/ml, 1.5 pg/ml, and 5 pg/ml, respectively.

Statistical Analysis

Results are expressed as mean (standard error of mean (SEM)). Differences between groups were examined for statistical significance using repeated-measures ANOVA with a Bonferroni multiple comparison test. p values of < 0.05 were considered significant.

RESULTS

The Pulmonary Pathology Findings and the Cell Differentiation in BALF

Figure 2 shows some examples of the pulmonary pathology findings. Apparently, DfAf mice had severe airway inflammation with eosinophil and neutrophil infiltration and hypersecretion, and this inflammation was suppressed by Dex (DfAf/Dex). This suppression was enhanced by addition of LAMB (DfAf/Dex/LAMB) but not ITCZ (DfAf/Dex/ITCZ).

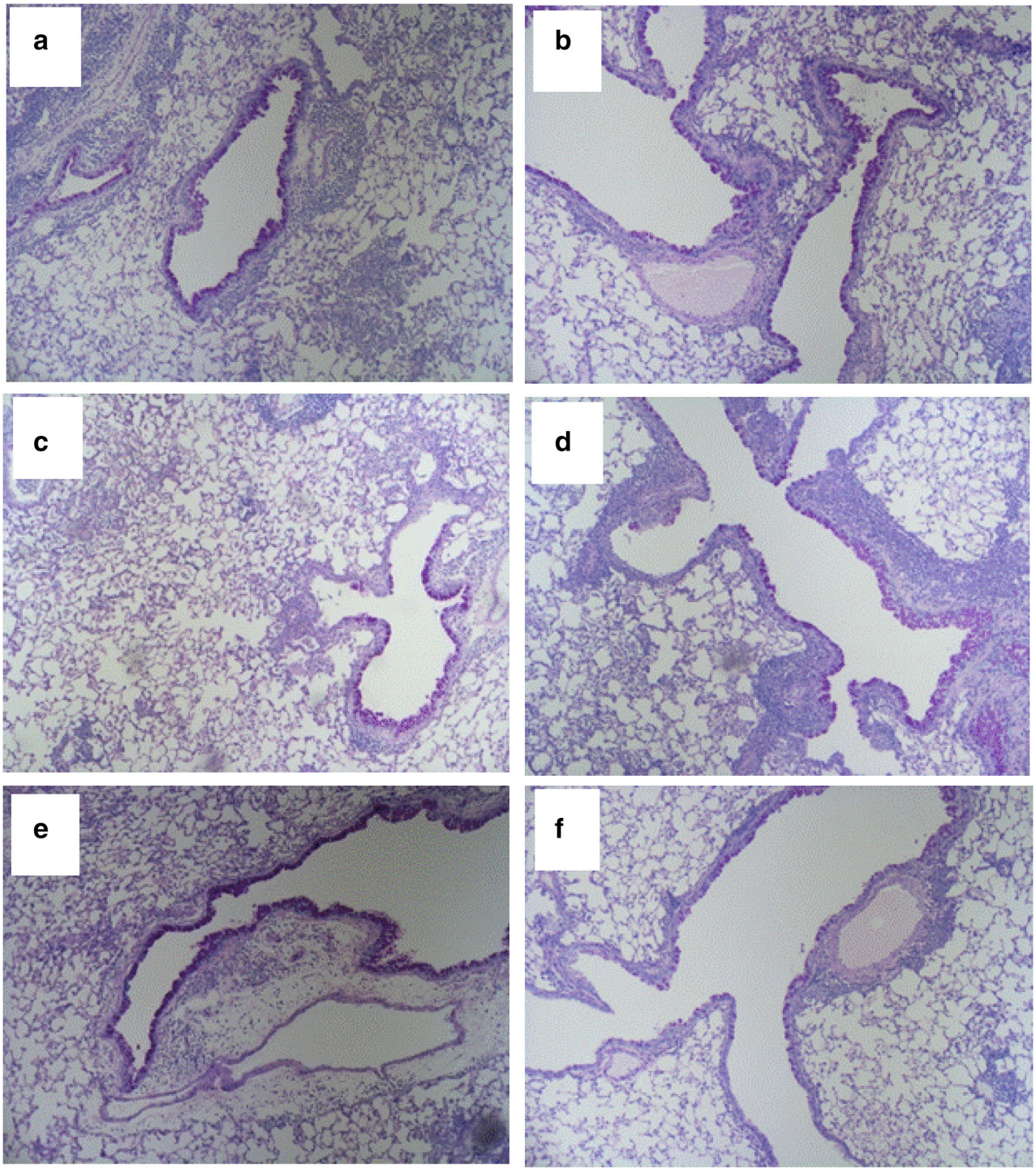

Fig. 2. Some examples of pulmonary pathology. **a** DfAf mice, DfAf mice had severe airway inflammation with eosinophil and neutrophil infiltration and hypersecretion. **b** DfAf/Dex mice, the inflammation caused by DfAf were suppressed by Dex. **c** DfAf/ITCZ mice. **d** DfAf/LAMB mice. **e** DfAf/Dex/ITCZ mice. **f** DfAf/Dex/LAMB, the inflammatory suppression efficacy of Dex was enhanced by addition of LAMB.

Table 1. The Total Cell Number and the Differentiation Ratio of Cells of BALF in Each Group

	Control	DfAf	DfAf/Dex	DfAf/ITCZ	DfAf/Dex/ITCZ	DfAf/LAMB	DfAf/Dex/LAMB
Total cell number, × 10^5 cells/μl	4.2 (2.1)	15.3 (8.0)†	9.3 (5.1)	4.9 (3.7)	5.4 (2.9)	5.4 (3.1)	4.7 (3.0)‡
Macrophages (%)	68 (12)	38 (10)	51 (12)	43 (6)	22 (9)	15 (10)	20 (11)
Neutrophils (%)	26 (10)	2 (2)	17 (4)‡	19 (2)‡	22 (6)‡	26 (9)‡	21 (13)‡
Lymphocytes (%)	6 (3)	3 (3)	13 (3)‡	5 (7)	16 (7)‡	21 (12)‡	9 (4)
Eosinophils (%)	0 (0)	57 (15)†	19 (12)†,‡	33 (5)†	40 (8)†	38 (10)†	50 (8)†

The data were presented as mean (SD)
$^{\dagger}p < 0.05$ *vs* the control group; $^{\ddagger}p < 0.05$ *vs* the DfAf group

Table 1 presents each medication effect on the BAL cell differentiation. The total cell numbers and eosinophil numbers increased by Df and Af exposure (DfAf group, $p < 0.05$ *vs* control group). This eosinophil number elevation was suppressed by Dex (DfAf/Dex group, $p < 0.05$ *vs* DfAf group). However, this suppression was not enhanced by the combination with ITCZ or with LAMB (DfAf/Dex/ITCZ or DfAf/Dex/LAMB groups *vs* DfAf/Dex group).

The Cytokine Concentrations in Homogenized Lungs

The concentrations of IL-5 and IL-13 (Th2 cytokines) and MIP-2 were significantly elevated in DfAf mice compared with control mice ($p < 0.05$ each; Table 2). Dex did not suppress any of the cytokine levels significantly. ITCZ and LAMB suppressed the elevation of MIP-2 (DfAf/ITCZ and DfAf/LAMB groups, $p < 0.05$, respectively *vs* DfAf group). Interestingly, the combination of Dex and LAMB significantly enhanced the suppression of MIP-2 elevation (DfAf/Dex/LAMB, $p < 0.05$ *vs* DfAf/Dex group) and significantly suppressed the elevation of IL-5 concentration (DfAf/Dex/LAMB group, $p < 0.05$ *vs* DfAf group), but the combination of Dex and ITCZ did not (DfAf/Dex/ITCZ group). None of Dex, ITCZ, or LAMB significantly affected the pulmonary IL-13 concentration.

Discussion

In this study, we found mainly three results. Firstly, our murine DfAf model showed eosinophilic and neutrophilic inflammation in the airways. Secondly, of these inflammations, eosinophilic inflammation (eosinophil infiltration in pathological finding and eosinophil number in BALF) was suppressed by Dex, and neutrophilic inflammation (neutrophil infiltration in pathological findings and MIP-2 in homogenized lung) was suppressed by ITCZ or LAMB. Thirdly, LAMB had additional effect on Dex for both types of inflammation suppression (IL-5 and MIP-2 in homogenized lungs).

Our ABPA mouse model may represent the human ABPA pathogenesis some degree [17, 18]. In agreement with previous report [17], the pathological analysis revealed that Df allergen sensitization and Af infection enhanced both eosinophilic and neutrophilic airway inflammations, along with mucus hyperproduction (DfAf groups; Fig. 2), which were associated with the cytokine profiles (DfAf group *vs* control group; Table 1). While ABPA is characterized by eosinophilia, it has also been correlated with increased sputum neutrophils and increased levels of IL-8 [28, 29]. The detection of Af in sputum was associated with sputum neutrophils, as well as Af IgE sensitization and reduced lung function [30]. These may be a basis of the therapy strategy of the combination of steroid and antifungal medicine for ABPM [15].

A study reported that antifungal therapy with oral ITCZ or voriconazole reduced serum total and Af-specific IgE as well as blood eosinophils in patients with severe asthma with fungal sensitization and ABPA [15]. In the present study, Dex and LAMB

Table 2. The Cytokine and Chemokine Levels in the Homogenized Lung (pg/g lung)

	Control	DfAf	DfAf/Dex	DfAf/ITCZ	DfAf/Dex/ITCZ	DfAf/LAMB	DfAf/Dex/LAMB
IL-5	0.3 (0.0)	92.7 (42.3)†	61.1 (22.9)†	77.8 (14.3)†	82.9 (25.7)†	71.4 (45.7)†	57.1 (31.4)†,‡
IL-13	0.2 (0.0)	520.0 (105.7)†	468.6 (111.4)†	500.0 (101.6)†	511.4 (104.0)†	451.4 (91.8)†	448.6 (91.2)†
MIP-2	0.1 (0.0)	417.1 (51.4)†	445.7 (57.1)†	208.6 (57.1)†,‡	397.1 (48.6)†	185.7 (68.5)†,‡,§	160.0 (40.0)†,‡,§

The data were presented as mean (SD)
$^{\dagger}p < 0.05$ *vs* the control group; $^{\ddagger}p < 0.05$ *vs* the Df/Af group; $^{\S}p < 0.05$ *vs* the Df/Af/Dex group

combination decreased IL-5, and ITCZ and LAMB decreased MIP-2. Thus, it is possible that each drug regulates the Af-exacerbated allergic airway inflammation differently. The pulmonary IL-5 and MIP-2 levels were also decreased by this combination treatment. These may play any role as the unique pathogenesis of ABPA [31]. The benefits of ITCZ in ABPA have been reported [12, 13]. In a recent 4-month study, while prednisolone was superior to itraconazole in inducing a composite response, itraconazole was also effective, and the exacerbation rate at 2 years was also similar between the prednisolone group and itraconazole group [22]. The usefulness of concomitant LAMB or ITCZ on corticosteroid sparing effect for ABPA therapy can be also expected.

This study has some limitations. Firstly, this model represented only a little part of the mechanism of cause or progression of ABPM. We have assumed the early stage of ABPM on present our murine model, but it might be necessary to create an advanced ABPA model also. The periodically type III allergy development result as bronchiectasis may be also important for antifungal therapy. Secondly, we have investigated only three kinds of cytokines (IL-5, IL-13, and MIP-2). Some other important cytokines or proteins (IL-17, IL-33, MMP-9, *etc.*) were not measured which may help our understanding of the ABPA pathogenesis. Both Df sensitization and Af infection induced significant increases in IL-13. None of the drugs, however, influenced IL-13, which is also associated with mucous hypersecretion. It appears that even the combination of Dex and either antifungal drug failed to inhibit goblet cell metaplasia.

In conclusion, the present study observed that antifungal therapy could have a benefit in fungus-exacerbated allergic asthma, which is characterized also by neutrophilic inflammation that is resistant to corticosteroids. The present study elucidated the immunological interactions between Af infection and preexisting allergic airway inflammation. Af infection enhanced not only Th2 responses and airway eosinophilia but also neutrophilic airway inflammation and/or goblet cell hyperplasia [17]. The combination of Dex and ITCZ or LAMB for the treatment of fungus-exacerbated asthma should also be evaluated as an effective treatment strategy of ABPA.

COMPLIANCE WITH ETHICAL STANDARDS

The procedures were reviewed and approved by the Nagasaki University School of Medicine Committee on Animal Research (No. 0307170304).

REFERENCES

1. Maturu, V.N., and R. Agarwal. 2015. Prevalence of Aspergillus sensitization and allergic bronchopulmonary aspergillosis in cystic fibrosis: systematic review and meta-analysis. *Clinical and Experimental Allergy* 45: 1765–1778.
2. Agarwal, R., A.N. Aggarwal, D. Gupta, and S.K. Jindal. 2009. Aspergillus hypersensitivity and allergic bronchopulmonary aspergillosis in patients with bronchial asthma: systematic review and meta-analysis. *The International Journal of Tuberculosis and Lung Disease* 13: 936–944.
3. Greenberger, P.A. 2002. Allergic bronchopulmonary aspergillosis. *The Journal of Allergy and Clinical Immunology* 110: 685–692.
4. Tillie-Leblond, I., and A.B. Tonnel. 2005. Allergic bronchopulmonary aspergillosis. *Allergy* 60: 1004–1013.
5. Gibson, P.G., P.A. Wark, J.L. Simpson, C. Meldrum, S. Meldrum, N. Saltos, and M. Boyle. 2003. Induced sputum IL-8 gene expression, neutrophil influx and MMP-9 in allergic bronchopulmonary aspergillosis. *The European Respiratory Journal* 21: 582–588.
6. Kawano, T., H. Matsuse, K. Iida, Y. Kondo, I. Machida, S. Saeki, S. Tomari, Y. Miyazaki, and S. Kohno. 2003. Two cases of allergic bronchopulmonary mycosis caused by Schizophyllum commune in young asthmatic patients. *Nihon Kokyūki Gakkai Zasshi* 41: 233–236.
7. Muscat, I., S. Oxborrow, and J. Siddorn. 1988. Allergic bronchopulmonary mycosis. *Lancet.* 1 (8598): 1341.
8. Greenberger, P.A., and R. Patterson. 1988. Allergic bronchopulmonary aspergillosis and the evaluation of the patient with asthma. *The Journal of Allergy and Clinical Immunology* 81: 646–650.
9. McCarthy, D.S., and J. Pepys. 1971. Allergic broncho-pulmonary aspergillosis. Clinical immunology. 2. Skin, nasal and bronchial tests. *Clinical Allergy* 1: 415–432.
10. Breslin, A.B., and C.R. Jenkins. 1984. Experience with allergic bronchopulmonary aspergillosis: some unusual features. *Clinical Allergy* 14: 21–28.
11. Golbert, T.M., and R. Patterson. 1970. Pulmonary allergic aspergillosis. *Annals of Internal Medicine* 72: 395–403.
12. Stevens, D.A., H.J. Schwartz, J.Y. Lee, B.L. Moskovitz, D.C. Jerome, A. Catanzaro, D.M. Bamberger, A.J. Weinmann, C.U. Tuazon, M.A. Judson, T.A. Platts-Mills, and A.C. DeGraff Jr. 2000. A randomized trial of itraconazole in allergic bronchopulmonary aspergillosis. *The New England Journal of Medicine* 342: 756–762.
13. Wark, P.A., M.J. Hensley, N. Saltos, M.J. Boyle, R.C. Toneguzzi, G.D. Epid, J.L. Simpson, P. McElduff, and P.G. Gibson. 2003. Anti-inflammatory effect of itraconazole in stable allergic bronchopulmonary aspergillosis: a randomized controlled trial. *The Journal of Allergy and Clinical Immunology* 111: 952–957.
14. Wark, P.A., P.G. Gibson, and A.J. Wilson. 2004. Azoles for allergic bronchopulmonary aspergillosis associated with asthma. *Cochrane Database of Systematic Reviews* (3): CD001108.
15. Pasqualotto, A.C., G. Powell, R. Niven, and D.W. Denning. 2009. The effects of antifungal therapy on severe asthma with fungal sensitization and allergic bronchopulmonary aspergillosis. *Respirology* 14: 1121–1127.
16. Salez, F., A. Brichet, S. Desurmont, J.M. Grosbois, B. Wallaert, and A.B. Tonnel. 1999. Effects of itraconazole therapy in allergic bronchopulmonary aspergillosis. *Chest* 116: 1665–1668.
17. Fukushima, C., H. Matsuse, S. Fukahori, T. Tsuchida, T. Kawano, H. Senjyu, and S. Kohno. 2010. Aspergillus fumigatus synergistically

enhances mite-induced allergic airway inflammation. *Medical Science Monitor* 16: BR197–BR202.
18. Matsuse, H., C. Fukushima, S. Fukahori, T. Tsuchida, T. Kawano, T. Nishino, and S. Kohno. 2013. Differential effects of dexamethasone and itraconazole on Aspergillus fumigatus-exacerbated allergic airway inflammation in a murine model of mite-sensitized asthma. *Respiration*. 85: 429–435.
19. Parmar, J.S., T. Howell, J. Kelly, and D. Bilton. 2002. Profound adrenal suppression secondary to treatment with low dose inhaled steroids and itraconazole in allergic bronchopulmonary aspergillosis in cystic fibrosis. *Thorax* 57: 749–750.
20. Skov, M., K.M. Main, I.B. Sillesen, J. Müller, C. Koch, and S. Lanng. 2002. Iatrogenic adrenal insufficiency as a side-effect of combined treatment of itraconazole and budesonide. *The European Respiratory Journal* 20: 127–133.
21. Patterson, T.F., G.R. Thompson 3rd, D.W. Denning, J.A. Fishman, S. Hadley, R. Herbrecht, D.P. Kontoyiannis, K.A. Marr, V.A. Morrison, M.H. Nguyen, B.H. Segal, W.J. Steinbach, D.A. Stevens, T.J. Walsh, J.R. Wingard, J.A. Young, and J.E. Bennett. 2016. Practice guidelines for the diagnosis and management of Aspergillosis: 2016 update by the Infectious Diseases Society of America. *Clinical Infectious Diseases* 63: e1–e60.
22. Agarwal, R., S. Dhooria, I. Singh Sehgal, A.N. Aggarwal, M. Garg, B. Saikia, D. Behera, and A. Chakrabarti. 2018. A randomized trial of itraconazole vs prednisolone in acute-stage allergic bronchopulmonary aspergillosis complicating asthma. *Chest* 153: 656–664.
23. Ram, B., A.N. Aggarwal, S. Dhooria, I.S. Sehgal, M. Garg, D. Behera, A. Chakrabarti, and R. Agarwal. 2016. A pilot randomized trial of nebulized amphotericin in patients with allergic bronchopulmonary aspergillosis. *The Journal of Asthma* 53: 517–524.
24. Cornely OA, Maertens J, Bresnik M, Ebrahimi R, Ullmann AJ, Bouza E, Heussel CP, Lortholary O, Rieger C, Boehme A, Aoun M, Horst HA, Thiebaut A, Ruhnke M, Reichert D, Vianelli N, Krause SW, Olavarria E, Herbrecht R; AmBiLoad Trial Study Group. 2007. Liposomal amphotericin B as initial therapy for invasive mold infection: a randomized trial comparing a high-loading dose regimen with standard dosing (AmBiLoad trial). Clinical Infectious Diseases 44: 1289–1297.
25. Godet, C., J.C. Meurice, F. Roblot, C. Kauffmann-Lacroix, M. Verdaguer, J.P. Frat, and J. Cadranel. 2012. Efficacy of nebulised liposomal amphotericin B in the attack and maintenance treatment of ABPA. *The European Respiratory Journal* 39: 1261–1263.
26. Purcell, I.F., and P.A. Corris. 1995. Use of nebulised liposomal amphotericin B in the treatment of Aspergillus fumigatus empyema. *Thorax* 50: 1321–1323.
27. Kawano, T., H. Matsuse, Y. Kondo, I. Machida, S. Saeki, S. Tomari, K. Mitsuta, Y. Obase, C. Fukushima, T. Shimoda, and S. Kohno. 2003. Cysteinyl leukotrienes induce nuclear factor kappa b activation and RANTES production in a murine model of asthma. *The Journal of Allergy and Clinical Immunology* 112: 369–374.
28. Pelikan, Z. 2011. Delayed asthmatic response to bronchial challenge with allergen-mediators, eicosanoids, eosinophil and neutrophil constituents in the blood and urine. *Respiration* 82: 225–236.
29. Gibson, P.G., J.L. Simpson, and N. Saltos. 2001. Heterogeneity of airway inflammation in persistent asthma: evidence of neutrophilic inflammation and increased sputum interleukin-8. *Chest* 119: 1329–1336.
30. Fairs, A., J. Agbetile, B. Hargadon, M. Bourne, W.R. Monteiro, C.E. Brightling, P. Bradding, R.H. Green, K. Mutalithas, D. Desai, I.D. Pavord, A.J. Wardlaw, and C.H. Pashley. 2010. IgE sensitization to Aspergillus fumigatus is associated with reduced lung function in asthma. *American Journal of Respiratory and Critical Care Medicine* 182: 1362–1368.
31. Denning, D.W., B.R. O'Driscoll, C.M. Hogaboam, P. Bowyer, and R.M. Niven. 2006. The link between fungi and severe asthma: a summary of the evidence. *The European Respiratory Journal* 27: 615–626.

Publisher's Note Springer Nature remains neutral with regard to jurisdictional claims in published maps and institutional affiliations.