American Journal of Case Reports

e-ISSN 1941-5923
© Am J Case Rep, 2019; 20: 381-384
DOI: 10.12659/AJCR.912747

Received: 2018.08.14
Accepted: 2018.12.06
Published: 2019.03.23

Idiopathic Hypereosinophilic Syndrome in an Elderly Female: A Case Report

Authors' Contribution:
Study Design A
Data Collection B
Statistical Analysis C
Data Interpretation D
Manuscript Preparation E
Literature Search F
Funds Collection G

E 1 Faiza Khalid
AF 2 Fernando Holguin

1 Department of Internal Medicine, University Hospital Cleveland Medical Center/Case Western Reserve University, Cleveland, OH, U.S.A.
2 Department of Pulmonary, Critical Care and Sleep Medicine, University of Colorado, Denver, CO, U.S.A.

Corresponding Author: Faiza Khalid, e-mail: faizakhalid24@gmail.com, Faiza.Khalid@UHhospitals.org
Conflict of interest: None declared

Patient: Female, 83
Final Diagnosis: Idiopathic hypereosinophilic syndrome
Symptoms: Dyspnea
Medication: —
Clinical Procedure: —
Specialty: Allergology

Objective: Rare disease
Background: Hypereosinophilic syndrome (HES) is defined as hypereosinophilia with eosinophil mediated organ damage or dysfunction, provided that other causes of organ damage have been excluded.
Case Report: An 83-year-old female presented with worsening dyspnea for 3 weeks. She was initially diagnosed with bronchitis and prescribed oral antibiotics along with prednisone taper. However, her dyspnea continued to worsen requiring hospitalization. Physical examination was significant for signs of volume overload. Laboratory investigations were notable for leukocytosis with eosinophilia, elevated BNP (brain natriuretic peptide) and troponin. Electrocardiogram (ECG) showed normal sinus rhythm with non-specific ST-T wave changes. Computed tomography (CT) scan of the chest showed pulmonary edema, bilateral peripheral ground glass opacities, and pleural effusions. Transthoracic echocardiogram (TTE) revealed an ejection fraction (EF) of 45%. She was diagnosed with NSTEMI (non-ST-elevation myocardial infarction) with new onset heart failure; appropriate management was initiated. Left heart catheterization did not show any significant obstructive lesions. Presence of peripheral ground glass opacities on the CT chest scan and eosinophilia raised suspicion for HES. Thorough HES workup was done, all tests came back negative except for elevated serum IgE level. Cardiac biopsy returned positive for eosinophilic myocarditis. Bone marrow biopsy showed 20% eosinophils. Positron emission tomography (PET) scan did not show any hypermetabolic lesions to suggest malignancy. The patient was managed for idiopathic HES with high dose steroids resulting in significant clinical improvement.
Conclusions: About 40% of patient with HES manifest cardiac involvement, and one quarter of patients with HES have pulmonary involvement with variable radiologic findings. Steroids remain the mainstay treatment for idiopathic HES.

MeSH Keywords: Disease Management • Hypereosinophilic Syndrome • Myocarditis

Full-text PDF: https://www.amjcaserep.com/abstract/index/idArt/912747

1252 — 3 9

This work is licensed under Creative Common Attribution-NonCommercial-NoDerivatives 4.0 International (CC BY-NC-ND 4.0)

Indexed in: [PMC] [PubMed] [Emerging Sources Citation Index (ESCI)] [Web of Science by Clarivate]

Background

Hypereosinophilia is defined as absolute eosinophil count >1500 cells/µL on 2 occasions separated by at least 1 month and/or pathologic confirmation of tissue hypereosinophilia. Hypereosinophilic syndrome (HES) is characterized by sustained eosinophilic overproduction (hypereosinophilia) and organ damage due to infiltration of eosinophils, provided that other causes of organ damage have been excluded [1]. Any condition where clinical manifestations and organ dysfunction can be explained by mechanism other than HES should not be termed "HES" even in the presence of hypereosinophilia.

HES was considered idiopathic until recently. However, etiologies for some forms of HES have now been described due to better understanding of the syndrome and availability of better investigative techniques.

Case Report

An 83-year-old female with well-controlled mild persistent asthma on inhaled corticosteroids, presented with a complaint of worsening dyspnea for 3 weeks. Prior to presenting to the hospital, she was treated for bronchitis with oral antibiotics and a prednisone taper in an outpatient setting. However, her dyspnea continued to progress requiring hospitalization. Physical examination was notable for signs of volume overload including grade 2+ pedal edema and bilateral crackles on lung auscultation. Laboratory investigations were notable for leukocytosis of 15.5×10^9/L (normal range: 4.5 to 11.0×10^9/L), 26.7% eosinophils (normal range: 0–6%), BNP (brain natriuretic peptide) 1600 ng/L (normal <450 ng/L for patients 75–99 years old), troponin level 12 ng/mL (normal <0.4 ng/mL), serum creatinine 1.6 mg/dL (normal range 0.6–1.2 mg/dL), erythrocyte sedimentation rate 60 mm/hr (normal: 0–29 mm/hr), and C-reactive protein 5.13 mg/L (normal <3.0 mg/L). Electrocardiogram (ECG) showed non-specific ST-T wave changes. Computed tomography (CT) chest showed interstitial edema, and bilateral peripheral ground glass opacities with pleural effusions (Figure 1).

Transthoracic echocardiogram (TTE) was remarkable for an ejection fraction (EF) of 35%. Patient was initially diagnosed with new onset heart failure in the setting of non-ST elevation myocardial infarction (NTESMI) and appropriate management was started. However, a left heart catheterization failed to show any significant obstructive lesions.

Peripheral ground glass opacities on the CT chest, non-ischemic cardiomyopathy and eosinophilia raised suspicion for HES. She underwent an extensive eosinophilia workup, which included tests for: human immunodeficiency virus (HIV) antibody, complement level, serum immunoglobulins including IgG4,

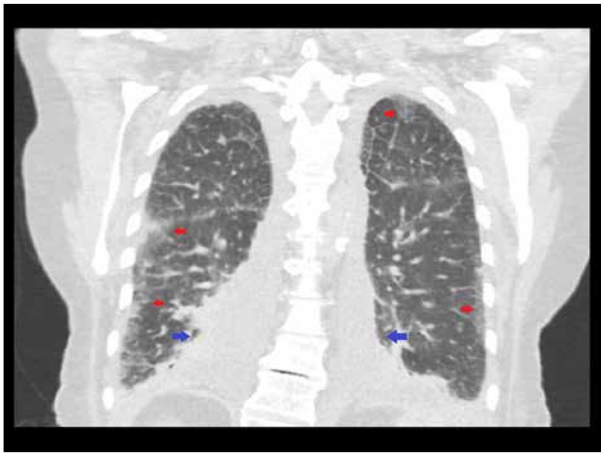

Figure 1. Computed tomography chest showing ground glass opacities and pleural effusions marked by red and blue pointers respectively.

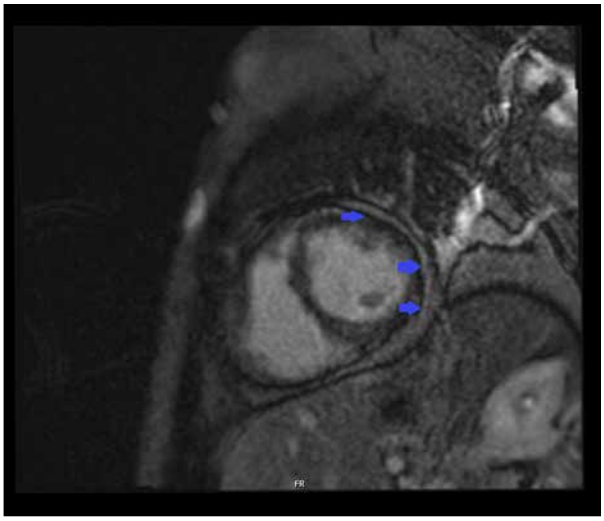

Figure 2. Cardiac magnetic resonance imaging showing late gadolinium enhancement of left ventricle epicardium (blue arrows).

serum tryptase, rheumatoid factor, anti-nuclear antibody (ANA), anti-neutrophil cytoplasmic antibody (ANCA), fluorescence *in situ* hybridization (FISH) for t(9;22) and BCR-ABL, peripheral blood PCR for T-cell clonality, fungal antibodies, parasitic serologies, and urine and serum protein electrophoresis. These were all negative except for a serum IgE level of 712 UI/mL (usual accepted upper limit: 150–300 UI/mL). Cardiac magnetic resonance imaging (MRI) was performed which showed late gadolinium enhancement of left ventricle epicardium (Figure 2).

Cardiac biopsy was performed and was compatible with eosinophilic myocarditis (Figure 3).

Bone marrow biopsy showed 20% eosinophils with a single large T-cell aggregate without any aberrant T-cell lymphocytes,

This work is licensed under Creative Common Attribution-NonCommercial-NoDerivatives 4.0 International (CC BY-NC-ND 4.0)
Indexed in: [PMC] [PubMed] [Emerging Sources Citation Index (ESCI)] [Web of Science by Clarivate]

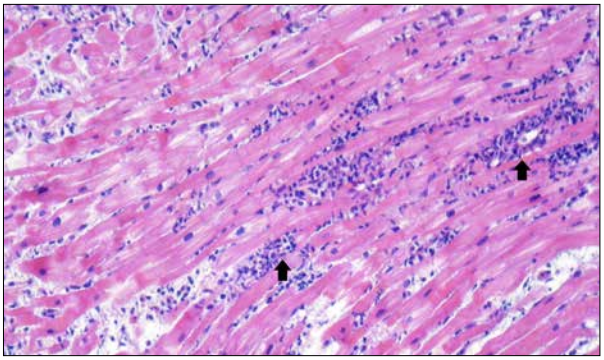

Figure 3. Cardiac biopsy showing eosinophils marked by black pointers infiltrating the cardiac smooth muscles.

which was favored to be benign as bone marrow flow cytometry was unremarkable. Flow cytometry analysis of cells within the lymphocyte gate did not show any abnormal T-lymphocyte subtype specifically associated with lymphocytic variant of HES (L-HES) including T-lymphocytes $CD4^+$ $CD3^-$, $CD3^+$ $TCR^{\alpha/\beta+}$, $CD4^-$ $CD8^-$ and $CD4^+$ $CD7^-$, which drive eosinophilia by secreting eosinophil-promoting cytokine (IL-5) [2]. Furthermore, analysis of the cells within the granulocyte and monocyte gates did not reveal a phenotypic abnormality. Bone marrow FISH study for FIPL1-PDGFRA, ETV6-PDGFRB or other PDFGRB rearrangements, FGFR1, and PCM-JAK2 was negative and a positron emission tomography (PET) scan did not show any hypermetabolic lesions. Ultimately, the patient was diagnosed with idiopathic HES and started on high dose steroids with significant clinical improvement. The recommended steroids are 1 mg/kg of prednisone. Intravenous steroids should be used in patients who are hypotensive or have gastrointestinal involvement. Our patient was started on 70 mg of prednisone daily (based on 1 mg/kg) for 1 week with dramatic improvement in eosinophil count (>50% drop). Slow and cautious tapering of steroid was initiated after 1 week. The patient was discharged from the hospital after 12 days with continued slow tapering of steroids and close follow-up. It should be noted that there are no evidence-based guidelines for steroid taper and duration in HES, tapering schedule is highly variable and should be guided by the severity of the presenting clinical complications and the extent to which eosinophil suppression has been achieved by treatment.

Our patient also had partial recovery of cardiac function on repeat outpatient echocardiogram with EF improving to 45% after 1 month. The patient was able to be taken off steroids completely after 6 months.

Discussion

The definition of hypereosinophilic syndrome (HES) includes [2]: 1) hypereosinophilia with absolute eosinophil count of >1500 cells/mm^3 on 2 occasions separated by at least 1 month or histologic evidence of tissue hypereosinophilia; 2) eosinophil mediated organ damage; 3) exclusion of other causes of organ damage.

HES is rare with an estimated prevalence of 0.36 to 6.3 per 100 000 [3]. Usual age of diagnosis for HES is 20–50 years old, however, cases in the elderly population have been noted as well [4], such as our patient. HES often involves the skin, lungs, heart, spleen, and nervous system [5]. In our patient case, there was involvement of the myocardium and lungs. Involvement of the myocardium in HES is the major cause of morbidity and mortality among patients. Acute myocardial eosinophilic infiltration can manifest as heart failure, chest pain, arrhythmia, or cardiac thrombi. Chronic manifestation of HES includes restrictive cardiomyopathy as the fibrosis ensues [6].

Pulmonary involvement in idiopathic HES is variable. Dulohery et al. conducted a retrospective study of 49 patients from 2004–2008 to ascertain the frequency of lung involvement in patients with HES. Their study found that 37% of patients had parenchymal infiltrates, 14% had pleural effusions, and intrathoracic lymphadenopathy was seen in 12% of the patients and 4% developed pulmonary emboli [7].

HES can be further subclassified according to the pathogenic mechanisms of eosinophil expansion: primary (neoplastic), secondary (reactive), or idiopathic [8]. In primary HES, there is clonal eosinophilic expansion which is triggered by stem cell, eosinophilic, or myeloid neoplasm. Elevated serum tryptase and FIPL1-PDGFRA fusion gene is associated with myeloid variant of HES [9], which was negative in our patient. Furthermore, the PET scan did not show any areas of hypermetabolic activity to suggest malignancy for our patient.

Secondary HES is polyclonal and caused by excess eosinophilopoietic cytokines as seen in parasitic infections, drug hypersensitivity, certain solid tumors, and lymphocytic variant of HES. Presence of aberrant T-cell lymphocytes is a hallmark of the lymphocytic variant. In our patient, bone marrow biopsy and flow cytometry did not suggest any lymphoproliferative process. Parasitic serologies were negative and no solid tumors were identified on imaging.

Familial eosinophilia is a rare form of inherited HES, however, it manifests early in life. Furthermore, our patient did not have any family history of hypereosinophilia.

Conclusions

HES is rare in the elderly population but still should be considered in the differential when there is presence of

This work is licensed under Creative Common Attribution-NonCommercial-NoDerivatives 4.0 International (CC BY-NC-ND 4.0)

Indexed in: [PMC] [PubMed] [Emerging Sources Citation Index (ESCI)] [Web of Science by Clarivate]

hypereosinophilia along with organ damage. A thorough and systematic workup is required to rule out primary and secondary causes of hypereosinophilia before idiopathic HES can be diagnosed. The organ systems that are commonly affected in HES include the skin, lungs, gastrointestinal tract, heart, and nervous system. Overwhelmingly in patients, the onset of symptoms is subtle, and eosinophilia may be detected incidentally. In a small number of patients, initial manifestations are severe due to the rapid evolution of cardiovascular or neurologic complications.

Steroids remain the mainstay treatment for HES. Patients not responding to recommended dose of steroids need alternatives such as mepolizumab, hydroxyurea, or pegylated interferon.

References:

1. Valent P, Klion AD, Horny HP et al: Contemporary consensus proposal on criteria and classification of eosinophilic disorders and related syndromes. J Allergy Clin Immunol, 2012; 130(3): 607–612e9
2. Cheung CC, Constantine M, Ahmadi A et al: Eosinophilic myocarditis. Am J Med Sci, 2017; 354(5): 486–92
3. Crane MM, Chang CM, Kobayashi MG, Weller PF: Incidence of myeloproliferative hypereosinophilic syndrome in the United States and an estimate of all hypereosinophilic syndrome incidence. J Allergy Clin Immunol, 2010; 126(1): 179–81
4. Navarro I, Torras J, Gomà M et al: Renal involvement as the first manifestation of hypereosinophilic syndrome: A case report. NDT Plus, 2009; 2(5): 379–81
5. Fauci AS, Harley JB, Roberts WC et al: NIH conference. The idiopathic hypereosinophilic syndrome. Clinical, pathophysiologic, and therapeutic considerations. Ann Intern Med, 1982; 97(1): 78–92
6. Desreumaux P, Janin A, Dubucquoi S et al: Synthesis of interleukin-5 by activated eosinophils in patients with eosinophilic heart diseases. Blood, 1993; 82(5): 1553–60
7. Dulohery MM, Patel RR, Schneider F, Ryu JH: Lung involvement in hypereosinophilic syndromes. Respir Med, 2011; 105(1): 114–21
8. Shehwaro N, Langlois AL, Gueutin V, Izzedine H: Renal involvement in idiopathic hypereosinophilic syndrome. Clin Kidney J, 2013; 6(3): 272–76
9. Khoury P, Makiya M, Klion AD: Clinical and biological markers in hypereosinophilic syndromes. Front Med (Lausanne), 2017; 4: 240

This work is licensed under Creative Common Attribution-NonCommercial-NoDerivatives 4.0 International (CC BY-NC-ND 4.0)
Indexed in: [PMC] [PubMed] [Emerging Sources Citation Index (ESCI)] [Web of Science by Clarivate]