# Development of Allergic Conjunctivitis Induced by House Dust Mite Extract From *Dermatophagoides pteronyssinus*

Young Ji Lee,[1,2] Soo Jung Han,[2] Hun Lee,[2,3] Jin Sun Kim,[2,4] and Kyoung Yul Seo[2]

[1]Yonsei Plus Eye Clinic, Seongnam, South Korea
[2]Institute of Vision Research, Department of Ophthalmology, Yonsei University College of Medicine, Seoul, South Korea
[3]Department of Ophthalmology, International St. Mary's Hospital, Catholic Kwandong University College of Medicine, Incheon, South Korea
[4]Department of Ophthalmology, Kim's Eye Hospital, Myung-Gok Eye Research Institute, Konyang University College of Medicine, Seoul, South Korea

Correspondence: Kyoung Yul Seo, Department of Ophthalmology, Yonsei University College of Medicine, 50 Yonsei-ro, Seodaemun-gu, Seoul 120-752, Republic of Korea; seoky@yuhs.ac.

Submitted: May 26, 2015
Accepted: February 8, 2016

Citation: Lee YJ, Han SJ, Lee H, Kim JS, Seo KY. Development of allergic conjunctivitis induced by house dust mite extract from *Dermatophagoides pteronyssinus*. *Invest Ophthalmol Vis Sci*. 2016;57:1773–1781. DOI:10.1167/iovs.15-17340

**Purpose.** The purpose of this study was to develop a murine model of allergic conjunctivitis induced by house dust mite (HDM) extract from *Dermatophagoides pteronyssinus*, a major allergen in humans.

**Methods.** Forty BALB/c mice were divided into five groups, immunized with placebo, ovalbumin (10 μg), or HDM extract following a schedule. Twenty minutes after topical challenge, mice were examined clinically. Material collected from mice was used for measuring total and specific IgE, antigen-specific lymphocyte proliferation, and supernatant cytokine levels and for conjunctival histopathology and flow cytometric analysis of conjunctival cells.

**Results.** This murine model showed similar clinical signs and laboratory findings to human allergy and the ovalbumin-induced allergic conjunctivitis model. Total IgE levels and conjunctival infiltration of mast cells and eosinophils in immunized mice were significantly higher than in the control group. Cervical lymphocyte proliferation was increased in antigen-stimulated cultures in immunized mice, concomitant with significantly higher IL-4 and IL-5 levels in the culture supernatant. The proportion of conjunctival $CD4^+$ T cells expressing the ST2 receptor was increased, and conjunctival $CD4^+ST2^+$ T cells exhibited an increase in intracellular IL-5.

**Conclusions.** House dust mite extract successfully induced allergic conjunctivitis in BALB/c mice. Ten micrograms of HDM extract was the optimal dose for systemic immunization in this model. This murine model is suitable for further studies on HDM-induced allergic conjunctivitis, and the data show that conjunctival $CD4^+$ T cells expressing ST2 may play an important role in IL-5 secretion, recruiting eosinophils into conjunctiva on ocular allergen challenge.

Keywords: allergic conjunctivitis, house dust mite, *Dermatophagoides pteronyssinus*, IL-4, IL-5, ST2

Ocular allergy is a common ocular immune disorder, and the incidence and prevalence of allergic conjunctivitis has increased dramatically all over the world, especially in westernized nations.[1,2] Allergic conjunctivitis is commonly combined with other allergic diseases such as allergic rhinitis, atopic dermatitis, and allergic asthma.[3] The allergic reactions result from IgE or T cell–mediated reactions. After cross-linking between the antigen and antigen-presenting cell is complete, dendritic cells (DCs) activate T helper (Th)2 cells, which results in the release of IL-4 (important to IgE synthesis) and IL-5 (important to eosinophil recruitment). Interleukin-4 regulates differentiation of naïve Th0 cells to antigen-specific Th2 cells, which then release IL-4, –5, –9, and –13 and stimulate IgE production by B cells. In allergic conjunctivitis, provocation of conjunctiva by allergen induces immigration of mature DCs via lymphatic vessels from allergen-exposed tissues to the cervical lymph node, promoting Th2 activation, resulting in increased conjunctival infiltration of mast cells and eosinophils producing various inflammatory cytokines that make an altered inflammatory tear film.[4,5] Recent studies have highlighted the immune-modulatory role of the conjunctival epithelium and goblet cells to allergic conjunctivitis and costimulation of DC–T-cell interaction via chemokine (C-C motif) receptor (CCR) 7.[6]

Clinically, the symptom of allergic conjunctivitis is characterized by itching, lid swelling, conjunctival redness, foreign body sensation, stinging eyeball pain, and excessive tearing.[1,7] Seasonal allergic conjunctivitis (SAC) and perennial allergic conjunctivitis (PAC) are two allergic conjunctival disorders that are predominantly caused by a mast cell–mediated hypersensitivity reaction to airborne or exposed allergens.[1] Atopic keratoconjunctivitis and vernal keratoconjunctivitis can become quite severe, leading to corneal involvement and rarely can lead to blindness.[7] Perennial allergic conjunctivitis is a chronic condition, which usually involves sensitization to allergens that are present year-round, such as house dust mites (HDMs), animal dander, molds, and air pollutants, and shows



This work is licensed under a Creative Commons Attribution-NonCommercial-NoDerivatives 4.0 International License.

Downloaded From: http://iovs.arvojournals.org/pdfaccess.ashx?url=/data/Journals/IOVS/935164/ on 05/17/2016

more eosinophil infiltration in conjunctiva compared with that in SAC.[8] Perennial allergic conjunctivitis is commonly due to an allergy to HDMs, which is sometimes related to atopic keratoconjunctivitis,[9] and most patients have specific serum IgE for HDM.[1] Perennial allergic conjunctivitis can induce mast cell and eosinophil infiltration into the conjunctiva, and an altered, inflammatory tear film resulted from chronic inflammation of the ocular surface would not provide a sufficient ocular surface, thereby compromising the defense system and decreasing the threshold for an allergen attack.[7]

House dust mites, commonly found in human dwellings, are an important source of inhalant and contact allergens. The sensitization rate to HDMs has increased in South Korea with industrialization and westernization.[10] In South Korea, *Dermatophagoides farina* and *Dermatophagoides pteronyssinus* are the most common HDM species.[10,11] The *D. pteronyssinus* Der p1 and Der p2 protein allergens are associated with 40%–60% of total immunity.[12]

A reliable animal model of allergic conjunctivitis using diverse allergens similar to the human equivalent is needed to delineate the pathophysiologic and immunologic mechanism of ocular allergic inflammation and to develop novel therapeutic strategies. To date, animal models of allergic conjunctivitis have been developed using limited allergens like ovalbumin, ragweed pollen, and cat allergen in guinea pigs, rats, and mice.[13] In contrast, reports on animal models aiming at understanding PAC such as HDM-induced allergic conjunctivitis are rare.[9,14,15] Hara et al.[9] developed atopic keratoconjunctivitis in an NC/Nga mouse model using *D. farina*. They applied dermatologic ointment with 5 mg *D. farina* used for skin sensitization without an adjuvant several times for 17 days and applied topical ophthalmic ointment or solution including allergen extracts of *D. farina* every 3 days. This is a novel murine atopic keratoconjunctivitis model, but for inducing an allergic condition, it needs a considerable supply of HDM extracts.

We developed a murine model of allergic conjunctivitis in Balb/c mice using an extract from a different *Dermatophagoides* species, *D. pteronyssinus*, which is an important source of major allergens of PAC. We used different concentrations of the allergen, because the allergen concentration is an important determinant of the allergic reaction, such that excess amounts of the allergen activate T-suppressor cells that result in suppression of the immune reaction.[7,16,17] We also performed flow cytometric analysis, serum IgE measurements, and conjunctival histopathologic assessments.

Recent studies suggest an important role for the IL-33–ST2 interaction in allergic diseases.[6,18–24] Epithelial cell–derived IL-33, induced by airborne allergens, viruses, and air pollutants, is known to activate naïve and Th2 lymphocytes, mast cells, and eosinophils and promotes Th2-type cytokine production via a ST2, a membrane-bound IL-33–specific receptor expressed on mast cells, Th2 cells, and eosinophils.[20] Therefore, we evaluated whether conjunctival $CD4^+$ T cells in our murine model of allergic conjunctivitis expressed ST2 and produced IL-5 on repeated allergen challenge. The murine model developed in this study presented clinical signs and histopathologic and molecular features of allergic conjunctivitis in humans and can be used to delineate the pathophysiologic mechanism of ocular allergy and in development of therapeutic strategies.

## Materials and Methods

### Experimental Animals

Forty female 8-week-old BALB/c mice were housed in a pathogen-free environment at Yonsei University Animal Center. The study protocol was approved by the Animal Experiments Ethics Review Committee of Yonsei University, College of Medicine, Seoul, Korea. All procedures were carried out in accordance with the ARVO statement for the Use of Animals in Ophthalmic and Vision Research.

### Reagents

The sensitization and challenge agents included ovalbumin (OVA; Grade V; Sigma-Aldrich Corp., St. Louis, MO, USA), HDM extract from *D. pteronyssinus*, and aluminum hydroxide (ALUM; Imject Alum; Thermo Scientific, Inc., Rockford, IL, USA). Lyophilized powder of HDM extract from *D. pteronyssinus* was purchased from the Internal Medicine Department, College of Medicine, Yonsei University. Major HDM extract allergen concentrations were 24.0 μg/mg (11.6 μg/mg of Der p1 and 12.4 μg/mg of Der p2), as assessed using two-site ELISA after reconstitution of lyophilized powder to 1 mg/mL in PBS.[25] Chloramphenicol inhibition assays showed that the allergen concentrations in the HDM extract were 12.8 AU/μg.[25]

### Experimental Allergic Conjunctivitis

Forty mice were divided into five groups (eight mice per group) and allergen-sensitized following protocols developed in our laboratory (Supplementary Fig. S1). Control mice were sensitized by an intraperitoneal injection of 0.2 mL PBS and ALUM (2.0 mg) on days 1 and 8. They were challenged by topical instillation of 5 μL PBS in each eye on days 15, 17, and 19. Mice in the OVA group were sensitized by intraperitoneal injection of 0.2 mL OVA (10 μg) absorbed on ALUM (2.0 mg), and 5 μL 5% OVA (250 μg OVA absorbed in PBS) was used for topical instillation on the scheduled days, as described previously.[26]

The mice in the three HDM groups were sensitized by intraperitoneal injection with different concentrations of allergen (0.2 mL of 10, 100, or 500 μg of HDM extract, respectively) absorbed on ALUM (2.0 mg). They were challenged by topical instillation of 5 μL of 10% HDM (500 μg HDM absorbed in PBS).

On day 19, clinical symptoms and signs in anesthetized mice were investigated 20 minutes after ocular allergen challenge. On day 20, mice were killed, and serum and cervical lymph node samples, whole eyeballs, including upper and lower eyelids, and conjunctival tissue samples were collected for further analyses.

### Evaluation of Symptoms and Signs

On day 19, mice were assessed for clinical symptoms and signs of an immediate hypersensitivity response 20 minutes after the ocular challenge under respiratory anesthesia by an independent observer blinded to the grouping. The symptoms of the mice in the cage, eye frowning, tearing/discharge, chemosis, hyperemia, and eyelid edema, were graded from 0 to 2 according to severity (0, no finding; 1, mild; 2, severe; Table 1).[27] The category "Behavior" including face washing, eye frowning, agitation, and lethargy/crouching can be considered reflections of severe ocular discomfort and stimulation during the acute-phase response (0, none of them; 1, one item among them; 2, more than two items among them; Fig. 1). The grades for each of the six parameters were added to obtain a total clinical score of between 0 and 12, proportional to the symptom intensity. Images of the eyes of the mice were also captured.

Twenty-four hours after the ocular allergen challenge of immunized mice, animals were anesthetized, and blood was collected through cardiac puncture. Cervical lymph node

Investigative Ophthalmology & Visual Science

Downloaded From: http://iovs.arvojournals.org/pdfaccess.ashx?url=/data/Journals/IOVS/935164/ on 05/17/2016

**Table 1.** Clinical Data for Murine Model of Allergic Conjunctivitis

| | Grade (score) | | |
|---|---|---|---|
| **Symptoms** | **Normal (0)** | **Mild (1)** | **Severe (2)** |
| Behavior | Normal | Irritability | Piloerection and squatting |
| Eye opening | Normal | Squinting | Eye frowning |
| Discharge | Absent | Mild | Prominent |
| Chemosis | Absent | Mild | Severe |
| Hyperemia | Absent | Mild | Severe |
| Eyelid edema | Absent | Mild | Severe |

dissection and eyeball enucleation were carried out. Then, total and specific IgE levels were measured, and assays of HDM-specific lymphocyte proliferation and supernatant cytokine levels and histopathologic evaluation of the conjunctiva were performed.

## Measurement of Total and HDM-Specific IgE Levels

Total and HDM-specific IgE antibodies in serum samples were measured using ELISA.[28] Briefly, 96-well Maxi-Sorp plates (Nunc; VWR Canlab, Mississauga, ON, Canada) were coated with 100 μL purified rat anti-mouse IgE antibodies (2 μg/mL; R35-72; BD Biosciences Pharmigen, San Diego, CA, USA) for total IgE antibody detection overnight at 4°C, and other plates were coated with 100 μL HDM extract (50 μg/mL in PBS) for HDM-specific IgE antibody detection overnight at 4°C. After blocking with 1% BSA in PBS for 1 hour at 37°C, serial dilutions of serum samples and standard mouse IgE antibodies (27-74; BD Pharmigen) were added, and the mixtures were incubated overnight at 4°C. The plates were then washed with PBS containing 0.05% Tween (PBS/T) and incubated with 100 μL horseradish peroxidase–conjugated rat anti-mouse IgE antibody (2 μg/mL; Southern Biotech, Birmingham, AL, USA) for 2 hours at 37°C.

After washing with PBS/T, samples were treated with tetramethyl-benzidine (Moss, Inc., Pasadena, CA, USA) for 15 minutes at room temperature, and the chromogenic reaction was stopped by adding 0.5 N HCI. The absorbance at 450 nm was measured, and total IgE concentrations were calculated, using the linear range of a standard of curve generated with purified mouse IgE antibody (27-74; BD Pharmingen). As no HDM-specific IgE standards exist, values were expressed in units of optical density (OD) at 450 nm.

## Allergen-Specific Lymphoid Cell Proliferation in Cervical Lymph Node

Cervical lymph node cells were mashed in RPMI 1640 medium (Gibco, Carlsbad, CA, USA) supplemented with 10% heat-inactivated fetal calf serum, penicillin (50 U/mL), streptomycin (50 μg/mL), and 2 mM L-glutamine, and the dispersed cells were filtered through a 100-μm strainer to obtain a single-cell suspension. Cells were reconstituted to a concentration of $4 \times 10^6$ cells/mL, with a final volume of 0.1 mL/well. For evaluation of antigen-specific lymphocyte proliferation, cervical lymphoid cells were cultured in U-bottomed 96-well immunoplates (Nunc), with or without stimulation, using 100 μg/mL HDM or 1 mg/mL OVA for 72 hours.

After culture, proliferation and cell cycle phase distribution of lymphocytes were assessed using a bromodeoxyuridine (BrdU) ELISA kit (BD Biosciences, San Jose, CA, USA). Levels of TNF-α, IFN-γ, IL-2, IL-4, and IL-5 in the culture supernatant were measured using ELISA kits (BD Cytometric Bead Array Mouse Th1/Th2 cytokine kit; BD Biosciences). Flow cytometry was performed with the FACSCalibur system (BDTM FACS LSR II; BD Biosciences).

## Histopathology

To evaluate the cellular infiltrates in conjunctiva during the late-phase reaction, the left eyes of the mice were used for histopathologic analysis. Whole eye tissue, including eyeballs, upper and lower eyelids, and the bulbar conjunctiva, were harvested 24 hours after the final topical challenge and fixed in 4% buffered formalin. Samples were embedded in paraffin and then vertically sectioned in 4-μm-thick planes of the central lesion. Samples were stained with hematoxylin-eosin for evaluation of general pathologic changes and with toluidine blue stain for analysis of mast cells. Fields from each sample, including the palpebral and bulbar conjunctiva, were examined under a light microscope (Olympus; Olympus Optical Co. Ltd., Tokyo, Japan) at ×400 magnification. Eosinophils were identified as cells in which the cytoplasmic granules were stained with eosin. An observer masked to the origin of the slides counted the infiltrating eosinophils and mast cells. A total of eight sections representing the central portion of samples from each group were counted, and the data are presented as the mean ± SD.

## Quantitative Analysis of $CD4^+$ T Lymphocytes in Conjunctiva

For quantitative analysis of $CD4^+$ T lymphocytes in conjunctiva, bulbar and palpebral conjunctival tissues were separated carefully from enucleated right eye tissues in the control, OVA, and HDM (10 μg) groups. The conjunctiva were sliced and incubated in complete medium supplemented with 5 mg/mL collagenase/dispase (Roche Diagnostics, Mannheim, Germany) and 0.1 mg/mL DNase type 1 (Sigma-Aldrich Corp.) and incubated at 37°C with stirring for 30 minutes three times. The dispersed cells were filtered through a 100-μm cell strainer, resuspended in complete medium, and centrifuged. The pellet was washed with 1% BSA in PBS and was stimulated with RPMI 1640 supplemented with phorbol myristate acetate (50 ng/mL), ionomycin (750 ng/mL), and Golgi plug (1 μg/mL) for 4 hours at 37°C. Cells were blocked using purified anti-mouse CD16/32 (E-bioscience, San Diego, CA, USA) for 15 minutes. After washing with 1% BSA in PBS, cells were labeled with anti-mouse CD4-efluor 605NC (E-bioscience), anti-mouse CD3-FITC (E-bioscience), or anti-mouse ST2-percp-efluor 710 (E-bioscience) for 30 minutes at 4°C. For intracellular staining, after perforating cell membranes with BD cytofix/cytoperm, cells were labeled with anti-mouse IL-5-phycoerythrin (PE) (E-bioscience) for 30 minutes at 4°C. Flow cytometry analysis was performed using the fluorescence-activated cell sorting (FACS) Calibur system.

## Statistical Analyses

Data were analyzed with SPSS Windows version 20.0 (SPSS, Inc., Chicago, IL, USA). All results are expressed as mean ± SD. The differences between experimental groups and control group were analyzed using ANOVA with Bonferroni adjusted post hoc comparison. In comparisons of cytokine levels with/without allergen stimulation within the same group, a paired *t*-test was used. Values of $P < 0.05$ were considered statistically significant.

# Results

We confirmed the development of allergic conjunctivitis induced by OVA and HDM antigens in our murine model,

Investigative Ophthalmology & Visual Science

Downloaded From: http://iovs.arvojournals.org/pdfaccess.ashx?url=/data/Journals/IOVS/935164/ on 05/17/2016

**Figure 1.** Clinical features of eyes in mice. (1) Before ocular allergen challenge and (2) eye discharge (*upper*) and conjunctival redness (*lower*) 20 minutes after ocular allergen challenge. (**A**) Phosphate-buffered saline challenge in control mice. (**B**) After ocular challenge with 5% OVA (OVA group). (**C–E**) After challenge with 10% HDM in HDM 10, 100, and 500 μg groups, respectively. (3) Behavior change after ocular allergen challenge. (**A**) Score 0, normal. (**B**) Score 2, eye frowning and lethargy/body squatting with piloerection reflect ocular discomfort and severe ocular inflammation following ocular allergen challenge.

based on the clinical symptoms, elevated total IgE levels, positive antigen-specific IgE levels, increased conjunctival infiltration of mast cells and eosinophils, increased antigen-specific lymphocyte proliferation, and in vitro increase in Th2 cytokine production after antigen stimulation.

## Clinical Symptoms and Signs

Representative images of the early phase of ocular allergy are shown in Figure 1. Significant increase of tearing or discharge after ocular allergen challenge was seen in all experimental groups, and mice exhibited clinical symptoms consistent with allergic conjunctivitis, including eye frowning, agitation, and lethargy/crouching, indicating severe ocular inflammation and pain. Mice showed intermittent conjunctival hyperemia, but no significant chemosis or eyelid edema. Clinical data are summarized in Table 2. The mean clinical scores of the five groups were 0, 7, 7, 6, and 6, respectively. None of the mice had a score of 12, and three mice in group 2 had the highest score (8). There was no significant difference in the clinical scores among experimental groups ($P > 0.05$).

**Table 2.** Results of Clinical Score in Experimental Allergic Conjunctivitis

| | | | HDM | | |
|---|---|---|---|---|---|
| **Symptoms** | **Control** | **OVA** | **10 μg** | **100 μg** | **500 μg** |
| Behavior | 0 | 2 | 2 | 2 | 2 |
| Eye opening | 0 | 2 | 2 | 2 | 2 |
| Discharge | 0 | 2 | 2 | 2 | 1 |
| Chemosis | 0 | 0 | 0 | 0 | 0 |
| Hyperemia | 0 | 1 | 1 | 0 | 1 |
| Eyelid edema | 0 | 0 | 0 | 0 | 0 |

## Total and HDM-Specific IgE in Serum

To exclude the effect of ALUM increasing IgE production, we added the total IgE and specific IgE data of naïve mice for better comparison. Significantly elevated serum levels of total IgE was found in both OVA and HDM groups compared with the control group (Fig. 2A). Total IgE titer was detected highest in the HDM (10 μg) group among HDM groups. As no HDM-specific IgE standards exist, HDM-specific IgE values were expressed in units of optical density (OD) at 450 nm. The detection of HDM-specific IgE confirms that allergic conjunctivitis is induced by HDM extract in this murine model (Fig. 2B).

## Increased Antigen-Specific Lymphocyte Proliferation and Th2-Type Cytokine Release After Antigen Stimulation

T helper 2 cytokine (IL-4 and IL-5) production in supernatant from cultured cervical lymphocytes after allergen stimulation was significantly increased compared with that without allergen stimulation in all immunized groups (Figs. 3A, 3B). Interleukin-4 and IL-5 levels were significantly higher in supernatant from immunized mice compared with that in

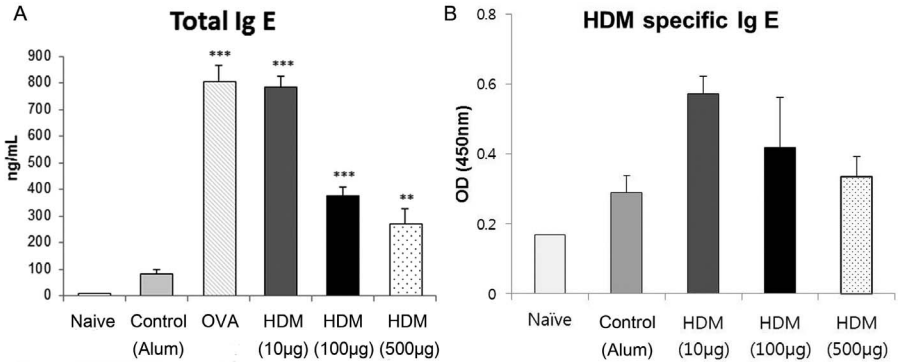


**Figure 2.** Levels of total and HDM-specific IgE. All serum samples were diluted 1:10 before measurement of IgE levels, and all data represent the mean ± SD. To exclude the effect of ALUM increasing IgE production, we added the total IgE and specific IgE data of naïve mouse as an additional negative control for comparison. As no HDM-specific IgE standards exist, HDM-specific IgE values were expressed in units of optical density (OD) at 450 nm. (**A**) Comparison of total IgE titers in serum. Total IgE was significantly increased in all allergen-sensitized groups compared with that in the control group. (**B**) The detection of HDM-specific IgE confirms that allergic conjunctivitis is induced by HDM extract in this murine model. $^{*}P < 0.05$; $^{**}P < 0.01$; and $^{***}P < 0.001$, all compared with the control group (ANOVA with Bonferroni-adjusted post hoc comparison).

Investigative Ophthalmology & Visual Science

Downloaded From: http://iovs.arvojournals.org/pdfaccess.ashx?url=/data/Journals/IOVS/935164/ on 05/17/2016

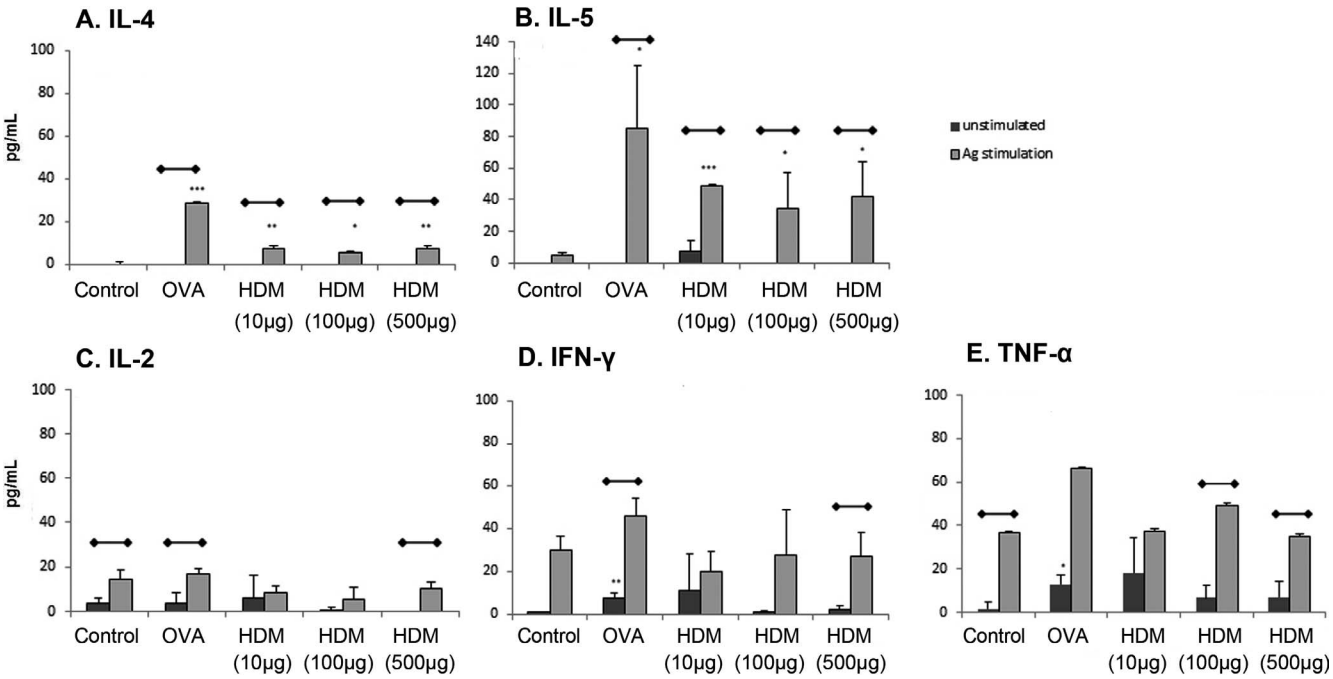


**Figure 3.** Measurement of cytokine levels in the supernatant from cervical lymphocyte cultures with/without allergen stimulation. Cervical lymphocytes from mice in the five groups (control, OVA, and HDM [10, 100, and 500 μg]) were cultured in vitro, and the levels of indicated cytokines in the supernatant were measured using ELISA. Data represent the mean ± SD of five independent trials. $^{*}P < 0.05$; $^{**}P < 0.01$; and $^{***}P < 0.001$, all compared with the control group. Note that the cytokine titers are significantly higher in the immunized groups compared with that in the control group, with allergen stimulation. $^{\leftrightarrow}P < 0.05$, in comparisons of cytokine levels with/without allergen stimulation within the same group. T helper 2 cytokine (IL-4 and 5) release was significantly higher in all immunized groups compared with in the control group in the in vitro culture with allergen. T helper 1 cytokine (IL-2 and IFN-γ) release was significantly increased in the OVA and HDM 500 μg group after allergen stimulation. Tumor necrosis factor-α, one of the inflammation cytokines, was significantly increased in control and HDM 100 μg and 500 μg groups after allergen stimulation. However, there is no difference in cytokine titers (TNF-α, IL-2, and IFN-γ) among experimental groups.

control mice after allergen stimulation. Interleukin-4 release from cervical lymphocytes with HDM stimulation was not significantly different among HDM groups; however, IL-5 release was significantly increased in the HDM (10 μg) group compared with other HDM groups.

T helper 1–type cytokine (IL-2 and IFN-γ) release was significantly increased in cultured cervical lymphocytes with allergen stimulation compared with that without allergen stimulation (OVA and HDM [500 μg] in Figs. 3C and 3D, respectively). Cytokine release of TNF-α, IFN-γ, and IL-2 from cultured cervical lymphocytes with antigen stimulation did not differ significantly between control and allergen-immunized groups (Figs. 3C–3E).

T-cell and $CD4^+$ T-cell lines from cervical lymph nodes of all immune-sensitized mice groups proliferated considerably in the in vitro cultures with specific allergen, OVA or HDM, as assessed using the BrdU assay (Fig. 4). These findings imply that OVA- or HDM-immunized mice have allergen-specific T lymphocytes and $CD4^+$ T cells in their cervical lymph nodes and can secrete significantly higher amounts of Th2 cytokines on allergen challenge.

## Histopathologic Analysis

Histopathologic analysis indicated significant increased conjunctival infiltration of eosinophils and mast cells in allergen-sensitized mice compared with control mice (Fig. 5). However, there was no significant difference in eosinophil or mast cell infiltration into conjunctiva among the HDM-immunized groups.

## Quantitative Analysis of $CD4^+$ T Lymphocytes in Conjunctiva

When CD4+ T lymphocytes from conjunctiva were stained for membrane-bounded ST2, an increase of conjunctival ST2+CD4+ T (Th2) lymphocytes in allergen-immunized mice, concomitant with increased intracellular IL-5, was seen, compared to that in control mice (Fig. 6).

## Discussion

In this study, we developed a new murine model of allergic conjunctivitis induced by *D. pteronyssinus* using BALB/c mice. In our laboratory, we tried to reproduce murine models with allergic conjunctivitis induced by HDM according to previously reported protocols.[14,15] However, we could not confirm clinical signs and laboratory data of allergic conjunctivitis as shown in the OVA-stimulated induction of allergic conjunctivitis in previous murine models.[26,28] In our preliminary studies, we found that BALB/c mice are more suitable for the allergic model than C57BL/6 mice, based on BALB/c mice tending to a more Th2-like profile (data not shown).[15] Moreover, the cervical lymph node was more suitable and specific than the spleen in estimating and representing the systemic immune response in allergic conjunctivitis, akin to the localized inflammation seen in human allergic conjunctivitis. Because the lymph from bulbar conjunctiva and eyelid contains soluble antigens and arrives at the cervical lymph nodes via afferent lymphatic vessels, cervical lymph nodes containing T helper cells against the allergens reflect ocular allergy activity well. Then, we developed an animal model of

Investigative Ophthalmology & Visual Science

Downloaded From: http://iovs.arvojournals.org/pdfaccess.ashx?url=/data/Journals/IOVS/935164/ on 05/17/2016

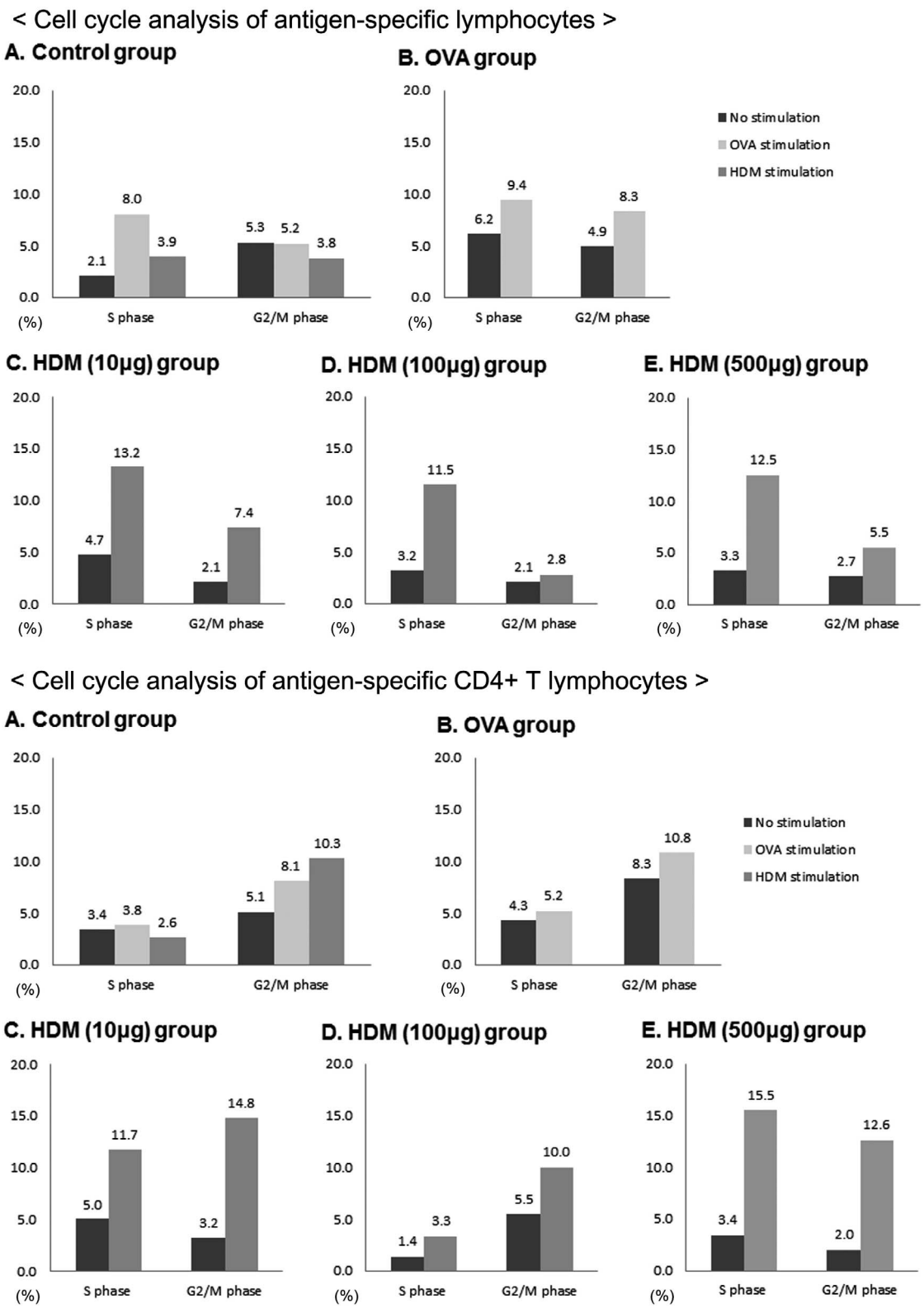


**Figure 4.** Quantitative cell cycle analysis of antigen-specific lymphocytes and antigen-specific $CD4^+$ T lymphocytes in cultures of cervical lymph node lymphocytes with/without antigen stimulation (BrdU ELISA assay). Bromodeoxyuridine is incorporated into newly synthesized DNA by cells entering and progressing through the S (DNA replication) phase of the cell cycle. In the OVA-immunized group, the cervical lymphocyte population of S-phase cells was increased in in vitro culture with OVA (6.2% vs. 9.4%). In all HDM-immunized mice, S-phase (13.2%, 11.5%, and 12.5% for the 10, 100, and 500 μg groups, respectively) of cervical lymphocyte population was significantly increased compared with 4.7%, 3.2%, and 3.3% of the population (no stimulation), respectively, after HDM stimulation. These demonstrated that antigen-specific lymphocytes in cervical lymph nodes of all immunized groups are actively proliferated after allergen stimulation. Similarly, the frequency of $CD4^+$ T cells that incorporated BrdU (S-phase) was 4.3% without OVA stimulation but was 5.2% with OVA stimulation in the cervical lymphocytes culture from the OVA-immunized group. The

Investigative Ophthalmology & Visual Science

Downloaded From: http://iovs.arvojournals.org/pdfaccess.ashx?url=/data/Journals/IOVS/935164/ on 05/17/2016

frequency of CD4$^+$ T cells in S-phase was 5.02%, 1.37%, and 2.01% without HDM stimulation but was increased to 11.7%, 3.33%, and 15.5%, respectively, with HDM stimulation in the HDM-immunized groups (10, 100, and 500 μg). These demonstrated that antigen-specific CD4$^+$ lymphocytes in cervical lymph nodes of all immunized groups are actively proliferated after allergen stimulation.

allergic conjunctivitis using *D. pteronyssinus* extract, a common perennial allergy-causing HDM allergen, in BALB/c mice.

Here, we provide strong evidence for the development of allergic conjunctivitis induced by *D. pteronyssinus* extract, corresponding to the early and late phases of allergic reaction, similar to that observed in human perennial and OVA-based models of allergic conjunctivitis.[28,29] Clinically, we observed that mice squatted with piloerection and presented with discharge, conjunctival hyperemia, lid swelling, and eye frowning. In addition to ocular symptoms, there was also a systemic immune response induced by the HDM extract, characterized by increased total and specific IgE titers in serum and increased proliferation of HDM-specific T lymphocytes and HDM-specific T helper cells in cervical lymph nodes, along with the production of IL-4 and IL-5.

In this study, systemic immunization using 10 μg HDM extract induced a more significant increase in Th2 cytokine and IgE than with other HDM doses. The allergic reaction induced with 500 μg HDM extract for systemic immunization in our study was greater than that observed at 5 μg HDM extract used by Giavina-Bianchi et al.[15]

Liu et al.[14] developed a mouse model of allergic conjunctivitis using lyophilized *D. farinae polypides* extracts at 3.86 kUA/L total potency. The immunization dose and schedule used by Liu et al.[14] requires a considerable expense for performing experiments in animal models of allergic conjunctivitis because the cost of HDM allergen is expensive. Therefore, the optimal dose for immunization described in our study, wherein a lower total amount of HDM extract induces maximal allergic reaction, is a more economical solution for future immunologic and therapeutic studies of allergic conjunctivitis in a murine model.

The culture of cervical lymphocytes of immunized mice with allergen stimulation significantly increased the release of IL-4 and IL-5. Moreover, in the OVA and HDM (500 μg) groups,

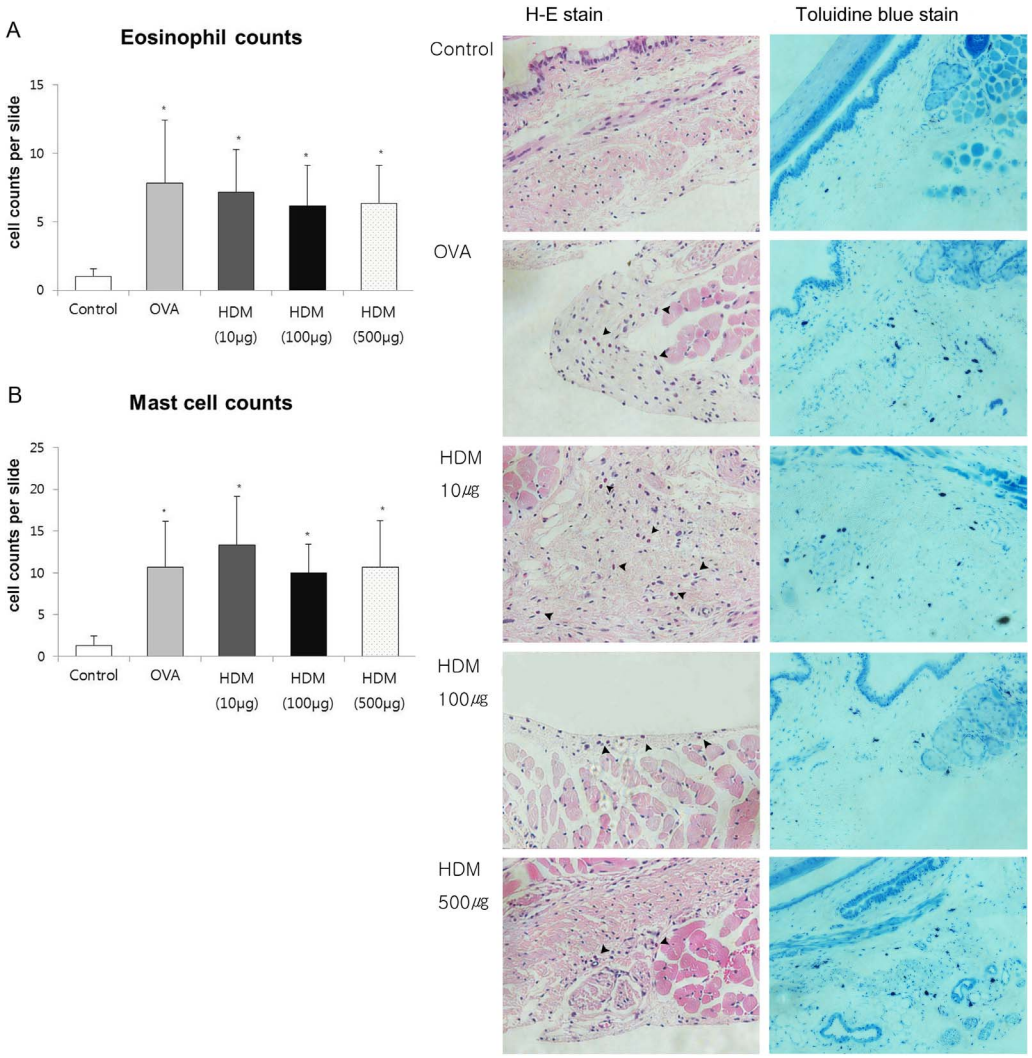


**Figure 5.** Histograms showing the relative numbers of eosinophils and mast cells per slide in conjunctiva .The conjunctival samples were isolated from mice 24 hours after the final challenge, and histopathologic analysis was performed as described in Materials and Methods. (**A**) Quantitative analysis of eosinophil infiltration into conjunctiva. (**B**) Quantitative analysis of mast cell infiltration into the conjunctiva. Data represent the mean ± SD of five independent trials. $^*P < 0.05$, compared with mice in the control group (ANOVA with Bonferroni-adjusted post hoc comparison).

Investigative Ophthalmology & Visual Science

Downloaded From: http://iovs.arvojournals.org/pdfaccess.ashx?url=/data/Journals/IOVS/935164/ on 05/17/2016

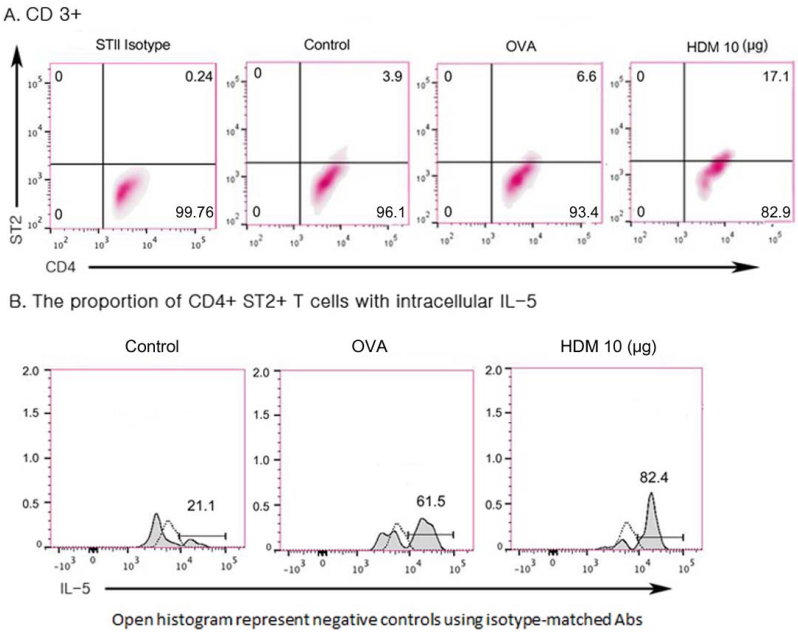


**Figure 6.** Analysis of intracellular IL-5 in $CD4^+ST2^+$ T lymphocytes. (**A**) Increase of ST2 expression in conjunctival $CD4^+$ T cells in OVA and HDM groups compared with that in the control group. (**B**) The proportion of conjunctival $CD4^+ST2^+$ T cells with intracellular IL-5 is increased in allergen-immunized mice with allergic conjunctivitis compared with that in the control group. ST2 expression, as well as the capacity of secreting IL-5, of conjunctival $CD4^+$ T cells is increased in HDM (10 μg)–immunized mice compared with that in OVA-immunized mice.

allergen-stimulated Th1 cytokine release was also higher; however, it was not significant compared with that in the control group. The interaction between Th1 and Th2 cytokines may account for the lower total IgE in serum in the HDM (500 μg) group compared with that in other HDM groups. The analysis of lymphocyte proliferation demonstrates the existence of antigen-specific lymphocytes and antigen-specific $CD4^+$ T-cell lines in cervical lymph nodes in all immunized mice. The increase of eosinophils and mast cells in conjunctiva may be interpreted based on the fact that antigen challenge of conjunctiva stimulates migration of mature DCs to the cervical lymph node, activating a Th2 cell–mediated response and B-cell proliferation, which then results in conjunctival mast cell activation and recruitment of mast cells and eosinophils to conjunctiva.[4,5]

Recent studies have highlighted the IL-33–ST2 interaction pathway as a potential target in allergic disease.[18–24] ST2 is an orphan receptor, an IL-1 receptor family member that is also known to be expressed on murine Th2 and mast cells and binds with the ligand IL-33.[18] $CD4^+$ T cells become $ST2^+$ on repeated antigenic stimulation under Th2-polarizing conditions, but in an IL-4–independent mechanism, and the cross-linking of IL-33 and ST2 induces proliferation and cytokine production in Th2, but not Th1, cells.[18] IL-33 is released by epithelial barrier tissue damage induced by different environmental stimuli such as airborne allergens, viruses, and air pollutants, and its cross-linking with ST2 on Th2 lymphocytes, mast cells, and eosinophils induces Th2 cytokine release (especially IL-5 and IL-13), which, in turn, plays an important role in allergic dermatitis, asthma, rhinitis, and allergic conjunctivitis.[18–22] In our murine model of allergic conjunctivitis, ST2 expression on the membranes of conjunctival $CD4^+$ T lymphocytes was increased in OVA- or HDM-immunized mice. The capacity for IL-5 production was especially increased in conjunctival $CD4^+ST2^+$ T lymphocytes of HDM-immunized mice. These data suggest that activated conjunctival $CD4^+$ T lymphocytes express ST2 after repeated ocular allergen challenge, and the subsequent increase in intracellular IL-5 may play a critical role in recruiting eosinophil into conjunctiva in mice with HDM-induced allergic conjunctivitis. This suggests that the ST2–IL-33 interaction, an IL-4–independent pathway, may contribute to the development of the murine model with HDM allergic conjunctivitis. This mechanism differs from the classical allergen-specific IgE-mediated allergic immunologic pathway. Further studies that focus on the association between conjunctival $CD4^+ST2^+$ T lymphocytes and release of other Th2 cytokines, such as IL-4, –5, and –9 and IL-13, and that investigate the IL-33–ST2 interaction in the conjunctiva of mice with allergic conjunctivitis may help identify new therapeutic targets in HDM allergic conjunctivitis.

In the acute phase of allergic conjunctivitis, type 1 hypersensitivity by mast cells is a main mechanism of allergic response, but in the chronic phase of allergic conjunctivitis or perennial allergic conjunctivitis, eosinophils and mast cells play a main role in making the allergic response. Therefore, this model, which showed increased eosinophils and mast cells in the conjunctiva and HDM-specific Th cells in cervical lymph nodes, can be used for future models of allergic conjunctivitis induced by HDM. The use of a mast cell stabilizer, steroid (immune inhibitor), and the lubricant as artificial tear (to reduce conjunctiva mucosal damage) can be helpful to reduce inflammatory response from various immune modulating cells from mast cells, eosinophils, local activated Th2 ($CD4^+ST2^+$) cells in conjunctiva, and specific-allergen Th cells in cervical lymph nodes.

## Conclusions

We expect that the murine model and findings described in this report will be applicable for future studies of HDM allergic conjunctivitis. We found that the effective and optimal dose of systemic immunization in this model was 10 μg HDM extract. Data from the clinical, histopathologic, and biochemical analyses support the development of allergic conjunctivitis in our murine model, akin to that induced by OVA and observed

Investigative Ophthalmology & Visual Science

Downloaded From: http://iovs.arvojournals.org/pdfaccess.ashx?url=/data/Journals/IOVS/935164/ on 05/17/2016

in human allergic conjunctivitis. These days, the incidence of allergic conjunctivitis induced by HDMs and air pollutants like fine dust is rising. In particular, our data support further analysis of strategies focused on suppression of ST2 expression in conjunctival $CD4^+$ T lymphocytes or mast cells, attenuation of IL-33 release from conjunctival epithelial cells after ocular allergen challenge, or blocking induction of their cross-linking, as novel avenues of research in allergic conjunctivitis treatment.

## *Acknowledgments*

Supported by funding provided by the Bio and Medical Technology Development Program of the National Research Foundation funded by the Ministry of Science, Information and Communication Technology (ICT) & Future Planning, Seoul, South Korea (NRF-2013M3A9D5072551) and an unrestricted faculty research grant from Yonsei University, College of Medicine. The authors alone are responsible for the content and writing of the paper.

Disclosure: **Y.J. Lee**, None; **S.J. Han**, None; **H. Lee**, None; **J.S. Kim**, None; **K.Y. Seo**, None

## *References*

1. Bielory L. Allergic and immunologic disorders of the eye. Part II: Ocular allergy. *J Allergy Clin Immunol*. 2000;106:1019–1032.
2. Hansen TE, Evjenth B, Holt J. Increasing prevalence of asthma, allergic rhinoconjunctivitis and eczema among schoolchildren: Three surveys during the period 1985-2008. *Acta Paediatr*. 2013;102:47–52.
3. Broide DH. Molecular and cellular mechanisms of allergic disease. *J Allergy Clin Immunol*. 2001;108:S65–71.
4. Fukuda K, Ohbayashi M, Morohoshi K, Zhang L, Liu FT, Ono SJ. Critical role of IgE-dependent mast cell activation in a murine model of allergic conjunctivitis. *J Allergy Clin Immunol*. 2009; 124:827–833.
5. Miyazaki D, Tominaga T, Yakura K, et al. Conjunctival mast cell as a mediator of eosinophilic response in ocular allergy. *Mol Vis*. 2008;14:1525–1532.
6. Saban DR, Calder V, Kuo CH, et al. New twists to an old story: novel concepts in the pathogenesis of allergic eye disease. *Curr Eye Res*. 2013;38:317–330.
7. Stern ME, Siemasko KF, Niederkorn JY. The Th1/Th2 paradigm in ocular allergy. *Curr Opin Allergy Clin Immunol*. 2005;5: 446–450.
8. McGill JI, Holgate ST, Church MK, Anderson DF, Bacon A. Allergic eye disease mechanisms. *Br J Ophthalmol*. 1998;82: 1203–1214.
9. Hara Y, Shoji J, Hori S, et al. Evaluation of eosinophilic inflammation in a novel murin atopic keratoconjunctivitis model induced by crude dermatophagoides farina antigen. *Allergol Int*. 2012;61:331–338.
10. Ree HI, Jeon SH, Lee IY, Hong CS, Lee DK. Fauna and geographical distribution of house dust mites in Korea. *Korean J Parasitol*. 1997;35:9–17.
11. Jeong KY, Park JW, Hong CS. House dust mite allergy in Korea: The most important inhalant allergen in current and future. *Allergy Asthma Immunol Res*. 2012;4:313–325.
12. Thomas WR, Heinrich TK, Smith WA, Hales BJ. Pyroglyphid house dust mite allergens. *Protein Pept Lett*. 2007;14:943–953.
13. Groneberg DA, Bielory L, Fischer A, et al. Animal models of allergic and inflammatory conjunctivitis. *Allergy*. 2003;58(11): 1101–1113.
14. Liu LL, Guo DD, Liang QX, et al. Sublingual immunotherapy for experimental allergic conjunctivitis in a murine model induced by *Dermatophagoides farinae* allergen. *Int Arch Allergy Immunol*. 2013;161:205–212.
15. Giavina-Bianchi P, Kalil J, Rizzo LV. Development of an animal model for allergic conjunctivitis: influence of genetic factors and allergen concentration on immune response. *Acta Ophthalmol*. 2008;86:670–675.
16. Niederkorn JY. Immune regulatory mechanisms in allergic conjunctivitis: insights from mouse models. *Curr Opin Allergy Clin Immunol*. 2008;8:472–476.
17. Kubo M, Ozaki A, Tanaka S, Okamoto M, Fukushima A. Role of suppressor of cytokine signaling in ocular allergy. *Curr Opin Allergy Clin Immunol*. 2006;6:361–366.
18. Meisel C, Bonhagen K, Lohning M, et al. Regulation and function of T1/ST2 expression on CD4+ T cells: induction of type 2 cytokine production by T1/ST2 cross-linking. *J Immunol*. 2001;166:3143–3150.
19. Liew FY, Pitman NI, McInnes IB. Disease-associated functions of IL-33: the new kid in the IL-1 family. *Nat Rev Immunol*. 2010;10:103–110.
20. Savinko T, Karisola P, Lehtimaki S, et al. ST2 regulates allergic airway inflammation and T-cell polarization in epicutaneously sensitized mice. *J Invest Dermatol*. 2013;133:2522–2529.
21. Matsuba-Kitamura S, Yoshimoto T, Yasuda K, et al. Contribution of IL-33 to induction and augmentation of experimental allergic conjunctivitis. *Int Immunol*. 2010;22:479–489.
22. Rogala B, Gluck J. The role of interleukin-33 in rhinitis. *Curr Allergy Asthma Rep*. 2013;13:196–202.
23. Nakae S, Morita H, Ohno T, Arae K, Matsumoto K, Saito H. Role of interleukin-33 in innate-type immune cells in allergy. *Allergol Int*. 2013;62:13–20.
24. Holgate ST. Trials and tribulations in identifying new biologic treatments for asthma. *Trends Immunol*. 2012;33:238–246.
25. Jeong KY, Choi SY, Lee JH, et al. Standardization of house dust mite extracts in Korea. *Allergy Asthma Immunol Res*. 2012;4: 346–350.
26. Barequet IS, Platner E, Sade K, et al. Topical tacrolimus for the management of acute allergic conjunctivitis in a mouse model. *Graefes Arch Clin Exp Ophthalmol*. 2013;251:1717–1721.
27. Nakamura T, Toda M, Ohbayashi M, Ono SJ. Detailed criteria for the assessment of clinical symptoms in a new murine model of severe allergic conjunctivitis. *Cornea*. 2003;22:S13–18.
28. Chung SH, Nam KH, Kweon MN. *Staphylococcus aureus* accelerates an experimental allergic conjunctivitis by Toll-like receptor 2-dependent manner. *Clin Immunol*. 2009;131:170–177.
29. Dart JK, Buckley RJ, Monnickendan M, Prasad J. Perennial allergic conjunctivitis: definition, clinical characteristics and prevalence. A comparison with seasonal allergic conjunctivitis. *Trans Ophthalmol Soc U K*. 1986;105(Pt 5):513–520.



Downloaded From: http://iovs.arvojournals.org/pdfaccess.ashx?url=/data/Journals/IOVS/935164/ on 05/17/2016