ARTICLE IN PRESS

Allergology International xxx (2017) 1–3

Contents lists available at ScienceDirect

Allergology International

journal homepage: http://www.elsevier.com/locate/alit

Letter to the Editor

Aquagenic urticaria: Severe extra-cutaneous symptoms following cold water exposure

Dear Editor,

Aquagenic urticaria (AU) is a rare form of contact urticaria marked by pruritic wheals that rapidly develop after contact with water, regardless of its temperature or pH.[1–4] The condition is characterized by follicular wheals, generally 1–3 mm in size, with an erythematous flare on sites exposed to water.[1,2] AU usually subsides spontaneously within 30–60 min.[2,3] Although most cases have been sporadic, familial cases have been reported.[5,6] AU accompanied by extra-cutaneous symptoms has rarely been reported.[4,6] To our knowledge, there is only one published case of AU with extra-cutaneous symptoms including shortness of breath, wheezing, dizziness and headache.[6] Herein we report the first case of AU presenting with severe extra-cutaneous symptoms, the severity of which correlated closely with water temperature. The patient was successfully treated with loratadine.

An 8-year-old girl presented with a history of shortness of breath, syncope and urticaria induced by cold water. Her parents had no history of anaphylaxis, urticaria, or atopic dermatitis. The patient's symptoms developed 20 min after contact with cold water without other inducers including exercise or food ingestion. Follicular wheals with erythematous flare were restricted to her legs where exposed to water. The patient also developed shortness of breath and syncope. These symptoms persisted for 30 min and subsided spontaneously. These symptoms fulfilled the clinical criteria for diagnosing anaphylaxis and were well-suited to the moderate grade.[7,8] The patient had experienced similar episodes 3 times. These episodes of anaphylaxis and urticaria developed only after contact with cold water; only slight perifollicular wheals had occasionally appeared after bathing in warm water. Physical and laboratory examinations showed no abnormalities. The patient had no coexisting inducible urticaria, including cold, heat, or cholinergic urticaria, as demonstrated by negative results on the ice cube test (10 min; method avoiding contact with water[6]) and exercise provocation test continued until sweating. AU can be diagnosed with a provocation test using a water-soaked compress,[2,4,6] therefore, a provocation test using a compress soaked in 35–37 °C water was performed on the patient's trunk. Within 20 min after application of the compress, follicular wheals with erythematous halos occurred within the contact area (Fig. 1a, b).

To confirm the diagnosis of AU in the present case, another provocation test using water in the bucket was performed.[5,6] After 20 min of contact with 35–37 °C water in the bucket, the patient developed many follicular wheals with erythematous halos (Fig. 1c). Interestingly, the patient developed similar follicular wheals with erythematous halos after only 5 min of contact with 4 °C water in the bucket (Fig. 1d). The patient had no wheals after 5 min of contact with 35–37 °C water in the bucket. Some reports have suggested that removal of the stratum corneum enhances the severity of the skin reaction.[6,9,10] Similarly, follicular wheals with erythematous halos appeared 10 min after application of a compress soaked in 35–37 °C water only at the site that had been pretreated with acetone prior to the challenge (Fig. 2a). No wheals occurred on the site that was not pretreated with acetone within 10 min (Fig. 2b). Acetone treatment without application of the water-soaked compress did not result in wheals. These results indicate that removal of the stratum corneum enhanced the development of AU. Because some reports have suggested the involvement of histamine in AU,[4,5,9] we performed provocation tests after oral administration of loratadine (10 mg once daily). After loratadine administration, wheals did not occur within 20 min either with or without acetone pretreatment on skin exposed to compresses soaked in 35–37 °C water (Fig. 2c, d). Moreover, wheals were sparse after 20 min of contact with 35–37 °C water in the bucket. She is in good condition without recurrence 15 months after loratadine administration.

AU is a rare inducible urticaria; diagnosis is based on clinical history and water provocation tests.[1–6,9,10] Extra-cutaneous symptoms of AU have rarely been reported.[4,6] This is the first report of AU accompanied by severe extra-cutaneous symptoms, the severity of which correlated closely with water temperature. Our patient showed a positive reaction after 5 min of contact with 4 °C water in the bucket (Fig. 1d), which was much earlier than with 35–37 °C water in the bucket (20 min; Fig. 1c). These results indicate that lower water temperature may have exacerbated symptoms in our patient. Therefore, we speculate that our patient developed intense symptoms, including shortness of breath and syncope, only when exposed to cold water.

The pathomechanism of AU remains unclear.[6] Several hypotheses have been suggested.[1–3,5,6] One is that the interaction of water with sebum or sebaceous might play a role.[3] Another is that a water-soluble epidermis antigen might be involved.[3] There is also a hypothesis that water acts as a carrier for an epidermal or dermis antigen.[4] We speculate that cold water might make the association of antigens with water easier or mast cells might degranulate easier in cold environment in our patient. Some reports have described the importance of removal of the stratum corneum in the

Peer review under responsibility of Japanese Society of Allergology.

https://doi.org/10.1016/j.alit.2017.10.007
1323-8930/Copyright © 2017, Japanese Society of Allergology. Production and hosting by Elsevier B.V. This is an open access article under the CC BY-NC-ND license (http://creativecommons.org/licenses/by-nc-nd/4.0/).

Please cite this article in press as: Fukumoto T, et al., Aquagenic urticaria: Severe extra-cutaneous symptoms following cold water exposure, Allergology International (2017), https://doi.org/10.1016/j.alit.2017.10.007

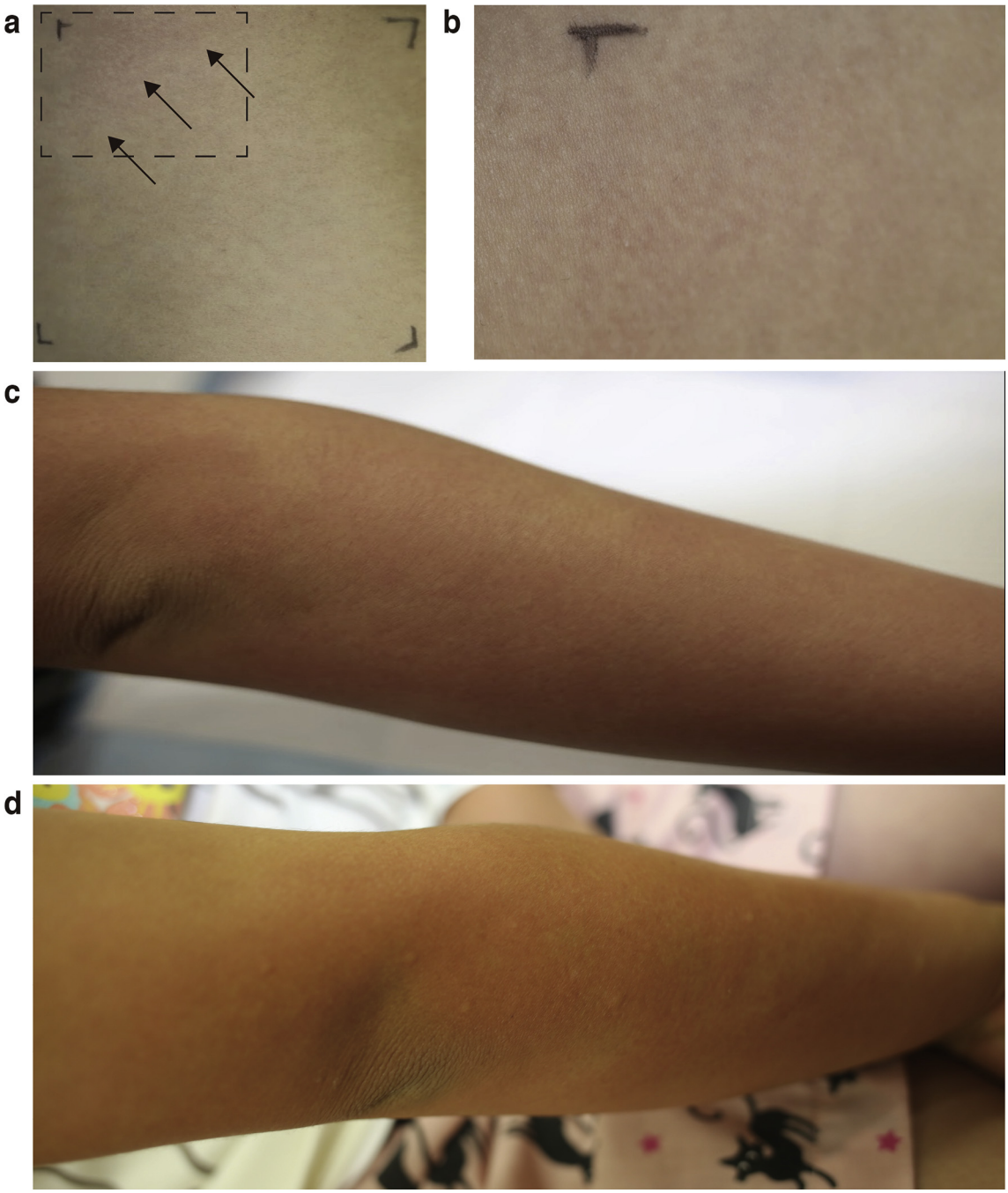

Fig. 1. Provocation tests. (**a**) Positive response on back after 20-min application of compress soaked in 35–37 °C water (arrows). Black square indicates follicular wheals with erythematous halos. (**b**) Enlargement of square in 1(**a**). (**c**) (**d**) Scattered c lesions with erythematous halos on patient's arm (**c**) after 20-min exposure to 35–37 °C water and (**d**) after 5-min exposure to 4 °C water in the bucket.

development of AU.[2,6,9,10] In our patient, removal of the stratum corneum with acetone pretreatment caused clear wheals in shorter time (10 min) than without acetone pretreatment (20 min). This finding suggests that removal of the stratum corneum enhances the severity of the reaction because of the possibility of a close association between water and components in the epidermis or dermis.

Treatment of AU remains a discussion. Although AU has been reportedly mediated in both a histamine-dependent and independent manner, antihistamines have been recommended as the first-line treatment.[2–6,9] Barrier creams, ultraviolet radiation monotherapy, and ultraviolet therapy in combination with antihistamines are also reported treatments for AU.[4,6] The patient's condition has been successfully controlled with loratadine. This result supports the hypothesis that histamine is involved in AU. One limitation of this study is that we could not perform the provocation test developing severe extra-cutaneous symptoms because her parents did not consent. The other is that serum histamine levels were not examined. Although more cases are necessary to validate our hypothesis, this case highlights the novel possibility that a part of AU may be exacerbated by cold water temperature.

Please cite this article in press as: Fukumoto T, et al., Aquagenic urticaria: Severe extra-cutaneous symptoms following cold water exposure, Allergology International (2017), https://doi.org/10.1016/j.alit.2017.10.007

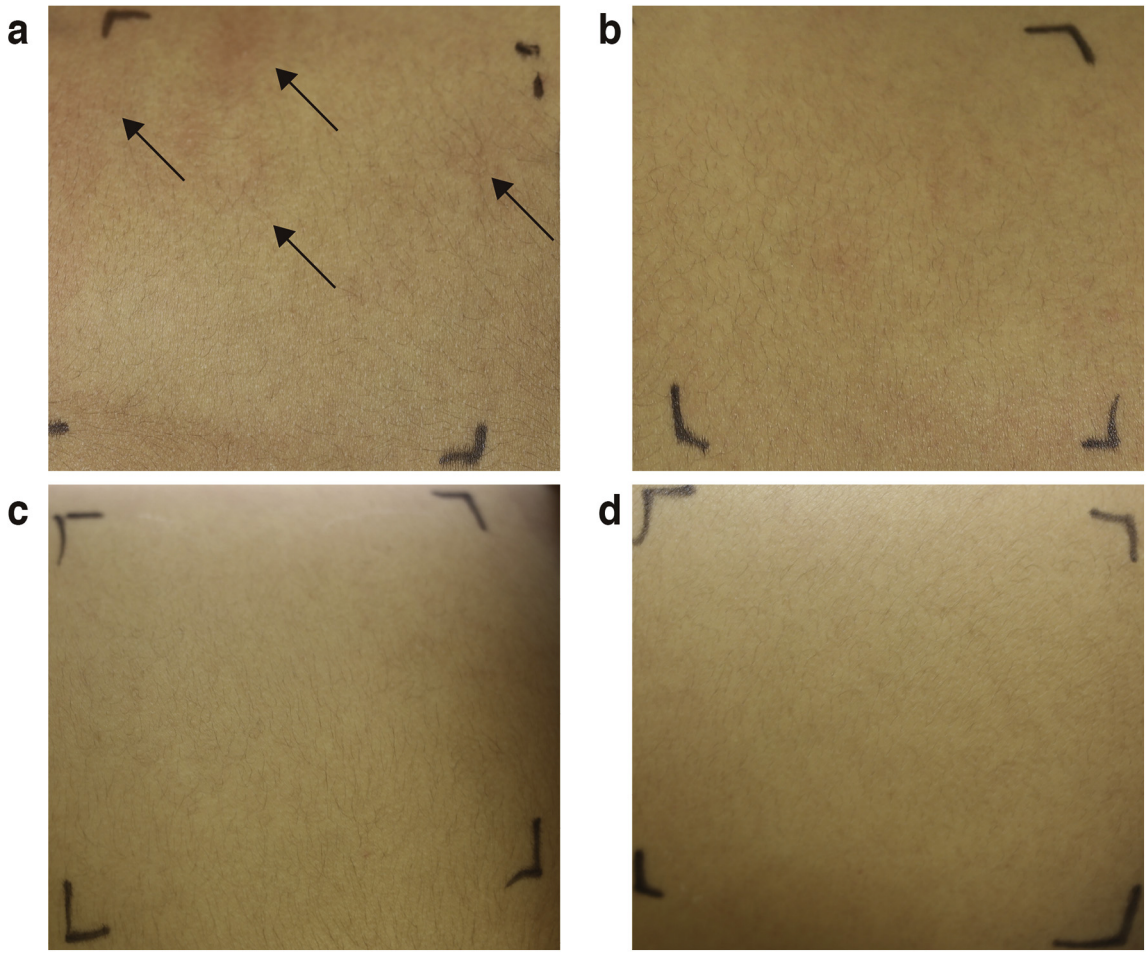

Fig. 2. Provocation tests with and without acetone pretreatment. (**a**) (**b**) Back skin after 10-min application of compress soaked in 35–37 °C water. (**a**) Positive response with acetone pretreatment (arrows). (**b**) Negative response without acetone pretreatment. (**c**) (**d**) Negative response with loratadine intake after 20-min application of compress soaked in 35–37 °C water without (**c**) and with (**d**) acetone pretreatment.

Conflict of interest

The authors have no conflict of interest to declare.

Takeshi Fukumoto [1], Kanako Ogura, Atsushi Fukunaga *, Chikako Nishigori

Division of Dermatology, Department of Internal Related, Kobe University Graduate School of Medicine, Kobe, Japan

* Corresponding author. Division of Dermatology, Department of Internal Related, Kobe University Graduate School of Medicine, 7-5-1 Kusunoki-cho, Chuo-ku, Kobe 650-0017, Japan.
E-mail address: atsushi@med.kobe-u.ac.jp (A. Fukunaga).

References

1. Shelley WB, Rawnsley HM. Aquagenic urticaria. Contact sensitivity reaction to water. *JAMA* 1964;**189**:895–8.
2. Rothbaum R, McGee JS. Aquagenic urticaria: diagnostic and management challenges. *J Asthma Allergy* 2016;**9**:209–13.
3. Wang F, Zhao YK, Luo ZY, Gao Q, Wu W, Sarkar R, et al. Aquagenic cutaneous disorders. *J Dtsch Dermatol Ges* 2017;**15**:602–8.
4. Magerl M, Altrichter S, Borzova E, Giménez-Arnau A, Grattan CE, Lawlor F, et al. The definition, diagnostic testing, and management of chronic inducible urticarias – the EAACI/GA(2) LEN/EDF/UNEV consensus recommendations 2016 update and revision. *Allergy* 2016;**71**:780–802.
5. Bayle P, Gadroy A, Messer L, Bazex J. Localized aquagenic urticaria: efficacy of a barrier cream. *Contact Dermatitis* 2003;**49**:160–1.
6. Luong KV, Nguyen LT. Aquagenic urticaria: report of a case and review of the literature. *Ann Allergy Asthma Immunol* 1998;**80**:483–5.
7. Sampson HA, Muñoz-Furlong A, Campbell RL, Adkinson Jr NF, Bock SA, Branum A, et al. Second symposium on the definition and management of anaphylaxis: summary report–second national institute of allergy and infectious disease/food allergy and anaphylaxis network symposium. *J Allergy Clin Immunol* 2006;**117**:391–7.
8. Brown SG. Clinical features and severity grading of anaphylaxis. *J Allergy Clin Immunol* 2004;**114**:371–6.
9. Sibbald RG, Black AK, Eady RA, James M, Greaves MW. Aquagenic urticaria: evidence of cholinergic and histaminergic basis. *Br J Dermatol* 1981;**105**:297–302.
10. Sanada S, Yamamura Y, Hide M, Yamamoto S. A case of aquagenetic urticaria. *Rinsho Derma* 2000;**42**:1023–6.

Received 20 September 2017
Received in revised form 13 October 2017
Accepted 17 October 2017
Available online xxx

[1] ORCID: http://orcid.org/0000-0003-0364-711X

Please cite this article in press as: Fukumoto T, et al., Aquagenic urticaria: Severe extra-cutaneous symptoms following cold water exposure, Allergology International (2017), https://doi.org/10.1016/j.alit.2017.10.007