Internal Medicine
The Japanese Society of Internal Medicine

doi: 10.2169/internalmedicine.0300-17
Intern Med Advance Publication
http://internmed.jp

【 CASE REPORT 】

A Case of Longstanding IgG4-related Ophthalmic Disease Dramatically Improved after Steroid Therapy

Yoko Hirata[1], Jiro Fukae[1], Akihiro Nishida[1], Shinsuke Fujioka[1], Mokoto Hamasaki[2], Masanari Nonokuma[3] and Yoshio Tsuboi[1]

Abstract:
A 61-year-old man was admitted to our hospital because of decreased visual acuity. On admission, he had marked blepharoedema, conjunctival injection, exophthalmos, diplopia, and blurred vision. He also had bronchial asthma and urinary retention requiring urethral catheterization. His serum immunoglobulin (Ig) G4 level was elevated to 1,830 U/mL. Fluorodeoxyglucose-positron emission tomography revealed an abnormal uptake in multiple organs. A histopathological examination of the salivary gland revealed IgG4-positive plasma cell infiltration, leading to a diagnosis of IgG4-related ophthalmic disease. After initiating steroid therapy, his longstanding ophthalmic, respiratory, and urinary symptoms dramatically improved. In IgG4-related disease, steroid therapy should be considered even if patients have longstanding symptoms.

Key words: IgG4-related disease, plasma cell, biopsy, FDG-PET, steroid therapy

(Intern Med Advance Publication)
(DOI: 10.2169/internalmedicine.0300-17)

Introduction

IgG4-related disease (IgG4RD) is a systemic disease associated with hyperplasia of the tissues and tumor-like formation. The histopathological characteristics of IgG4RD include extensive infiltration of IgG4-positive plasma cells with fibrosis (1, 2). IgG4RD affects various organs, such as the lymph nodes, pancreas, kidney, and retroperitoneal tissues. Ocular adnexal lymphoproliferative disorders are particularly frequently referred to as IgG4-related ophthalmic disease (IgG4ROD) (3). We herein report a patient suffering from longstanding IgG4ROD-related symptoms who exhibited dramatic improvement in all of his symptoms after undergoing steroid therapy.

Case Report

The patient first became aware of slight exophthalmos and blepharoedema of his right eye at the age of 40. Swelling of the right submandibular lymph node appeared at the age of 51. A histopathological examination of a lymph node biopsy showed nonspecific inflammation without any malignant findings. At the same time, he also became aware of blurred vision. At the age of 60, he developed urinary retention and needed urethral catheterization. While he was also diagnosed with bronchial asthma because of a persistent cough, treatment with a β2-agonist did not resolve his symptoms. At the age of 61, in addition to having bilateral exophthalmos, blepharoedema, and conjunctival injection, it became impossible for him to perform normal daily activities due to his significantly decreased visual acuity. As a result, he was admitted to our hospital. On admission, he had marked blepharoedema, conjunctival injection, exophthalmos, diplopia, and decreased visual acuity. There was no vascular bruit around the eyes and no jaundice in the ocular conjunctiva. His visual acuity was 0.1 in the right eye and 0.125 in the left, and he had bilateral abducens palsy. A funduscopic examination found no abnormal findings, such as papilledema, ischemia, or atrophic change. Muscle weakness and sensory disturbance were not observed. However, he did exhibit bilateral swelling of the submandibular glands, and he developed urinary retention that subsequently required urethral catheterization. He never had persistent abdominal

[1]Department of Neurology, Fukuoka University, Japan, [2]Department of Pathology, Fukuoka University, Japan and [3]Department of Radiology, Fukuoka University, Japan
Received: October 4, 2017; Accepted: January 29, 2018; Advance Publication by J-STAGE: May 18, 2018
Correspondence to Dr. Yoshio Tsuboi, tsuboi@cis.fukuoka-u.ac.jp

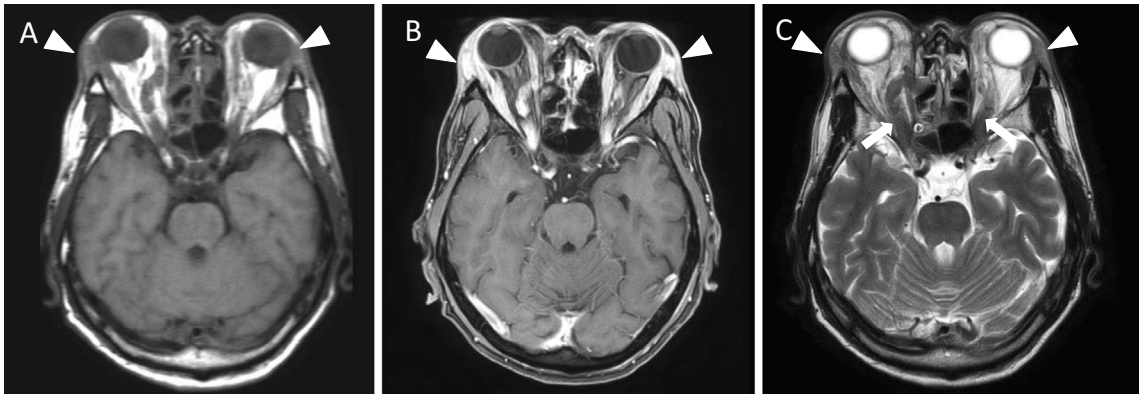

Figure 1. Brain magnetic resonance imaging (MRI). (A) T1-weighted image, (B) T1-weighted image with enhancement, (C) T2-weighted image. The T1-weighted image shows bilateral exophthalmos (A). The supraorbital nerve enlargement and extraocular muscles were enhanced with gadolinium (B). The T2-weighted image shows enlargement of the bilateral supraorbital nerve and extraocular muscles (arrows in C). Panels (A) to (C) show swelling of the bilateral lacrimal glands. There was no hypertrophic pachymeningitis in the T1-weighted image with enhancement (B).

pain.

The laboratory findings were follows: leukocyte count 8,200/μL (neutrophils, 55.5%; lymphocytes, 26.9%; eosinophils, 10.0%; basophils, 2.3%), C-reactive protein (CRP) 0.03 mg/dL, and an erythrocyte sedimentation rate of 30 mm/h. The serum IgG level was 3,277 U/mL (normal range, 870-1,700 U/mL), and the serum IgG4 level was 1,830 U/mL (normal, 4-108 U/mL). He also exhibited an elevation in his soluble interleukin (IL)-2 receptor level to 1,075 U/mL (normal, 122-496 U/mL). The thyroid function was normal. Autoantibodies, including anti-TPO, anti-thyroglobulin antibodies, antinuclear antibodies, PR3-ANCA, and MPO-ANCA, were all negative. The findings of cerebrospinal fluid examinations were normal. A respiratory function test indicated obstructive ventilatory impairment (%VC: 126.5%, FEV1.0%: 64.5%). Brain magnetic resonance imaging (MRI) showed exophthalmos of both eyes, with swelling of the lacrimal glands and thickening of all extraocular muscles (Fig. 1A-C). Furthermore, the right trigeminal nerve and its branches were markedly enlarged, with part of the nerve exhibiting enhancement with gadolinium. T1-weighted contrast MRI did not indicate the presence of hypertrophic pachymeningitis (Fig. 1B). ^{18}F-fluorodeoxyglucose (FDG)-positron emission tomography/computed tomography (PET/CT) showed an abnormal accumulation in the optic nerves, submandibular glands, mediastinal hilar lymph node, bronchial tubes, pancreas, aorta, and prostate (Fig. 2A-F).

A histopathological examination of the biopsied small salivary gland revealed the infiltration of numerous plasma cells (Fig. 3A). Immunohistochemical staining (anti-IgG antibody [SIG-3411]; BioLegend Inc., [MA, USA]; anti-IgG4 antibody (MAB1313); Chemicon, [CA, USA]) revealed a high frequency of anti-IgG4-positive cells. The ratio of plasma cells to the IgG4/IgG was 45% (Fig. 3B and C). In addition, more than 100 IgG4-positive plasma cells were identified in a single high-power field (Fig. 3C). We also performed the same examinations using the submandibular lymph node that had been biopsied at 51 years of age, with the results showing IgG4-positive cells scattered around the germinal center and the marginal region around the follicle (Fig. 3E). The IgG4/IgG-positive plasma cell ratio was 48.7% (Fig. 3E and F).

Three major criteria are used to diagnose IgGROD (3). The first requires that imaging studies show an enlargement of the lacrimal gland, trigeminal nerve, or extraocular muscle as well as the presence of masses, enlargement, or hypertrophic lesions in various ophthalmic tissues. The second requires that histopathologic examinations show marked infiltration of lymphocytes and plasma cells and occasionally fibrosis. A germinal center is frequently observed. Furthermore, IgG4-positive plasma cells need to satisfy the following criteria: a ratio of IgG4-positive cells to IgG positive cells of 40% or above, or more than 50 IgG4-positive cells per high-power field. The third requires that a blood test show an elevated serum IgG4 level (≥135 mg/dL). Our current case was diagnosed with IgG4ROD, as he met all of the diagnostic criteria for IgG4ROD. Steroid pulse therapy was given twice at 10 days after the initial admission.

An immediate improvement was noted in the patient's blurred vision and conjunctival injection after just the first round of steroid pulse therapy. We also noted improvement in the blepharoedema in both eyes and in the visual acuity. After the treatment, his visual acuity improved to 1.2 in the right eye and 1.5 in the left. As his urinary retention also dramatically improved, he no longer needed the urethral catheterization. After the second round of steroid pulse therapy, the swelling of the submandibular glands and his coughing resolved. At this point, we started the patient on 40 mg/day oral prednisolone. Although the prednisolone dose was gradually reduced to 10 mg/day, the symptoms did not recur. One year after starting the steroid therapy, his serum IgG4 and soluble IL-2 receptor had decreased to 157

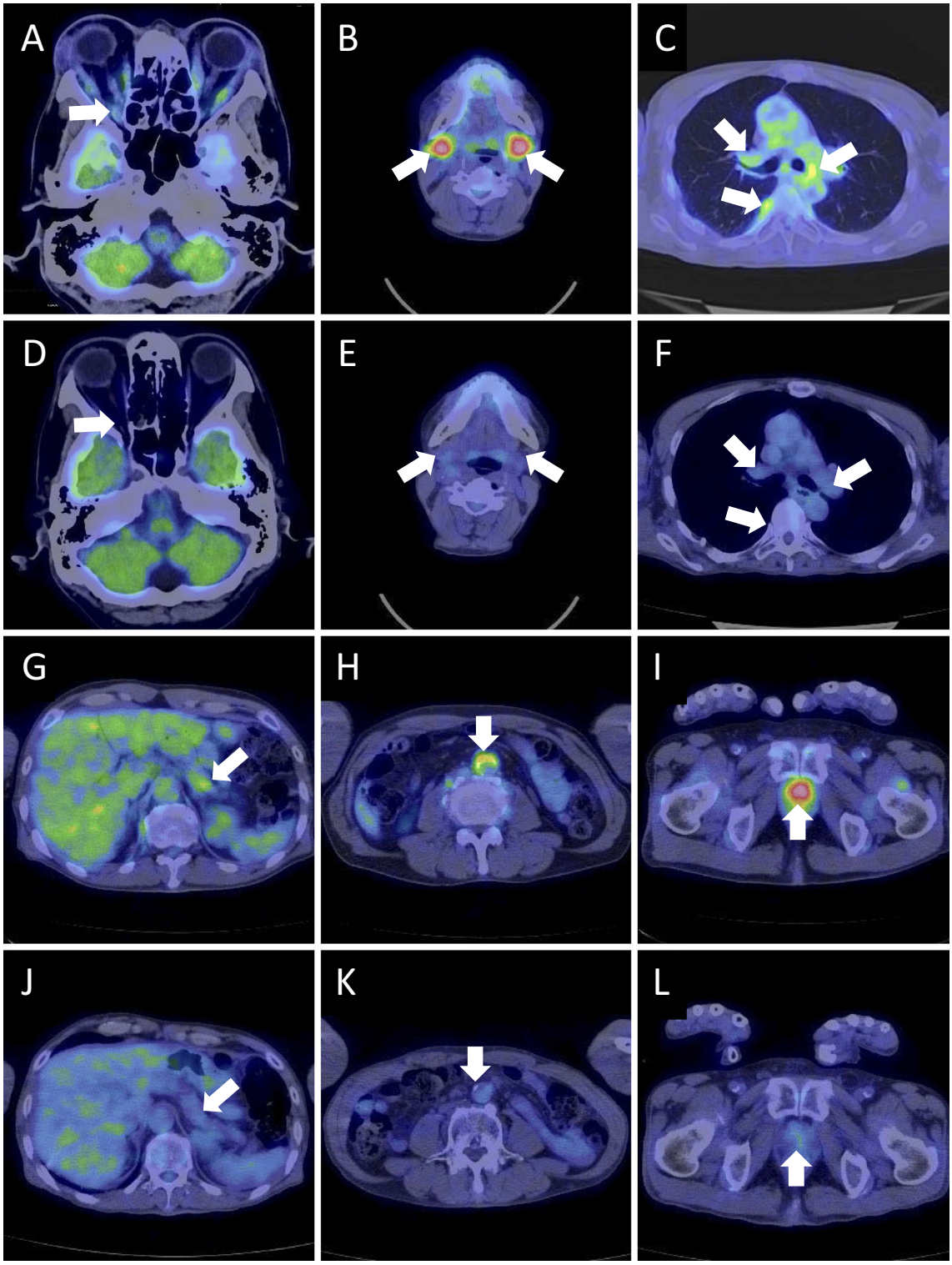

Figure 2. FDG-PET findings. FDG-PET findings before steroid therapy (A-C, G-I) and after steroid therapy (D-F, J-K). An abnormal uptake of FDG was seen in the bilateral optic nerve (arrow in A), submandibular glands (arrows in B), bronchus and lymph node (arrows in C), part of the pancreas (arrow in G), aorta (arrows in H), and prostate (arrows in I), suggesting a general inflammatory reaction. After steroid therapy, the abnormal FDG uptake disappeared in all of the organs (arrows in D-F, J-L).

mg/dL and 290 U/mL, respectively. Furthermore, ^{18}F-FDG-PET/CT showed that the abnormal accumulation had disappeared in all organs (Fig. 2D-F, J-L).

Discussion

IgG4ROD is clinically characterized by exophthalmos as-

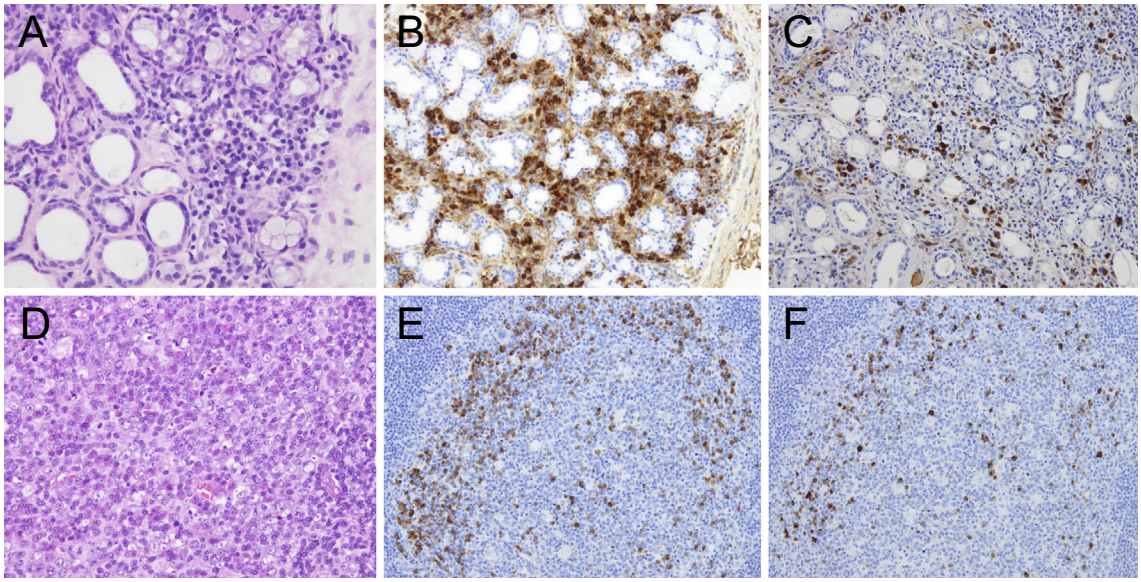

Figure 3. Histopathological studies of the lymph nodes and minor salivary glands. Histopathological findings of the minor salivary glands at the age of 61 (A-C): A, Hematoxylin and Eosin (H&E) staining (×200); B, IgG immunostaining (×200); C, IgG4 immunostaining (×200). Numerous plasma cells infiltrated around the minor salivary glands (A). The IgG4/IgG-positive plasma cell ratio was 45% (B and C), with more than 100 IgG4-positive plasma cells found in each high-power field (C). Histopathological findings of the lymph node at the age of 51 (D-F): D, H&E staining (×400); E, IgG immunostaining (×100); F, IgG4 immunostaining (×100). Panel (D) shows reactive follicular hyperplasia with plasma cells. IgG-positive plasma cells were found in the germinal center and marginal zone in the lymph node (E). The IgG4/IgG-positive plasma cell ratio was 48.7% (E and F), with approximately 30 IgG4-positive plasma cells found in each high-power field (F).

sociated with swelling of the lacrimal gland, intra-orbital nerve branches, and extraocular muscles (4). Visual impairment is rare in IgG4ROD, having only been reported in approximately 9% of the patients (4). Although the exact mechanism underlying the visual impairment in IgG4ROD remains unknown, hypotheses that have been proposed include the compression of the optic nerves due to swelling of the extraocular muscles and nerve branches (4, 5), hypertrophic pachymeningitis or hypophysitis (6, 7), or inflammation of the soft tissues in the orbits infiltrating the optic nerves (8, 9), thereby causing uveitis (8). In IgG4-related neuropathy, inflammation associated with IgG4 was observed in both the epineurium and perineurium, but not in the nerve bundle (9, 10). Furthermore, there was no necrotizing vasculitis, such as blood vessel occlusion and fibrinoid necrosis (10). The disease duration in this case was very long, over a 21-year period, with his first symptoms noted at the age of the 40 and steroid therapy started at the age of 61. Despite the long disease duration, our patient's blurred vision improved immediately after steroid administration, suggesting that inflammation caused by IgG4 did not induce blood vessel occlusion and fibrinoid necrosis in this case.

Despite the longstanding ophthalmic symptoms, our case showed a dramatic response to steroid therapy. A previous study also reported treating patients with IgG4-related kidney disease who showed a dramatic improvement in longstanding symptoms, such as swelling of the lymph nodes, an intraorbital tumor, and an impaired kidney function, at one month after the initiation of steroid therapy (11). These findings suggest that steroid therapy can be beneficial for patients diagnosed with IgG4RD, even when they have been affected over a long period of time. Thus, steroid therapy should be recommended in IgG4RD patients regardless of the length of the disease duration. The dose recommended in these patients is an initial oral administration of prednisolone at 0.6 mg/kg/day, followed by a 10% titration every 2 weeks (12). In addition, steroid pulse therapy can also be administered in severe IgG4ROD cases involving visual impairment. Furthermore, it has also been suggested that immunosuppressant and/or rituximab administration should be considered as a treatment in patients with steroid-resistant IgG4ROD (8, 13).

Patients with IgG4RD may exhibit respiratory symptoms due to inflammation in the bronchi (14, 15). Furthermore, prostatitis has been shown to be an IgG4-related symptom. Among 117 men with IgG4-associated disease, 9 (7.7%) exhibited complications due to IgG4-related prostatitis (16). All of the patients in that study with IgG4-related prostatitis showed improvement after receiving steroid administration. In our current case, FDG-PET/CT revealed an abnormal uptake in the prostate. Since the urinary retention in our case disappeared soon after undergoing the steroid therapy, this suggested that the prostatitis had been due to IgG4-induced

inflammation. Furthermore, FDG-PET in this case also showed an abnormal accumulation in the pancreas and aorta. IgG4-related inflammation has been reported to also cause autoimmune pancreatitis and periaortitis (2, 17). Autoimmune pancreatitis frequently induces painless jaundice due to the narrowing of the intrapancreatic common bile duct, while periaortitis usually induces abdominal pain due to inflammation in the adventitia of the aorta. FDG-PET demonstrated that multiple organs, including the pancreas and the aorta, were involved without any related symptoms or laboratory abnormalities, suggesting that these lesions might have been subclinical in this case.

After undergoing steroid therapy, an excellent response was observed in our patient who had been affected with IgG 4ROD over a long 21-year period. Thus, physicians need to consider IgG4RD as a differential diagnosis for patients who longitudinally manifest symptoms indicative of multiple organ involvement. In patients with IgG4-related disease, steroid therapy should be considered even if these patients are known to have longstanding symptoms.

The authors state that they have no Conflict of Interest (COI).

References

1. Umehara H, Okazaki K, Masaki Y, et al. A novel clinical entity, IgG4-related disease (IgG4RD): general concept and details. Mod Rheumatol **22**: 1-14, 2012.
2. Stone JH, Zen Y, Deshpande V. IgG4-related disease. N Engl J Med **366**: 539-551, 2012.
3. Goto H, Takahira M, Azumi A; Japanese Study Group for IgG4-Related Ophthalmic Disease. Diagnostic criteria for IgG4-related ophthalmic disease. Jpn J Ophthalmol **59**: 1-7, 2015.
4. Sogabe Y, Ohshima K, Azumi A, et al. Location and frequency of lesions in patients with IgG4-related ophthalmic diseases. Graefes Arch Clin Exp Ophthalmol **252**: 531-538, 2014.
5. Noshiro S, Wanibuchi M, Akiyama Y, et al. IgG4-related disease initially presented as an orbital mass lesion mimicking optic nerve sheath meningioma. Brain Tumor Pathol **32**: 286-290, 2015.
6. Sakai T, Kondo M, Yoshii S, Tomimoto H. IgG4-related disease that presented cranial, cervical, lumbar and sacral hypertrophic pachymeningitis associated with infundibulo-hypophysitis. Rinsho Shinkei Gaku (Clinical Neurology) **54**: 664-667, 2014 (in Japanese, Abstract in English).
7. Taji K, Takamura T, Mouri K, et al. The case of lymphocytic hypophysitis during the development of IgG4 related disease. Nihon Naibunpi Gakkai Zasshi (Endocrine Journal) **85**: 42-44, 2009 (in Japanese).
8. Lee CS, Harocopos GJ, Kraus CL, et al. IgG4-associated orbital and ocular inflammation. J Ophthalmic Inflamm Infect **5**: 15, 2015.
9. Sogabe Y, Miyatani K, Goto R, Ishii G, Ohshima K, Sato Y. Pathological findings of infraorbital nerve enlargement in IgG4-related ophthalmic disease. Jpn J Ophthalmol **56**: 511-514, 2012.
10. Ohyama K, Koike H, Iijima M, et al. IgG4-related neuropathy: a case report. JAMA Neurol **70**: 502-505, 2013.
11. Peng T, Hu Z, Xie T, Jiang B, Zhen J, Yang X. IgG4-related disease: a case report with duration of more than 16 years and review of literature. Springerplus **5**: 804, 2016.
12. Masaki Y, Kurose N, Umehara H. IgG4-related disease: a novel lymphoproliferative disorder discovered and established in Japan in the 21st century. J Clin Exp Hematop **51**: 13-20, 2011.
13. Wallace ZS, Deshpande V, Stone JH. Ophthalmic manifestations of IgG4-related disease: single-center experience and literature review. Semin Arthritis Rheum **43**: 806-817, 2014.
14. Matsui S, Hebisawa A, Sakai F, et al. Immunoglobulin G4-related lung disease: clinicoradiological and pathological features. Respirology **18**: 480-487, 2013.
15. Yamamoto H, Yasuo M, Ito M, et al. Clinical features of central airway involvement in autoimmune pancreatitis. Eur Respir J **38**: 1233-1236, 2011.
16. Buijs J, Maillette de Buy Wenniger L, van Leenders G, et al. Immunoglobulin G4-related prostatitis: a case-control study focusing on clinical and pathologic characteristics. Urology **83**: 521-526, 2014.
17. Inoue D, Zen Y, Abo H, et al. Immunoglobulin G4-related periaortitis and periarteritis: CT findings in 17 patients. Radiology **261**: 625-633, 2011.

The Internal Medicine is an Open Access article distributed under the Creative Commons Attribution-NonCommercial-NoDerivatives 4.0 International License. To view the details of this license, please visit (https://creativecommons.org/licenses/by-nc-nd/4.0/).

© The Japanese Society of Internal Medicine
Intern Med Advance Publication