Accepted Manuscript



Nickel-related adverse reactions in the treatment of cerebral aneurysms: a literature review

Anderson Chun On Tsang, MBBS, Patrick Nicholson, MB BCh, Vitor Mendes Pereira, MD

PII: S1878-8750(18)30791-5

DOI: 10.1016/j.wneu.2018.04.073

Reference: WNEU 7909

To appear in: *World Neurosurgery*

Received Date: 16 March 2018

Revised Date: 10 April 2018

Accepted Date: 11 April 2018

Please cite this article as: Tsang ACO, Nicholson P, Pereira VM, Nickel-related adverse reactions in the treatment of cerebral aneurysms: a literature review, *World Neurosurgery* (2018), doi: 10.1016/j.wneu.2018.04.073.

This is a PDF file of an unedited manuscript that has been accepted for publication. As a service to our customers we are providing this early version of the manuscript. The manuscript will undergo copyediting, typesetting, and review of the resulting proof before it is published in its final form. Please note that during the production process errors may be discovered which could affect the content, and all legal disclaimers that apply to the journal pertain.

ACCEPTED MANUSCRIPT

Nickel-related adverse reactions in the treatment of cerebral aneurysms: a literature review

Authors:

Anderson Chun On Tsang (MBBS) [1,2], Patrick Nicholson (MB BCh)[1], Vitor Mendes Pereira (MD)[1]

Affiliations:

1. Division of Neuroradiology, Joint Department of Medical Imaging, Toronto Western Hospital, University of Toronto
2. Division of Neurosurgery, Department of Surgery, Queen Mary Hospital, The University of Hong Kong

Corresponding Author:

Anderson Chun On Tsang, Division of Neurosurgery, Department of Surgery, Queen Mary Hospital, 102 Pokfulam Road, Hong Kong. email: acotsang@hku.hk Telephone: +852 22553368

Keywords: Aneurysm, Complications, Device, Material, Nickel

ACCEPTED MANUSCRIPT

ACCEPTED MANUSCRIPT

Abstract

Background:

Nickel is the most common metal allergen and predominantly affects women. It is also the ubiquitous component in the alloys used to manufacture intracranial devices for aneurysm treatments, including aneurysm clips, self-expanding stents, flow-diverting stents and endosaccular occlusion devices. Adverse events related to nickel-allergy after deployment of such devices are uncommon but can be severe, resulting in dilemmas in the choice of treatment strategies and devices in managing nickel-sensitive patients with intracranial aneurysms.

Methods:

A literature search in accordance with the PRISMA guidelines was performed to identify studies reporting on nickel-related adverse events in cerebral aneurysm treatment. The material of the culprit devices, clinical presentation, histological feature and treatment were reviewed. The clinical consideration and management options for nickel allergy patients were discussed.

Results:

Nickel is a major component of the cobalt-alloy used in aneurysm clips, and of nitinol which is commonly used in flow-diverters and intracranial stents. There were 9 papers reporting 10 unique cases of nickel-related adverse events after aneurysm treatment. Half of the cases occurred after aneurysm clipping and the remaining 5 was attributed to endovascular devices.

ACCEPTED MANUSCRIPT

ACCEPTED MANUSCRIPT

Two presented with dermatological and 8 with neurological manifestations including cerebral edema and cerebritis.

Conclusions:

Neurological complication related to nickel in cerebral aneurysm treatments is rare but remains a concern due to the high prevalence of nickel allergy in the population. Surgeons and interventionists should consider the metal-allergy history and its potential clinical significance in managing nickel-allergic patients with aneurysms.

ACCEPTED MANUSCRIPT

ACCEPTED MANUSCRIPT

Introduction

Nickel allergy affects approximately 10-15% of the population with it more common in women.[1] It is the most common allergen identified on skin patch testing, and is associated with a history of ear piercing.[2,3] While most presented as contact dermatitis, other manifestations in the gastrointestinal, respiratory and neurological systems are possible after intake of nickel-rich food, referred to as the systemic nickel allergy syndrome.[4] Nickel-containing alloys have become ubiquitous in the manufacturing of modern neurovascular medical devices due to its memory and flexibility. In the treatment of cerebral aneurysms in particular, aneurysm clips, endovascular devices and stents including the new developed flow-diverting devices are made of a varying proportion of nickel.

Allergic reactions to nickel had been implicated in complications related to coronary stents, causing migraine headaches and in-stent stenosis. In addition, systemic allergic responses such as fever, dyspnea, generalized dermatitis and pericarditis after endovascular treatment with nickel-containing stent-grafts or implants have been reported.[5] In order to familiarize surgeons and interventionists with the clinical significance of this under-recognized but potentially consequential nickel allergy in the management of cerebral aneurysms, we reviewed the literature on the composition of commonly used neurosurgical and neurointerventional devices, and the complications related to nickel allergy in the setting of cerebral aneurysm treatment.

Material Methods

Literature Search and Study Selection

ACCEPTED MANUSCRIPT

The nickel content of common devices used in aneurysm treatment was identified from the product specifications or through medical device approval bodies. The manufacturers of these devices were contacted to confirm the nickel content of specific devices when such information was not available in the literature.

We performed a systematic search in the English literature with Ovid Medline, Pubmed, and Embase from 1960 to January 2018. The following terms and their combinations are used as keywords or MeSH terms: nickel, nitinol, stainless steel, allergy, hypersensitivity, aneurysms, cerebral aneurysm, clips, stent, coil, endovascular, embolization, clipping, reconstruction and adverse effects. We also searched the references of relevant articles to identify additional studies pertaining to nickel-related adverse events that were not included in the initial literature search.

Studies reporting confirmed or probable nickel-related adverse events after cerebral aneurysm treatment were included. Exclusion criteria were: (1) cases with adverse events due to materials or metals other than nickel, (2) cases where nickel-related adverse events occurred after treatment of extracranial vascular pathologies such as peripheral artery or coronary artery disease.

Outcome variables

The offending device, material, clinical presentation and treatment outcome of cases with nickel-related adverse events were extracted from the included studies. The results of skin patch test and histological findings of individual patients were included where applicable.

Results

ACCEPTED MANUSCRIPT

The initial literature search yielded 494 studies. After an initial screening of the title and abstract to exclude irrelevant papers, 38 studies were assessed for eligibility. Of these, 14 papers containing descriptions of unique patients presented with adverse events after cerebral aneurysm treatment were evaluated with the inclusion and exclusion criteria. 2 studies reporting non-nickel metal allergies and 3 studies with adverse events attributed to the non-metallic coating of coils were eliminated, leaving 9 studies to be included in the final analysis.[6-14] The PRISMA process was presented in Figure 1.

All the included studies were case reports or series. In one study that reported 2 patients with adverse events after endovascular treatment of cerebral aneurysms, one patient was proven to be non-reactive to nickel with skin patch test and was excluded, leaving a total of 10 unique patients in the review.

Nickel content in common neurosurgical and neurointervention devices

Aneurysm clips

Modern aneurysm clips currently available are either made of cobalt-alloys or titanium-alloys. Phynox, Elgiloy, and MP35N are 3 common cobalt-alloys used in the Yarsagil FE, Sugita and Slim-line (including Sundt clips) aneurysm clips, respectively. Phynox and Elgiloy contain 14-16% nickel, and MP35N contained 35% nickel.

Newer iterations of the common aneurysm clip systems are available with titanium-alloy since the mid-1990s. These clips are made with Ti6Al4V alloys which comprised of over 89% titanium, 6% of aluminium and 4% of vanadium, and do not contain nickel. (Table 1)

ACCEPTED MANUSCRIPT

ACCEPTED MANUSCRIPT

Endovascular aneurysm devices

The detachable coils were all nickel-free. Other common devices used in aneurysm treatment such as all intracranial self-expanding stents were made of nitinol, as were the endosaccular occlusion devices (WEB, Luna), and selected flow-diverters (SILK, FRED, P64). The main component of Pipeline embolization device was another nickel-alloy 35NLT, which comprised of 33-37% nickel. Surpass were made of a cobalt- chromium alloy and contained the lowest nickel content of 14-16% amongst flow-diverters. (Table 1)

Nickel-related complications after aneurysm treatment

All 10 patients identified were female, and the median age was 47.8 years old (range 33-64). Half had nickel-related adverse events after aneurysm clipping, and the remaining occurred after endovascular treatments. The clinical characteristics, offending device, adverse events, skin patch test results, histological findings and clinical course of the patients were detailed in Table 2. The diagnostic certainly of the nickel-related allergic response were classified as “probable” or “highly likely” if they fulfilled one or both of the following criteria: 1) histological prove of immunologic response, and 2) positive reaction to nickel skin patch test or prior history of nickel allergy.

Dermatological reactions

ACCEPTED MANUSCRIPT

ACCEPTED MANUSCRIPT

Ross et al. described the first nickel allergy reaction after aneurysm clipping with a Phynox clip, which contained 14-16% nickel. His patient developed generalized pruritis and a papular rash one month after clipping, with skin patch test confirming nickel reaction. The cutaneous symptoms resolved after the Phynox clip was exchanged for a titanium clip in a second craniotomy.[10] More recently, scalp erythema with localized alopecia attributed to allergic reaction to the nickel-containing 316 stainless steel head pins was reported in a patient after aneurysm clipping. The scalp lesions resolved with regrowth of hair after topical steroid treatment.[8]

Neurological reactions

Loco-regional cerebritis and cerebral edema were the predominant presentation of nickel allergy in the central nervous system. There were 8 such cases that occurred after cerebral aneurysm treatment with nickel-containing devices. In the 3 cases where cerebral reactions occur after clipping with nickel-containing clips, the patients presented 10 days to 2 months after the craniotomy with cerebral edema as the common radiological feature.[6,10,11,13] Neurological symptoms ranged from cerebral infarction and seizure to benign headache. Permanent deficits occurred in 2 patients. All underwent a second craniotomy with biopsy samples taken adjacent to the nickel-containing aneurysm clip showing histological evidence of cerebritis and vasculitis such as perivascular lymphocytic aggregation, compatible with delayed hypersentivity reaction. They were treated with systemic steroid and the offending aneurysm clips were exchanged to titanium ones in 2 patients.

ACCEPTED MANUSCRIPT

ACCEPTED MANUSCRIPT

Following endovascular treatment, there were 4 reports including 5 patients where adverse cerebral reactions related to nickel allergy were identified.[7,9,12,14] The reactions were attributed to intracranial stents and flow-diverter made of nitinol (55% nickel) in 4 patients, and to the nitinol guidewire used in the procedure in 1 patient. Similar to the clipping-related cases, the majority of these patients presented in a subacutely within the first month after coiling of the aneurysm. Diffuse cerebral edema with seizure or focal neurological deficits related to the involved territory was the main clinical presentation, resulting in hemiparesis, visual disturbance and brainstem pseudobulbar palsy. They were treated medically with systemic high dose methylprednisolone followed by a course of prednisolone, and all had radiological resolution of the cerebral edema and symptomatic improvement.

Discussion

Nickel use in aneurysm treatment devices

Nickel is commonly alloyed to use in the production of medical devices and implants for its ductility, strength profile and biocompatibility. Nickel-containing stainless steel can be made without ferromagnetism to allow for MRI compatibility, favouring its use in devices used in the treatment of neurovascular diseases such as aneurysms where MRI is frequently used for diagnosis and subsequent surveillance. The first documented aneurysm clip used was made of silver.[15] Since then, the predominant material had evolved to stainless steel for the stronger spring action in 1950s, and subsequently to cobalt alloys for its superior tissue compatibility since the 1980s. While most stainless steel clips made from ferromagnetic 301 or 304 stainless steel containing 6-8% nickel had since been discontinued, cobalt alloy clips such as Phynox,

Elgiloy and MP35N remain widely used. Newer iterations of the common aneurysm clip systems are available with nickel-free titanium-alloy since the mid-1990s. However, cobalt alloy clips are unlikely to be completely replaced as they afford a stronger spring action and clamping force.[16]

The armamentarium of endovascular aneurysm treatment consisted of coils, flow-diverters, endosaccular occlusion devices, and in selected cases stents and bifurcation devices. Apart from the detachable coils which were all nickel-free, the majority of the other devices were made with nickel-containing alloys such as nitinol. Nickel is the major component of nitinol, accounting for 55% by weight with the rest being titanium. The main advantage of nitinol is the shape-memory, which is instrumental in self-expanding stents and devices.

Spectrum and clinical course of nickel-related complications

Given the 10-15% prevalence of nickel allergy in the population[1], the reported incidence of nickel-related adverse events after aneurysm treatment was remarkably low, and only 10 cases were identified in the literature. These reactions may well be under-diagnosed, especially when many could be sub-clinical and reversible. All the reported nickel-related adverse reactions occurred in female patients, with either dermatological or neurological manifestations.

Allergic skin reactions after implantation of nickel-containing device have been reported after orthopaedic implants, coronary stenting, implantation of patent foramen ovale occluders and cardiac pacemakers, as well as stenting for peripheral vascular disease and aortic aneurysm repair.[5,17-19] Those patients typically presented with generalized rash and varying degree of systemic allergic response such as fever or respiratory difficulties within days after device implantation. In the neurosurgical field, dermatological reactions related the nickel-containing

devices were extremely rare and only 2 cases were identified.[8,10] One presented as generalized rash secondary to a Phynox aneurysm clip, and the other as alopecia after local contact with nickel-containing head pins. In contrast, the neurological complications including cerebritis and cerebral edema in 8 of the included patients were unique to intracranial aneurysm treatment and not reported in non-neurosurgical procedures involving nickel implants.

Apart from the nickel content, the amount of free nickel ion release after device implantation may be of critical importance, as systemic allergic response was initiated with the release of free nickel ions in the body.[20] In an in vitro study using human endothelial cells, inflammatory markers were significantly up-regulated after incubation with nitinol wires with a higher release of free nickel ions, but not when incubated with low nickel release wires.[21]

While there were no studies on the nickel release after aneurysm clipping or stenting, Ries et al. studied the serum nickel concentration in 67 atrial septal defect patients before and after implantation of a nitinol foramen ovale occluder containing 55% nickel. [22] Compared with preoperative serum, the free nickel level increased significantly at 24 hours, peaked at 1 month, then gradually returned to baseline at 12 months after the nitinol occluder implantation. The temporal pattern of nickel concentration change corresponded to the 3 to 4-week latency of the adverse reactions occurring in the patients after treatment with nitinol intracranial stents in our review. Notably, Ries et al. demonstrated the marked individual variation in the nickel levels after implantation of the same device. This variability may account for the difference in severity of symptoms and the lack of reactions in known nickel-sensitive patients treated with nitinol devices, as allergic reactions to nickel are known to display a clear dose-response relationship amongst nickel-sensitive persons.[23] After nitinol devices were implanted, the release of nickel ions reduces over time.[24] This is likely the result of the development of a titanium-oxide surface

layer as shown in in-vitro bioenvironment, coupled with the effect of endothelialization of the nitinol stent.[24] This could explain the radiological resolution of cerebral edema over time in 6 of the patients, even though the nickel-containing clip or stent was not removed.

Treatment of nickel-related reactions

Although mild contact dermatitis can be managed with topical steroid alone, removal of the offending implant should be considered in patients with systemic reaction to the nickel. Prior reports concerning stenting in peripheral vascular diseases reported prompt resolution of allergic response after the nitinol stent was removed with subsequent surgical reconstruction of the parent vessel.[17] In the setting of implanted cerebrovascular devices, however, this can be both challenging and risky. For the 4 patients who developed nickel reaction after aneurysm clipping, the aneurysm clips were removed and exchanged to titanium-made ones in 3 patients. The remaining patient developed severe scarring around the aneurysm clip, and microsurgical dissection and clip manipulation was deemed too risky.

Contrary to the clipping cases, where the clip is extra-vascular, those who developed reaction after placement of an endovascular nitinol stent cannot have the implant endovascularly removed without excessive risk of vessel dissection and perforation. As previously noted, these patients tend to present weeks after the initial treatment, when endothelial remodelling may have partially incorporated the stents. In the reported cases, they were instead treated medically with systemic steroid and all had radiological and symptomatic resolution. Extracting the stent with open surgery followed by aneurysm clipping and parent vessel bypass or reconstruction may

ACCEPTED MANUSCRIPT

serve as a last resort for medically-refractory patients, and had been performed in other scenarios such as migrated flow-diverters. [25,26]

Management considerations

Enquiring the patient for an allergy history to metal could be easily done preoperatively and would provide important information. Nickel-allergy should be suspected as a potential cause for unusual neurological or dermatological reactions occurring in the first weeks after aneurysm treatment with nickel-containing devices, after ruling out vascular or infective complications. While histological samples would be the gold standard for diagnosing immunologic response related to metal allergy, open biopsy may not be justified especially in endovasculary-treated patients and should be reserved when there was diagnostic difficulty. Allergy to nickel can also be readily confirmed with skin patch test in patients with known or suspected nickel allergy.[27] Typically, 2.5% and 5% nickel sulphate solution were placed on a reservoir sheet epidermically, and the occurrence and severity of local erythematous and papular reactions were assessed after 7 days. Other metal constituents of the contemplated device could also be tested, such as cobalt chloride and chromium trichloride. Skin patch test using a reagent triturated from the endovascular device itself may be of value in establishing definitive diagnosis of allergic reactions secondary to the implantation. Uwatoko et al., identified a rare case of allergic reaction to platinum detachable coils after aneurysm coiling by performing skin patch test with such reagent, and Shotar et al., likewise patch tested a patient with the SILK flow-diverter. [12,28]

ACCEPTED MANUSCRIPT

ACCEPTED MANUSCRIPT

Development of aneurysm clips made of titanium had replaced the majority of stainless steel clips and effectively removed the risk of nickel reaction in aneurysm patients amenable to surgical clipping. In the rare case when patients with history of severe reactions to nickel required implantation of a nickel-containing device for aneurysm treatment (eg. a giant internal carotid artery aneurysm best treated with stent-assisted coiling or flow-diverter), nickel desensitization could be considered. This is performed with incremental oral dose of nickel, and had been shown in a randomized controlled trial to be effective in systemic nickel allergy syndrome.[29] For patients presenting with a nickel-related reactions after aneurysm treatment, an initial course of systemic steroid should be considered. In the future, next-generation stents made of novel materials such as nickel-free alloys or polymers may be the solution.[30]

Conclusion

While complication related to nickel in cerebral aneurysm treatments is rare, it remains a concern due to the high prevalence of nickel allergy in the population. Surgeons and interventionists should consider the metal-allergy history and its potential clinical significance in managing nickel-allergic patients with aneurysms.

Funding Statement:

This work was supported by the Health and Medical Research Fund of Hong Kong Food and Health Bureau, grant number 01150027.

ACCEPTED MANUSCRIPT

ACCEPTED MANUSCRIPT

Competing Interests Statement:

The authors reported no competing interests.

Data Sharing Statement:

Not applicable.

Reference:

1. Warshaw EM, Belsito DV, Taylor JS, et al. North American Contact Dermatitis Group patch test results: 2009 to 2010. *Dermatitis : contact, atopic, occupational, drug.* Mar-Apr 2013;24(2):50-59.
2. Mortz CG, Bindslev-Jensen C, Andersen KE. Nickel allergy from adolescence to adulthood in the TOACS cohort. *Contact dermatitis.* Jun 2013;68(6):348-356.
3. Warshaw EM, Kingsley-Loso JL, DeKoven JG, et al. Body piercing and metal allergic contact sensitivity: North American contact dermatitis group data from 2007 to 2010. *Dermatitis : contact, atopic, occupational, drug.* Sep-Oct 2014;25(5):255-264.
4. Ricciardi L, Arena A, Arena E, et al. Systemic nickel allergy syndrome: epidemiological data from four Italian allergy units. *International journal of immunopathology and pharmacology.* Jan-Mar 2014;27(1):131-136.
5. Honari G, Ellis SG, Wilkoff BL, Aronica MA, Svensson LG, Taylor JS. Hypersensitivity reactions associated with endovascular devices. *Contact dermatitis.* Jul 2008;59(1):7-22.
6. Grande A, Grewal S, Tackla R, Ringer AJ. Life-threatening allergic vasculitis after clipping an unruptured aneurysm: Case report, weighing the risk of nickel allergy. *Surgical neurology international.* 2014;5(Suppl 4):S161-164.
7. Lobotesis K, Mahady K, Ganesalingam J, et al. Coiling-associated delayed cerebral hypersensitivity: Is nickel the link? *Neurology.* Jan 6 2015;84(1):97-99.
8. Ono H, Takasuna H, Tanaka Y. Alopecia due to an allergic reaction to metal head-pins used in a neurosurgical operation. *Surgical neurology international.* 2016;7(Suppl 1):S5-7.
9. Park HS, Nakagawa I, Yokoyama S, et al. Nickel-associated delayed multiple white matter lesions after stent-assisted coil embolization of intracranial unruptured aneurysm. *J Neurointerv Surg.* Jan 2018;10(1):e1.
10. Ross IB, Warrington RJ, Halliday WC. Cell-mediated allergy to a cerebral aneurysm clip: case report. *Neurosurgery.* Nov 1998;43(5):1209-1211.
11. Schmidlin K, Verzwyvelt J, Bernstein D, Kim H. Probable delayed-type hypersensitivity to nickel-containing cerebral aneurysm clip associated with neurologic deficits. *The journal of allergy and clinical immunology. In practice.* Jul-Aug 2015;3(4):609-611.

12. Shotar E, Law-Ye B, Baronnet-Chauvet F, et al. Non-ischemic cerebral enhancing lesions secondary to endovascular aneurysm therapy: nickel allergy or foreign body reaction? Case series and review of the literature. *Neuroradiology.* Sep 2016;58(9):877-885.

13. Tan T, Tee JW, Han TF. Cell-mediated allergy to cerebral aneurysm clip causing extensive cerebral edema. *J Neurosurg.* Oct 2014;121(4):924-928.

14. Ulus S, Yakupoglu A, Kararslan E, Islak C, Siva A, Kocer N. Reversible intracranial parenchymal changes in MRI after MCA aneurysm treatment with stent-assisted coiling technique; possible nickel allergy. *Neuroradiology.* Aug 2012;54(8):897-899.

15. Louw DF, Asfora WT, Sutherland GR. A brief history of aneurysm clips. *Neurosurgical focus.* Aug 15 2001;11(2):E4.

16. McFadden JT. Magnetic resonance imaging and aneurysm clips. *J Neurosurg.* Jul 2012;117(1):1-11.

17. D'Arrigo G, Giaquinta A, Virgilio C, Davi A, Pierfrancesco V, Veroux M. Nickel allergy in a patient with a nitinol stent in the superficial femoral artery. *J Vasc Interv Radiol.* Aug 2014;25(8):1304-1306.

18. Jetty P, Jayaram S, Veinot J, Pratt M. Superficial femoral artery nitinol stent in a patient with nickel allergy. *J Vasc Surg.* Nov 2013;58(5):1388-1390.

19. Thyssen JP, Menne T, Schalock PC, Taylor JS, Maibach HI. Pragmatic approach to the clinical work-up of patients with putative allergic disease to metallic orthopaedic implants before and after surgery. *The British journal of dermatology.* Mar 2011;164(3):473-478.

20. Thyssen JP, Uter W, McFadden J, et al. The EU Nickel Directive revisited--future steps towards better protection against nickel allergy. *Contact dermatitis.* Mar 2011;64(3):121-125.

21. McLucas E, Rochev Y, Carroll WM, Smith TJ. Analysis of the effects of surface treatments on nickel release from nitinol wires and their impact on candidate gene expression in endothelial cells. *Journal of materials science. Materials in medicine.* Mar 2008;19(3):975-980.

22. Ries MW, Kampmann C, Rupprecht HJ, Hintereder G, Hafner G, Meyer J. Nickel release after implantation of the Amplatzer occluder. *American heart journal.* Apr 2003;145(4):737-741.

23. Jensen CS, Menne T, Lisby S, Kristiansen J, Veien NK. Experimental systemic contact dermatitis from nickel: a dose-response study. *Contact dermatitis.* Sep 2003;49(3):124-132.

24. Wever DJ, Veldhuizen AG, de Vries J, Busscher HJ, Uges DR, van Horn JR. Electrochemical and surface characterization of a nickel-titanium alloy. *Biomaterials.* Apr-May 1998;19(7-9):761-769.

25. Turek G, Kochanowicz J, Lewszuk A, et al. Early surgical removal of migrated coil/stent after failed embolization of intracranial aneurysm. *J Neurosurg.* Oct 2015;123(4):841-847.

26. Bowers CA, Taussky P, Park MS, Neil JA, Couldwell WT. Rescue microsurgery with bypass and stent removal following Pipeline treatment of a giant internal carotid artery terminus aneurysm. *Acta Neurochir (Wien).* Dec 2015;157(12):2071-2075.

27. Mowad CM. Patch testing: pitfalls and performance. *Current opinion in allergy and clinical immunology.* Oct 2006;6(5):340-344.

28. Uwatoko T, Tsumoto T, Wada N, et al. Dermatitis caused by metal allergy after coil embolization for unruptured cerebral aneurysm. *J Neurointerv Surg.* Oct 2016;8(10):e42.

29. Di Gioacchino M, Ricciardi L, De Pita O, et al. Nickel oral hyposensitization in patients with systemic nickel allergy syndrome. *Annals of medicine.* Feb 2014;46(1):31-37.

30. Karsy M, Guan J, Brock AA, Amin A, Park MS. Emerging Technologies in Flow Diverters and Stents for Cerebrovascular Diseases. *Current neurology and neuroscience reports.* Oct 28 2017;17(12):96.

ACCEPTED MANUSCRIPT

ACCEPTED MANUSCRIPT

Figure legend

Figure 1: Literature search in accordance with PRISMA

ACCEPTED MANUSCRIPT

ACCEPTED MANUSCRIPT

Table 1. Nickel content in common devices for cerebrovascular diseases.

Device	Manufacturer	Main Material	Nickel content
Aneurysm clips			
Yasargil Phynox	Aesculap	Phynox	14-16%
AVM Microclips	Aesculap	Phynox	14-16%
Sugita standard	Mizuho	Elgiloy	14-16%
Sugita AVM clips	Mizuho	Elgiloy	14-16%
Slim-line aneurysm clips	Codman	MP 35N	35%
Yarsargil Titanium	Aesculap	Titanium alloy ASTM F136	0%
Sugita T2	Mizuho	Titanium alloy ASTM F136	0%
Perneczky aneurysm clips	Adeor	Titanium alloy ISO 5832-3	0%
Self-expanding Stents/ Bifurcation devices			
Enterprise/ Enterprise 2	Codman Neuro	Nitinol	55%
LVIS	MicroVention	Nitinol	55%
Neuroform EZ/ Neuroform 3	Stryker	Nitinol	55%
Wingspan	Stryker	Nitinol	55%
PulseRider	Pulsar Vascular	Nitinol	55%
pCONUS	Phenox	Nitinol	55%
Leo+/ Leo+ baby	Balt	Nitinol	55%
Carotid Wallstent	Boston Scientific	Elgiloy	14-16%
Cerebral Coils (detachable component)			
Axium/ Axium Prime	Medtronic	Platinum	0%
Axium MicroFX	Medtronic	Platinum, PGLA/Nylon filaments	0%

ACCEPTED MANUSCRIPT

HydroFill/HydroFrame/ HydroSoft	MicroVention	Platinum, hydrogel-coated	0%
MicroPlex	Microvention	Platinum	0%
Target	Stryker	Platinum	0%
GDC	Stryker	Platinum	0%
Matrix2	Stryker	Platinum, PGLA braid	0%
Micrus	Codman Neuro	Platinum +/- cerecyte-PGA	0%
Smart Coil	Penumbra	Platinum	0%
Penumbra Coil 400	Penumbra	Platinum	0%
Flow-diverters			
Pipieline embolization device	Medtronic	35N LT, Platinum	25%-28%
SILK	Balt	Nitinol	55%
FRED	MicroVention	Nitinol	55%
Surpass	Stryker	Cobalt-chromium alloy, Platinum	14-16%
P64	Phenox	Nitinol	55%
Endosaccular occlusion device			
WEB	Sequent	Nitinol	55%
Luna	Covidien	Nitinol	55%
Stent Retreivers			
Solitaire Platinum/ Solitaire FR	Medtronic	Nitinol	55%
Trevo XP / Trevo	Stryker	Nitinol	55%
Catch plus	Balt	Nitinol	55%
Head frame pins			
Sugita pins	Mizuho	316L stainless steel	10-12%
Mayfield pins	Integra	630 stainless steel	3-5%

ACCEPTED MANUSCRIPT

ACCEPTED MANUSCRIPT

Table 2. Clinical characteristics, treatment and outcome of nickel-related adverse reactions after aneurysm treatment.

	Age	Location	History of Metal allergy	Treatment Device	Presentation	Latency	Skin patch test	Histology	Diagnostic certainty	Management	Outcome
Ross et al., 1998[10]	36/F	Left MCA	No	Phynox aneurysm clip	Generalized pruritis, papular rash	1 month	Positive for nickel and cobalt	Lymphocytic infiltrate	Highly likely	Clip exchanged to titanium clip	Complete symptom resolution
Tan et al., 2014[13]	60/F	Right MCA	Nickel	Phynox aneurysm clip	Cerebral edema, headache	2 months	nil	Lymphocytic aggregates, intraparenchymal histiocytic infiltrate	Highly likely	Cerebral biopsy and prednisolone	Complete symptom and radiological resolution
Grande et al., 2014[6]	33/F	Left PcomA	No	Nickel-containing aneurysm clip	Seizure, infarct	11days	nil	Perivascular lymphocytic cuffing, vasculitis,	Probable	Clip exchanged to titanium clip	Residual neurological deficit
Schmidlin et al., 2015[11]	33/F	Left PComA	Stainless steel	Nickel-containing aneurysm clip	Bilateral cerebral infarction, aphasia	10 days	Positive for nickel	scattered eosinophils with perivascular lymphocyte cuffing	Highly likely	Methylprednisolone, clip exchanged to titanium clip	Residual neurological deficits
Ono et al., 2016[8]	45/F	AcomA	Metal jewellery	Sugita headpins	Alopecia, scalp erythema	21 days	nil	nil	Possible	Topical corticosteroid	Complete symptom resolution

ACCEPTED MANUSCRIPT

ACCEPTED MANUSCRIPT

Ulus et al., 2012[14]	41/F	Left MCA	No	Enterprise Stent, GDC coils	Cerebral edema, visual disturbance, headache	1 month	nil	nil	Possible	Conservative	Complete symptom and radiological resolution
Lobotesis et al., 2015[7]	60/F	Right ICA	No	Nitinol guidewire, Platinum coils	Left episodic hemiparesis, seizure, headache multifocal edema	19 days	Positive to nickel	nil	Probable	Methylprednisolone and prednisolone	Complete symptom and radiological resolution
Shotar et al., 2016[12]	54/F	Right ICA	No	Flow diverter (SILK) + coils	Cerebral edema, seizure	12 months	Positive to nickel, cobalt, copper	Lymphocytic infiltration, eosinophil margination in capillaries	Highly likely	Prednisolone	Improved symptoms and radiological resolution
Park et al, 2018[9]	52/F	Right VA	No	Enterprise Stent, GDC coils	Cranial nerve 6-9 palsy; medulla, pons, thalamus, corpus callosum white matter lesions	18 days	Positive to nickel	nil	Probable	Methylprednisolone and prednisolone	Improved symptoms and complete radiological resolution
	64/F	Left ICA	No	Enterprise Stent, GDC coils	White matter lesions, right hemiparesis	21 days	nil	nil	Possible	Methylprednisolone and prednisolone	Complete symptom and radiological resolution

MCA: Middle cerebral artery; PcomA: Posterior communicating artery; AcomA: Anterior communicating artery; ICA, Internal carotid artery; VA: Vertebral artery

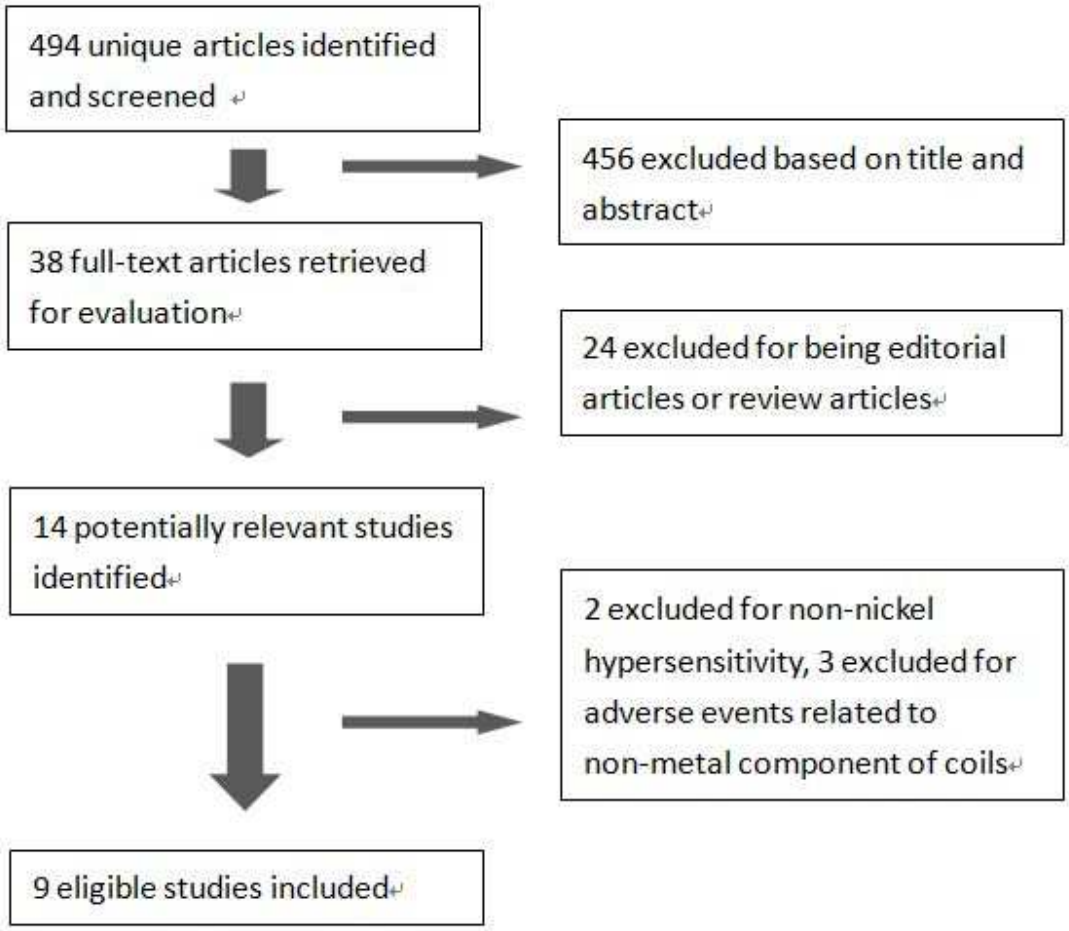
494 unique articles identified and screened
456 excluded based on title and abstract
38 full-text articles retrieved for evaluation
24 excluded for being editorial articles or review articles
14 potentially relevant studies identified
2 excluded for non-nickel hypersensitivity, 3 excluded for adverse events related to non-metal component of coils
9 eligible studies included

ACCEPTED

ACCEPTED MANUSCRIPT

Highlights

- Nickel is ubiquitous in the devices used in cerebral aneurysm treatment
- Although rare, dermatological and neurological complications including cerebral edema and cerebritis could occur after treatment with nickel-containing aneurysm clips or stents.
- Most nickel-related adverse events could be managed with steroid therapy.
- Clinicians should consider the metal allergy history in deciding the optimal treatment device when managing these patients with aneurysms.

ACCEPTED MANUSCRIPT

ACCEPTED MANUSCRIPT

Abbreviation list

AcomA: Anterior communicating artery
ICA, Internal carotid artery
MCA: Middle cerebral artery
PcomA: Posterior communicating artery
PRISMA: Preferred Reporting Items for Systematic Reviews and Meta-Analyses
VA: Vertebral artery

ACCEPTED MANUSCRIPT

ACCEPTED MANUSCRIPT

Conflict of interest statement:

The authors declare that the article content was composed in the absence of any commercial or financial relationships that could be construed as a potential conflict of interest.

ACCEPTED MANUSCRIPT