Accepted Manuscript



Novel cytoskeletal mutations with immunodeficiency: why is the raven like a writing desk?

Mikko RJ. Seppänen

PII: S0091-6749(18)31264-8

DOI: 10.1016/j.jaci.2018.08.020

Reference: YMAI 13591

To appear in: *Journal of Allergy and Clinical Immunology*

Received Date: 1 August 2018

Revised Date: 14 August 2018

Accepted Date: 25 August 2018

Please cite this article as: Seppänen MR, Novel cytoskeletal mutations with immunodeficiency: why is the raven like a writing desk?, *Journal of Allergy and Clinical Immunology* (2018), doi: 10.1016/j.jaci.2018.08.020.

This is a PDF file of an unedited manuscript that has been accepted for publication. As a service to our customers we are providing this early version of the manuscript. The manuscript will undergo copyediting, typesetting, and review of the resulting proof before it is published in its final form. Please note that during the production process errors may be discovered which could affect the content, and all legal disclaimers that apply to the journal pertain.

ACCEPTED MANUSCRIPT

JACI-D-18-01024
EDITORIAL

Novel cytoskeletal mutations with immunodeficiency: why is the raven like a writing desk?

Mikko RJ Seppänen[1,2]

[1]Rare Diseases Center, Children's Hospital, University of Helsinki and Helsinki University Hospital, P.O.Box 280, FI-00029 HUS, Finland
[2]Adult Immunodeficiency Unit, Infectious Diseases, Inflammation Center, University of Helsinki and Helsinki University Hospital, Helsinki, Finland

Corresponding author:

Mikko RJ Seppänen, MD, PhD

Rare Disease Center

Children's Hospital

Hospital District of Helsinki and Uusimaa

House G

Stenbäckinkatu 11, P.O.Box 281,

FI-00029 Helsinki

Finland

e-mail: mikko.seppanen@hus.fi

Tel: +358 50 4279606

Fax: +358 9 47174703

Word count: 1230

COI Statement: CSL Behring (Speaker's fees), Helsinki University Research Funds, Foundation for Paediatric Research (Research grants)

Key Words: Immunologic Deficiency Syndromes; Inborn Genetic Syndromes; Hereditary Autoinflammatory Diseases; WDR1 Deficiency; Neutropenia; Leukocyte Disorders; Thrombocytopenia; Cytoskeletal Proteins; Wiskott-Aldrich Syndrome;

ACCEPTED MANUSCRIPT

ACCEPTED MANUSCRIPT

The title contains a classical quote from *Alice's Adventures in Wonderland* and *Through the Looking Glass* by Lewis Carroll. It perfectly describes the feelings that followed two recent reports on novel, somewhat overlapping primary immunodeficiency (PID) syndromes caused by autosomal recessive mutations in WD repeat-containing protein 1 (*WDR1*).[1,2] These lead to actin cytoskeleton abnormalities due to loss-of-function through impaired levels or abnormal cellular distribution of WDR1. In this issue of *JACI*, Pfajfer et al. describe the extended phenotype of this newly described, fascinating PID.[3]

To date, at least 13 known PIDs are associated with cytoskeletal defects.[4] These classically include combined immunodeficiencies and phagocyte disorders.[5] Actin cytoskeleton is required for various immune cell functions (*e.g.* migration, adhesion, phagocytosis, cell division, receptor signaling, gene expression, calcium flux) and for the dynamic assembly and disassembly of concurrent complex intracellular contacts. The dynamic nature of these contacts requires rapid remodeling of the cytoskeleton that leads to directional changes in cell migration. To achieve this, cells generate branched actin filaments from globular (G-) actin and suppress the formation of filamentous (F-) actin by processes like capping and severing.[5,6]

WDR1, previously known as actin-interacting protein 1, is a nearly ubiquitously expressed negative regulator of F-actin.[6] In general, WD40 repeat (WDR) domain-formed β-sheets represent one of the most abundant protein interaction domains in the human proteome. WDR domains of WDR1 are typically organized into two seven-bladed β-propeller domains with a doughnut shape.[1,6,7] Together with cofilin, WDR1 dynamically enhances F-actin disassembly and severing of actin filaments. Jointly, they also facilitate F-actin recycling and polymerization from newly created barbed ends.[5-7]

Hypomorphic homozygous *Wdr1* mutations in mice were known to cause increased polymerized actin levels in phagocytes and predispose to spontaneous autoinflammatory disease (AID) and macrothrombocytopenia.[8] Uniquely, this murine AID was later shown to be caused by elevated IL-18 (but not IL-1β) production by the pyrin inflammasome. In various phagocytic cells, the increased IL-18 production was restricted to monocytes.[9]

In 2016, Kuhns et al. described autosomal recessive *WDR1* mutations in four children from three families with a previously-described, rare autosomal recessive “lazy leukocyte syndrome”. Clinically, these patients displayed recurrent invasive infections due to gram-positive and -negative bacteria, fatal varicella, impaired wound healing and severe stomatitis with acquired microstomia and oral stenosis. Patients had mild neutropenia, defective neutrophil mobilization, nuclear lobe herniation with regionally agranular cytoplasm due to increased F-actin and abnormal random (chemokinesis) and directed (chemotaxis) migration.[1]

The following year, Standing et al. described a novel autoinflammatory disease coined autoinflammatory periodic fever, immunodeficiency and thrombocytopenia (PFIT) -syndrome, caused by a homozygous *WDR1* mutation in two siblings. Clinically, patients suffered from periodic fever lasting 3-7 d, every 6-12 wk, with clear acute phase response, thrombocytopenia, hyperferritenemia and high serum IgA. Their autoinflammatory phenotype largely recapitulated the mouse phenotype with constitutively elevated IL-18. In response to LPS, patients displayed exaggerated IL-18 production by both monocytes and neutrophils. Again, IL-1β production was similar to controls. Overlapping with lazy leukocyte syndrome, patients displayed invasive pyogenic infections caused by gram-positive cocci, severe stomatitis with acquired microstomia, reduced neutrophil chemotaxis and increased intracellular F-actin aggregates. In all four described families, mutations seemed to affect the functionally critical β-propeller sheets of WDR1. Adaptive immunity, affected in most known cytoskeletal defects, remained little studied.[2] Whether *WDR1* mutations cause two distinct clinical entities or rather a single disease remained unanswered. Also if found, significant impairments of adaptive immunity would suggest treatment with stem cell transplantation, reported successful in two affected individuals.[1,2]

Pfajfer et al. now take major steps towards answering some open questions on WDR1 deficiency, in six patients from three families with nearly abrogated WDR1 expression in PBMCs.[3] Like in previous reports, patients variably suffered from severe stomatitis, periodic fevers and gram-positive respiratory and skin

infections. Patients also displayed abnormal nuclear lobe herniation in neutrophils or loss of nuclear integrity, intracellular accumulation of F-actin and impaired migration. Increased actin in patient monocytes lead to increased podosome assembly and spreading, mimicking findings in *WDR1*-mutated monocyte-derived dendritic cells due to misfolded WDR1.[2,3]

In these patients, neutrophil counts were normal or increased, patients displayed opportunistic bacterial and viral infections, abscesses, organ-specific autoimmunity, recurrent fevers and (auto)inflammatory skin conditions like pyoderma gangrenosum and *acne conglobata*. Acute phase response, including ferritin levels, remained mostly normal or were only mildly elevated during fevers. Mechanisms of autoinflammation were not studied further. Patients frequently had smallish stature, facial dysmorphism and learning difficulties. Furthermore, they exhibited somewhat impaired T cell function with diminished TCR-induced Ca^{2+} responses, aberrant actin meshwork organization and spreading, and occasionally reduced anti-CD3/28 responses. They also displayed lymphoproliferation, impaired B cell immunity with abnormal B cell development, severe reduction of bone marrow $CD20^{+}$ B cell precursors, reduced B cell and T follicular helper cell levels and increased B cell apoptosis. Residual peripheral B cells displayed impaired somatic hypermutation and were abnormally skewed toward the transitional $CD10^{+}CD38^{+}$ B-cell stage ("recent bone marrow emigrants"). The oldest two patients had highly clonal BCR repertoire, suggesting that clonality may increase with age. Systematic testing of vaccine responses in WDR1 deficiency has not been performed.[1-3] Clearly, WDR1 plays a prominent role in actin-regulated lymphocyte and neutrophil development and function, suggesting further studies.

Thus, a picture emerges where different *WDR1* mutations cause an overlapping spectrum of clinical manifestations (Figure). This disease could be classified as an autoinflammatory disorder, combined or neutrophil immunodeficiency. It thus resembles Wiskott-Aldrich syndrome, another disorder of actin cytoskeleton. In WDR1 deficiency, severe atopy seems uncommon and the reported mean platelet volumes were higher, in the range of 8.2-13.7 fL.[3,10] Reported hematologic and clinical changes due to WDR1 deficiency will aid in clinical diagnosis (Figure).[1-3] The variably impaired or dysregulated neutrophils, monocytes, B and T cells explain the occasional severe opportunistic infections, autoimmunity and autoinflammation. Fluctuating and chronic thrombocytopenia is potentially caused by multiple mechanisms, including impaired production, dysfunctional shedding, splenomegaly and autoimmunity.[2,3,8] A genotype-phenotype correlation and the exact mechanisms of neurologic sequelae remain to be assessed. Of note, a more pronounced deficiency in adaptive immunity together with neurologic phenotype has thus far been described only for patients with near-absent WDR1 expression.[3] *Wdr-/Wdr-* mice are known to be embryonic lethal.[6] Treatment options reported for WDR1 deficiency include immunoglobulin replacement, antibiotic prophylaxis and stem cell transplant (SCTx).[1,2] SCTx unlikely corrects the neurologic phenotype.[3] Effects of SCTx against various (auto)inflammatory manifestations remain to be confirmed. Further exact mechanisms for the clinically highly variable autoinflammation and the noted specific IL-18 overproduction seen in PFIT remain intriguing.[2,8,9] Against autoinflammation, anakinra and various emerging anti-IL-18 treatments (*e.g.* IL18BP, anti-IL18) under development need to be tested.

Currently, WDR1 deficiency is classified under congenital defects of phagocyte number or function.[4] The extended WDR1 phenotype nicely illustrates a current, more general trend and brings the opposite of Lewis Carroll's answer to the title's famous riddle in mind (*Because it can produce a few notes, tho they are very flat; and it is nevar put with the wrong end in front!*) [2,3]. In many novel monogenic but pleiotropic PIDs, classification into a single PID class based on the mutated gene has become impossible.[4] Patients commonly display combinations of immunodeficiency, autoimmunity, autoinflammation and malignancy that vary even between family members carrying the same mutation. Consequently, clinical diagnostics of rare PIDs has become extremely demanding and frequently results in next generation sequencing early in the diagnostic process. Whether augmented intelligence-based diagnostic decision support systems will direct us towards more targeted approaches in the future remains to be seen.

ACCEPTED MANUSCRIPT

References

1. Kuhns DB, Fink DL, Choi U, Sweeney C, Lau K, Priel DL, et al. Cytoskeletal abnormalities and neutrophil dysfunction in WDR1 deficiency. Blood 2016;128:2135-43.
2. Standing AS, Malinova D, Hong Y, Record J, Moulding D, Blundell MP, et al. Autoinflammatory periodic fever, immunodeficiency, and thrombocytopenia (PFIT) caused by mutation in actin-regulatory gene WDR1. J Exp Med 2017;214:59-71.
3. Pfajfer L, Mair NK, Jimenez-Heredia R, Genel F, Gulez N, Ardeniz O, et al. Mutations affecting the actin regulator WD repeat–containing protein 1 lead to aberrant lymphoid immunity. J Allergy and Clin Immunol. doi:10.1016/j.jaci.2018.04.023.
4. Journal of Allergy and Clinical Immunology, Volume 0, Issue 0,Picard C, Gaspar HB, Al-Herz W, Bousfiha A, Casanova JL, Chatila T, et al. International Union of Immunological Societies: 2017 Primary Immunodeficiency Diseases Committee Report on inborn errors of immunity. J Clin Immunol 2018;38:96-128.
5. Burns SO, Zarafov A, Thrasher AJ. Primary immunodeficiencies due to abnormalities of the actin cytoskeleton. Curr Opin Hematol 2017;24:16-22.
6. Ono S. Functions of actin-interacting protein 1 (AIP1)/WD repeat protein 1(WDR1) in actin filament dynamics and cytoskeletal regulation. Biochem Biophys Res Commun doi:10.1016/j.bbrc.2017.10.096.
7. Schapira M, Tyers M, Torrent M, Arrowsmith CH. WD40 repeat domain proteins: a novel target class? Nat Rev Drug Discov 2017;16:773-86.
8. Kile BT, Panopoulos AD, Stirzaker RA, Hacking DF, Tahtamouni LH, Willson TA, et al. Mutations in the cofilin partner Aip1/Wdr1 cause autoinflammatory disease and macrothrombocytopenia. Blood 2007;110:2371-80.
9. Kim ML, Chae JJ, Park YH, De Nardo D, Stirzaker RA, Ko HJ, et al. Aberrant actin depolymerization triggers the pyrin inflammasome and autoinflammatory disease that is dependent on IL-18, not IL-1β. J Exp Med 2015;212:927-38.
10. Lee PP, Lobato-Márquez D, Pramanik N, Sirianni A, Daza-Cajigal V, Rivers E, et al. Wiskott-Aldrich syndrome protein regulates autophagy and inflammasome activity in innate immune cells. Nat Commun 2017;8:1576.

ACCEPTED MANUSCRIPT

ACCEPTED MANUSCRIPT

Figure Legend. Frequency of reported features in 12 patients from 7 families with autosomal recessive WDR1 deficiency. Respiratory bacterial infections = streptococci, staphylococci, *Haemophilus influenzae*. Other invasive bacterial infections = abscesses, sepsis, arthritis, necrotizing cellulitis, typhlitis, urinary tract and skin infections due to streptococci, staphylococci, enterococci, *Haemophilus influenzae*, *Eschericia coli*. Opportunistic infections = disseminated varicella, *Pneumocystis jiroveci* pneumonia, *Burkholderia gladioli* abscess, mucocutaneous candidiasis, clinically diagnosed viral encephalitis (each n=1), chronic HBV carriership (n=2).

ACCEPTED MANUSCRIPT

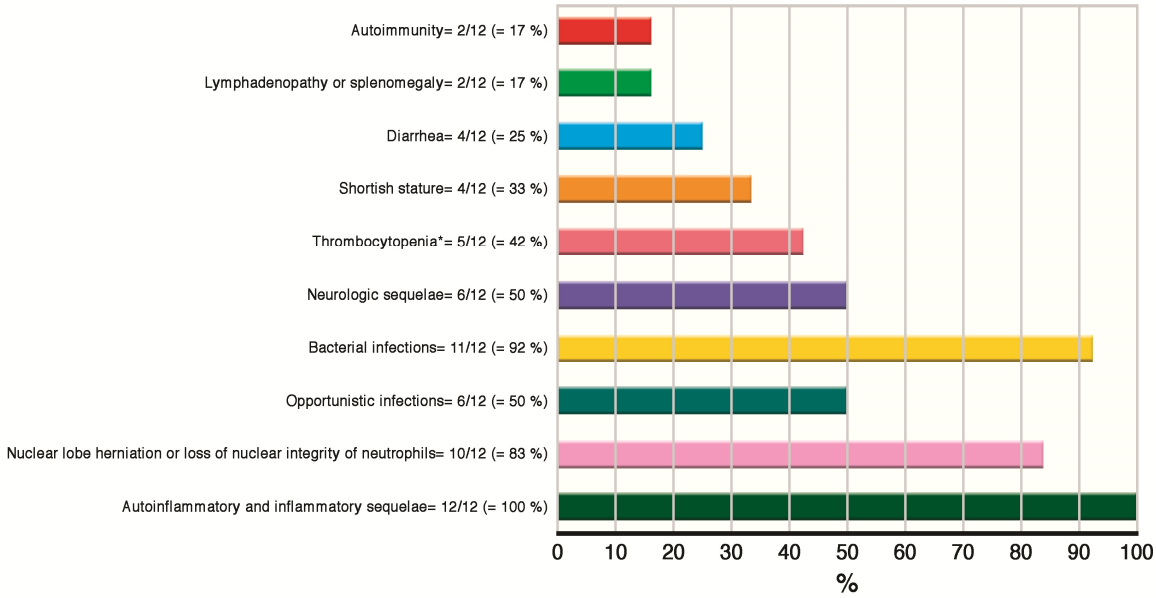

ACCEPTED MANUSCRIPT