A Fishy Situation: Allergic Contact Dermatitis of the Fingertips Due to Propyl Gallate

David G. Holzer, BS, Sophia M. Akhiyat, MD, and Keri Chaney, MD, FAAD

PRECÍS

We present a unique case of fingertip allergic contact dermatitis from sprinkling fish food containing the inciting allergen, propyl gallate.

A 58-year-old woman presented with a 1-year history of dermatitis localized to the fingertips of the first 3 fingers of both hands. The distal aspects of the patient's bilateral first (thumb), second, and third digits demonstrated ill-defined eczematous plaques with superficial fissures and thin scales (Fig. 1). The woman had previously used petrolatum on her hands, which provided moderate symptomatic relief, and clobetasol 0.05% ointment, which provided no significant improvement. Her dermatitis had responded well to narrowband UV-B phototherapy for 12 weeks but flared up again 1 week after discontinuing phototherapy.

A review of the materials she frequently handled included her keyboard at work, disinfectant wipes, New-Skin Liquid Bandage (Advantice Health, LLC, New Jersey), and her fish food, which she fed to her fish twice daily. Patch testing was performed with the American Contact Dermatitis Society Core Series (2017), a cosmetic series (Chemotechnique Diagnostics, Sweden), and the patient's New-Skin Liquid Bandage. Her final patch testing results revealed a 1+ reaction to ethyl cyanoacrylate (10% petrolatum), 1+ to octyl gallate (0.25% petrolatum), and 2+ to propyl gallate (1% petrolatum). After review of her personal products, it was discovered that her fish food contained propyl gallate (Fig. 2). The patient stated that 2 to 3 times per day, she crushed and then sprinkled the fish food in her aquariums using the thumb and second and third fingers of both hands, which were precisely the areas of her active dermatitis. She had begun using the fish food roughly 1 year before the onset of her symptoms. It was recommended that the patient either switch to gallate-free fish food or use protective gloves while feeding her fish. Her symptoms improved gradually during the following months with usage of gloves and avoidance of direct contact with the fish food.

Propyl gallate is an alkyl gallate commonly used in cosmetics, oils, fatty foods, and perfumes for its antioxidant properties and preservative qualities.[1] It has been shown to be a strong contact sensitizer, namely, in cases of dermatitis affecting the perioral region in which lip balm containing propyl gallate was identified as the allergen.[1,2] Cessation of the lip balm led to alleviation of dermatitis. In another case, propyl gallate in makeup and sandals was found to be the offending agent leading to contact depigmentation of the forehead and feet.[3] The most common reported symptoms of gallate dermatitis include erythema, pruritus, burning sensation, and edema; propyl gallate is the most commonly reported contact allergen of the gallate family.[4] After reading the ingredients of multiple types of fish food at a local pet store, it seems that propyl gallate is found in fish flakes, but not in fish food pellets.

Although there is a general paucity of literature on rates of gallate dermatitis, one European study showed that propyl gallate sensitivity seems to have increased in recent decades.[5] In that study, it was suggested that the change could potentially be attributed to the

Figure 1. On presentation, dermatitis was noted bilaterally on the distal aspects of the patient's first, second, and third digits.

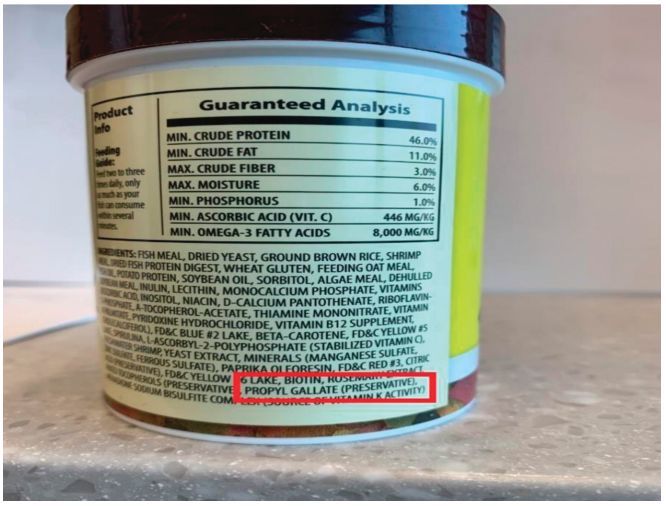

Figure 2. Ingredients list of patient's fish food revealed that it contained propyl gallate.

From the Medical College of Wisconsin Affiliated Hospitals, Wauwatosa.
Address reprint requests to David G. Holzer, BS, 2237 N 106th St, Wauwatosa, WI 53226. E-mail: dholzer@mcw.edu.

The authors have no funding or conflicts of interest to declare.

DOI: 10.1097/DER.0000000000000611

© 2020 American Contact Dermatitis Society. All Rights Reserved.

Copyright © 2021 American Contact Dermatitis Society. Unauthorized reproduction of this article is prohibited.

increased usage of gallates in cosmetics coupled with decreased usage in food, thereby decreasing oral tolerance.[5]

PEARL

Propyl gallate should be considered as a potential etiology of contact dermatitis in locations where fish food and other oily products are regularly handled.

REFERENCES

1. Kahn G, Phanuphak P, Claman HN. Propyl gallate–contact sensitization and orally-induced tolerance. *Arch Dermatol* 1974;109:506–509.
2. Yu Y, Scheinman PL. Lip and perioral dermatitis caused by propyl gallate. *Dermatitis* 2010;21:118–119.
3. Pandhi D, Vij A, Singal A. Contact depigmentation induced by propyl gallate. *Clin Exp Dermatol* 2011;36:366–368.
4. Holcomb Z, Van Noord M, Atwater AR. Gallate contact dermatitis: product update and systematic review. *Dermatitis* 2017;28:115–127.
5. Perez A, Basketter DA, White IR, et al. Positive rates to propyl gallate on patch testing: a change in trend. *Contact Dermatitis* 2008;58:47–48.

If Eczematous Lesions Are Difficult to Treat, Asking About Paints May Be the Key!

Ambra Di Altobrando, MD, Colombina Vincenzi, MD, Michelangelo La Placa, MD, Bianca Maria Piraccini, MD, Andrea Sechi, MD, and Iria Neri, MD

PRECÍS

We present a pediatric patient with atopic dermatitis (AD) and contact allergy to Kathon CG experiencing a worsening of cutaneous eczematous lesions, in which a simple question would have led to the correct diagnosis.

DISCUSSION

A 15-year-old girl with lifelong moderate AD was referred because of an impressive worsening of her cutaneous lesions of 2 months' duration. In addition to the flexural areas, which were chronically affected, cutaneous examination showed that eczematous patches had extended to other body regions, namely, abdomen, waistline, upper extremities, and thighs (Fig. 1). Because of her atopic diathesis, the girl had already undergone food/inhalant radioallergosorbent (RAST) and blood tests, including immunoglobulin E, with normal results, and prick test, showing a positivity to *Dermatophagoides pteronyssinus*. Moreover, the patient had already been tested at another hospital with the Italian Society of Allergological, Occupational and Environmental Dermatology baseline series, revealing allergic contact dermatitis (ACD) to Kathon CG 0.01% in petrolatum. The patient had not reacted to other allergens. Because the patient had been informed of the presence of Kathon GC in both personal care products and cosmetics, she had been careful afterwards to avoid products containing isothiazolinones. Her history showed that the recent eczematous lesions had only transiently improved with systemic cetirizine and topical methylprednisolone aceponate cream. Although the possibility of an exacerbation of AD was considered, a skin biopsy was performed to evaluate for other potential causes. Histologic examination demonstrated parakeratosis and focal spongiosis, mild epidermal psoriasiform hyperplasia with a preserved granular layer, and dilated dermal vessels with a perivascular, predominantly lymphocytic infiltrate. These findings were suggestive of subacute dermatitis. Subsequent history taking revealed that the worsening of the patient's dermatitis coincided with the painting of her bedroom walls, and that the paint used contained methylchloroisothiazolinone (MCI) and methylisothiazolinone (MI). Based on this timeline, exposure history, and previous patch test results, we suspected a diagnosis of airborne ACD secondary to isothiazolinone-containing wall paint. Over 1 month in which the patient avoided entering her room, the recent eczematous lesions gradually cleared with the application of topical methylprednisolone aceponate cream 2 times daily. Once the patient returned to the same room, her dermatitis

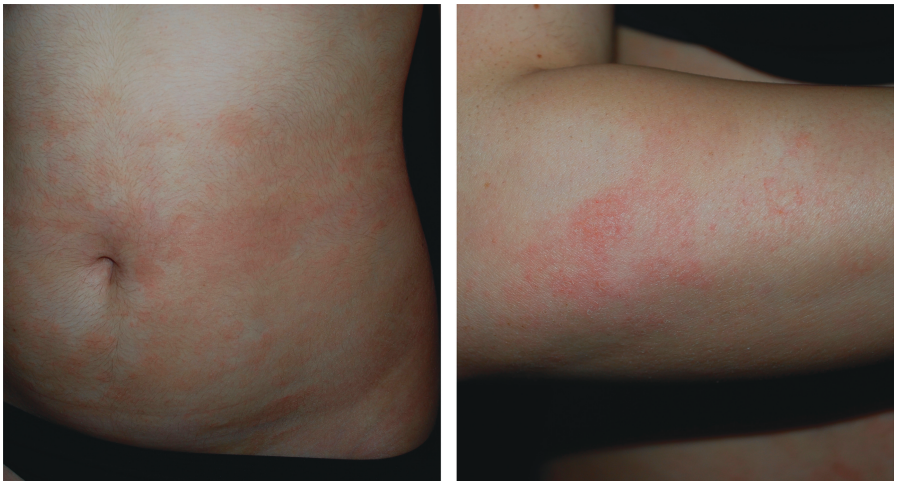

Figure 1. Erythematous patches on the abdomen (left) and extensor upper extremities (right).

Copyright © 2021 American Contact Dermatitis Society. Unauthorized reproduction of this article is prohibited.

did not flare. Notably, in the month when she had not been in her bedroom and even when she had returned, a well-aired environment had been guaranteed. However, the eczematous lesions on her flexural areas did not completely resolve.

Allergic contact dermatitis in AD can be challenging to diagnose. Although the relationship between AD and ACD is frequently debated, multiple factors can contribute to a higher risk of ACD in AD patients, including the breakdown of the skin barrier, compromised antimicrobial defenses, mutations in the filaggrin gene, and protracted exposure to chemical substances contained in skin care products.[1,2]

Kathon CG, a mixture of MCI and MI in the ratio of 3:1, is widely used as a preservative, including water-based paints. Because of its antimicrobial properties, MCI/MI prevents physical and chemical degradation of the products.[2] However, both wet and dried wall paints have been shown to release significant quantities of allergen over long periods, and may lead to severe and long-lasting dermatitis.[2,3]

Although in the current case the patient's wall paint product declared the presence of isothiazolinones on the label, this is not always the case.[4] Therefore, patients with isothiazolinone contact sensitization should be aware of this potential allergen source and consider alternative paint options free of this preservative.[5] Clinicians may be aided in the diagnosis and treatment of ACD by posing questions related to paint use to patients who are found to have isothiazolinone sensitization. Strategies to inactivate isothiazolinone or to paint over have been proposed as alternatives to physical removal of the isothiazolinone-containing paint layer.[2,5]

ZEBRA

In cases of recalcitrant dermatitis among patients with isothiazolinone contact allergy, consider paint as a potential culprit.

REFERENCES

1. Di Altobrando A, Vincenzi C, La Placa M, et al. When sneakers turn out to be false friends: allergic contact dermatitis to chromium in a 4-year-old child with atopic dermatitis. *Contact Dermatitis* 2020;82(5):320–321.
2. Bohn S, Niederer M, Brehm K, et al. Airborne contact dermatitis from methylchloroisothiazolinone in wall paint. Abolition of symptoms by chemical allergen inactivation. *Contact Dermatitis* 2000;42(4):196–201.
3. Amsler E, Aerts O, Raison-Peyron N, et al. Airborne allergic contact dermatitis caused by isothiazolinones in water-based paints: a retrospective study of 44 cases. *Contact Dermatitis* 2017;77(3):163–170.
4. Goodier MC, Siegel PD, Zang LY, et al. Isothiazolinone in residential interior wall paint: a high-performance liquid chromatographic-mass spectrometry analysis. *Dermatitis* 2018;29(6):332–338.
5. Gruye LE, Yanovsky RL, Goldminz AM. Preventing relapses of airborne allergic contact dermatitis to isothiazolinones in wall paint by painting over with an isothiazolinone-free paint. *Contact Dermatitis* 2020;82(2):130–131.

Allergic Contact Dermatitis to Boldo

Roberto Valdes, MD, Alexandra Feuereisen, and Matias Bellinghausen

DISCUSSION

A 64-year-old previously healthy man presented with 6 months of ongoing dermatitis on his face, arms, and dorsum of both hands. This time frame matched the purchase of a plot in Curacaví (Región Metropolitana, Chile), where boldo and quillai trees (*Peumus boldus* and *Quillaja saponaria*, respectively) are commonly found, along with a warehouse for processing leaves (Fig. 1) and bark of those trees.

The physical examination was compatible with allergic contact dermatitis in an airborne pattern. He was patch tested using the North American Contact Dermatitis Group standard series, cosmetic supplements series, botanical series, and his own tree elements, such as sawdust, twigs, and leaves, of both quillai and boldo. After 96 hours, he showed a positive reaction to boldo leaves (Fig. 2). To confirm the allergic reaction to this plant, in a second trial, we tested boldo essential oil 20% in petrolatum for which he tested positive as well (Fig. 3).[1] Ten volunteers were also tested to this dilution, and none showed an irritant reaction. During the follow-up, it was noted that after avoiding the exposure to boldo his dermatitis cleared. An eventual systemic reaction could not be assessed in this patient, because he denied the consumption of boldo as a tea.

Peumus boldus belongs to the Monimiaceae family of trees. It is endemic to the central region of Chile, where it can be found between the provinces of Limarí and Osorno.[2] Dry boldo leaves are

Figure 1. Boldo leaves.

Copyright © 2021 American Contact Dermatitis Society. Unauthorized reproduction of this article is prohibited.

Figure 2. Patient's mild erythematous rash reaction after 96 hours of exposure to boldo leaves.

often used to make infusions as a homemade digestive herbal tea, but they are also advertised as natural and safe in several other uses, including to manage rheumatologic and neuropathic pain.[2] The said medical properties are believed to come from the chemical components, such as essential oils, alkaloids, flavonoids, catechins, and resins, which have anti-inflammatory and antioxidant effects.[3,4] Outside of Chile and neighboring countries, dry boldo leaves can be found in specialized stores across North America and Europe.

In certain developing countries, more than 80% of the population uses some kind of alternative or complementary medicine. In Chile, more than 70% of people use them, and boldo is one of the most popular medicinal plants; more than a thousand tons of dry boldo leaves are consumed every year.[5] Although it has been proven that within treatment doses there are no toxic effects,[4] allergic contact dermatitis is an adverse effect to be considered, as shown earlier. In addition, high doses have been linked to abortions and teratogenic effects; therefore, the use of boldo is discouraged during pregnancy and lactation.[4]

ZEBRA

Boldo should be considered as a potential allergen in considering airborne allergic contact dermatitis in exposed patients or workers.

Figure 3. Patient's reaction after exposure to boldo essential oil 20% petrolatum.

REFERENCES

1. de Groot A, Schmidt E. Essential oils, part IV: contact allergy. *Dermatitis* 2016; 27:170–175.
2. Medicamentos Herbarios Tradicionales. Ministerio de Salud—Gobierno de Chile. Available at: https://www.minsal.cl/mht/. Published 2020. Accessed February 16, 2020.
3. Mejía-Dolores J, Mendoza-Quispe D, Moreno-Rumay E, et al. Neurotoxic effect of aqueous extract of boldo (*Peumus boldus*) in an animal model. *Rev Peru Med Exp Salud Publica* 2014;31:62–68.
4. Villar del Fresno A, Gomez-Serranillos P. Boldo. *Farm Prof* 2006;20:74–78.
5. Avello LM, Cisternas FI. Origins and situation of phytotherapy in Chile. *Rev Med Chil* 2010;138:1288–1293.

Airborne Allergic Contact Dermatitis to Vanillin

Priscilla Ly Kojder, MD*
and Corinne Leigh Erickson, MD†

PRECÍS

To our knowledge, we report the first case of vanillin as a direct cause of airborne allergic contact dermatitis.

Figure 1. Erythematous and edematous plaques of bilateral eyelids, cheeks, nasolabial folds, chin, and neck 48 hours after exposure to vanilla extract.

Copyright © 2021 American Contact Dermatitis Society. Unauthorized reproduction of this article is prohibited.

DISCUSSION

A 40-year-old woman presented to our clinic for patch testing after experiencing an erythematous and pruritic rash on the face and neck 24 hours after making homemade vanilla extract. The rash started as mild swelling and erythema surrounding the patient's eyes, which progressed to involve her cheeks, chin, and neck for 48 hours (Fig. 1). The process of making vanilla extract involved mixing Madagascar vanilla beans with Smirnoff Vodka, and the patient reported mixing large amounts to gift to family and friends for the holidays (Fig. 2).

Patch testing was performed with the American Contact Dermatitis Core Allergen Series and a supplemental patch of the patient's homemade vanilla extract. Readings at 48 hours revealed an irritant reaction to the vanilla extract. The readings at 72 hours were mostly unchanged, and an open scratch test with the vanilla extract was performed on the inner aspect of the patient's forearm to rule out contact urticaria. After 15 and 30 minutes, urticarial changes were not found. After 24 hours, however, the patient noted an edematous, erythematous, and pruritic plaque forming in the area tested (Fig. 3). Concurrently, her patch test reading at 96 hours demonstrated increased erythema and induration extending beyond the original borders in the area of homemade vanilla extract, suggesting a 2+ reaction.

Figure 2. The patient's homemade vanilla extract containing Madagascar vanilla beans and Smirnoff Vodka.

Figure 3. Erythematous and indurated plaque appearing 24 hours after the in-office scratch test with homemade vanilla extract.

Airborne contact dermatitis can occur when allergens are released into the atmosphere and settle on exposed skin. This may occur through heating volatile liquids to vaporize a sufficient amount of gas into the air or through dispersing tiny liquid or solid particles through various mediums such as sprays, powders, or smoke.[1] Our case of airborne allergic contact dermatitis is most likely explained by the mixing of a volatile alcohol with vanilla beans, allowing for the dissemination of vanillin into the air. Classic areas of exposed skin were involved in our patient including bilateral eyelids and the "V" of the neck. She also demonstrated the "beak sign," a clinical sign of airborne contact dermatitis, which refers to sparing of the nose due to high sebaceous content.[2] Given the timeline of her rash, a diagnosis of airborne allergic contact dermatitis to vanillin was made.

The standard protocol for patch testing is to remove the patches after 48 hours and perform a delayed reading at 72 to 96 hours after application.[3] Our patient's patch test reading for vanilla extract was interpreted as an irritant reaction at 48 and 72 hours. This led us to perform an open scratch test to rule out airborne contact urticaria. Use of a commercial patch for vanillin may have also prevented the irritant reaction, as standardized vanillin is tested at 10% in

Copyright © 2021 American Contact Dermatitis Society. Unauthorized reproduction of this article is prohibited.

petroleum. In a Patch Test Questionnaire sent to US dermatologists, nearly half of respondents performed both a 48- and 96-hour reading for patch testing, whereas a quarter of respondents performed a single reading at 48 or 72 hours.[4] As seen in this case, a patch test reading after 72 hours may be essential to accurately identify contact allergens.

ZEBRAS

Airborne allergic contact dermatitis to vanillin is rare. Patch testing can confirm the diagnosis, and it is important to consider delayed reactions that appear after 72 hours.

REFERENCES

1. Dooms-Goossens AE, Debusschere KM, Gevers DM, et al. Contact dermatitis caused by airborne agents. A review and case reports. *J Am Acad Dermatol* 1986;15:1–10.
2. Staser K, Ezra N, Sheehan MP, et al. The beak sign: a clinical clue to airborne contact dermatitis. *Dermatitis* 2014;25:97–98.
3. Matiz C, Russell K, Jacob SE. The importance of checking for delayed reactions in pediatric patch testing. *Pediatr Dermatol* 2011;28(1):12–14.
4. Warshaw EM, Nelson D. Prevalence of patch testing and methodology of dermatologists in the US: results of a cross-sectional survey. *Am J Contact Dermat* 2002;13:53–58.

Copyright © 2021 American Contact Dermatitis Society. Unauthorized reproduction of this article is prohibited.