Internal Medicine
The Japanese Society of Internal Medicine

doi: 10.2169/internalmedicine.1303-18
Intern Med Advance Publication
http://internmed.jp

【 CASE REPORT 】

Usefulness of Cardiac Magnetic Resonance in the Diagnosis of Löffler Endocarditis Secondary to Eosinophilic Granulomatosis with Polyangiitis

Kana Kurokawa[1], Eiryu Sai[2,3], Eri Hayashi[4], Kentaro Minowa[4], Koji Sugano[5], Takuma Yoshihara[2,3], Tadashi Miyazaki[2,3], Makoto Hiki[3], Takayuki Yokoyama[3], Masaru Suzuki[6] and Katsumi Miyauchi[2,3]

Abstract:

A 40-year-old man who was diagnosed with bronchial asthma and eosinophilia was transferred to our hospital due to a worsening respiratory status. He was diagnosed with eosinophilic granulomatosis with polyangiitis (EGPA), and eosinophilic pneumoniae. Cardiac magnetic resonance (CMR) imaging indicated Löffler endocarditis. Treatment was initiated using intravenous methylprednisolone, cyclophosphamide, and heparin as anticoagulation therapy. Three months later, CMR showed the improvement of the LV myocardium.

In this case, the early diagnosis of Löffler endocarditis by CMR could prevent systemic embolism and CMR was useful for assessing the curative effects of steroid and immunosuppressant therapy.

Key words: Cardiac magnetic resonance, Löffler endocarditis, Eosinophilic granulomatosis with polyangiitis

(Intern Med Advance Publication)
(DOI: 10.2169/internalmedicine.1303-18)

Introduction

Eosinophilic granulomatosis with polyangiitis (EGPA) is a systemic necrotizing vasculitis, with cardiac involvement that commonly includes pericarditis, ischemia, and myocarditis (1). The early diagnosis of cardiovascular events and treatment are necessary because a delayed diagnosis may be associated with a worse prognosis. We herein report the case of a patient who presented to our hospital with worsening dyspnea, chest oppression, and numbness gradually spreading from the sole of the foot, who was diagnosed with EGPA complicated by Löffler endocarditis.

Case

A 40-year-old man with a history of bronchial asthma, which had been diagnosed 10 years previously, was admitted to another hospital because of chest oppression and numbness gradually spreading from the sole of the foot. On admission, a laboratory analysis showed a white blood cell count of 30,500/mL with hypereosinophilia of 21,655/mL (71% of all white blood cells) and an elevated troponin T level (2.62 μg/L). Chest X-ray and whole-body computed tomography (CT) showed bilateral pneumonia, pleural effusion (Fig. 1-A, B), and paranasal sinusitis. Electrocardiography (ECG) showed an abnormal Q wave in V1-4 and horizontal ST depression in II III aVf V5-6. In addition, ultrasound cardiography (UCG) showed diffuse left ventricular

[1]Department of Respiratory Medicine, Juntendo University Graduate School of Medicine, Japan, [2]Department of Cardiovascular Medicine, Juntendo Tokyo Koto Geriatric Medical Center, Japan, [3]Department of Cardiovascular Medicine, Juntendo University Graduate School of Medicine, Japan, [4]Department of Internal Medicine and Rheumatology, Juntendo Tokyo Koto Geriatric Medical Center, Japan, [5]Department of Respiratory Medicine, Juntendo Tokyo Koto Geriatric Medical Center, Japan and [6]Department of Radiology, Juntendo Tokyo Koto Geriatric Medical Center, Japan
Received: April 2, 2018; Accepted: June 19, 2018; Advance Publication by J-STAGE: August 24, 2018
Correspondence to Dr. Eiryu Sai, eiryu@juntendo.ac.jp

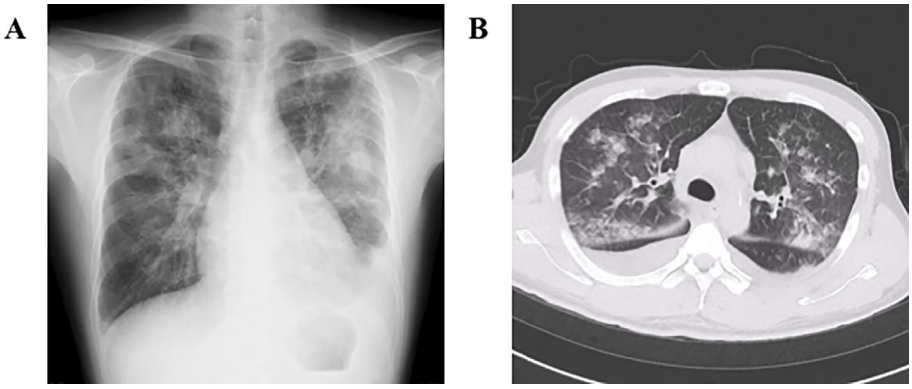

Figure 1. **(A) Chest X-ray showed bilateral pneumonia. (B) Whole-body CT revealed bilateral pneumonia and pleural effusion.**

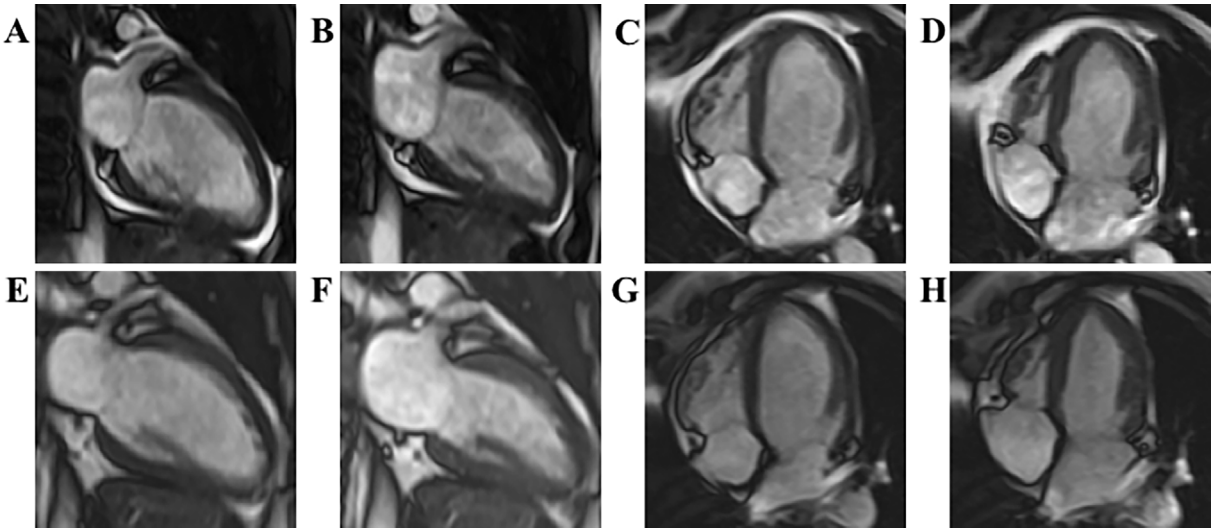

Figure 2. **Cine imaging. (A) End-diastolic two-chamber view at the onset of treatment. (B) End-systolic two-chamber view at the onset of treatment. (C) End-diastolic four-chamber view at the onset of treatment. (D) End-systolic four-chamber view at the onset of treatment. (E) End-diastolic two-chamber view after 3 months of treatment. (F) End-systolic two-chamber view after 3 months of treatment. (G) End-diastolic four-chamber view after 3 months of treatment. (H) End-systolic four-chamber view after 3 months of treatment.**

(LV) hypokinesis and pericardial effusion. Emergent coronary angiography showed no substantial signs of coronary artery disease or arterial occlusion.

The patient was transferred to our hospital due to fever, weight loss, and a worsening respiratory status. He was diagnosed with eosinophilic pneumonia, and steroid therapy was initiated with oral prednisolone (50 mg/day) after steroid pulse treatment with intravenous methylprednisolone (1,000 mg/day) for three days. Although anti-myeloperoxidase antineutrophil cytoplasm antibodies were not detected, his systemic symptoms and laboratory findings met the diagnostic criteria for EGPA. Intermittent intravenous cyclophosphamide pulse therapy (750 mg/day, every four weeks) was added to the steroid treatment. Heparin, as anticoagulation therapy, was initiated due to the possibility of complication with eosinophilic cardiomyopathy.

Cine imaging using the steady-state free precession technique demonstrated a decreased LV ejection fraction (28.0%) with diffuse severe LV hypokinesis and pericardial effusion (Fig. 2A-D), which was in line with the UCG findings. CMR imaging with gadolinium contrast showed extensive subendocardial late gadolinium enhancement (LGE) in the left ventricle, indicating the presence of inflammatory edema and fibrosis (Fig. 3A, B). The imaging characteristics of the partial myocardium on turbo spin-echo (TSE) T2-weighted imaging were compatible with Löffler endocarditis (Fig. 4A, B). Anticoagulation with warfarin was concurrently started to prevent stroke. Brain MRI performed before the patient left our hospital revealed no cerebral infarcts. Treatment with oral prednisolone was tapered to a maintenance dose of 5 mg/day at our hospital during outpatient treatment. The patient also received intravenous cyclophosphamide pulse treatment each month as immunosuppressant therapy.

Three months later, cine imaging showed the improvement of the LV ejection fraction (47.9%; Fig. 2E-H). The

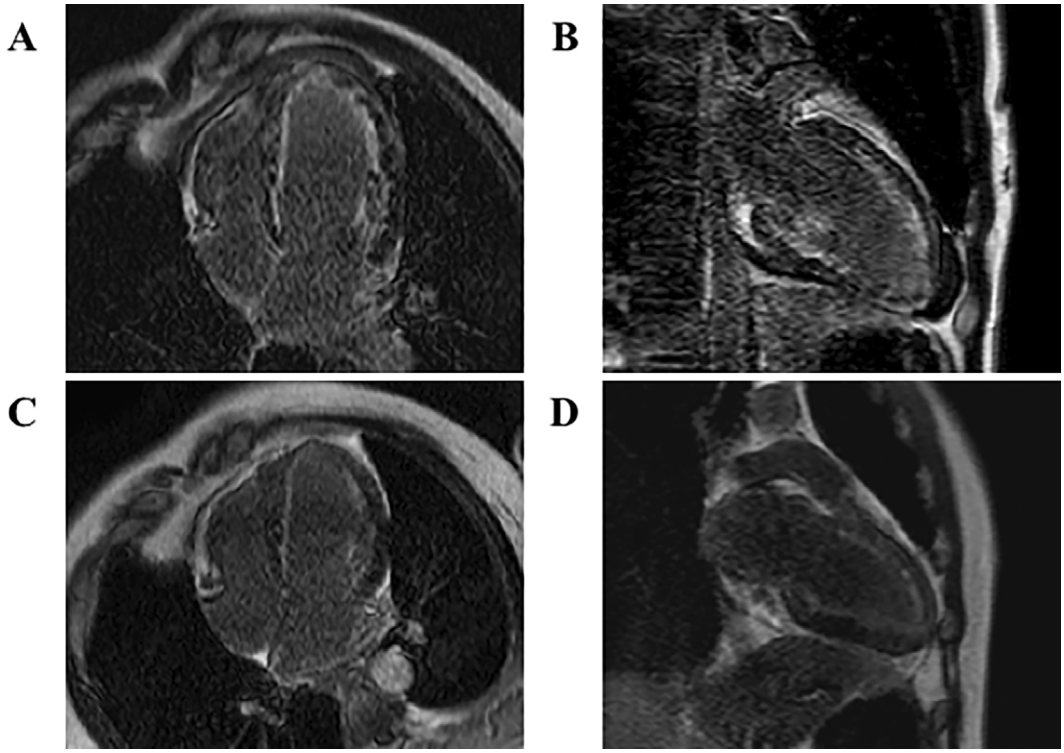

Figure 3. **Endocardial late gadolinium enhancement (LGE) indicating the presence of inflammatory edema and fibrosis. (A) Four-chamber view at the onset of treatment. (B) Two-chamber view at the onset of treatment. (C) Four-chamber view after three months of treatment. (D) Two-chamber view after three months of treatment.**

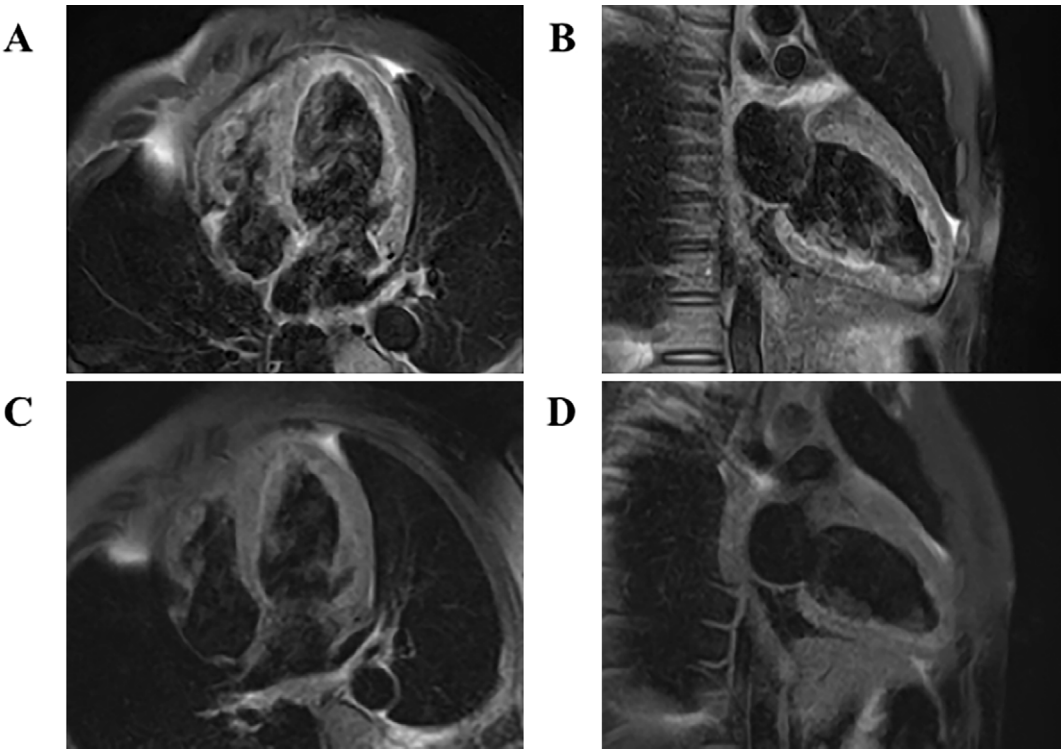

Figure 4. **T2-weighted imaging showed the presence of edema indicating inflammation in the left ventricular myocardium. (A) Four-chamber view at the onset of treatment. (B) Two-chamber view at the onset of treatment. (C) Four-chamber view after three months of treatment. (D) Two-chamber view after three months of treatment.**

disappearance of pericardial effusion was observed on cine imaging, the LGE area in the LV myocardium was found to have decreased (Fig. 3C, D), and the high-intensity area in the partial myocardium had normalized on TSE T2-weighted imaging (Fig. 4C, D).

In this case, CMR was useful for the early diagnosis of Löffler endocarditis to prevent systemic embolism, including cerebral infarct and assess the curative effects of steroid and immunosuppressant therapy.

Discussion

EGPA, formerly known as Churg-Strauss syndrome, is one of the rarest multisystemic vasculitis belonging to the small vessel anti-neutrophil cytoplasmic antibody-associated vasculitides. Once suspected, vasculitis involvement of the gut, kidney, and/or heart must be investigated because they have been proven to have a significant association with poorer progress (2). Approximately 15-56% of patients with EGPA show clinical cardiac manifestations (3). To detect cardiac abnormalities, diagnostic imaging (e.g., chest X-ray, ECG, and UCG) is initially performed. In particular, UCG provides adequate information about cardiac abnormalities, while CMR has been shown to be a superior noninvasive method for detecting myocardial involvement in patients with EGPA (4, 4).

In the present case, CMR imaging was performed to detect the cardiac involvement and showed extensive endocardial LGE of almost the entire left ventricle, which was compatible with Löffler endocarditis, as previously reported (6, 7). Although it was difficult to distinguish whether this was due to ischemic heart disease or Löffler endocarditis based on endocardial LGE, we could have diagnosed Löffler endocarditis based on the CMR results because coronary artery disease (CAD) was excluded from the coronary angiography results performed in the previous hospital. Löffler endocarditis is often associated with large thrombus formation, which may lead to systemic embolism. The initiation of anticoagulation therapy with heparin carries few risks, even without differentiating between CAD and Löffler endocarditis.

The greatest advantage of a diagnostic approach using CMR is the possibility of avoiding myocardial biopsy. We hesitated in performing CMR due to a cardiac rhythm abnormality and a worsening of the respiratory status. Fortunately, sinus rhythm was maintained in this case; thus, CMR was immediately performed after the patient's breathing status improved following steroid therapy. Cine and LGE imaging may be sufficient to make a diagnosis of Löffler endocarditis. In this case, T2-weighted imaging was the key method for investigating the presence of edema indicating inflammation in the LV myocardium. Cine imaging revealed pericardial effusion and diffuse hypokinesis of the LV wall motion. These findings showed that eosinophilic myocarditis was complicated. CMR is reported to be a useful tool for monitoring reversible and irreversible myocardial tissue injuries over the course of myocarditis (7). Comparing T2-weighted imaging with LGE imaging makes it easy to assess inflammation of the LV myocardium.

EGPA with Löffler endocarditis is frequently associated with a poor prognosis. Thus, cardiovascular problems should be evaluated and treatment should be started as early as possible. CMR may also be useful for assessing cardiovascular problems secondary to EGPA and for determining curative effects without myocardial biopsy.

Disclosures

The authors declare no conflicts of interest in association with the present study.

The authors state that they have no Conflict of Interest (COI).

Acknowledgement

The authors would like to extend their profound gratitude to Hidenori Kakizoe, R.T., Masanobu Takahashi, R.T., and Yoshitaka Noguchi, R.T., Juntendo Tokyo Koto Geriatric Medical Center Department of Radiology, for their invaluable technical support on CMR.

References

1. Hasley PB, Follansbee WP, Coulenhan JL. Cardiac manifestations of Churg-Strauss syndrome: report of a case and review of the literature. Am Heart J **120**: 996-9, 1990.
2. Guillevin L, Pagnoux C, Seror R, Mahr A, Mouthon L, Le Toumelin P. French Vasculitis Study Group (FVSG). The Five-Factor Score revisited: assessment of prognoses of systemic necrotizing vasculitides based on the French Vasculitis Study Group (FVSG) cohort. Medicine **90**: 19-27, 2011.
3. Mouthon L, Dunogue B, Guillevin L. Diagnosis and classification of eosinophilic granulomatosis with polyangiitis (formerly named Chaurg-Strauss syndrome). J Autommun **48-49**: 99-103, 2014.
4. Marmursztejn J, Vignaux O, Cohen P, Guilpain P, Gouya H, Mouthon L, Legmann P, Duboc D, Guillevin L. Impact of cardiac magnetic resonance imaging for assessment of churg-Strauss syndrome: a cross-sectional study in 20 patients. Clin Exp Rheumatol **27**: S70-6, 2009.
5. Szczeklik W, Miszalski-Jamka T, Mastalerz L, Sokolowska B, Dropinski J, Banys R, Hor KN, Mazur W, Musial J. Multimodality assessment of cardiac involvement in Churg-Strauss syndrome patients in clinical remission. Circ J **75**: 649-55, 2011.
6. Schreiber K, Zuern CS, Gawaz M. Loeffler endocarditis: findings on magnetic resonance imaging. Heart **93**: 354, 2007.
7. Zagrosek A, Adbel-sty H, Boyé P, Wassmuth R, Messroghli D, Rudolph A, Bohl S, Dietz R, Schulz-Menger J. Cardiac magnetic resonance monitors reversible and irreversible myocardial injury in myocarditis. JACC Cardiovasc Imaging **2**: 131-138, 2009.

The Internal Medicine is an Open Access article distributed under the Creative Commons Attribution-NonCommercial-NoDerivatives 4.0 International License. To view the details of this license, please visit (https://creativecommons.org/licenses/by-nc-nd/4.0/).

© The Japanese Society of Internal Medicine