[Downloaded free from http://www.njcponline.com on Wednesday, November 14, 2018, IP: 78.13.220.127]

Original Article

# Anisakiasis: The Risks of Seafood Consumption

*K Furuya, H Nakajima[1], Y Sasaki, Y Urita*

Department of General Medicine and Emergency Care, School of Medicine, Omori Hospital, Toho University, Tokyo, [1]Department of Internal Medicine, Kizukuri Adult Disease Center, Aomori, Japan

**Abstract**

**Context and Aims:** Japanese cuisine is now popular worldwide, and consumption of raw fish has thus increased at sushi bars and Japanese restaurants outside Japan. Anisakiasis, also known as herring-worm disease, is caused by ingesting larval nematodes in raw seafood and is a common illness in Japan. However, due to the rising popularity of Japanese food, gastroenterologists outside Japan need to be familiar with this disease. **Subjects and Methods and Results:** We treated 158 patients presenting with acute gastrointestinal manifestations caused by anisakiasis from April 1991 to April 2000. One or more nematodes were removed endoscopically within 48 h of presentation in 44% of these patients, which resulted in prompt resolution of symptoms. Major endoscopic findings were gastric ulcer accompanied by hemorrhage, erosion, redness, and edema of the gastric mucosa in areas penetrated by larvae and other areas. **Conclusions:** Endoscopy was valuable for the diagnosis and treatment of anisakiasis. We recommend endoscopy in suspected cases of anisakiasis. Moreover, it is desirable to combine complementary tests such as immunological tests/IgE measurement. As the popularity of Japanese cuisine increases, reports of anisakiasis are likely to be more frequent in countries other than Japan.

**Keywords:** *Anisakiasis, Anisakis, herring worm, Japanese cuisine, Pseudoterranova, raw fish*

**Date of Acceptance:**
08-Jul-2018

## Introduction

The larvae of nematode parasites in marine animals can inhabit or invade the gastrointestinal tract of humans, causing a condition known as anisakiasis, also known as herring-worm disease, or heterocheilidiasis. Sushi, sashimi, and seafood salads made from sliced raw fish are the foods usually responsible for this condition. The rising popularity of Japanese cuisine worldwide has increased opportunities for the consumption of raw fish at sushi bars and Japanese restaurants. Thus, people in countries other than Japan are likely to encounter this disease.

## Subjects and Methods

We reviewed the medical records of patients who developed acute gastrointestinal manifestations after ingesting raw seafood; gastric herring worms were observed endoscopically in 158 patients at the Department of Internal Medicine, Kizukuri Adult Disease Center (Tsugaru city, Aomori prefecture, Japan), a related hospital of Toho University Omori Medical Center from April 1991 to April 2000. The clinical features of these patients, such as symptoms, causative food, and worm location, were investigated. The Institutional Review Board of our hospital approved the review of patient medical records.

## Results

Epigastric pain is the primary feature of anisakiasis, but patients exhibit varied symptoms, including acute gastrointestinal manifestations. Rarely, no symptoms were reported [Table 1]. The reported interval from

***Address for correspondence:*** Dr. K Furuya, 6-11-1 Omori-Nishi, Ota-Ku, Tokyo 143-8541, Japan. E-mail: emmanuelpetit1717@yahoo.co.jp

**Access this article online**

**Quick Response Code:**

**Website**: www.njcponline.com

**DOI**: 10.4103/njcp.njcp_256_17

This is an open access journal, and articles are distributed under the terms of the Creative Commons Attribution-NonCommercial-ShareAlike 4.0 License, which allows others to remix, tweak, and build upon the work non-commercially, as long as appropriate credit is given and the new creations are licensed under the identical terms.

**For reprints contact:** reprints@medknow.com

**How to cite this article:** Furuya K, Nakajima H, Sasaki Y, Urita Y. Anisakiasis: The risks of seafood consumption. Niger J Clin Pract 2018;21:1492-4.

[Downloaded free from http://www.njcponline.com on Wednesday, November 14, 2018, IP: 78.13.220.127]



**Table 1: Symptoms caused by herring worm disease**

| Symptons | Number of cases |
|---|---|
| Epigastic pain | 121 (51%) |
| Nausea | 37 (17%) |
| Vomiting | 26 (11%) |
| Uriticaria | 11 (5%) |
| Diarrhea | 11 (5%) |
| Epigastic discomfort | 10 (4%) |
| Midabdominal pain | 3 |
| Left hypochondralgia | 3 |
| Back pain | 1 |
| Low abdominal pain | 1 |
| No symptons | 3 |
| Unknown | 9 |

**Table 2: Time interval from ingestion to symptom appearance**

| Time from ingestion | Number of cases |
|---|---|
| ~1 h | 4 |
| ~2 | 5 |
| ~3 | 22 |
| ~4 | 6 |
| ~5 | 8 |
| ~6 | 14 |
| ~7 | 2 |
| ~8 | 4 |
| ~9 | 3 |
| ~10 | 5 |
| Over 10 h | 12 |
| Unknown | 76 |

**Figure 1:** Herring frequently have worms, which are the origin of anisakiasis

ingestion of the causative food to symptom onset was usually 2–6 h [Table 2]. One or more herring worms were removed endoscopically within 48 h of infection in 44% of the present patients, which resulted in prompt resolution of symptoms. The endoscopically removed larvae were identified by morphology as *Anisakis* (64%) and *Pseudoterranova* (36%). Major endoscopic findings were gastric ulcer accompanied by hemorrhage, erosion, redness, and edema of the gastric mucosa in areas penetrated by larvae and other areas. The worms were mostly located in the upper gastrointestinal tract, and the greater curvature of the gastric antrum was the most frequent (52.2%) site [Table 3]. The causative foods are shown in Table 4. Although cod was the most common culprit in our patients, all types of fish and fish products can harbor the causative larvae.

**Table 3: Location of worms**

| Location | *Pseudoterranova* | *Anisakis* |
|---|---|---|
| Esophagus | 0 | 3 |
| C | | |
| Anterior | 0 | 0 |
| Lesser curv | 1 | 4 |
| Posterior | 2 | 0 |
| Greater curv | 0 | 1 |
| M | | |
| Upper | | |
| Anterior | 0 | 1 |
| Lesser curv | 1 | 2 |
| Posterior | 8 | 8 |
| Greater curv | 10 | 16 |
| Middle | | |
| Anterior | 0 | 2 |
| Lesser curv | 0 | 3 |
| Posterior | 3 | 3 |
| Greater curv | 4 | 15 |
| Lower | | |
| Anterior | 1 | 5 |
| Lesser curv | 3 | 0 |
| Posterior | 5 | 7 |
| Greater curv | 2 | 13 |
| A | | |
| Anterior | 0 | 7 |
| Lesser curv | 1 | 6 |
| Posterior | 0 | 9 |
| Greater curv | 5 | 24 |
| Duodenum | 0 | 1 |
| Total | 46 | 130 |

C: Cardia, M: Body, A: Antrum

**Table 4: Causative food in herring worm disease**

| Kind of food | *Pseudoterranova* | *Anisakis* | Total |
|---|---|---|---|
| Cod | 28 | 15 | 43 |
| Tuna | 2 | 19 | 21 |
| Squid | 2 | 19 | 21 |
| Salmon | 0 | 19 | 19 |
| Shark | 1 | 14 | 15 |
| Mackerel | 0 | 13 | 13 |
| Flat fish | 3 | 6 | 9 |
| Yellow tail | 1 | 8 | 9 |
| Cod testicles | 1 | 5 | 6 |
| Cod ovaries | 0 | 6 | 6 |
| Herring | 0 | 3 | 3 |
| Other | 2 | 7 | 9 |

[Downloaded free from http://www.njcponline.com on Wednesday, November 14, 2018, IP: 78.13.220.127]



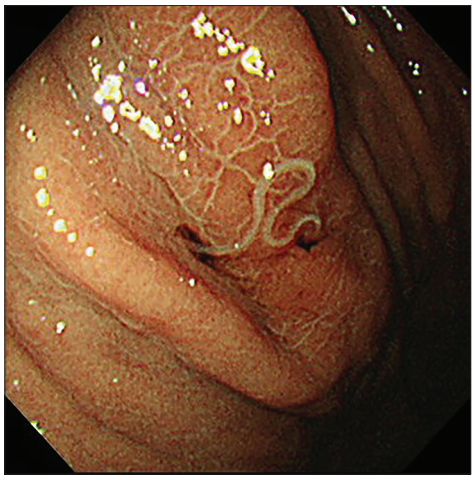

**Figure 2:** Nematode found at corpus of the stomach at greater curvature

## Discussion

Anisakiasis originated in fish such as herring [Figure 1], cod, squid, mackerel, and the worms are frequently found in the stomach by gastroendoscopy [Figure 2]. Anisakiasis is a fish-borne parasitic disease caused by consumption of raw or undercooked fish. The parasitic species are the third-stage larvae of the *Anisakidae* family, including *Anisakidae, Anisakis pegreffi*, and *Pseudoterranova*. Approximately 20,000 cases are reported annually – mostly in countries with high-fish consumption, such as Japan.[1] In Japan, the clinical research on anisakiasis began in the 1950s, because of the cultural tradition of eating raw fish. It is believed that freezing effectively kills *Anisakis* species. For example, salmon is usually frozen at −20°C for at least 48 h in Japan. In recent years, countries outside Japan began to report an increase of human infections caused by the *Anisakis* species. Japanese cuisine is included on the Intangible Culture Heritage List of the United Nations Educational, Scientific and Cultural Organization; thus, the opportunities to eat raw fish at sushi bars and Japanese restaurants outside Japan are increasing. Therefore, gastroenterologists outside Japan need to familiarize themselves with this disease. Dutch law requires fish to be frozen at a temperature lower than −20°C for longer than 24 h, and this recommendation is supported by the hygiene standards of the European Union. In 2005, the United States Food and Drug Administration announced that *A. simplex* dies at low temperatures.[2] In a related study, freezing at a temperature lower than −20°C for longer than 60 h was required to completely kill *A. simplex*. These findings appear to contradict the aforementioned law in the Netherlands.

Studies indicate that the causative fish and fish products differ for seafood from the North Atlantic Sea,[3] North Sea,[4] and Mediterranean Sea.[5] With the rising popularity of Japanese cuisine outside Japan, we believe that studies of Japanese seafood, such as this one, should be performed in countries outside Japan so that the necessary information can be collected worldwide. Although most consumers are aware of the risk of parasitic disease when consuming raw seafood, a large-scale study of the processing and freezing of raw seafood is required to ensure parasite-free seafood.

Despite the low incidence of anisakiasis, gastroenterologists, and internists need to be aware of it in clinical practice. First, a complete medical history is important. Second, immediate endoscopy with abdominal ultrasonography is the best procedure for diagnosis and treatment in suspected cases. Although we could not collect data in the present study, we should also consider about immunological tests (specific IgE), because these measurements are can be minimally invasive and valuable. The primary symptom, abdominal pain, usually resolves soon after nematode removal. We found no living nematodes in cod after freezing; however, premium sushi is often made from fresh rather than frozen fish.

## Conclusions

The rising popularity of Japanese foods such as sashimi and sushi is likely to increase the incidence of anisakiasis in many countries. Sushi and sashimi are established Japanese traditional foods and are popular in seafood restaurants. Physicians need to be more aware of the risk of anisakiasis. Moreover, additional surveillance of this disease is warranted.

### Financial support and sponsorship

Nil.

### Conflicts of interest

There are no conflicts of interest.

## References

1. Pravettoni V, Primavesi L, Piantanida M. *Anisakis* simplex: Current knowledge. Eur Ann Allergy Clin Immunol 2012;44:150-6.
2. Adams AM, Ton MN, Wekell MM, MacKenzie AP, Dong FM. Survival of *Anisakis* simplex in arrowtooth flounder (*Atheresthes stomia*) during frozen storage. J Food Prot 2005;68:1441-6.
3. Levsen A, Lunestad BT. *Anisakis* simplex third stage larvae in Norwegian spring spawning herring (*Clupea harengus* L.), with emphasis on larval distribution in the flesh. Vet Parasitol 2010;171:247-53.
4. Smith JW, Wootten R. Experimental studies on the migration of *Anisakis* sp. larvae (Nematoda: Ascaridida) into the flesh of herring, *Clupea harengus* L. Int J Parasitol 1975;5:133-6.
5. Rello FJ, Adroher FJ, Benítez R, Valero A. The fishing area as a possible indicator of the infection by anisakids in *Anchovies* (*Engraulis encrasicolus*) from Southwestern Europe. Int J Food Microbiol 2009;129:277-81.