Drugs
https://doi.org/10.1007/s40265-019-01173-2

REVIEW ARTICLE

Pharmacotherapies for the Treatment of Eosinophilic Esophagitis: State of the Art Review

Willemijn E. de Rooij[1] · Evan S. Dellon[2] · Claire E. Parker[3] · Brian G. Feagan[3,4,5] · Vipul Jairath[3,4,5] · Christopher Ma[3,6] · Albert J. Bredenoord[1]

© Springer Nature Switzerland AG 2019

Abstract

Eosinophilic esophagitis (EoE), a chronic allergic disorder of the esophagus, is characterized by symptoms of esophageal dysfunction and eosinophil-predominant inflammation. The incidence of EoE has increased substantially over the past two decades, coinciding with the so-called allergy epidemic. Current treatment options consist of dietary intervention, endoscopic dilatation, and pharmacotherapy. Given that EoE is a chronic progressive disease that is prone to relapse after cessation of therapy, these treatment options are suboptimal for long-term management. Persistent, uncontrolled esophageal inflammation is associated with esophageal remodeling and stricture formation, thus, the creation and/or discovery of alternative treatments is of paramount importance. The pathogenesis of EoE is currently under intense investigation, and recent insights concerning cellular and molecular etiology have led to the development of therapies that target specific pathophysiological pathways. This article provides an overview of established EoE pharmacotherapies, which include proton pump inhibitors and swallowed topical steroids. Additionally, anti-allergic targets, immunosuppressives, and monoclonal antibodies (such as mepolizumab, reslizumab, QAX576, RPC4046, dupilumab, omalizumab, and infliximab) that have been evaluated as treatments for EoE are summarized. Finally, several promising therapeutic agents (e.g., sialic acid-binding immunoglobulin-like lectin 8 antibodies, the transforming growth factor-β1 signal blocker losartan, CC chemokine receptor type 3 antagonists, thymic stromal lymphopoietin antibodies, antibodies targeting the α4β7 integrin, anti-interleukin-9 antibodies, and anti-interleukin-15 antibodies) that target specific molecules or cells implicated in the pathogenesis of EoE are proposed.

1 Introduction

Eosinophilic esophagitis (EoE) is a chronic, progressive, T-helper type 2 (Th2) immune-mediated disorder characterized by symptoms of esophageal dysfunction and eosinophil-predominant inflammation [1, 2]. The incidence and prevalence of EoE has risen considerably since it was first described as a unique disease entity in the early 1990s [3–6]. In industrialized countries, incidence and prevalence estimates are five to ten cases per 100,000 individuals and 0.5–1 per 1000 individuals, respectively [3, 7–13]. By comparison, these rates are similar to those of Crohn's disease [14]. The rise of EoE coincides with the global so-called allergy epidemic, and most patients with EoE have atopic comorbidities such as allergic rhinitis, asthma, immunoglobulin E (IgE)-mediated food allergies and atopic dermatitis [15, 16]. The peak incidence of EoE is between the ages of 20 and 40 years, with a 3:1 male-to-female ratio in every age group [17]. Children often present with non-specific symptoms of abdominal pain, failure to thrive and feeding disorder, whereas adults typically experience dysphagia and food impaction [1, 2, 18].

When EoE is suspected on clinical grounds, an upper endoscopy with at least six biopsies taken from two levels

✉ Albert J. Bredenoord
a.j.bredenoord@amc.uva.nl

1 Department of Gastroenterology and Hepatology, Academic Medical Centre, PO Box 22660, 1100 DD Amsterdam, The Netherlands

2 Division of Gastroenterology and Hepatology, Center for Esophageal Diseases and Swallowing, University of North Carolina School of Medicine, Chapel Hill, NC, USA

3 Robarts Clinical Trials Inc, London, ON, Canada

4 Department of Medicine, University of Western Ontario, London, ON, Canada

5 Department of Epidemiology and Biostatistics, University of Western Ontario, London, Canada

6 Division of Gastroenterology and Hepatology, University of Calgary, Calgary, AB, Canada

Published online: 27 July 2019

Key Points

The incidence of eosinophilic esophagitis (EoE) has increased substantially over the past two decades, coinciding with the so-called allergy epidemic.

Current treatment options consist of dietary intervention, endoscopic dilatation, and pharmacotherapy, including proton pump inhibitors and swallowed topical corticosteroids.

The pathogenesis of EoE is currently under intense investigation, and recent insights concerning cellular and molecular etiology have led to the development of therapies that target specific pathophysiological pathways.

of the esophagus is recommended [19]. Endoscopic disease activity is detected in approximately 90% of symptomatic patients. While edema, linear furrows, and white exudates are common in pediatric EoE, both inflammatory and fibrotic features—including rings and strictures—frequently manifest in adults [20]. A diagnosis of EoE is confirmed if at least one esophageal biopsy shows a minimum of 15 eosinophils per high power field (eos/hpf) and other causes of esophageal eosinophilia are excluded [21].

In clinical practice, the management of EoE has historically consisted of the "3-D approach": diet, drugs, and dilation, with the choice of strategy depending on disease phenotype (inflammatory and/or fibrotic) and patient preferences. A therapeutic algorithm is proposed in the European EoE guidelines, as shown in Fig. 1 [21].

Patients with EoE are prone to relapse following initial response to therapy, and longstanding inflammation is associated with esophageal remodeling and consecutive stricture formation [22–24]. Although reducing or eliminating esophageal inflammation may prevent the fibrotic process, direct evidence to support this theory is lacking. Thus, the treatment objectives in EoE are to reduce symptoms of esophageal dysfunction and prevent long-term complications and esophageal damage by maintaining histologic remission.

This article summarizes the contemporary pharmacological strategies for treating EoE, the drugs currently under investigation, and the therapeutic targets on the horizon.

2 Goals of Therapy

Management of EoE requires an integrated approach, with identification and avoidance of dietary antigens playing a fundamental role. The short-term goals of medical therapy include symptom resolution and attainment of histologic remission, defined as an eosinophil count of < 15 eos/hpf, while a growing body of evidence indicates that prevention of dysmotility and strictures is a long-term management goal [22, 24]. Thus, medical treatments that prevent submucosal fibrosis and tissue remodeling are of considerable interest.

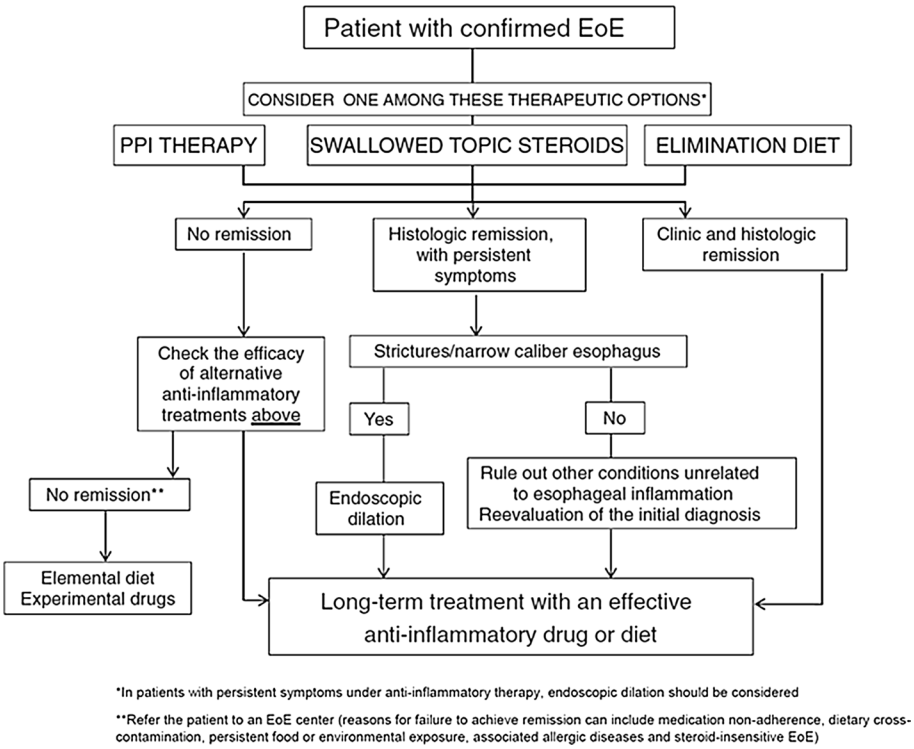

Fig. 1 Therapeutic algorithm proposed by Lucendo et al. [21] for treating eosinophilic esophagitis in clinical practice

Whether targeted anti-inflammatory therapy can achieve this goal, or a need exists for antifibrotic agents capable of changing the natural course of disease, are critical questions for drug development.

2.1 Induction and Maintenance Therapy

After successful induction of remissin with corticosteroids, EoE recurs almost uniformly with drug cessation. Accordingly, effective maintenance therapy is needed [1, 25, 26]. A growing body of evidence demonstrates the value of proton pump inhibitors (PPIs) as maintenance agents. Sustained 1-year remission rates of approximately 70–80% have been reported for low-dose PPI maintenance therapy among children and adults [27–29]. Long-term PPI use is generally well-tolerated, although the lowest effective dose should be used to minimize potential complications [30, 31]. Most efficacy data for swallowed topical corticosteroids comes from short-term induction studies, and, as such, the efficacy and safety of maintenance therapy with these agents is poorly understood. Observational studies suggest that the benefits of corticosteroids diminish over time [32, 33]. Only one placebo-controlled randomized controlled trial (RCT) has evaluated the effect of swallowed budesonide (0.25 mg twice daily [BID]). After 1 year of follow-up, 35.7% (5/14) of patients receiving budesonide and 0% (0/14) of those receiving placebo achieved disease remission [34]. In a prospective, open-label study of 54 children who received swallowed aerosolized fluticasone, a sustained remission rate of 63% was observed after 2 years of follow-up [35].

Potential adverse events associated with long-term systemic corticosteroid exposure include oral and esophageal candidiasis infections, adrenal suppression, growth retardation, osteopenia, osteoporosis, glucose intolerance, and cataract formation [18, 36, 37]. However, the limited absorption and high first-pass metabolism by the liver mean the systemic effects of swallowed corticosteroids are minimal [38]. The fibrosing nature of the EoE disease process and high rate of recurrence following cessation of induction therapy may require prolonged treatment. At present, the minimum dose of swallowed topical corticosteroids required to effectively and safely maintain remission of EoE is unknown. Furthermore, existing data indicate that the durability of this strategy is suspect [39].

2.2 Management of Complications and Treatment Algorithms

Esophageal rigidity, with symptoms such as dysphagia and food impaction, are consequences of the progressive, fibrostenotic course of EoE. Each additional year of undiagnosed EoE is estimated to increase the risk of stricture by 9% [24]. Therefore, prevention and reversal of structural remodeling and fibrosis are attractive therapeutic goals [1]. In EoE, the Th2 response is characterized by several pro-inflammatory cytokines that promote eosinophil activation and recruitment to the esophageal tissue as well as activation of basophils and mast cells [40–42]. Eosinophils express transforming growth factor (TGF)-β, which induces tissue fibrosis and subsequent esophageal remodeling and stricture formation [43]. In addition, wall stiffness increases esophageal smooth muscle cell gene expression of phospholamban and collagen I by mechanical signals ("mechanosignaling"), which results in smooth muscle hypertrophy. This inflammation-independent mechanism implies that treatment strategies focused on blocking the effects of inflammatory mediators may be effective in EoE management [44].

In clinical practice, choice of treatment strategy depends on EoE phenotype (inflammatory and/or fibrostenotic) and patient preferences [21]. Both dietary intervention and swallowed topical corticosteroids are efficacious in patients with an inflammatory phenotype [45, 46], whereas patients with fibrostenosing disease may be less likely to respond to an elimination diet [47]. Limited evidence indicates that control of inflammation may decrease the need for subsequent esophageal dilation of fibrostenotic strictures in adult patients with EoE, thereby suggesting that remission of eosinophilic inflammation reduces the process of tissue remodeling and fibrosis [48]. However, other studies have shown that resolution of superficial epithelial eosinophilia does not preclude subepithelial remodeling and progression to stricture formation [47, 49, 50]. The process of subepithelial remodeling and fibrosis requires further elucidation, with a key question being whether this progression is reversible. Although age and disease duration may be critical factors for disease progression, little is known about other determinants. Better understanding of the molecular mechanisms of fibrosis in EoE are needed to inform clinical decision making.

3 Proton Pump Inhibitors

The role of PPIs in EoE management has evolved over the last two decades. Past guidelines recommended initiating 8 weeks of high-dose PPI therapy in patients with a suspected diagnosis of EoE to rule out PPI-responsive esophageal eosinophilia (PPI-REE)—a designation used to describe patients with symptomatic, endoscopic, and histologic evidence of EoE who do not present with gastroesophageal reflux disease (GERD) yet respond to PPI therapy [1, 21, 51]. More recent insights indicate that although PPI-REE is a sub-phenotype of EoE, GERD and EoE are not mutually

exclusive [52]. It is hypothesized that (1) increased acid exposure may be secondary to EoE since esophageal dysmotility contributes to reflux and (2) patients with GERD are predisposed to develop EoE given that gastric acid damages the mucosal barrier [53]. For this reason, PPIs are now used as first-line or adjunctive therapy in both PPI-REE (though this term is being phased out) and EoE with co-existing GERD [19].

Additional observations support the notion that a complex relationship exists between acid reflux and EoE. Patients with EoE are more sensitive to acid exposure than are healthy controls, and PPIs are effective for reducing pain [54]. The efficacy of PPIs for reducing symptomatic esophageal eosinophilia has been reported in several case series and a small clinical trial that showed a 50% (5/10) rate of disease remission after 8 weeks of PPI therapy [55–58]. According to a systematic review and meta-analysis that included data from 619 patients (188 children and 431 adults) with symptomatic esophageal eosinophilia, 60.8% (376/619) of cases had clinical improvement and 50.5% (313/619) cases achieved histologic remission (defined as < 15 eos/hps) after PPI treatment [59]. The mechanism by which PPIs reduce esophageal eosinophilia may be secondary to restoration of mucosal barrier integrity and reduced environmental allergen exposure [60].

The potential role of acid suppression in EoE management is also supported by the observation that vonoprazan, a potassium-competitive acid blocker (P-CAB), induces histologic remission in patients with EoE that do not respond to PPIs [61]. However, PPIs are associated with several acid-independent anti-inflammatory effects that may reduce esophageal eosinophilia, including attenuation of Th2-cytokine-induced eotaxin-3 expression—a process relevant to reduced eosinophil activation and migration [62–64]. PPIs also inhibit acid-induced endothelial expression of adhesion molecules (including intracellular adhesion molecule 1 and vascular cell adhesion molecule 1), which may decrease eosinophilic inflammation [65]. In contrast to the effect on epithelial cells, PPIs do not appear to inhibit Th2-cytokine stimulated eotaxin-3 expression by esophageal fibroblasts directly, suggesting that PPIs have limited impact on esophageal remodeling and fibrosis formation [66].

Although PPIs are endorsed in current EoE treatment guidelines, no specific recommendations exist regarding the role of PPIs as initial or combination therapy [19]. PPI use remains off-label as this drug class has not been formally registered by any regulatory agency as an EoE therapy.

4 Topical Corticosteroids

Swallowed topical corticosteroids are a mainstay of EoE therapy that provide an anti-inflammatory effect by non-specifically inhibiting the Th2 immune response, with secondary improvement in esophageal barrier integrity and reduced esophageal remodeling and fibrosis [67, 68]. An observational study of 20 pediatric patients who received methylprednisolone 1.5 mg/kg BID for 4 weeks provided the first evidence that oral corticosteroids are effective in treating EoE. Clinical remission and clinical response were achieved in 65% (13/20) and 95% (19/20) of patients, respectively, with the average number (± standard deviation [SD]) of eos/hpf declining from 34.2 ± 9.6 to 1.5 ± 0.9 [69]. At 12 months after treatment, 50% (10/20) of patients remained asymptomatic. In a subsequent RCT of 80 pediatric patients with EoE, no difference was observed between the oral systemic corticosteroid prednisone 1 mg/kg BID and oral topical corticosteroid fluticasone propionate (two puffs [110 µg/puff] four times daily). After 4 weeks of therapy, 95% (30/32) of patients receiving prednisolone and 94% (34/36) of those assigned to fluticasone propionate attained combined clinical remission and histologic improvement [26]. Importantly, systemic adverse events (e.g., hyperphagia, weight gain, and cushingoid features) were reported in 40% (16/40) of prednisolone-treated patients, whereas none of the topically treated patients experienced systematic, steroid-related adverse events. It should be noted that 15% (6/40) of fluticasone propionate-treated patients developed esophageal candidiasis compared with 0% (0/40) in the prednisolone group.

No corticosteroids are currently approved by the US FDA for the treatment of EoE. Nevertheless, oral aerosolized fluticasone propionate and oral viscous budesonide are frequently prescribed as off-label therapy. Recently, these treatments were directly compared for initial treatment of EoE in a randomized, double-blind trial [147]. Patients were randomized to receive oral viscous budesonide slurry BID plus a placebo inhaler ($n = 56$) or a multi-dose fluticasone inhaler BID plus placebo slurry ($n = 55$). Between baseline and week 8, the mean peak eosinophil count decreased from 73 to 15 eos/hpf and from 77 to 21 eos/hpf in the oral viscous budesonide and multi-dose fluticasone inhaler groups, respectively ($p = 0.31$). Similarly, there was no statistically significant between-group difference with respect to the change in the Dysphagia Symptom Questionnaire (DSQ) score: the mean DSQ score decreased from 11 to 5 in the oral viscous budesonide group and from 8 to 4 in the multi-dose fluticasone inhaler group ($p = 0.70$). These findings suggest that both oral aerosolized fluticasone and oral viscous budesonide are acceptable EoE treatments.

In an RCT comparing 8 weeks of viscous ($n = 11$) and nebulized topical budesonide ($n = 11$) therapy, the latter agent was demonstrated to be more effective than the former in reducing esophageal eosinophilia, likely due to better esophageal distribution and increased contact time [70]. This finding underscores the importance of bioavailability and has prompted the initiation of pharmacokinetic and dose-finding studies of existing corticosteroids in addition to the development of novel formulations.

Induction treatment with two budesonide formulations (budesonide effervescent tablet [BET] for orodispersible use, 1 or 2 mg BID, and budesonide viscous suspension [BVS], 5 ml BID, 0.4 mg/ml) was evaluated in a placebo-controlled RCT that included 76 adult patients with EoE [71]. Over 94% of patients in the BET, BVS, and placebo groups achieved clinical response, defined as a decrease in the dysphagia score of at least 3 points from baseline after 2 weeks. Budesonide—irrespective of dose or formulation—was demonstrated to be statistically superior to placebo for induction of histologic remission (BET 1 mg/d = 100% [19/19]; BET 2 mg/d = 94.7% [18/19]; BVS = 94.7% [18/19]; placebo = 0% [0/19]). When asked which formulation was preferable, 80% of patients chose BET over BVS. Moreover, in a placebo-controlled, phase III RCT of adult patients with EoE, 58% (34/59) of those who received BET 1 mg BID achieved the primary endpoint of complete remission (defined as a mean dysphagia and odynophagia severity score ≤ 2 on a scale of 0–10 for each day during week 5 of the double-blind study and a peak eosinophil count < 5 eos/hpf) compared with none of the patients in the placebo arm (0/29) at week 6 ($p < 0.0001$) [72]. In 2017, the European Medicines Agency (EMA) approved swallowed effervescent budesonide for use in adult patients with EoE [73].

A tablet formulation of fluticasone propionate that dissolves on the tongue, APT-1011, was recently evaluated in a phase I trial of 22 healthy subjects (NCT03191864). Overall, APT-1011 demonstrated low systemic absorption (< 200 pg/ml), consistent with acceptable esophageal contact time. The potential effect of extending fluticasone propionate absorption among patients with EoE with APT-1011 is currently under further investigation in a phase II, placebo-controlled RCT (NCT03191864).

5 Anti-Allergic Targets

The mast cell-stabilizing agent cromolyn sodium, which modifies chloride channels in mast cell membranes, was initially investigated as an EoE treatment in a pediatric cohort study ($N = 381$) that failed to show either clinical or histologic improvement [36]. Similarly, a recent 8-week RCT that enrolled pediatric patients with EoE did not demonstrate a statistically significant reduction in either clinical symptoms or peak eosinophil counts in those assigned to viscous oral cromolyn sodium compared with placebo [74]. The use of mast cell stabilizers is therefore not recommended, as either induction or maintenance therapy in EoE.

It was previously speculated that decreasing eosinophil chemotaxis and cellular activity by using eosinophil-targeted agents may be an effective treatment strategy for eosinophilic-related gastrointestinal disorders and asthma. Data from an *in vitro* study and retrospective chart review suggested that montelukast, a leukotriene D_4 receptor antagonist that inhibits eosinophil protease activity and subsequent eosinophil chemoattraction, reduced symptoms and maintained remission in EoE [75, 76]. However, a subsequent placebo-controlled RCT and a prospective cohort study failed to demonstrate efficacy for maintenance of corticosteroid-induced remission [77, 78].

Other prostaglandins play critical roles in the eosinophilic inflammation cascade. Prostaglandin D_2 (PGD_2; also known as chemoattractant receptor-homologous molecule expressed on Th2 cells [CRTH2]) mediates chemotaxis of eosinophils and expression of Th2 cytokines [79, 80]. In a small, placebo-controlled RCT performed in 26 adult patients with corticosteroid-dependent or corticosteroid-refractory EoE, treatment with the selective CRTH2 antagonist OC000459 resulted in a significant, although modest, reduction in clinical symptoms and peak eosinophil counts compared with placebo after 8 weeks of treatment [81]. These results support further investigation of CRTH2 antagonists as potential corticosteroid-sparing agents.

6 Immunosuppressives

Evidence supporting the use of immunosuppressives in EoE is limited. The published literature consists of a single case series ($N = 3$) that found thiopurines to be effective for maintaining clinical and histologic remission in corticosteroid-dependent patients with EoE. It is postulated that azathioprine and 6-mercaptopurine inhibit the recruitment and/or proliferation of T and B lymphocytes in the esophageal epithelium, thereby decreasing antigen processing and subsequent esophageal inflammation [82]. However, the use of thiopurines is not recommended in EoE because of their unfavorable safety profile and the lack of controlled evidence to support efficacy [83]. Data evaluating other immunosuppressives, including cyclosporine, tacrolimus, and methotrexate, are not currently available.

7 Monoclonal Antibodies

The introduction of biologic therapy has revolutionized the management of refractory allergic diseases such as asthma, atopic dermatitis, and nasal polyposis. In EoE, the Th2 cytokine signature indicates an allergic etiology. As such, research efforts have focused on both evaluation of therapies designed for other atopic conditions and development of antibodies directed against EoE-specific pathways. Investigational monoclonal antibodies that directly target cell signaling proteins implicated in Th2-predominant inflammation include interleukin (IL)-5, -4, -13, and IgE. Monoclonal antibodies directed toward T-helper type 1 cytokines including tumor necrosis factor (TNF)-α antagonists have also been evaluated (Table 1).

7.1 Interleukin (IL)-5 Antagonists

IL-5 is a pro-inflammatory cytokine secreted by T lymphocytes, mast cells, and eosinophils that induces eosinophil production, primes eosinophils to respond to activation signals, and promotes eosinophil trafficking to the esophagus [84–86]. Transgenic IL-5 overexpression is associated with the development of an EoE-like disease in murine models and local IL-5 inducing Th2 cell overexpression in EoE [87]. Targeting the IL-5 pathway with monoclonal antibodies was first explored in atopic conditions that feature tissue eosinophilia (i.e., asthma, nasal polyposis, and atopic dermatitis) [88–90]. In EoE, two monoclonal antibodies against IL-5 have been evaluated.

Mepolizumab, a humanized anti-IL-5 monoclonal IgG1 antibody, was first assessed in an open-label study ($N=4$) of adults with longstanding, symptomatic EoE. Following three infusions of intravenous mepolizumab 10 mg/kg (to a maximum of 750 mg), all patients demonstrated clinical response at week 4 [91]. Although a substantial decrease in esophageal eosinophilia was observed, peak eosinophil counts remained > 20 eos/hpf. In contrast, limited clinical improvement and a substantial reduction in mean eos/hpf count was reported in a subsequent placebo-controlled, phase II RCT ($N=11$) that investigated 4 weeks of mepolizumab (750 mg/week for two doses, followed by 1500 mg/week for two doses if remission was not achieved) compared with placebo [92]. These findings are similar to those of a phase II RCT performed in 59 pediatric patients who received a total of three infusions, one every 4 weeks, of mepolizumab 0.55 mg/kg ($n=19$), 2.5 mg/kg ($n=20$), or 10 mg/kg ($n=20$) [93]. When the dose groups were combined, 89.5% (51/59) of patients had a mean esophageal eosinophil count < 20 eos/hpf.

Reslizumab, a fully humanized IgG4 antibody against IL-5, was evaluated in a controlled RCT of 226 pediatric patients with EoE who were randomized to monthly infusions of 1, 2, or 3 mg/kg of intravenous reslizumab or placebo. After 4 months of treatment, a statistically significant difference in the proportion of reslizumab patients with a reduced median peak eosinophil count compared with placebo was observed, yet reslizumab was not found to be effective for induction of clinical response [94]. Six patients from one site continued to receive reslizumab (2 mg/kg) in an open-label extension (OLE) phase [95]. Additionally, four patients were treated with reslizumab on the grounds of compassionate use. After 9 years of treatment, reslizumab was associated with substantial improvement in symptoms related to EoE, including dysphagia, abdominal pain, heart burn, vomiting, and reflux, as well as reduced eosinophil counts.

Targeting the IL-5 pathway by administration of benralizumab, an antibody that blocks the IL-5Rα receptor, is a highly effective therapy for asthma; it recently received FDA and EMA approval as add-on maintenance therapy for children (> 12 years) and adults with severe eosinophilic asthma [96–98]. Benralizumab has not yet been evaluated in EoE, but a placebo-controlled clinical trial (NCT03473977) is currently investigating the efficacy and safety of three monthly doses of benralizumab 30 mg for the treatment of eosinophilic gastritis/gastroenteritis in children (> 12 years) and adults.

7.2 IL-13 and IL-4/IL-13 Antagonists

IL-13 secreted by Th2 cells and activated eosinophils plays a vital role in the pathogeneses of EoE by increasing eotaxin-3 and promoting fibroblasts to produce periostin, which increases eosinophil chemotaxis [42, 99]. IL-13 also affects epithelial barrier integrity, as it is implicated in the dysregulation of the important basement membrane proteins desmosomal cadherin desmoglein 1, filaggrin, and involucrin [100, 101]. In mouse models, administration of pharmacological doses of IL-13 induces pathology similar to human EoE and has been shown to cause esophageal tissue remodeling. In addition, IL-13 was found to be markedly overexpressed in the esophagus of patients with EoE [41, 42, 102]. Similarly, IL-4, a cytokine that causes naïve T-helper cells to differentiate into Th2 cells and activates B-cell class switching to produce IgE is found in increased concentrations in patients with EoE [41]. Furthermore, stimulation of epithelial cells by IL-4 leads to production of eotaxin-3 through STAT6 signaling and subsequent recruitment of eosinophils into tissue. Two monoclonal antibodies targeting IL-13 (QAX576 and RPC4046) and one monoclonal antibody targeting IL-4/IL-13 (dupilumab) have been evaluated in EoE.

QAX576 was first evaluated as an EoE therapy during a phase II trial of 23 adults who were randomized to three infusions of QAX576 6 mg/kg or placebo at weeks 0, 4, and

Table 1 Clinical studies evaluating monoclonal antibodies for the treatment of eosinophilic esophagitis

Target	Monoclonal antibody	Study	Design	Population (*N*)	Dosage	Duration (months)	Clinical response	Histo-logic response	Safety and tolerability
IL-5	Mepolizumab	Stein et al. [91]	Open-label, phase I RCT	Adults (4)	10 mg/kg monthly, max. 750 mg	3	+	+	Mild AEs
		Straumann et al. [92]	Placebo-controlled, phase II RCT	Adults (11)	750 mg weekly for two doses + 1500 mg for two doses if not in remission	1	–	–	Mild AEs
		Assa'ad et al. [93]	Placebo-controlled, phase II RCT	Children (59)	0.55, 2.5, or 10 mg/kg monthly	3	–	–	No AEs
IL-5	Reslizumab	Spergel et al. [94]	Placebo-controlled RCT	Children (226)	1, 2, or 3 mg/kg monthly	4	–	+	Mild AEs
		Markowitz et al. [95]	OLE of placebo-controlled RCT	Children (9)	2 mg/kg monthly	108	+	+	Well-tolerated
IL-13	QAX576	Rothenberg et al. [103]	Placebo-controlled, phase II RCT	Adults (23)	6 mg/kg monthly	3	–	+	Well-tolerated
IL-13	RPC4046	Hirano et al. [104]	Placebo-controlled, phase II RCT	Adults (99)	180 or 360 mg weekly	4	–	+	Mild AEs
IL-4/ IL-13	Dupilumab	NCT02379052	Placebo-controlled, phase II RCT	Adults (47)	300 mg weekly	3	+	+	Well-tolerated
IgE	Omalizumab	Clayton et al. [116]	Placebo-controlled, phase II RCT	Adults (30)	0.016 mg/kg/IgE every 2–4 weeks	4	–	–	Well-tolerated
		Loizou et al. [117]	Open-label, non-randomized	Adults (15)	1 mg/kg/IgE monthly	3	+	+	Well-tolerated
Anti-TNF	Infliximab	Straumann et al. [120]	Open-label, non-randomized	Adults (3)	5 mg/kg monthly for 2 infusions	1	–	–	Well-tolerated

AE adverse event, *EoE* eosinophilic esophagitis, *IgE* immunoglobulin E, *IL* interleukin, *OLE* open-label extension, *RCT* randomized controlled trial, *TNF* tumor necrosis factor

+ Indicates statistically significant response; – indicates no statistically significant response

8 [103]. Although the primary endpoint (histologic response, defined as ≥ 75% reduction in peak esophageal eosinophil count) was not met, the mean eosinophil count was reduced by 60% in the QAX576-treated group and increased by 23% in the placebo arm at 6 months ($p = 0.004$). No significant improvement in dysphagia was reported by patients assigned to active drug compared with those who received placebo. Development of QAX576 has since been discontinued.

RPC4046 is a monoclonal antibody that blocks IL-13 from binding to both IL-13 receptor subunit alpha 1 (IL13RA1) and 2 (IL13RA2). In a recent phase II placebo-controlled RCT, 99 adult patients with EoE were assigned to RPC4046 180 or 360 mg or placebo once weekly in a 1:1:1 ratio [104]. After 16 weeks of treatment, a statistically significant reduction in mean eosinophil count was observed in both RPC4046 groups (180 mg: 94.8 ± 67.3, $p < 0.0001$;

360 mg: 99.9 ± 79.5, $p < 0.0001$) compared with placebo (4.4 ± 59.9). Moreover, patients treated with RPC4046 were statistically more likely to achieve endoscopic and histologic disease improvement as measured by difference in endoscopic severity score and total histological grade and stage scores, as measured by a validated disease activity index (the EoE histologic scoring system [EoE-HSS]) [105]. A numerical trend in favor of RPC4046 was reported with respect to symptom improvement, particularly dysphagia. Additionally, results from the OLE study, in which patients received RPC4046 360 mg once weekly, demonstrated sustained symptomatic and histologic improvement at week 52 following successful induction therapy [106].

Two other IL-13 monoclonal antibodies, lebrikizumab and tralokinumab, have been successfully studied in asthma and atopic dermatitis and may be effective for the treatment of EoE [107–110].

Dupilumab, a monoclonal antibody targeting the shared alpha subunit of the IL-4 and IL-13 receptors, was studied in a phase II trial of 47 patients who received subcutaneous dupilumab 300 mg or placebo for 12 weeks (NCT02379052). Clinical response, as measured by the Straumann Dysphagia Index, was significantly improved after 10 weeks' treatment compared with placebo (45 vs. 19%, $p = 0.0304$). In addition, the peak eosinophil count was significantly reduced at week 12 among patients treated with dupilumab as compared with placebo (92 vs. 15%, $p < 0.0001$). Total EoE-HSS grade and stage scores and distensibility plateau were improved at week 12 (all $p < 0.001$ vs. placebo). Considering these promising results, a phase III trial was initiated to determine the efficacy and safety of dupilumab in adult EoE patients and is currently recruiting (NCT03633617).

Other agents targeting inhibition of IL-4 and IL-13 may be effective in down-regulating the Th2 immune response in patients with EoE. A phase I safety trial of MEDI 9314, an anti-IL-4Rα antibody, has completed; at present, this drug will be developed as a treatment for atopic dermatitis (NCT02669667).

7.3 Monoclonal Antibodies Targeting Immunoglobulin (Ig)-E

It is generally accepted that mast cell activation in EoE is IgE-dependent, analogous to asthma [1, 111]. Moreover, the increased number of IgE-bearing mast cells, increased B-lymphocyte density, upregulation of genes involved in B-cell activation and B-cell class switching to produce local IgE support the notion that EoE is an IgE-mediated disease [112, 113]. From an epidemiologic perspective, the observation that food- and aero-allergen IgE-mediated hypersensitivity is more frequent in patients with EoE than in the general population further supports this concept [1].

The monoclonal anti-IgE antibody omalizumab was initially evaluated in several case studies that reported clinical, but not histologic or endoscopic, improvement [114, 115]. Subsequently, an RCT was conducted in 30 adult patients with EoE who received either subcutaneous omalizumab 0.016 mg/kg/IgE or placebo. No statistically significant reduction in clinical symptoms or tissue eosinophil counts were observed when the active and control groups were compared at week 16 [116]. In addition, an open-label single-arm trial showed that 33% (5/15) of adult patients treated with omalizumab achieved complete clinical and histologic remission after 12 weeks of therapy (three infusions of 1 mg/kg/IgE) [117]. These findings suggest that IgE does not play an important role in the inflammatory process in EoE. No drug development program for anti-IgE therapy is currently active.

7.4 Tumor Necrosis Factor-α Antagonists

High concentrations of TNF-α are found in the esophageal tissue of patients with EoE. While classically thought of as a T-helper type 1 (TH1) cytokine, TNF-α generates a synergistic effect on IL-4 increased eotaxin-3 production [40, 118]. Targeting TNF-α with the IgG1 monoclonal antibody infliximab has been shown to be an effective treatment in chronic inflammatory diseases such as Crohn's disease [119]. Administration of two infusions of infliximab 5 mg/kg was evaluated in a prospective study of three adult patients with corticosteroid-dependent EoE [120]. Although well-tolerated, infliximab therapy did not induce a clinical response or reduce the number of esophageal eosinophils. This experience should be interpreted with caution because of the small number of patients evaluated; however, it has discouraged further evaluation of this class of agents in EoE.

8 Other Potential Therapeutic Targets

Several drugs that target specific molecules and or cells implicated in the pathogenesis of EoE have been proposed as potential future therapeutic agents (Table 2).

8.1 Sialic Acid-Binding Ig-Like Lectin 8 (Siglec-8)

Sialic acid-binding Ig-like lectin 8 (Siglec-8) is a cell surface protein selectively expressed on human eosinophils and mast cells. The binding of specific antibodies to Siglec-8 causes eosinophil apoptosis via caspase- and mitochondrial-dependent pathways. In mast cells, only inhibition of mediator release was observed [121]. In a murine model of EoE, administration of a monoclonal antibody to Siglec-F (the murine isoform of Siglec-8) decreased esophageal basal zone hyperplasia, angiogenesis, and deposition of

Table 2 Potential therapeutic targets for eosinophilic esophagitis

Target	Drug	Role in disease pathogenesis	Available data
Siglec-8	Anti-Siglec-8 antibodies (AK001 and AK002)	Eosinophil apoptosis and inhibition of mast cells	Eosinophilic gastritis/gastroenteritis (ongoing); atopic keratoconjunctivitis (ongoing)
TGF-β1	Angiotensin-1 receptor antagonist (losartan)	Tissue remodeling and fibrosis development	Connective tissue disease; EoE (with or without connective tissue disease; ongoing)
CCR3 (eotaxin-3 receptor)	Anti-CCR3	Recruitment of eosinophils	Asthma
TSLP	Anti-TSLP (tezepelumab, AMG 157)	Promotion of Th2-type immune response	Asthma; atopic dermatitis
Integrin α4β7	Vedolizumab	Mediates adhesion to MAdCAM-1 (improves eosinophil survival)	Crohn's disease; ulcerative colitis
IL-4Rα[a]	Anti-IL-4Rα (MEDI 9314)	Activation and recruitment of eosinophils	Healthy subjects in atopic dermatitis (upcoming)
IL-5Rα[b]	Anti-IL-5Rα (Benralizumab)	Activation and recruitment of eosinophils	Asthma; atopic dermatitis (ongoing); nasal polyposis (ongoing); eosinophilic gastritis/gastroenteritis (ongoing)
IL-13[a]	Anti-IL-13 (tralokinumab, lebrikizumab)	Eosinophil recruitment, barrier dysfunction and remodeling	Atopic dermatitis; asthma
IL-9	Anti-IL-9 (MEDI 528)	Epithelial barrier dysregulation by alteration of E-cadherin	Asthma
IL-15	Anti-IL-15 (CALY-002)	Controls Th2 and natural killer T-cell responses, promotes epithelial inflammation and prevents eosinophil apoptosis	Celiac disease (upcoming); EoE (upcoming)

CCR3 CC chemokine receptor type 3, *EoE* eosinophilic esophagitis, *IL* interleukin, *MAdCAM-1* mucosal vascular addressin cell adhesion molecule 1, *TGF* transforming growth factor, *TSLP* thymic stromal lymphopoietin

[a]Dupilumab (IL-4/IL-13 antagonist) and RPC4046 (IL-13 antagonist) have been previously studied in EoE (see Table 1)

[b]Benralizumab (IL-5Rα receptor antagonist) is currently being studied in eosinophilic gastritis/gastroenteritis)

fibronectin, which are important histologic features in EoE pathogenesis [122]. In another mouse study, administration of AK002, a non-fucosylated IgG1 monoclonal antibody targeting Siglec-8, resulted in selective depletion of tissue and blood eosinophils and reduction of mast cells [123]. A phase II, placebo-controlled trial of AK002 in adult patients with eosinophilic gastritis and/or gastroenteritis is currently recruiting (NCT03496571).

8.2 Transforming Growth Factor-β1

The role of TGF-β1 in tissue remodeling and the development of fibrosis in EoE is well-established [33]. Losartan, an angiotensin-1 receptor antagonist widely used for the treatment of hypertension, reduces signaling of TGF-β1 [124–128]. Losartan may be an effective therapy in patients with a fibrotic EoE phenotype who experience persistent symptoms. In support of this concept, losartan has been used to prevent vascular complications in patients with connective tissue disorders such as Marfan and Loeys-Dietz syndrome [129]. A single clinical trial is evaluating the effect of losartan in patients with EoE with or without connective tissue disorders (NCT03029091).

8.3 CC Chemokine Receptor Type 3

The CC chemokine receptor type 3 (CCR-3), which is primarily expressed on eosinophils and basophils, has multiple ligands, including CCL-11, -24, and -26 (eotaxins). Eotaxin-3 (CCL-26) is one of the most potent chemo-attractants in EoE. Notwithstanding that an oral CCR3 antagonist (GW766944) was not effective in patients with asthma and eosinophilic bronchitis, blocking this chemokine receptor by using either an anti-CCR3 monoclonal antibody or small molecule could be an effective therapy for EoE [130]. No clinical trials are evaluating CCR3 antagonists in EoE.

8.4 Thymic Stromal Lymphopoietin

EoE is associated with polymorphisms in the gene that encodes thymic stromal lymphopoietin (TSLP), a cytokine that promotes Th2-type responses. It was previously

demonstrated in a mouse model that the development of eosinophilic inflammation was TSLP dependent and could be prevented by using antibodies to this cytokine [131]. Furthermore, treatment with fluticasone propionate reduces expression of multiple pro-inflammatory cytokines, including TSLP [68]. A fully human monoclonal IgG2 antibody against TSLP, tezepelumab (AMG 157), was evaluated in patients with mild allergic asthma, and both early and late asthmatic responses reduced [132]. More recently, a phase II trial completed in 113 adult patients with moderate-to-severe atopic dermatitis showed a statistically significant improvement in the Eczema Area and Severity Index score compared with placebo [133]. Overall, targeting of TSLP needs to be further studied, and tezepelumab could hold promise as a potential target agent in EoE.

8.5 Integrin α4β7

The α4β7 integrin, which is expressed on both T-lymphocytes and eosinophils, mediates adhesion to the vascular endothelial cells of the gut through interaction with its ligand, mucosal vascular addressin cell adhesion molecule 1 (MAdCAM-1). This mechanism facilitates the migration of these cells from the vasculature into inflamed tissue. It is also noteworthy that E-cadherin, a second ligand for α4β7, is highly expressed by epithelial cells in human allergic gastrointestinal tissue, including EoE. It is believed that this interaction enhances the retention of inflammatory cells in mucosal tissue [134]. Vedolizumab, a monoclonal antibody that selectively blocks the α4β7 integrin interaction with MAdCAM-1, is FDA approved for moderate-to-severe Crohn's disease and ulcerative colitis. Recently, vedolizumab therapy in a patient with Crohn's disease and concurrent EoE was reported to induce remission of both diseases [135]. Consistent with this observation, a retrospective series showed improvement of eosinophil-associated gastrointestinal disorders following vedolizumab therapy for inflammatory bowel disease. However, these data are uncontrolled and were not adjusted for the potential influences of known confounders such as corticosteroid therapy [136]. A preclinical trial is currently investigating the mechanistic role of the α4β7 integrin and MAdCAM-1 pathway in eosinophil recruitment in EoE (NCT02546219). Further research is needed to further elucidate the potential role of vedolizumab and other anti-integrins as treatment for EoE.

8.6 Il-9

An increased concentration of IL-9 has been detected in the eosinophils of patients with active EoE [137]. Moreover, IL-9-expressing mast cells are important in food allergies, and patients with EoE sensitized to food have significant increased mast cells in the esophageal epithelium [138, 139]. The effect of an anti-IL-9 antibody, MEDI-528, was evaluated in adults with uncontrolled asthma without success [140]. However, recent data showed that IL-9 and its effect on E-cadherin is an important mediator of esophageal epithelial dysfunction in EoE. Therefore, this pathway may represent a new therapeutic target [141].

8.7 Il-15

IL-15, a cytokine that is upregulated in human EoE, controls Th2 and natural killer T-cell responses, promotes epithelial inflammation and prevents eosinophil apoptosis [142–145]. The effects of IL-15 influence multiple cells that are relevant to the EoE-pathway, thus, blockade of this mediator may be an effective treatment target. An intercepting humanized anti-IL-15 antibody with unique neutralization of IL-15 cis and trans signaling that could be relevant to EoE treatment, CALY-002, was recently discovered [146].

9 Conclusion

EoE is a chronic immune-mediated disorder of the esophagus that can adversely impact quality of life. Characterized by eosinophilic inflammation, patients typically experience dysphagia and food impaction as a result of progressive esophageal remodeling and fibrosis. It is now recognized that the pathophysiology of EoE resembles certain aspects of other allergic diseases such as asthma and atopic dermatitis, which has prompted the evaluation of drugs used to treat these conditions within the context of EoE. Furthermore, advanced understanding of the pathological processes involved in EoE has led to the development of unique compounds and the recognition of novel treatment targets that may prove to be effective.

Compliance with Ethical Standards

Funding No sources of funding were used to conduct this study or prepare this manuscript.

Conflicts of interest WEdR has no conflicts of interest that are directly relevant to the content of this article. ESD has received research funding from Adare, Allakos, GSK, Meritage, Miraca, Nutricia, Celgene/Receptos, Regeneron, and Shire; consulting fees from Adare, Alivio, Allakos, AstraZeneca, Banner, Calypso, Enumeral, EsoCap, Celgene/Receptos, GSK, Regeneron, Robarts and Shire; and educational grants from Allakos, Banner, and Holoclara. CEP is an employee of Robarts Clinical Trials Inc. BGF has received grant/research support from AbbVie Inc., Amgen Inc., AstraZeneca/MedImmune Ltd., Atlantic Pharmaceuticals Ltd., Boehringer-Ingelheim, Celgene Corporation, Celltech, Genentech Inc/Hoffmann-La Roche Ltd., Gilead Sciences Inc., GlaxoSmithKline (GSK), Janssen Research & Development LLC., Pfizer Inc., Receptos Inc./Celgene International, Sanofi, Santarus Inc., Takeda Development Center Americas Inc., Tillotts Pharma AG, and UCB; consulting fees from Abbott/AbbVie, Akebia Thera-

peutics, Allergan, Amgen, Applied Molecular Transport Inc., Aptevo Therapeutics, Astra Zeneca, Atlantic Pharma, Avir Pharma, Biogen Idec, BioMx Israel, Boehringer-Ingelheim, Bristol-Myers Squibb, Calypso Biotech, Celgene, Elan/Biogen, EnGene, Ferring Pharma, Roche/Genentech, Galapagos, GiCare Pharma, Gilead, Gossamer Pharma, GSK, Inception IBD Inc, JnJ/Janssen, Kyowa Kakko Kirin Co Ltd., Lexicon, Lilly, Lycera BioTech, Merck, Mesoblast Pharma, Millennium, Nestle, Nextbiotix, Novonordisk, Pfizer, Prometheus Therapeutics and Diagnostics, Progenity, Protagonist, Receptos, Salix Pharma, Shire, Sienna Biologics, Sigmoid Pharma, Sterna Biologicals, Synergy Pharma Inc., Takeda, Teva Pharma, TiGenix, Tillotts, UCB Pharma, Vertex Pharma, Vivelix Pharma, VHsquared Ltd., and Zyngenia; speakers bureaux fees from Abbott/AbbVie, JnJ/Janssen, Lilly, Takeda, Tillotts, and UCB Pharma; is a scientific advisory board member for Abbott/AbbVie, Allergan, Amgen, Astra Zeneca, Atlantic Pharma, Avaxia Biologics Inc., Boehringer-Ingelheim, Bristol-Myers Squibb, Celgene, Centocor Inc., Elan/Biogen, Galapagos, Genentech/Roche, JnJ/Janssen, Merck, Nestle, Novartis, Novonordisk, Pfizer, Prometheus Laboratories, Protagonist, Salix Pharma, Sterna Biologicals, Takeda, Teva, TiGenix, Tillotts Pharma AG, and UCB Pharma; and is the Senior Scientific Officer of Robarts Clinical Trials Inc. CM has received consulting fees from Robarts Clinical Trials Inc. VJ has received consulting fees from AbbVie, Eli Lilly, GlaxoSmithKline, Arena Pharmaceuticals, Genetech, Pendopharm, Sandoz, Merck, Takeda, Janssen, Robarts Clinical Trials Inc, Topivert, and Celltrion; and speaker's fees from Takeda, Janssen, Shire, Ferring, Abbvie, and Pfizer. AJB has received research funding from Nutricia, Norgine, and Bayer; and speaker and/or consulting fees from Laborie, EsoCap, Diversatek, Medtronic, DrFalk, Calypso, Thelial, Regeneron, Celgene, Bayer, Norgine, AstraZeneca, Almirall, and Allergan.

References

1. Liacouras CA, Furuta GT, Hirano I, Atkins D, Attwood SE, Bonis PA, et al. Eosinophilic esophagitis: updated consensus recommendations for children and adults. J Allergy Clin Immunol. 2011;128(1):3.e6–20.e6. https://doi.org/10.1016/j.jaci.2011.02.040 **(quiz 1-2)**.
2. Furuta GT, Liacouras CA, Collins MH, Gupta SK, Justinich C, Putnam PE, et al. Eosinophilic esophagitis in children and adults: a systematic review and consensus recommendations for diagnosis and treatment. Gastroenterology. 2007;133(4):1342–63. https://doi.org/10.1053/j.gastro.2007.08.017.
3. Warners MJ, de Rooij W, van Rhijn BD, Verheij J, Bruggink AH, Smout A, et al. Incidence of eosinophilic esophagitis in the Netherlands continues to rise: 20-year results from a nationwide pathology database. Neurogastroenterol Motil. 2018;30(1):1. https://doi.org/10.1111/nmo.13165.
4. Dellon ES, Erichsen R, Baron JA, Shaheen NJ, Vyberg M, Sorensen HT, et al. The increasing incidence and prevalence of eosinophilic oesophagitis outpaces changes in endoscopic and biopsy practice: national population-based estimates from Denmark. Aliment Pharmacol Ther. 2015;41(7):662–70. https://doi.org/10.1111/apt.13129.
5. Attwood SEA, Smyrk TC, Demeester TR, Jones JB. Esophageal eosinophilia with dysphagia. Dig Dis Sci. 1993;38(1):109–16. https://doi.org/10.1007/bf01296781.
6. Arias A, Perez-Martinez I, Tenias JM, Lucendo AJ. Systematic review with meta-analysis: the incidence and prevalence of eosinophilic oesophagitis in children and adults in population-based studies. Aliment Pharmacol Ther. 2016;43(1):3–15. https://doi.org/10.1111/apt.13441.
7. Dellon ES, Hirano I. Epidemiology and natural history of eosinophilic esophagitis. Gastroenterology. 2018;154(2):319.e3–332.e3. https://doi.org/10.1053/j.gastro.2017.06.067.
8. Dellon ES, Jensen ET, Martin CF, Shaheen NJ, Kappelman MD. Prevalence of eosinophilic esophagitis in the United States. Clin Gastroenterol Hepatol. 2014;12(4):589.e1–596.e1. https://doi.org/10.1016/j.cgh.2013.09.008.
9. Giriens B, Yan P, Safroneeva E, Zwahlen M, Reinhard A, Nydegger A, et al. Escalating incidence of eosinophilic esophagitis in Canton of Vaud, Switzerland, 1993–2013: a population-based study. Allergy. 2015;70(12):1633–9. https://doi.org/10.1111/all.12733.
10. Hruz P, Straumann A, Bussmann C, Heer P, Simon HU, Zwahlen M, et al. Escalating incidence of eosinophilic esophagitis: a 20-year prospective, population-based study in Olten County, Switzerland. J Allergy Clin Immunol. 2011;128(6):1349.e5–1350.e5. https://doi.org/10.1016/j.jaci.2011.09.013.
11. Mansoor E, Cooper GS. The 2010–2015 prevalence of eosinophilic esophagitis in the USA: a population-based study. Dig Dis Sci. 2016;61(10):2928–34. https://doi.org/10.1007/s10620-016-4204-4.
12. Prasad GA, Alexander JA, Schleck CD, Zinsmeister AR, Smyrk TC, Elias RM, et al. Epidemiology of eosinophilic esophagitis over three decades in Olmsted County, Minnesota. Clin Gastroenterol Hepatol. 2009;7(10):1055–61. https://doi.org/10.1016/j.cgh.2009.06.023.
13. Schoepfer A, Blanchard C, Dawson H, Lucendo A, Mauro A, Ribi C, et al. Eosinophilic esophagitis: latest insights from diagnosis to therapy. Ann N Y Acad Sci. 2018;1434(1):84–93. https://doi.org/10.1111/nyas.13731.
14. Molodecky NA, Soon IS, Rabi DM, Ghali WA, Ferris M, Chernoff G, et al. Increasing incidence and prevalence of the inflammatory bowel diseases with time, based on systematic review. Gastroenterology. 2012;142(1):46.e42–54.e42. https://doi.org/10.1053/j.gastro.2011.10.001 **(quiz e30)**.
15. DeBrosse CW, Collins MH, Buckmeier Butz BK, Allen CL, King EC, Assa'ad AH, et al. Identification, epidemiology, and chronicity of pediatric esophageal eosinophilia, 1982–1999. J Allergy Clin Immunol. 2010;126(1):112–9. https://doi.org/10.1016/j.jaci.2010.05.027.
16. Eder W, Ege MJ, von Mutius E. The asthma epidemic. N Engl J Med. 2006;355(21):2226–35. https://doi.org/10.1056/NEJMra054308.
17. Dellon ES. Epidemiology of eosinophilic esophagitis. Gastroenterol Clin North Am. 2014;43(2):201–18. https://doi.org/10.1016/j.gtc.2014.02.002.
18. Noel RJ, Putnam PE, Rothenberg ME. Eosinophilic esophagitis. N Engl J Med. 2004;351(9):940–1. https://doi.org/10.1056/nejm200408263510924.
19. Dellon ES, Liacouras CA, Molina-Infante J, Furuta GT, Spergel JM, Zevit N, et al. Updated international consensus diagnostic criteria for eosinophilic esophagitis: proceedings of the AGREE conference. Gastroenterology. 2018;155(4):1022.e10–1033.e10. https://doi.org/10.1053/j.gastro.2018.07.009.
20. Prasad GA, Talley NJ, Romero Y, Arora AS, Kryzer LA, Smyrk TC, et al. Prevalence and predictive factors of eosinophilic esophagitis in patients presenting with dysphagia: a prospective study. Am J Gastroenterol. 2007;102(12):2627–32. https://doi.org/10.1111/j.1572-0241.2007.01512.x.
21. Lucendo AJ, Molina-Infante J, Arias A, von Arnim U, Bredenoord AJ, Bussmann C, et al. Guidelines on eosinophilic esophagitis: evidence-based statements and recommendations for diagnosis and management in children and adults. United Eur Gastroenterol J. 2017;5(3):335–58. https://doi.org/10.1177/2050640616689525.

22. Schoepfer AM, Safroneeva E, Bussmann C, Kuchen T, Portmann S, Simon HU, et al. Delay in diagnosis of eosinophilic esophagitis increases risk for stricture formation in a time-dependent manner. Gastroenterology. 2013;145(6):1230.e1-2–1236.e1-2. https://doi.org/10.1053/j.gastro.2013.08.015.
23. Straumann A, Bussmann C, Zuber M, Vannini S, Simon HU, Schoepfer A. Eosinophilic esophagitis: analysis of food impaction and perforation in 251 adolescent and adult patients. Clin Gastroenterol Hepatol. 2008;6(5):598–600. https://doi.org/10.1016/j.cgh.2008.02.003.
24. Warners MJ, Oude Nijhuis RAB, de Wijkerslooth LRH, Smout A, Bredenoord AJ. The natural course of eosinophilic esophagitis and long-term consequences of undiagnosed disease in a large cohort. Am J Gastroenterol. 2018;113(6):836–44. https://doi.org/10.1038/s41395-018-0052-5.
25. Greuter T, Bussmann C, Safroneeva E, Schoepfer AM, Biedermann L, Vavricka SR, et al. Long-term treatment of eosinophilic esophagitis with swallowed topical corticosteroids: development and evaluation of a therapeutic concept. Am J Gastroenterol. 2017;112(10):1527–35. https://doi.org/10.1038/ajg.2017.202.
26. Schaefer ET, Fitzgerald JF, Molleston JP, Croffie JM, Pfefferkorn MD, Corkins MR, et al. Comparison of oral prednisone and topical fluticasone in the treatment of eosinophilic esophagitis: a randomized trial in children. Clin Gastroenterol Hepatol. 2008;6(2):165–73. https://doi.org/10.1016/j.cgh.2007.11.008.
27. Gomez-Torrijos E, Garcia-Rodriguez R, Castro-Jimenez A, Rodriguez-Sanchez J, Mendez Diaz Y, Molina-Infante J. The efficacy of step-down therapy in adult patients with proton pump inhibitor-responsive oesophageal eosinophilia. Aliment Pharmacol Ther. 2016;43(4):534–40. https://doi.org/10.1111/apt.13496.
28. Gutierrez-Junquera C, Fernandez-Fernandez S, Cilleruelo ML, Rayo A, Echeverria L, Borrell B, et al. Long-term treatment with proton pump inhibitors Is effective in children with eosinophilic esophagitis. J Pediatr Gastroenterol Nutr. 2018;67(2):210–6. https://doi.org/10.1097/mpg.0000000000001952.
29. Molina-Infante J, Rodriguez-Sanchez J, Martinek J, van Rhijn BD, Krajciova J, Rivas MD, et al. Long-term loss of response in proton pump inhibitor-responsive esophageal eosinophilia is uncommon and influenced by CYP2C19 genotype and rhinoconjunctivitis. Am J Gastroenterol. 2015;110(11):1567–75. https://doi.org/10.1038/ajg.2015.314.
30. Moledina DG, Perazella MA. PPIs and kidney disease: from AIN to CKD. J Nephrol. 2016;29(5):611–6. https://doi.org/10.1007/s40620-016-0309-2.
31. Ye X, Liu H, Wu C, Qin Y, Zang J, Gao Q, et al. Proton pump inhibitors therapy and risk of hip fracture: a systematic review and meta-analysis. Eur J Gastroenterol Hepatol. 2011;23(9):794–800. https://doi.org/10.1097/MEG.0b013e328348a56a.
32. Eluri S, Runge TM, Hansen J, Kochar B, Reed CC, Robey BS, et al. Diminishing effectiveness of long-term maintenance topical steroid therapy in PPI non-responsive eosinophilic esophagitis. Clin Transl Gastroenterol. 2017;8(6):e97. https://doi.org/10.1038/ctg.2017.27.
33. Rajan J, Newbury RO, Anilkumar A, Dohil R, Broide DH, Aceves SS. Long-term assessment of esophageal remodeling in patients with pediatric eosinophilic esophagitis treated with topical corticosteroids. J Allergy Clin Immunol. 2016;137(1):147.e8–156.e8. https://doi.org/10.1016/j.jaci.2015.05.045.
34. Straumann A, Conus S, Degen L, Frei C, Bussmann C, Beglinger C, et al. Long-term budesonide maintenance treatment is partially effective for patients with eosinophilic esophagitis. Clin Gastroenterol Hepatol. 2011;9(5):400.e1–409.e1. https://doi.org/10.1016/j.cgh.2011.01.017.
35. Andreae DA, Hanna MG, Magid MS, Malerba S, Andreae MH, Bagiella E, et al. Swallowed fluticasone propionate is an effective long-term maintenance therapy for children with eosinophilic esophagitis. Am J Gastroenterol. 2016;111(8):1187–97. https://doi.org/10.1038/ajg.2016.238.
36. Liacouras CA, Spergel JM, Ruchelli E, Verma R, Mascarenhas M, Semeao E, et al. Eosinophilic esophagitis: a 10-year experience in 381 children. Clin Gastroenterol Hepatol. 2005;3(12):1198–206.
37. Noel RJ, Putnam PE, Collins MH, Assa'ad AH, Guajardo JR, Jameson SC, et al. Clinical and immunopathologic effects of swallowed fluticasone for eosinophilic esophagitis. Clin Gastroenterol Hepatol. 2004;2(7):568–75.
38. Falcoz C, Oliver R, McDowall JE, Ventresca P, Bye A, Daley-Yates PT. Bioavailability of orally administered micronised fluticasone propionate. Clin Pharmacokinet. 2000;39(Suppl 1):9–15. https://doi.org/10.2165/00003088-200039001-00002.
39. Eluri S, Runge T, Hansen J, Kochar B, Reed CC, Robey B, et al. Mo1175 Diminishing effectiveness of maintenance topical steroid therapy on long-term endoscopic and histologic outcomes in eosinophilic esophagitis. Gastroenterology. 2016;150(4):S658–9. https://doi.org/10.1016/S0016-5085(16)32250-8.
40. Straumann A, Bauer M, Fischer B, Blaser K, Simon HU. Idiopathic eosinophilic esophagitis is associated with a T(H)2-type allergic inflammatory response. J Allergy Clin Immunol. 2001;108(6):954–61. https://doi.org/10.1067/mai.2001.119917.
41. Blanchard C, Stucke EM, Rodriguez-Jimenez B, Burwinkel K, Collins MH, Ahrens A, et al. A striking local esophageal cytokine expression profile in eosinophilic esophagitis. J Allergy Clin Immunol. 2011;127(1):208–317. https://doi.org/10.1016/j.jaci.2010.10.039.
42. Blanchard C, Mingler MK, Vicario M, Abonia JP, Wu YY, Lu TX, et al. IL-13 involvement in eosinophilic esophagitis: transcriptome analysis and reversibility with glucocorticoids. J Allergy Clin Immunol. 2007;120(6):1292–300. https://doi.org/10.1016/j.jaci.2007.10.024.
43. Aceves SS, Newbury RO, Dohil R, Bastian JF, Broide DH. Esophageal remodeling in pediatric eosinophilic esophagitis. J Allergy Clin Immunol. 2007;119(1):206–12. https://doi.org/10.1016/j.jaci.2006.10.016.
44. Tkachenko E, Rawson R, La E, Doherty TA, Baum R, Cavagnero K, et al. Rigid substrate induces esophageal smooth muscle hypertrophy and eosinophilic esophagitis fibrotic gene expression. J Allergy Clin Immunol. 2016;137(4):1270.e1–1272.e1. https://doi.org/10.1016/j.jaci.2015.09.020.
45. Chehade M, Sher E. Medical therapy versus dietary avoidance in eosinophilic esophagitis: Which approach is better? Allergy Asthma Proc. 2017;38(3):170–6. https://doi.org/10.2500/aap.2017.38.4036.
46. Gonsalves N. Steroids versus dietary therapy for the treatment of eosinophilic esophagitis. Curr Opin Gastroenterol. 2014;30(4):396–401. https://doi.org/10.1097/mog.0000000000000086.
47. Gonsalves N, Yang GY, Doerfler B, Ritz S, Ditto AM, Hirano I. Elimination diet effectively treats eosinophilic esophagitis in adults; food reintroduction identifies causative factors. Gastroenterology. 2012;142(7):1451.e1–1459.e1. https://doi.org/10.1053/j.gastro.2012.03.001.
48. Runge TM, Eluri S, Woosley JT, Shaheen NJ, Dellon ES. Control of inflammation decreases the need for subsequent esophageal dilation in patients with eosinophilic esophagitis. Dis Esophagus. 2017;30(7):1–7. https://doi.org/10.1093/dote/dox042.
49. Lucendo AJ, Arias A, De Rezende LC, Yague-Compadre JL, Mota-Huertas T, Gonzalez-Castillo S, et al. Subepithelial collagen deposition, profibrogenic cytokine gene expression, and changes after prolonged fluticasone propionate treatment in adult eosinophilic esophagitis: a prospective study. J Allergy Clin Immunol. 2011;128(5):1037–46. https://doi.org/10.1016/j.jaci.2011.08.007.

50. Rieder F, Nonevski I, Ma J, Ouyang Z, West G, Protheroe C, et al. T-helper 2 cytokines, transforming growth factor beta1, and eosinophil products induce fibrogenesis and alter muscle motility in patients with eosinophilic esophagitis. Gastroenterology. 2014;146(5):1266.e1-9–1277.e1-9. https://doi.org/10.1053/j.gastro.2014.01.051.
51. Dellon ES, Gonsalves N, Hirano I, Furuta GT, Liacouras CA, Katzka DA. ACG clinical guideline: evidenced based approach to the diagnosis and management of esophageal eosinophilia and eosinophilic esophagitis (EoE). Am J Gastroenterol. 2013;108(5):679–92. https://doi.org/10.1038/ajg.2013.71.
52. Spechler SJ, Genta RM, Souza RF. Thoughts on the complex relationship between gastroesophageal reflux disease and eosinophilic esophagitis. Am J Gastroenterol. 2007;102(6):1301–6. https://doi.org/10.1111/j.1572-0241.2007.01179.x.
53. Molina-Infante J, van Rhijn BD. Interactions between gastro-oesophageal reflux disease and eosinophilic oesophagitis. Best Pract Res Clin Gastroenterol. 2015;29(5):749–58. https://doi.org/10.1016/j.bpg.2015.06.009.
54. Krarup AL, Villadsen GE, Mejlgaard E, Olesen SS, Drewes AM, Funch-Jensen P. Acid hypersensitivity in patients with eosinophilic oesophagitis. Scand J Gastroenterol. 2010;45(3):273–81. https://doi.org/10.3109/00365520903469931.
55. Desai TK, Stecevic V, Chang CH, Goldstein NS, Badizadegan K, Furuta GT. Association of eosinophilic inflammation with esophageal food impaction in adults. Gastrointest Endosc. 2005;61(7):795–801.
56. Dranove JE, Horn DS, Davis MA, Kernek KM, Gupta SK. Predictors of response to proton pump inhibitor therapy among children with significant esophageal eosinophilia. J Pediatr. 2009;154(1):96–100. https://doi.org/10.1016/j.jpeds.2008.07.042.
57. Molina-Infante J, Ferrando-Lamana L, Ripoll C, Hernandez-Alonso M, Mateos JM, Fernandez-Bermejo M, et al. Esophageal eosinophilic infiltration responds to proton pump inhibition in most adults. Clin Gastroenterol Hepatol. 2011;9(2):110–7. https://doi.org/10.1016/j.cgh.2010.09.019.
58. Ngo P, Furuta GT, Antonioli DA, Fox VL. Eosinophils in the esophagus–peptic or allergic eosinophilic esophagitis? Case series of three patients with esophageal eosinophilia. Am J Gastroenterol. 2006;101(7):1666–70. https://doi.org/10.1111/j.1572-0241.2006.00562.x.
59. Lucendo AJ, Arias A, Molina-Infante J. Efficacy of proton pump inhibitor drugs for inducing clinical and histologic remission in patients with symptomatic esophageal eosinophilia: a systematic review and meta-analysis. Clin Gastroenterol Hepatol. 2016;14(1):13.e1–22.e1. https://doi.org/10.1016/j.cgh.2015.07.041.
60. van Rhijn BD, Weijenborg PW, Verheij J, van den Bergh Weerman MA, Verseijden C, van den Wijngaard RM, et al. Proton pump inhibitors partially restore mucosal integrity in patients with proton pump inhibitor-responsive esophageal eosinophilia but not eosinophilic esophagitis. Clin Gastroenterol Hepatol. 2014;12(11):1815.e2–1823.e2. https://doi.org/10.1016/j.cgh.2014.02.037.
61. Ishimura N, Ishihara S, Kinoshita Y. Sustained acid suppression by potassium-competitive acid blocker (P-CAB) may be an attractive treatment candidate for patients with eosinophilic esophagitis. Am J Gastroenterol. 2016;111:1203. https://doi.org/10.1038/ajg.2016.167.
62. Cheng E, Zhang X, Huo X, Yu C, Zhang Q, Wang DH, et al. Omeprazole blocks eotaxin-3 expression by oesophageal squamous cells from patients with eosinophilic oesophagitis and GORD. Gut. 2013;62(6):824–32. https://doi.org/10.1136/gutjnl-2012-302250.
63. Weinstein MLSM, Adams EL. Omeprazole attenuates oxygen-derived free radical production from human neutrophils. Free Radic Biol Med. 1996;21(5):727–31.
64. Zhang X, Cheng E, Huo X, Yu C, Zhang Q, Pham TH, et al. Omeprazole blocks STAT6 binding to the eotaxin-3 promoter in eosinophilic esophagitis cells. PloS One. 2012;7(11):e50037. https://doi.org/10.1371/journal.pone.0050037.
65. Sasaki T, Yamaya M, Yasuda H, Inoue D, Yamada M, Kubo H, et al. The proton pump inhibitor lansoprazole inhibits rhinovirus infection in cultured human tracheal epithelial cells. Eur J Pharmacol. 2005;509(2–3):201–10. https://doi.org/10.1016/j.ejphar.2004.12.042.
66. Cheng E, Zhang X, Wilson KS, Wang DH, Park JY, Huo X, et al. JAK-STAT6 pathway inhibitors block eotaxin-3 secretion by epithelial cells and fibroblasts from esophageal eosinophilia patients: promising agents to improve inflammation and prevent fibrosis in EoE. PloS One. 2016;11(6):e0157376. https://doi.org/10.1371/journal.pone.0157376.
67. Aceves SS, Newbury RO, Chen D, Mueller J, Dohil R, Hoffman H, et al. Resolution of remodeling in eosinophilic esophagitis correlates with epithelial response to topical corticosteroids. Allergy. 2010;65(1):109–16. https://doi.org/10.1111/j.1398-9995.2009.02142.x.
68. van Rhijn BD, Verheij J, van den Bergh Weerman MA, Verseijden C, van den Wijngaard RM, de Jonge WJ, et al. Histological response to fluticasone propionate in patients with eosinophilic esophagitis is associated with improved functional esophageal mucosal integrity. Am J Gastroenterol. 2015;110(9):1289–97. https://doi.org/10.1038/ajg.2015.247.
69. Liacouras CA, Wenner WJ, Brown K, Ruchelli E. Primary eosinophilic esophagitis in children: successful treatment with oral corticosteroids. J Pediatr Gastroenterol Nutr. 1998;26(4):380–5.
70. Dellon ES, Sheikh A, Speck O, Woodward K, Whitlow AB, Hores JM, et al. Viscous topical is more effective than nebulized steroid therapy for patients with eosinophilic esophagitis. Gastroenterology. 2012;143(2):321.e1–324.e1. https://doi.org/10.1053/j.gastro.2012.04.049.
71. Miehlke S, Hruz P, Vieth M, Bussmann C, von Arnim U, Bajbouj M, et al. A randomised, double-blind trial comparing budesonide formulations and dosages for short-term treatment of eosinophilic oesophagitis. Gut. 2016;65(3):390–9. https://doi.org/10.1136/gutjnl-2014-308815.
72. Lucendo AJ, Miehlke S, Schlag C, Vieth M, von Arnim U, Molina-Infante J, et al. Efficacy of Budesonide orodispersible tablets as induction therapy for eosinophilic esophagitis in a randomized placebo-controlled trial. Gastroenterology. 2019. https://doi.org/10.1053/j.gastro.2019.03.025 **(e-pub ahead of print)**.
73. European Medicines Agency. New medicine for rare inflammatory condition of the oesophagus: Jorveza approved under accelerated assessment. https://www.ema.europa.eu/en/news/new-medicine-rare-inflammatory-condition-oesophagus. Accessed 2 Jan 2 2018.
74. Lieberman JA, Zhang J, Whitworth J, Cavender C. A randomized, double-blinded, placebo-controlled study of the use of viscous oral cromolyn sodium for the treatment of eosinophilic esophagitis. Ann Allergy Asthma. 2018;120(5):527–31. https://doi.org/10.1016/j.anai.2018.03.006.
75. Langlois A, Ferland C, Tremblay GM, Laviolette M. Montelukast regulates eosinophil protease activity through a leukotriene-independent mechanism. J Allergy Clin Immunol. 2006;118(1):113–9. https://doi.org/10.1016/j.jaci.2006.03.010.
76. Stumphy J, Al-Zubeidi D, Rahhal R, Mitros F, Guerin L. Observations on use of montelukast in pediatric eosinophilic esophagitis: insights for the future. Dis Esophagus. 2011;24(4):229–34. https://doi.org/10.1111/j.1442-2050.2010.01134.x.

77. Alexander JA, Ravi K, Enders FT, Geno DM, Kryzer LA, Mara KC, et al. Montelukast does not maintain symptom remission after topical steroid therapy for eosinophilic esophagitis. Clin Gastroenterol Hepatol. 2017;15(2):214.e2–221.e2. https://doi.org/10.1016/j.cgh.2016.09.013.
78. Lucendo AJ, De Rezende LC, Jimenez-Contreras S, Yague-Compadre JL, Gonzalez-Cervera J, Mota-Huertas T, et al. Montelukast was inefficient in maintaining steroid-induced remission in adult eosinophilic esophagitis. Dig Dis Sci. 2011;56(12):3551–8. https://doi.org/10.1007/s10620-011-1775-y.
79. Peinhaupt M, Sturm EM, Heinemann A. Prostaglandins and their receptors in eosinophil function and as therapeutic targets. Front Med (Lausanne). 2017;4:104. https://doi.org/10.3389/fmed.2017.00104.
80. Pettipher R. The roles of the prostaglandin D(2) receptors DP(1) and CRTH2 in promoting allergic responses. Br J Pharmacol. 2008;153(Suppl 1):S191–9. https://doi.org/10.1038/sj.bjp.0707488.
81. Straumann A, Hoesli S, Bussmann C, Stuck M, Perkins M, Collins LP, et al. Anti-eosinophil activity and clinical efficacy of the CRTH2 antagonist OC000459 in eosinophilic esophagitis. Allergy. 2013;68(3):375–85. https://doi.org/10.1111/all.12096.
82. Netzer P, Gschossmann JM, Straumann A, Sendensky A, Weimann R, Schoepfer AM. Corticosteroid-dependent eosinophilic oesophagitis: azathioprine and 6-mercaptopurine can induce and maintain long-term remission. Eur J Gastroenterol Hepatol. 2007;19(10):865–9. https://doi.org/10.1097/MEG.0b013e32825a6ab4.
83. Molina-Infante J, Schoepfer AM, Lucendo AJ, Dellon ES. Eosinophilic esophagitis: what can we learn from Crohn's disease? United Eur Gastroenterol J. 2017;5(6):762–72. https://doi.org/10.1177/2050640616672953.
84. Mishra A, Hogan SP, Brandt EB, Rothenberg ME. IL-5 promotes eosinophil trafficking to the esophagus. J Immunol. 2002;168(5):2464–9.
85. O'Byrne PM, Inman MD, Parameswaran K. The trials and tribulations of IL-5, eosinophils, and allergic asthma. J Allergy Clin Immunol. 2001;108(4):503–8. https://doi.org/10.1067/mai.2001.119149.
86. Rothenberg ME. Eosinophilia. N Eng J Med. 1998;338(22):1592–600. https://doi.org/10.1056/nejm199805283382206.
87. Masterson JC, McNamee EN, Hosford L, Capocelli KE, Ruybal J, Fillon SA, et al. Local hypersensitivity reaction in transgenic mice with squamous epithelial IL-5 overexpression provides a novel model of eosinophilic oesophagitis. Gut. 2014;63(1):43–53. https://doi.org/10.1136/gutjnl-2012-303631.
88. Antoniu SA. Mepolizumab for difficult-to-control asthma with persistent sputum eosinophilia. Expert Opin Investig Drugs. 2009;18(6):869–71. https://doi.org/10.1517/13543780902922678.
89. Gevaert P, Van Bruaene N, Cattaert T, Van Steen K, Van Zele T, Acke F, et al. Mepolizumab, a humanized anti-IL-5 mAb, as a treatment option for severe nasal polyposis. J Allergy Clin Immunol. 2011;128(5):989.e1-8–995.e1-8. https://doi.org/10.1016/j.jaci.2011.07.056.
90. Plotz SG, Simon HU, Darsow U, Simon D, Vassina E, Yousefi S, et al. Use of an anti-interleukin-5 antibody in the hypereosinophilic syndrome with eosinophilic dermatitis. N Engl J Med. 2003;349(24):2334–9. https://doi.org/10.1056/NEJMoa031261.
91. Stein ML, Collins MH, Villanueva JM, Kushner JP, Putnam PE, Buckmeier BK, et al. Anti-IL-5 (mepolizumab) therapy for eosinophilic esophagitis. J Allergy Clin Immunol. 2006;118(6):1312–9. https://doi.org/10.1016/j.jaci.2006.09.007.
92. Straumann A, Conus S, Grzonka P, Kita H, Kephart G, Bussmann C, et al. Anti-interleukin-5 antibody treatment (mepolizumab) in active eosinophilic oesophagitis: a randomised, placebo-controlled, double-blind trial. Gut. 2010;59(1):21–30. https://doi.org/10.1136/gut.2009.178558.
93. Assa'ad AH, Gupta SK, Collins MH, Thomson M, Heath AT, Smith DA, et al. An antibody against IL-5 reduces numbers of esophageal intraepithelial eosinophils in children with eosinophilic esophagitis. Gastroenterology. 2011;141(5):1593–604. https://doi.org/10.1053/j.gastro.2011.07.044.
94. Spergel JM, Rothenberg ME, Collins MH, Furuta GT, Markowitz JE, Fuchs G 3rd, et al. Reslizumab in children and adolescents with eosinophilic esophagitis: results of a double-blind, randomized, placebo-controlled trial. J Allergy Clin Immunol. 2012;129(2):456.e1-3–463.e1-3. https://doi.org/10.1016/j.jaci.2011.11.044.
95. Markowitz JE, Jobe L, Miller M, Frost C, Laney Z, Eke R. Safety and efficacy of reslizumab for children and adolescents with eosinophilic esophagitis treated for 9 years. J Pediatr Gastroenterol Nutr. 2018;66(6):893–7. https://doi.org/10.1097/mpg.0000000000001840.
96. Nair P, Wenzel S, Rabe KF, Bourdin A, Lugogo NL, Kuna P, et al. Oral glucocorticoid-sparing effect of benralizumab in severe asthma. N Engl J Med. 2017;376(25):2448–58. https://doi.org/10.1056/NEJMoa1703501.
97. Matera MG, Rogliani P, Calzetta L, Canonica GW, Cazzola M. Benralizumab for the treatment of asthma. Drugs Today (Barc). 2017;53(12):633–45. https://doi.org/10.1358/dot.2017.53.12.2736670.
98. FitzGerald JM, Bleecker ER, Nair P, Korn S, Ohta K, Lommatzsch M, et al. Benralizumab, an anti-interleukin-5 receptor alpha monoclonal antibody, as add-on treatment for patients with severe, uncontrolled, eosinophilic asthma (CALIMA): a randomised, double-blind, placebo-controlled phase 3 trial. Lancet. 2016;388(10056):2128–41. https://doi.org/10.1016/s0140-6736(16)31322-8.
99. Blanchard C, Mingler MK, McBride M, Putnam PE, Collins MH, Chang G, et al. Periostin facilitates eosinophil tissue infiltration in allergic lung and esophageal responses. Mucosal Immunol. 2008;1(4):289–96. https://doi.org/10.1038/mi.2008.15.
100. Blanchard C, Stucke EM, Burwinkel K, Caldwell JM, Collins MH, Ahrens A, et al. Coordinate interaction between IL-13 and epithelial differentiation cluster genes in eosinophilic esophagitis. J Immunol. 2010;184(7):4033–41. https://doi.org/10.4049/jimmunol.0903069.
101. Sherrill JD, Kc K, Wu D, Djukic Z, Caldwell JM, Stucke EM, et al. Desmoglein-1 regulates esophageal epithelial barrier function and immune responses in eosinophilic esophagitis. Mucosal Immunol. 2014;7(3):718–29. https://doi.org/10.1038/mi.2013.90.
102. Mishra A, Rothenberg ME. Intratracheal IL-13 induces eosinophilic esophagitis by an IL-5, eotaxin-1, and STAT6-dependent mechanism. Gastroenterology. 2003;125(5):1419–27.
103. Rothenberg ME, Wen T, Greenberg A, Alpan O, Enav B, Hirano I, et al. Intravenous anti-IL-13 mAb QAX576 for the treatment of eosinophilic esophagitis. J Allergy Clin Immunol. 2015;135(2):500–7. https://doi.org/10.1016/j.jaci.2014.07.049.
104. Hirano I, Collins MH, Assouline-Dayan Y, Evans L, Gupta S, Schoepfer AM, et al. RPC4046, a monoclonal antibody against IL13, reduces histologic and endoscopic activity in patients with eosinophilic esophagitis. Gastroenterology. 2018. https://doi.org/10.1053/j.gastro.2018.10.051.
105. Collins MH, Martin LJ, Alexander ES, Boyd JT, Sheridan R, He H, et al. Newly developed and validated eosinophilic esophagitis histology scoring system and evidence that it outperforms peak eosinophil count for disease diagnosis and monitoring. Dis Esophagus. 2017;30(3):1–8. https://doi.org/10.1111/dote.12470.
106. Dellon ES, Collins MH, Assouline-Dayan Y, Evans L, Gupta S, Schoepfer A, et al. Long-term efficacy and safety of RPC4046, an anti-interleukin-13 monoclonal antibody, in

patients with eosinophilic esophagitis: results from the open-label extension of the HEROES study. J Allergy Clin Immunol. 2019;143(2):AB208. https://doi.org/10.1016/j.jaci.2018.12.635.
107. Corren J, Lemanske RF, Hanania NA, Korenblat PE, Parsey MV, Arron JR, et al. Lebrikizumab treatment in adults with asthma. N Engl J Med. 2011;365(12):1088–98. https://doi.org/10.1056/NEJMoa1106469.
108. Piper E, Brightling C, Niven R, Oh C, Faggioni R, Poon K, et al. A phase II placebo-controlled study of tralokinumab in moderate-to-severe asthma. Eur Respir J. 2013;41(2):330–8. https://doi.org/10.1183/09031936.00223411.
109. Simpson EL, Flohr C, Eichenfield LF, Bieber T, Sofen H, Taieb A, et al. Efficacy and safety of lebrikizumab (an anti-IL-13 monoclonal antibody) in adults with moderate-to-severe atopic dermatitis inadequately controlled by topical corticosteroids: a randomized, placebo-controlled phase II trial (TREBLE). J Am Acad Dermatol. 2018;78(5):863.e11–871.e11. https://doi.org/10.1016/j.jaad.2018.01.017.
110. Wollenberg A, Howell MD, Guttman-Yassky E, Silverberg JI, Kell C, Ranade K, et al. Treatment of atopic dermatitis with tralokinumab, an anti-IL-13 mAb. J Allergy Clin Immunol. 2019;143(1):135–41. https://doi.org/10.1016/j.jaci.2018.05.029.
111. Abonia JP, Blanchard C, Butz BB, Rainey HF, Collins MH, Stringer K, et al. Involvement of mast cells in eosinophilic esophagitis. J Allergy Clin Immunol. 2010;126(1):140–9. https://doi.org/10.1016/j.jaci.2010.04.009.
112. Mulder DJ, Mak N, Hurlbut DJ, Justinich CJ. Atopic and non-atopic eosinophilic oesophagitis are distinguished by immunoglobulin E-bearing intraepithelial mast cells. Histopathology. 2012;61(5):810–22. https://doi.org/10.1111/j.1365-2559.2012.4303.x.
113. Vicario M, Blanchard C, Stringer KF, Collins MH, Mingler MK, Ahrens A, et al. Local B cells and IgE production in the oesophageal mucosa in eosinophilic oesophagitis. Gut. 2010;59(1):12–20. https://doi.org/10.1136/gut.2009.178020.
114. Arasi S, Costa S, Magazzù G, Ieni A, Crisafulli G, Caminiti L, et al. Omalizumab therapy in a 13-year-old boy with severe persistent asthma and concomitant eosinophilic esophagitis. Ital J Pediatr. 2016;42:32. https://doi.org/10.1186/s13052-016-0243-x.
115. Rocha R, Vitor AB, Trindade E, Lima R, Tavares M, Lopes J, et al. Omalizumab in the treatment of eosinophilic esophagitis and food allergy. Eur J Pediatr. 2011;170(11):1471–4. https://doi.org/10.1007/s00431-011-1540-4.
116. Clayton F, Fang JC, Gleich GJ, Lucendo AJ, Olalla JM, Vinson LA, et al. Eosinophilic esophagitis in adults is associated with IgG4 and not mediated by IgE. Gastroenterology. 2014;147(3):602–9. https://doi.org/10.1053/j.gastro.2014.05.036.
117. Loizou D, Enav B, Komlodi-Pasztor E, Hider P, Kim-Chang J, Noonan L, et al. A pilot study of omalizumab in eosinophilic esophagitis. PloS One. 2015;10(3):e0113483. https://doi.org/10.1371/journal.pone.0113483.
118. Kagami S, Saeki H, Komine M, Kakinuma T, Tsunemi Y, Nakamura K, et al. Interleukin-4 and interleukin-13 enhance CCL26 production in a human keratinocyte cell line, HaCaT cells. Clin Exp Immunol. 2005;141(3):459–66. https://doi.org/10.1111/j.1365-2249.2005.02875.x.
119. Targan SR, Hanauer SB, van Deventer SJ, Mayer L, Present DH, Braakman T, et al. A short-term study of chimeric monoclonal antibody cA2 to tumor necrosis factor alpha for Crohn's disease. Crohn's Disease cA2 study group. N Engl J Med. 1997;337(15):1029–35.
120. Straumann A, Bussmann C, Conus S, Beglinger C, Simon HU. Anti-TNF-alpha (infliximab) therapy for severe adult eosinophilic esophagitis. J Allergy Clin Immunol. 2008;122(2):425–7. https://doi.org/10.1016/j.jaci.2008.06.012.
121. Radonjic-Hoesli S, Valent P, Klion AD, Wechsler ME, Simon H-U. Novel targeted therapies for eosinophil-associated diseases and allergy. Annu Rev Pharmacol Toxicol. 2015;55(1):633–56. https://doi.org/10.1146/annurev-pharmtox-010814-124407.
122. Rubinstein E, Cho JY, Rosenthal P, Chao J, Miller M, Pham A, et al. Siglec-F inhibition reduces esophageal eosinophilia and angiogenesis in a mouse model of eosinophilic esophagitis. J Pediatr Gastroenterol Nutr. 2011;53(4):409–16. https://doi.org/10.1097/MPG.0b013e3182182ff8.
123. Youngblood B, Brock EC, Leung J, Bebbington C, Tomasevic N. Anti-Siglec-8 antibody reduces eosinophil and mast cell infiltration in a mouse model of eosinophilic gastritis: a novel therapeutic approach for eosinophilic gastrointestinal diseases. Gastroenterology. 2018;154(6):S1358. https://doi.org/10.1016/s0016-5085(18)34443-3.
124. Lavoie P, Robitaille G, Agharazii M, Ledbetter S, Lebel M, Lariviere R. Neutralization of transforming growth factor-beta attenuates hypertension and prevents renal injury in uremic rats. J Hypertens. 2005;23(10):1895–903.
125. Habashi JP, Judge DP, Holm TM, Cohn RD, Loeys BL, Cooper TK, et al. Losartan, an AT1 antagonist, prevents aortic aneurysm in a mouse model of Marfan syndrome. Science (New York, NY). 2006;312(5770):117–21. https://doi.org/10.1126/science.1124287.
126. Dietz HC. TGF-beta in the pathogenesis and prevention of disease: a matter of aneurysmic proportions. J Clin Investig. 2010;120(2):403–7. https://doi.org/10.1172/jci42014.
127. Cohn RD, van Erp C, Habashi JP, Soleimani AA, Klein EC, Lisi MT, et al. Angiotensin II type 1 receptor blockade attenuates TGF-beta-induced failure of muscle regeneration in multiple myopathic states. Nat Med. 2007;13(2):204–10. https://doi.org/10.1038/nm1536.
128. Chamberlain JS. ACE inhibitor bulks up muscle. Nat Med. 2007;13(2):125–6. https://doi.org/10.1038/nm0207-125.
129. Takeda N, Yagi H, Hara H, Fujiwara T, Fujita D, Nawata K, et al. Pathophysiology and management of cardiovascular manifestations in Marfan and Loeys-Dietz syndromes. Int Heart J. 2016;57(3):271–7. https://doi.org/10.1536/ihj.16-094.
130. Neighbour H, Boulet LP, Lemiere C, Sehmi R, Leigh R, Sousa AR, et al. Safety and efficacy of an oral CCR130 antagonist in patients with asthma and eosinophilic bronchitis: a randomized, placebo-controlled clinical trial. Clin Exp Allergy. 2014;44(4):508–16. https://doi.org/10.1111/cea.12244.
131. Noti M, Wojno ED, Kim BS, Siracusa MC, Giacomin PR, Nair MG, et al. Thymic stromal lymphopoietin-elicited basophil responses promote eosinophilic esophagitis. Nat Med. 2013;19(8):1005–13. https://doi.org/10.1038/nm.3281.
132. Gauvreau GM, O'Byrne PM, Boulet LP, Wang Y, Cockcroft D, Bigler J, et al. Effects of an anti-TSLP antibody on allergen-induced asthmatic responses. N Engl J Med. 2014;370(22):2102–10. https://doi.org/10.1056/NEJMoa1402895.
133. Simpson EL, Parnes JR, She D, Crouch S, Rees W, Mo M, et al. Tezepelumab, an anti-TSLP monoclonal antibody, in the treatment of moderate to severe atopic dermatitis: a randomized phase 2a clinical trial. J Am Acad Dermatol. 2018. https://doi.org/10.1016/j.jaad.2018.11.059.
134. Caldwell JM, Collins MH, Kemme KA, Sherrill JD, Wen T, Rochman M, et al. Cadherin 26 is an alpha integrin-binding epithelial receptor regulated during allergic inflammation. Mucosal Immunol. 2017;10(5):1190–201. https://doi.org/10.1038/mi.2016.120.
135. Nhu QM, Chiao H, Moawad FJ, Bao F, Konijeti GG. The anti-alpha4beta7 integrin therapeutic antibody for inflammatory bowel disease, vedolizumab, ameliorates eosinophilic esophagitis: a novel clinical observation. Am J Gastroenterol.

2018;113(8):1261–3. https://doi.org/10.1038/s41395-018-0145-1.
136. Kim HP, Reed CC, Herfarth HH, Dellon ES. Vedolizumab treatment may reduce steroid burden and improve histology in patients with eosinophilic gastroenteritis. Clin Gastroenterol Hepatol. 2018;16(12):1992–4. https://doi.org/10.1016/j.cgh.2018.03.024.
137. Otani IM, Anilkumar AA, Newbury RO, Bhagat M, Beppu LY, Dohil R, et al. Anti-IL-5 therapy reduces mast cell and IL-9 cell numbers in pediatric patients with eosinophilic esophagitis. J Allergy Clin Immunol. 2013;131(6):1576–82. https://doi.org/10.1016/j.jaci.2013.02.042.
138. Aceves SS, Chen D, Newbury RO, Dohil R, Bastian JF, Broide DH. Mast cells infiltrate the esophageal smooth muscle in patients with eosinophilic esophagitis, express TGF-beta1, and increase esophageal smooth muscle contraction. J Allergy Clin Immunol. 2010;126(6):1198.e4–1204.e4. https://doi.org/10.1016/j.jaci.2010.08.050.
139. Chen CY, Lee JB, Liu B, Ohta S, Wang PY, Kartashov AV, et al. Induction of interleukin-9-producing mucosal mast cells promotes susceptibility to IgE-mediated experimental food allergy. Immunity. 2015;43(4):788–802. https://doi.org/10.1016/j.immuni.2015.08.020.
140. Oh CK, Leigh R, McLaurin KK, Kim K, Hultquist M, Molfino NA. A randomized, controlled trial to evaluate the effect of an anti-interleukin-9 monoclonal antibody in adults with uncontrolled asthma. Respir Res. 2013;14:93. https://doi.org/10.1186/1465-9921-14-93.
141. Doshi A, Khamishon R, Rawson R, Duong L, Dohil L, Myers SJ, et al. Interleukin 9 alters epithelial barrier and E-cadherin in eosinophilic esophagitis. J Pediatr Gastroenterol Nutr. 2019;68(2):225–31. https://doi.org/10.1097/mpg.0000000000002144.
142. Hoontrakoon R, Chu HW, Gardai SJ, Wenzel SE, McDonald P, Fadok VA, et al. Interleukin-15 inhibits spontaneous apoptosis in human eosinophils via autocrine production of granulocyte macrophage-colony stimulating factor and nuclear factor-kappaB activation. Am J Respir Cell Mol Biol. 2002;26(4):404–12. https://doi.org/10.1165/ajrcmb.26.4.4517.
143. Mori A, Suko M, Kaminuma O, Inoue S, Ohmura T, Nishizaki Y, et al. IL-15 promotes cytokine production of human T helper cells. J Immunol. 1996;156(7):2400–5.
144. Rayapudi M, Rajavelu P, Zhu X, Kaul A, Niranjan R, Dynda S, et al. Invariant natural killer T-cell neutralization is a possible novel therapy for human eosinophilic esophagitis. Clin Transl Immunology. 2014;3(1):e9. https://doi.org/10.1038/cti.2013.13.
145. Zhu X, Wang M, Mavi P, Rayapudi M, Pandey AK, Kaul A, et al. Interleukin-15 expression is increased in human eosinophilic esophagitis and mediates pathogenesis in mice. Gastroenterology. 2010;139(1):182.e7–193.e7. https://doi.org/10.1053/j.gastro.2010.03.057.
146. Vicari AP, Schoepfer AM, Meresse B, Goffin L, Leger O, Josserand S, et al. Discovery and characterization of a novel humanized anti-IL-15 antibody and its relevance for the treatment of refractory celiac disease and eosinophilic esophagitis. MAbs. 2017;9(6):927–44. https://doi.org/10.1080/19420862.2017.1332553.
147. Dellon ES, Woosley JT, Arrington A, McGee SJ, Covington J, Moist SE, et al. Efficacy of budesonide vs fluticasone for initial treatment of eosinophilic esophagitis in a randomized controlled trial. Gastroenterology. 2019;15791:65–73. https://doi.org/10.1053/j.gastro.2019.03.014.