Brief Report

Patch testing with expired Indian patch test kits: Results of a pilot study

Vikram K. Mahajan, Pushpinder Singh Chauhan, Karaninder Singh Mehta, Anuj Sharma, Bhumika Chowdhary, Niharika Dhattarwal, Hitender Sharma, Monika Chandel, Yog Raj Verma

Department of Dermatology, Venereology and Leprosy, Dr. Rajendra Prasad Government Medical College, Kangra (Tanda), Himachal Pradesh, India

Corresponding author:
Dr. Vikram K. Mahajan,
Department of Dermatology,
Venereology and Leprosy,
Dr. Rajendra Prasad,
Government Medical College,
Kangra (Tanda) - 176 001,
Himachal Pradesh, India.
vkm1@rediffmail.com

Received: May, 2019
Accepted: August, 2020
Published:

DOI:
10.25259/IJDVL_390_19

PMID:
***

Abstract

Background: The reliability of patch testing with expired Indian standard patch test kits has been not evaluated before.

Methods: Thirty adults (men:women 25:5) with allergic contact dermatitis were divided into three groups of ten patients each for patch testing by Finn chamber® method using Indian standard patch test kits having expiry in 2016, 2015 and 2014. The results were compared with those from a new kit with 2018 expiry.

Results: Ten patients in group-1, eight patients in group-2 and seven patients in group-3 developed positive reactions of identical intensities and mostly from identical allergens from all four kits. The major contact allergens eliciting positive reactions of identical intensities were parthenium in nine, five and three patients, colophony in four, one and zero patients, fragrance mix in three, three and one patients, thiuram mix in three, one and one patients, and paraphenylene diamine in two, one and three patients from group-1,-2, and -3, respectively.

Limitations: Small number of patients in each group remains the major limitation of the study. Whether or not these results can be extrapolated with patch test results from other similar patch test kits available across countries also needs confirmation.

Conclusion: The patch test allergens can be used beyond labeled expiry dates but needs confirmation by a few large studies and using other available patch test kits. This is important as the relevance of patch test results for individual allergen in this scenario may remain debatable requiring careful interpretation.

Key words: Airborne contact dermatitis, allergic contact dermatitis, Indian patch test series, parthenium, Patch test

Introduction

When performed accurately with correct interpretation of results, the patch test remains an important investigative tool to identify specific allergens responsible for causing allergic contact dermatitis, preventing recurrences and to differentiate allergic contact dermatitis from irritant contact dermatitis. Several allergens or haptens which are common sensitizers responsible for >80% of cases of allergic contact dermatitis are grouped together in a patch test battery or series. A patch test series usually includes metals (nickel, chromates, cobalt, etc.), rubber and leather chemicals, formaldehyde, lanolin, fragrances, constituents of cosmetics and toiletries, hair colorants, pharmaceutical items, preservatives and other additives from foods, beverages or other products of daily use, and extracts such as sesquiterpine oleoresin from *Compositae* plants (*Parthenium hysterophorus* in India) as common allergens. It is usually standardized for safety and reproducibility of results before approval/recommendation

How to cite this article: Mahajan VK, Chauhan PS, Mehta KS, Sharma A, Chowdhry B, Dhattarwal N, *et al*. Patch testing with expired Indian patch test kits: Results of a pilot study. Indian J Dermatol Venereol Leprol, doi: 10.25259/IJDVL_390_19

This is an open-access article distributed under the terms of the Creative Commons Attribution-Non Commercial-Share Alike 4.0 License, which allows others to remix, tweak, and build upon the work non-commercially, as long as the author is credited and the new creations are licensed under the identical terms.

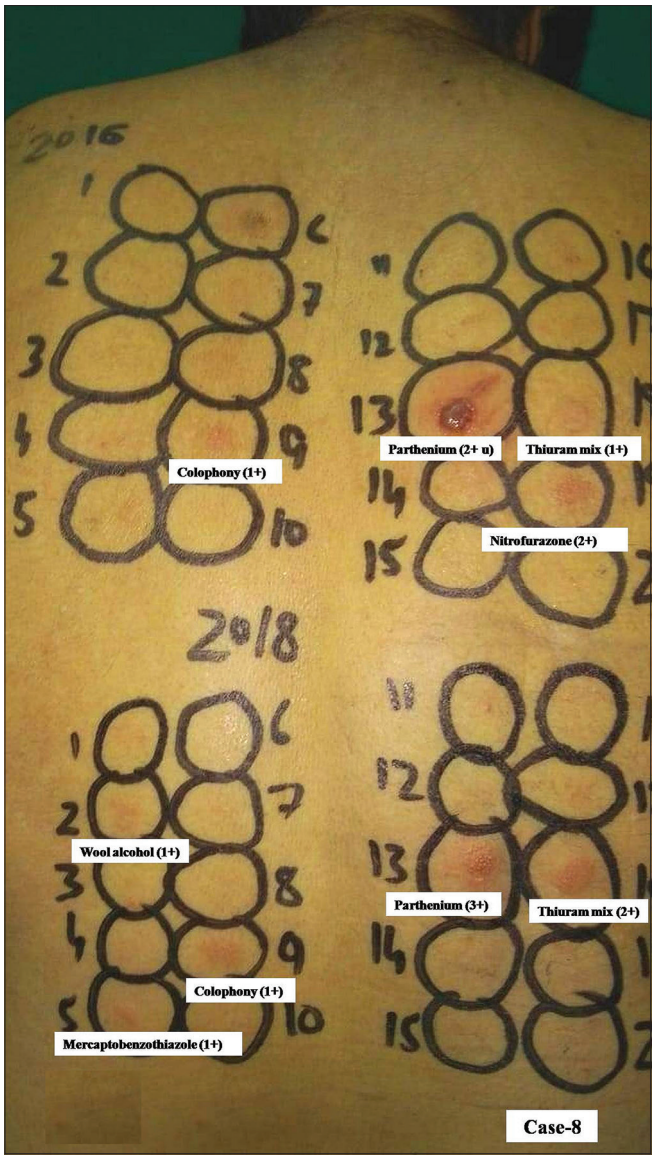

Figure 1a: Group 1, Case 8, positive patch test reactions from parthenium, colophony and thiuram mix were observed from haptens in both kits. Interestingly, parthenium from kit expired in 2016 elicited extreme positive reaction (3+ with ulceration) while reaction from thiuram mix was stronger (2+) compared to 1+ from the new kit. Nitrofurazone from expired kit was another clinically relevant allergen (sensitization was from medicated strips frequently used by him). However, only mercaptobenzothiazole, wool alcohol and fragrance mix from new kit elicited positive reactions

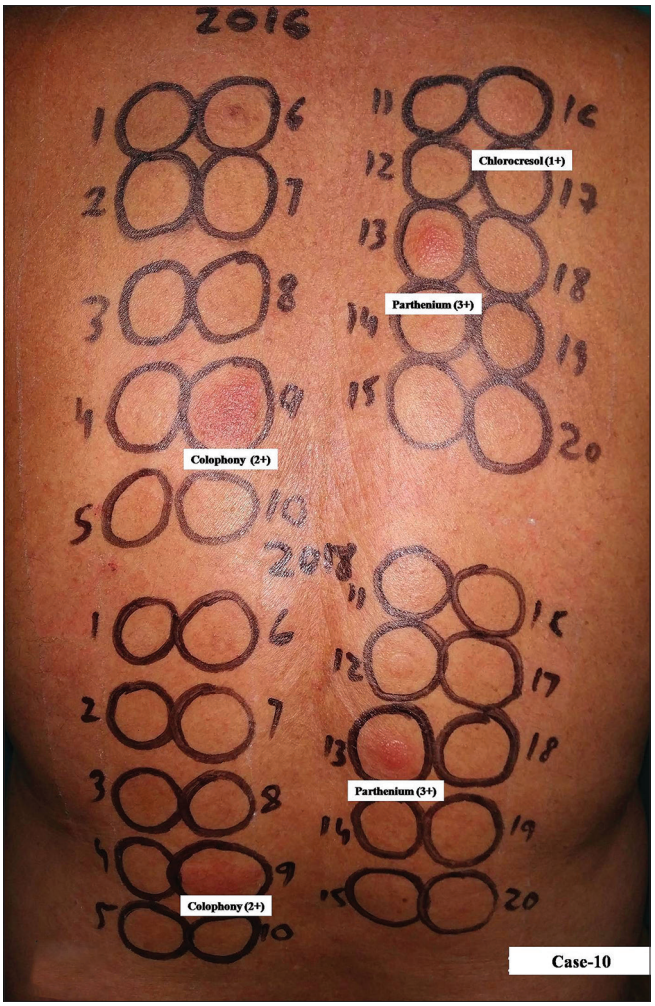

Figure 1b: Group 1, Case 10, positive patch test reactions of equal intensity were observed due to parthenium and colophony from both kits. Parthenium from kit expired in 2016 elicited stronger positive reaction (3+) compared to that from the new kit while colophony elicited positive reaction (2+) of equal intensity. Cholorocresol (a fungicide/antiseptic in topical medications) from the expired kit was another relevant allergen eliciting positive reaction

by national or international authorities/research groups prior to marketing and use in clinical practice. However, reluctance to do patch testing is not uncommon among dermatologists, who believe that it is not cost effective, is time consuming and needs several patient visits. Besides, unavailability of suitable test materials and the perceived risk involved in using a patch test kit beyond expiry date further discourage dermatologists from doing patch testing routinely. We studied the capacity of long-expired Indian standard patch test kits to elicit positive reactions in comparison to an un-expired kit.

Methods

The study comprised 30 patients aged 18 years and above and clinically suspected to have allergic contact dermatitis. After approval from Institutional Ethics Committee (Registration no ECR/490/Inst/HP/2013/RR-16) and informed/written consent, they were patch tested between Jan and Dec 2018 with Contact Dermatitis and Occupational Dermatoses Forum of India approved Indian standard patch test kit, marketed in India by Chemotechnique Diagnostics, Sweden, (www.chemotechnique.se) in collaboration with Systopic India Ltd, New Delhi (India) presently costing about rupees ten thousand each. Pregnant or lactating women were excluded from the

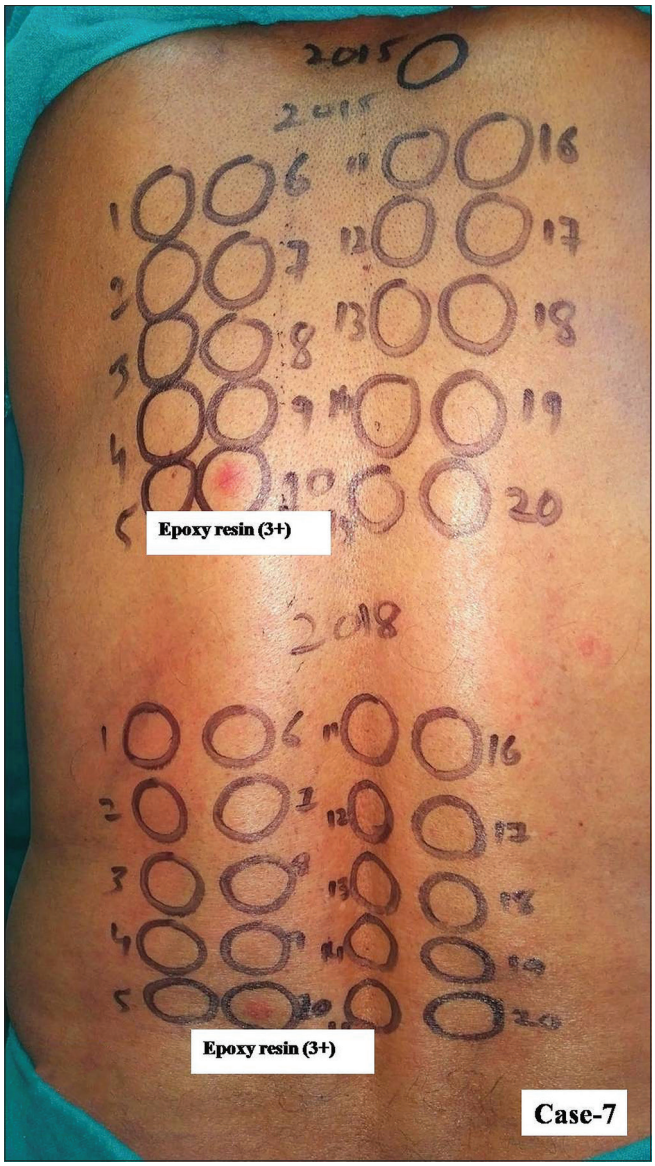

Figure 2a: Group 2, Case 7, positive patch test reactions of equal intensity were observed from epoxy resin from both kits

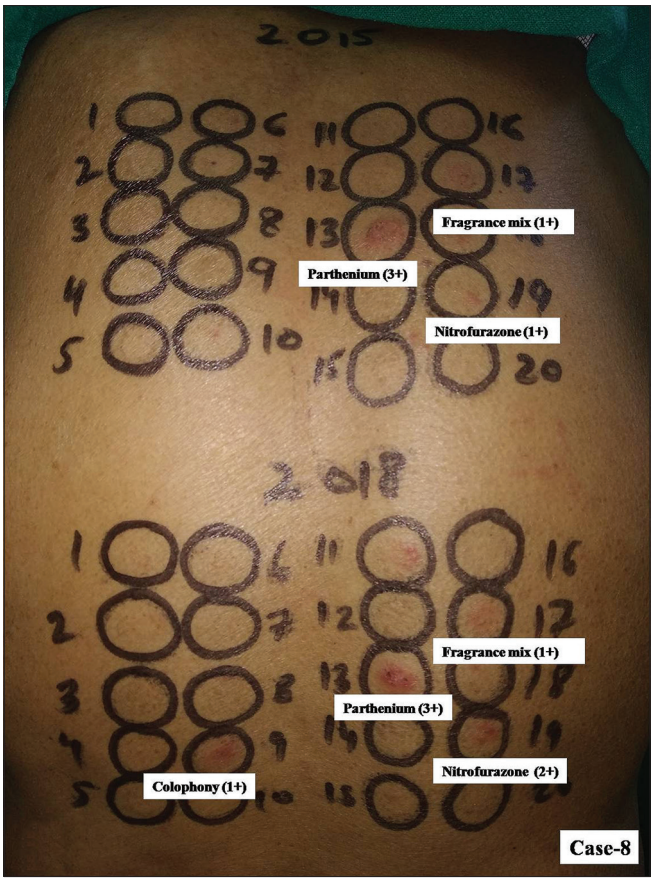

Figure 2b: Group 2, Case 8, positive patch test reactions of equal intensity were observed due to parthenium and fragrance mix from both kits. Colophony elicited positive reaction (1+) from kit expired in 2015 was another relevant allergen eliciting positive reaction in him

study and patients having acute dermatitis were enrolled only after acute dermatitis had subsided and they were off systemic or topical corticosteroids for ≥2 weeks. All enrolled patients were hospitalized and subjected to detailed medical history and clinical examination and divided into three groups of ten patients each. The patch testing was performed by Finn chamber® method according to European Society of Contact Dermatitis (ESCD) guidelines with Indian standard patch test kits having expiry date in 2016, 2015 and 2014.[1] The results were compared with those from a new patch test kit having expiry date in 2018 tested concurrently. All the patch test kits having identical allergens were purchased from Systopic India Ltd, New Delhi (India) and had been stored at 4ºC before testing. The Finn chambers (8mm) with test allergens were applied on non hairy upper back after gentle cleansing with ethyl alcohol and left for 48 h. The reading of results was done after 48 h (D2) and 72 h (D3).The results were graded according to the International Contact Dermatitis Research Group criteria.[1] Only positive reactions persisting on D3 were considered positive and significant for final analysis. The relevance of positive patch test results was determined clinically as "definite" if the reaction was positive to the patch test allergen and exposure to it could be verified, "probable" if the presence of identified allergen in the known skin contactants could be verified, "possible" if the patient was exposed to the material known to have the putative allergen, "past" if a positive patch test reaction could be related to previous and unrelated episode of contact dermatitis and "unknown" if no relevance could be made out.[2]

Results

These 30 patients (men: women 25:5) were aged between 29 and 75 years (mean: 56.6 years). They were primarily involved in agriculture and related activities. They had allergic contact dermatitis for two months to 25 years (mean: 21.3 years) with exacerbations and remissions. Common

clinical patterns were airborne contact dermatitis in eight patients, chronic actinic dermatitis in fourteen patients, facial, acral and acrofacial contact dermatitis in seven patients and scalp contact dermatitis in one patient.

Tables 1-3 depict detailed baseline characteristics and patch test results in each group. Intragroup comparisons showed that all the ten patients in group-1, eight patients in group-2 and seven patients in group-3 developed clinically relevant positive reactions of identical intensities from identical allergens from both the kits [Table 4]. The major contact allergens from both the patch kits eliciting positive reactions of identical intensities in group-1 were parthenium in nine patients, colophony in four patients, fragrance mix and thiuram mix in three patients each and paraphenylene diamine and black rubber mix in two patients each [Figures 1a and b]. The positive reactions due to other allergens such as chlorocresol, *Myroxylon pereirae* (balsam of Peru) and nitrofurazone were also similar from both the kits in a majority of the cases. Three men aged 63, 70 and 60 years (case-1,-2 and -3), patch tested 3, 4 and 5 years back had shown parthenium as a major contact allergen. Upon re-testing, they again showed positive reactions of the same intensity from both the kits. Similarly, among eight patients in group-2, parthenium in five patients and fragrance mix in three patients were the major allergens eliciting positive reactions of identical intensities [Figures 2a and b]. Positive reactions from neomycin, formaldehyde, potassium dichromate, epoxy resin, paraben mix, nitrofurazone, colophony, thiuram mix and wool alcohol were also of similar intensity from both the kits. In group-3 patients, paraphenylene diamine in three patients, parthenium in two patients and fragrance mix in one patient were the major contact allergens from both the kits eliciting positive reactions of identical intensities [Figures 3a and b]. Other common allergens with identical intensity of positive reactions included *Myroxylon pereirae*, potassium dichromate, paraben mix and chlorocresol in one patient each. One patient in group-3 developed angry back phenomenon from both the kits.

Discussion

Over the years, Contact Dermatitis and Occupational Dermatoses Forum of India-approved Indian standard patch test kit has become established across the country for patch testing.[3-7] The reliability of patch testing with expired patch test kits has been not evaluated before. Parthenium, paraphenylene diamine, thiuram mix and black rubber mix

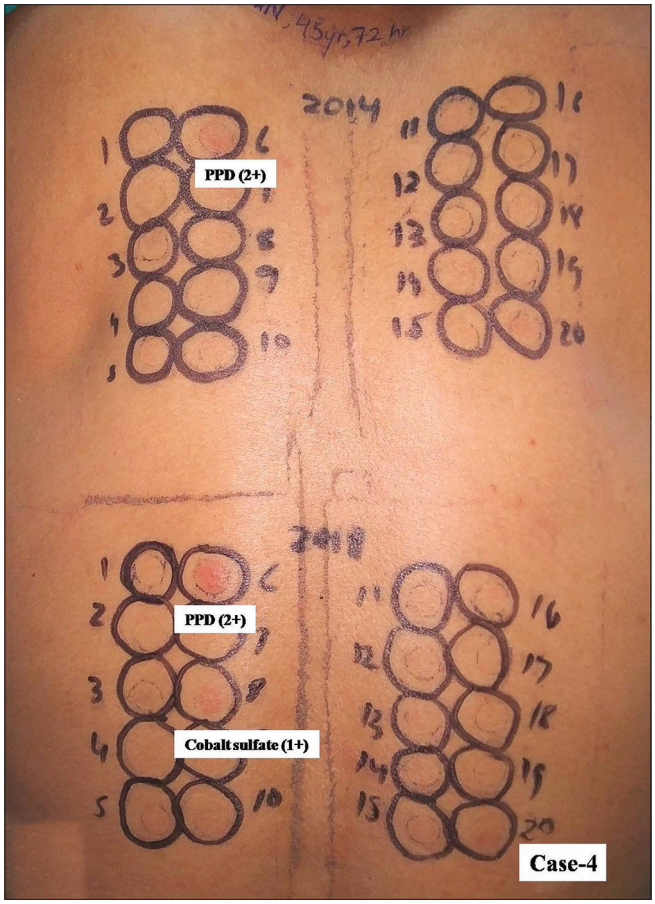

Figure 3a: Group 3, Case 4, positive patch test reactions from paraphenylene diamine occured from haptens in both kits. However, only cobalt sulfate from new kit elicited positive reaction

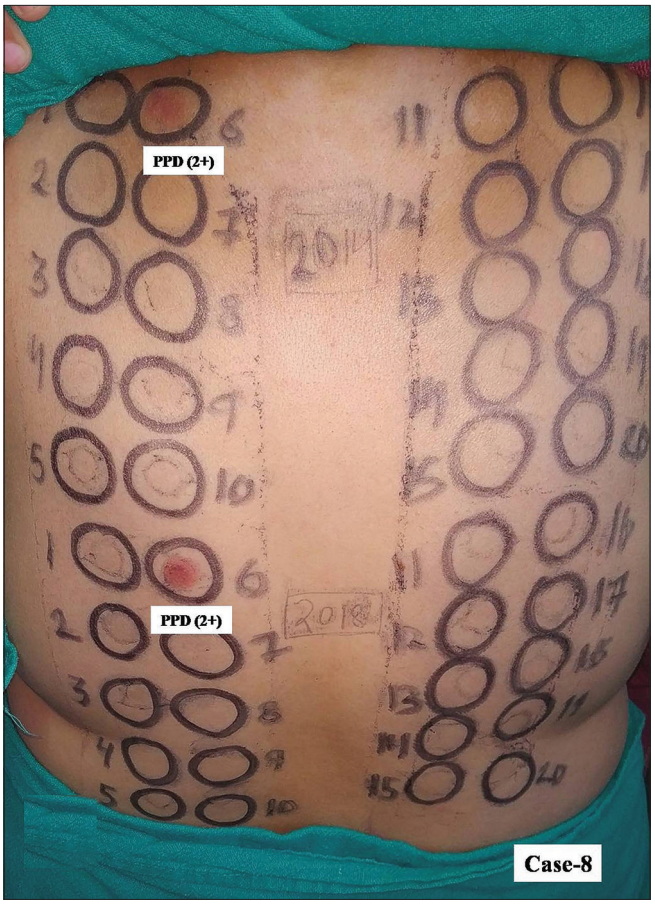

Figure 3b: Group 3, Case 8, positive patch test reactions of equal intensity (2+) were observed due to paraphenylene diamine in a patient with contact dermatitis from hair colorant

are potent and ubiquitous contact sensitizers which was seen in the subjects of this study as well. *Myroxylon pereirae*, fragrances, colophony, preservatives, other prominent contact allergens in our patients, are common additives in topical medications leading to contact sensitization from their frequent use by dermatology patients. All these have been frequently documented allergens in the region.[6,7] The positive reactions from patch test kits with expiry in 2016, 2015 and 2014 were from almost identical allergens and were comparable in intensity with those from the patch test kit with expiry in 2018. Fragrance mix and/or parthenium from both the kits also elicited positive reactions in one patient (case-3

Table 1: Group-1 patch test results with Indian standard patch test series with expiry in 2016 versus 2018

Case number	Age in years/sex	Occupation	Sites of dermatitis	Clinical diagnosis	Duration	Patch test results (grades) ISPTS kit 2016*	Patch test results (grades) ISPTS kit 2018*
1	70/male[a]	Agriculture	Face, trunk and upper limbs	ABCD	18 years	**Parthenium (3+)**	**Parthenium (3+)**
2	60/male[b]	Agriculture	Face, V area-neck and dorsal hands/ feet	CAD	10 years	**Parthenium (3+)**	**Parthenium (3+)**
3	63/male[c]	Agriculture	Face, neck, back and limb flexures	ABCD	20 years	**Parthenium (3+u) Fragrance mix (1+)**	**Parthenium (3+u) Fragrance mix (1+)**
4	62/female	Homemaker/ Agriculture	Face, hands and feet	Acrofacial dermatitis	2 months	**PPD (3+), benzocaine (1+) and** MBT (1+)	**PPD (2+), benzocaine (1+) and** epoxy resin (2+)
5	68/male	Agriculture	Face, neck and limb flexures	ABCD	4 years	**Parthenium (3+) and colophony (1+)**	**Parthenium (3+), colophony (1+) and** *Myroxylon pereirae* (1+)
6	70/male	Agriculture	Scalp, face, V area-neck and dorsal hands/feet	CAD	2 years	**Parthenium (3+u), PPD (3+), colophony (3+), chlorocresol (3+) and thiuram mix (3+) Black rubber mix (3+), fragrance mix (2+), nitrofurazone (2+), *Myroxylon pereirae* (2+), paraben mix (1+),** cobalt sulfate (1+) and formaldehyde (1+)	**Parthenium (3+u), PPD (3+), colophony (3+), chlorocresol (3+) and thiuram mix (3+) Black rubber mix (3+), fragrance mix (3+), nitrofurazone (1+), Myroxylon pereirae (2+) and paraben mix (1+)**
7	48/male	Self-employed (business), spare time agriculturist	Face, trunkand upper limbs	ABCD	20 years	**Parthenium (3+), thiuram mix (3+), black rubber mix (1+), fragrance mix (1+) and nitrofurazone (1+) Formaldehyde (1+),** neomycin (1+) and benzocaine (1+)	**Parthenium (3+), thiuram mix (1+), black rubber mix (1+), fragrance mix (1+) and nitrofurazone (1+) Formaldehyde (1+) and** *Myroxylon pereirae* (1+)
8	57/male	Office work (accountant)	Face, hands and feet	Acrofacial dermatitis	15 years	**Parthenium (3+u), colophony (2+), thiuram mix (1+) and** nitrofurazone (2+)	**Parthenium (3+), colophony (2+), thiuram mix (2+),** MBT (2+) and wool alcohol (1+)
9	46/male	Agriculture	Scalp, face, V area-neck and dorsal hands/feet	CAD	7 years	**Parthenium (1+)**	**Parthenium (1+)**
10	75/male	Agriculture	Face, neck and trunk upper limbs	ABCD	4 years	**Parthenium (3+) Colophony (2+) and** Chlorocresol (1+)	**Parthenium (2+) Colophony (2+)**

Positive results shown in bold indicate allergens common to both kits. "3+u" indicates intense positive reaction with ulceration. *All positive results were of definite clinical relevance, [a]Patch test results in 2013: parthenium (2+), colophony (1+), *Myroxylon pereirae* (1+) and nitrofurazone (2+), [b]Patch test results in 2014: parthenium (3+) and black rubber mix (2+), [c]Patch test results in 2015: parthenium (2+), fragrance mix (1+) and colophony (1+). Baseline characteristics: Males: Females 9:1; Age: 46-75 (mean 61.9) years; Duration of dermatitis: 2 months-18 (mean 10.02) years, Clinical patterns of dermatitis: ABCD in five patients, CAD in three patients and acrofacial dermatitis in two patients. ISPTS: Indian standard patch test series, MBT: mercaptobenzothiazole, PPD: paraphenylene diamine, ABCD: airborne contact dermatitis, CAD: chronic actinic dermatitis

Table 2: Group-2 patch test results with Indian standard patch test series with expiry in 2015 versus 2018

Case number	Age in years/sex	Occupation	Sites of dermatitis	Clinical diagnosis	Duration	Patch test results (grades) ISPTS kit 2015*	Patch test results (grades) ISPTS kit 2018*
1	70/male[a]	Agriculture	Face, neck and hands	Acrofacial dermatitis	8 years	**Parthenium (3+), neomycin (1+), fragrance mix (1+), formaldehyde (1+) and** benzocaine (1+)	**Parthenium (3+), neomycin (1+), fragrance mix (1+), formaldehyde (1+) and** chlorocresol (1+)
2	52/male	Agriculture	Face, V area-neck and dorsal hands/feet	CAD	10 years	**Parthenium (3+u) and** thiuram mix (3+)	**Parthenium (3+),** formaldehyde (2+) and 2MBT (2+)
3	61/female	Homemaker/ agriculture	Scalp dermatitis	CD from hair color	6 months	**All negative**	**All negative**
4	54/male	Agriculture/ mason (part time)	Face, hands and feet	Acrofacial dermatitis	4 years	**Parthenium (2+)**	**Parthenium (2+)**
5	40/male	Agriculture	Face, neck and limb flexures	ABCD	1 year	**All negative**	**All negative**
6	61/male[b]	Agriculture	Scalp, face, V area-neck and dorsal hands/feet	CAD	10 years	**Parthenium (3+), pot. dichromate (3+),** benzocaine (1+), thiuram mix (2+), nitrofurazone (2+) and black rubber mix (3+)	**Parthenium (3+), pot. dichromate (3+) and** chlorocresol (3+)
7	62/male	Self-employed gardening (spare time activity)	Face	Facial dermatitis	3 months	**Epoxy resin (3+),**	**Epoxy resin (3+),**
8	63/male	Agriculture	Face, neck, upper back and forearms (extensors)	CAD	25 years	**parthenium (3+), nitrofurazone (2+) andfragrance mix (1+)**	**parthenium (3+), nitrofurazone (2+), fragrance mix (1+),** paraben (2+) andcolophony (1+)
9	60/female	Home maker/ agriculture	Face, chest, dorsal hands, forearms and legs (extensors)	CAD	6 months	**PPD (1+) andfragrance mix (1+)**	**PPD (1+) andfragrance mix (1+)**
10	47/female[c]	Home maker/ agriculture	Face, neck and trunk upper limbs	ABCD with photo aggravation	15 years	**Parthenium (3+), wool alcohol (2+), thiuram mix (1+) and** 2 MBT (2+)	**Parthenium (3+), wool alcohol (1+) andthiuram mix (2+)**

Positive results shown in bold indicate allergens common to both kits. "3+ u" indicates intense positive reaction with ulceration. *All positive results were of definite clinical relevance, [a]Patch test results in 2010: parthenium (2+), [b]Patch test results in 2014: parthenium (1+), [c]Patch test results in 2010: parthenium (3+). Baseline characteristics: Males: Females 8:2; Age: 40-70 (mean 57.0) years; Duration of dermatitis: 3 months-25 (mean 7.43) years; Clinical patterns of dermatitis: ABCD in two patients, CAD in five patients, facial or acrofacial dermatitis in two patients and scalp dermatitis in one patient. ISPTS: Indian standard patch test series, MBT: mercaptobenzothiazole, PPD: paraphenylene diamine, ABCD: airborne contact dermatitis, CAD: chronic actinic dermatitis

in group 1) who had positive reactions from them in the past as well. Angry back or phenomenon of skin hyperreactivity in a group-3 patient from both the patch test kits reflected a potential to cause exaggerated true sensitivity by the expired kit as well.

It has been demonstrated that fragrances, acrylates or other volatile allergens are unstable and their concentration likely to vary from storage at room temperature affecting their allergenic potential.[8,9] However, acrylates/methylacrylates in syringes retain their allergenic potential above 80% compared with IQ™ chambers when stored in a plastic bag in a refrigerator.[10] Interestingly, parthenium from all the kits showed equally intense positive reactions, contrary to the belief that its aqueous extract, like other volatile allergens deteriorates in a short time and tends to lose its potential to elicit positive patch test reactions.[11] However, paraphenylene diamine, formaldehyde resin, paraben mix, benzocaine, epoxy resin, rubber allergens are nonvolatile allergens and remain relatively stable retaining their allergenic potential when stored well.[12]

Limitations

The small number of patients in each group remains the major limitation of the study. Sequential patch testing for true sensitivity reaction was not performed in patient with angry back phenomenon. We did not read results for late reactions. Whether or not these results can be extrapolated with patch test results from other similar patch test kits available across countries also needs confirmation.

Table 3: Group-3 patch test results with Indian standard patch test series with expiry in 2014 versus 2018

Case number	Age in years/ sex	Occupation	Sites of dermatitis	Clinical diagnosis	Duration	Patch test results (grades) ISPTS kit 2014*	Patch test results (grades) ISPTS kit 2018*
1	73/male	Agriculture	Dorsal hands and feet, forearms (extensors)	Acral dermatitis	1 year	**Chlorocresol (1+)**	**Chlorocresol (1+)**
2	65/male	Agriculture	Face and V-area-neck	CAD	10 years	**Parthenium (3+u),** 2MBT (1+), colophony (1+) andneomycin (1+)	**Parthenium (3+)**
3	29/female	Homemaker/teacher	Face and dorsal hands	Acrofacial dermatitis	1 year	**All negative**	**All negative**
4	45/male	Agriculture	Face and thighs	Acrofacial dermatitis	6 months	**PPD (2+)**	**PPD (2+)** andcobalt sulfate (1+)
5	54/malea	Agriculture	Face, neck and upper limb extensors	CAD	10 year	**Angry back phenomenon**	**Angry back phenomenon**
6	55/maleb	Agriculture	Scalp, face, V-area-neck and dorsal hands/feet	CAD (cause hair color)	1 year	**All negative**	**All negative**
7	62/male	Self- employed	Face, neck and upper back	CAD	1 year	**PPD (1+) and** fragrance mix (1+)	**PPD (1+)**
8	43/female	Home maker/ agriculture	Face, V area-neck, upper back and forearms (extensors)	CAD (cause hair color)	5 years	**PPD (2+)**	**PPD (2+)**
9	37/male	Mason/agriculture	Face and neck	ABCD	3 years	**All negative**	**All negative**
10	47/male	Agriculture	Face, neck and dorsal hands	CAD	6 years	**Parthenium (3+), *Myroxylon pereirae* (2+), pot. dichromate (1+), paraben mix (1+), fragrance mix (2+), thiuram mix (1+)**, nickel sulfate (1+), cobalt sulfate (1+) andwool alcohol (1+)	**Parthenium (3+), *Myroxylon pereirae* (1+), pot. dichromate (1+), paraben mix (1+), fragrance mix (2+), thiuram mix (3+),** epoxy resin (1+), formaldehyde (1+), nitrofurazone (1+) and PPD (1+)

Positive results shown in bold indicate allergens common to both kits. "3+ u" indicates intense positive reaction with ulceration. *All positive results were of definite clinical relevance, [a]Developed angry back phenomenon, [b]Showed positive patch test results from his own hair color. Baseline characteristics: Males: Females 8:2; Age: 29-73 (mean 51.0) years; Duration of dermatitis: 6 months-10 (mean 3.85) years; Clinical patterns of dermatitis: ABCD in one patient, CAD in six patients, acrofacial dermatitis in two patients and acral dermatitis in one patient. ISPTS: Indian standard patch test series, MBT: mercaptobenzothiazole, PPD: paraphenylene diamine

Table 4: Summary of positive patch test results in the three groups (*n*=10)

Patch test allergen	Concentration used of patch test allergen	Number of patients with positive results (Group-1)		Number of patients with positive results (Group-2)		Number of patients with positive results (Group-3)	
		Year of expiry					
		2016	2018	2015	2018	2014	2018
Vaseline	100% petrolatum	0	0	0	0	0	0
Wool alcohols	30.0% petrolatum	0	1	1	1	1	0
Myroxylon pereirae (Balsam of Peru)	25.0% petrolatum	1	3	0	0	1	1
Formaldehyde	1.0% petrolatum	2	1	1	2	0	1
MBT	2.0% petrolatum	1	1	1	1	1	0
Potassium dichromate	0.5% petrolatum	0	0	1	1	1	1
Nickel sulphate	5.0% petrolatum	0	0	0	0	1	0
Cobalt sulphate	1.0% petrolatum	1	0	0	0	1	1
Colophony	20.0% petrolatum	4	4	0	1	1	0
Epoxy resin	1.0% petrolatum	0	1	1	1	0	1
Paraben	15.0% petrolatum	1	1	0	1	1	1
PPD	1.0% petrolatum	2	2	1	1	3	4
Parthenium	1.0% aqueous	9	9	6	6	2	2
Neomycin sulphate	20.0% petrolatum	1	0	1	1	1	0
Benzocaine	5.0% petrolatum	2	1	2	0	0	0
Chlorocresol	1.0% petrolatum	2	1	0	2	1	1
Fragrance mix	8.0% petrolatum	3	3	3	3	2	1
Thiuram mix	1.0% petrolatum	3	3	3	1	1	1
Nitrofurazone	1.0% petrolatum	3	2	2	1	0	1
Black rubber mix	0.6% petrolatum	2	2	1	0	0	0
Total positive patch test results*		37	35	24	23	18	16

*Preexisting sensitivity for a particular allergen is required to elicit positive patch test reaction in a given patient; hence, the positive results in two patients will be different despite a common baseline series used. Each study groups had three different sets of patients; thus, intragroup and not intergroup comparison will give actual results which cannot be similar and statistically comparable in terms of number and nature of allergen and how strong reaction an allergen will elicit. MBT: mercaptobenzotiazole, PPD: paraphenylenediamine

Conclusion

Our observations reflect that most of the common patch test allergens including parthenium (aq) remain stable for long periods and a well stored Indian standard patch test kit can be used reliably even beyond the labeled expiry date, saving scarce economic resources. Since the safety of such kits may be a concern and relevance of patch test results from individual allergens in such a scenario perhaps remains questionable and requires careful interpretation, a few large studies are highly desirable before making any recommendations.

Acknowledgements

The authors sincerely thank Systopic India Ltd., New Delhi (India) for providing patch test kits with an expiry date. The authors also thank their patients/subjects who volunteered for the study.

Declaration of patient consent

The authors certify that they have obtained all appropriate patient consent.

Financial support and sponsorship

Nil.

Conflicts of interest

There are no conflicts of interest.

References

1. Johansen JD, Aalto-Korte K, Agner T, Andersen KE, Bircher A, Bruze M, *et al*. European Society of Contact Dermatitis guideline for diagnostic patch testing-recommendations on best practice. Contact Dermatitis 2015;73:195-221.
2. Jindal N, Sharma NL, Mahajan VK, Shanker V, Tegta GR, Verma GK. Evaluation of photopatch test allergens for Indian patients of photodermatitis: Preliminary results. Indian J Dermatol Venereol Leprol 2011;77:148-55.
3. Bajaj AK, Saraswat A, Mukhija G, Rastogi S, Yadav S. Patch testing experience with 1000 patients. Indian J Dermatol Venereol Leprol 2007;73:313-8.
4. Jindal R, Sharma NL, Mahajan VK, Tegta GR. Contact sensitization in venous eczema: Preliminary results of patch testing with Indian standard series and topical medicaments. Indian J Dermatol Venereol Leprol 2009;75:136-41.
5. Ahamed Shariff VN, Deepa K, Balamurugan L, Nirmala S. A study on incidence of various allergens involved in allergic contact dermatitis by patch testing among 150 patients in a tertiary care hospital in South India. Int J Res Dermatol 2018;4:205-10.
6. Sharma V, Mahajan VK, Mehta KS, Chauhan PS. Occupational contact dermatitis among construction workers: Results of a pilot study. Indian J Dermatol Venereol Leprol 2014;80:159-61.
7. Handa S, Jindal R. Patch test results from a contact dermatitis clinic in North India. Indian J Dermatol Venereol Leprol 2011;77:194-6.
8. Mose KF, Andersen KE, Christensen LP. Stability of selected volatile contact allergens in different patch test chambers under different storage conditions. Contact Dermatitis 2012;66:172-9.
9. Mowitz M, Zimerson E, Svedman C, Bruze M. Stability of fragrance patch test preparations applied in test chambers. Br J Dermatol 2012;167:822-7.
10. Goon AT, Bruze M, Zimerson E, Sörensen Ö, Goh CL, Koh DS, *et al*. Variation in allergen content over time of acrylates/methacrylates in patch test preparations. Br J Dermatol 2011;164:116-24.
11. Mahajan VK, Sharma V, Gupta M, Chauhan PS, Mehta KS, Garg S. Parthenium dermatitis: Is parthenolide an effective choice for patch testing? Contact Dermatitis 2014;70:340-3.
12. Jou PC, Siegel PD, Warshaw EM. Vapor pressure and predicted stability of American Contact Dermatitis Society Core Allergens. Dermatitis 2016;27:193-201.