The Journal of Emergency Medicine, Vol. ■, No. ■, pp. 1–4, 2019
© 2019 Elsevier Inc. All rights reserved.
0736-4679/$ - see front matter

https://doi.org/10.1016/j.jemermed.2019.03.026

Clinical Communications: Adult

ACUTE ST-SEGMENT ELEVATION MYOCARDIAL INFARCTION FOLLOWING INTRAMUSCULAR DICLOFENAC: A CASE OF KOUNIS SYNDROME

Fahad Rajh, MD,* Rawia Raja, MD,† Fares Rajah, MD,‡ and Abdulaziz AlAli, MD§

*Department of Emergency Medicine, King Faisal Specialist Hospital and Research Center, Riyadh, Saudi Arabia, †College of Medicine, Alfaisal University, Riyadh, Saudi Arabia, ‡Department of Medicine, King Abdulaziz Medical City–Riyadh, Riyadh, Saudi Arabia, and §Department of Emergency Medicine, King Faisal Specialist Hospital & Research Center, Riyadh, Saudi Arabia

Reprint Address: Fahad Rajh, MD, Department of Emergency Medicine, King Faisal Specialist Hospital and Research Center, PO Box 3354, Riyadh, 11211, Saudi Arabia

☐ **Abstract—Background: Kounis syndrome (allergic myocardial infarction) is the rare occurrence of systemic anaphylaxis with spontaneous electrocardiographic changes in response to an exogenous agent. Often the syndrome is caused by a drug reaction involving drugs such as non-steroidal anti-inflammatory drugs, antibiotics, or opioids. There are a few reported cases in the literature regarding diclofenac-induced Kounis syndrome, and little is known about the management of this clinical entity. Case Report: A case of Kounis syndrome with ST-elevation myocardial infarction secondary to intramuscular (i.m.) diclofenac in a patient with prior coronary artery bypass graft surgery is described in this report. Additionally, we discuss the pathophysiology, clinical presentation, and management of this rare clinical entity. Why Should an Emergency Physician Be Aware of This?: As i.m. diclofenac is a commonly used drug in the emergency department, we urge emergency physicians to be aware of the existence of this potentially fatal diclofenac-related adverse drug effect. If Kounis syndrome is suspected, the emergency physician is advised to balance the benefit of epinephrine for the treatment of anaphylaxis with the small theoretical risk of increasing coronary vasospasm.** **© 2019 Elsevier Inc. All rights reserved.**

☐ **Keywords—Kounis syndrome; diclofenac; ST-elevation; allergic myocardial infarction; coronary artery bypass graft**

INTRODUCTION

Intramuscular (i.m.) diclofenac is a nonsteroidal anti-inflammatory drug (NSAID) that is widely used to relieve severe pain of several etiologies ranging from renal colic to fractures (1). Intramuscular diclofenac is associated with a variety of local and systemic adverse effects, including allergic reactions, and can also cause anaphylaxis.

The use of diclofenac in patients with or without known cardiovascular disease has been shown to increase the risk for thrombotic cardiovascular events (1). However, immediate myocardial infarction has only been seen rarely with the use of diclofenac and involved systemic allergic reaction or anaphylaxis to the drug. This phenomenon—allergic myocardial infarction—is known as Kounis syndrome.

Here we report a case of Kounis syndrome with ST-elevation myocardial infarction (STEMI) secondary to i.m. diclofenac in a patient with earlier coronary artery bypass graft surgery.

CASE REPORT

About an hour before his arrival at the emergency department, a 69-year-old man was experiencing shoulder pain and had reported to a local clinic. He was told that he had

RECEIVED: 29 July 2018; FINAL SUBMISSION RECEIVED: 2 March 2019;
ACCEPTED: 16 March 2019

osteoarthritis and, therefore, was administered an i.m. diclofenac injection for pain relief. Ten minutes after receiving the injection, he began experiencing sudden-onset acute shortness of breath and was unable to speak in complete sentences. This was also accompanied by wheezing. Having noticed these symptoms, his son decided to bring him to our emergency department. The patient stated that this was similar to an aspirin-induced asthma attack he had 20 years ago, during which he was intubated and required admission to the intensive care unit. His bronchial asthma is otherwise stable on medications (albuterol and Symbicort, as needed). The patient's presentation was not associated with any chest pain, palpitations, facial swelling, erythema, itching, or skin rash. There was also a negative history of a cough or sputum production. He had not experienced any headaches, loss of consciousness, dizziness, or blurred vision. The patient denied having recent fevers, night sweats, or weight loss. The patient also denied contact with sick people and had not traveled anywhere recently. His medical history was significant for type 2 diabetes, bronchial asthma, hypertension, gastroesophageal reflux disease, and coronary artery disease. He underwent coronary artery bypass graft surgery for three-vessel disease 6 years prior to presentation, with no complications.

On examination, the patient was an overweight tachypneic man in acute respiratory distress; he was oriented to time, place, and person. His respiratory rate was 32 breaths/min, heart rate 81 beats/min, blood pressure 167/67 mm Hg, temperature 36.1°C, and O_2 saturation 93%. Respiratory examination showed decreased air entry bilaterally with inspiratory and expiratory wheezes. Cardiovascular examination was unremarkable, with normal S1 and S2. The electrocardiography (ECG) showed new ST-segment elevations in inferior leads (Figure 1). The ECG was compared to a previous ECG done on a routine clinic visit 6 weeks prior to presentation (Figure 2). Complete blood count showed an elevated white blood cell count of 22,300/μL blood. Blood chemistry was unremarkable other than mildly elevated serum phosphate. Cardiac enzymes showed an elevated creatine kinase level of 370 U/L, but normal troponin T and pro-brain natriuretic peptide.

An initial diagnosis of STEMI and NSAID-induced asthma was made. Based on this, the patient was administered albuterol and ipratropium nebulization, as well as i.v. methylprednisolone and magnesium sulfate, after which he improved moderately. The patient was then immediately sent for coronary angiography. The coronary angiogram did not show new occlusions and confirmed the patient's pre-existing three-vessel disease (100% occluded left anterior descending artery, 20–30% of the left coronary artery, and 70% of the right coronary artery). The graft study demonstrated patency through the left internal mammary artery to the left anterior ascending artery and saphenous vein graft to diagonal arteries. The patient was discharged in a stable condition after a day of observation. He was doing well on subsequent follow-up visits, including his last appointment, which was 8 months after this presentation.

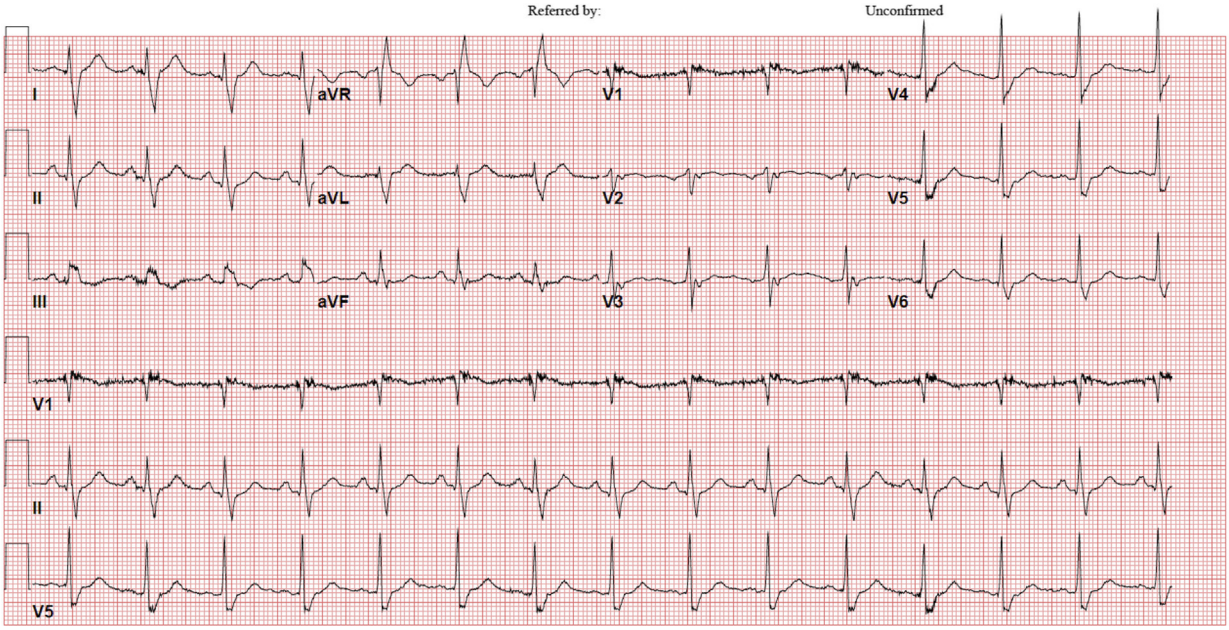

Figure 1. Electrocardiogram upon patient arrival to the emergency department showed ST-elevations in leads III and aVF; with changes in leads V4, V5, V6, I, and II. Source: Emergency Department, King Faisal Specialist Hospital and Research Center.

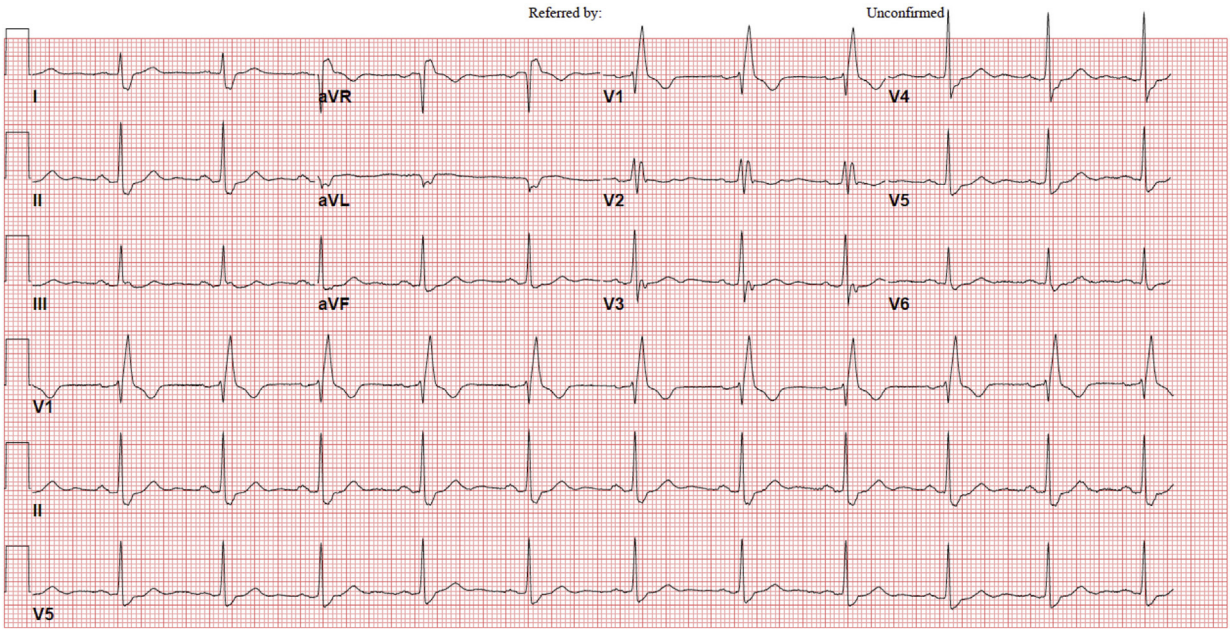

Figure 2. Previous electrocardiogram of the patient done 6 weeks prior to presentation. Source: Emergency Department, King Faisal Specialist Hospital and Research Center.

DISCUSSION

Kounis syndrome was first identified in 1991 and described by Kounis and Zavras as "the coincidental occurrence of chest pain and allergic reactions accompanied by clinical, laboratory, and electrocardiographic findings of acute myocardial ischemia" (2). Kounis syndrome is a rare complication of drug-induced anaphylaxis and is widely accepted to be an Immunoglobulin-E–mediated constriction of major vessels, particularly the coronary arteries. Three different types of Kounis syndrome have been recognized: type I (acute constriction in otherwise normal coronary arteries), type II (mediator-induced atheroma formation), and type III (drug-eluting stent thrombosis). All of these mechanisms can result in ST elevations on ECG. Gormel et al. suggest that as elevated serum histamine and tryptase levels might indicate an allergic reaction, these tests could suggest the diagnosis of Kounis syndrome (3).

Kounis syndrome secondary to diclofenac is rarely seen. Contrary to our case, patients typically present with signs and symptoms of anaphylactic shock, such as hypotension and widespread urticarial lesions shortly after administration of tramadol, with some patients experiencing chest pains (4,5). ECG then reveals ST elevation.

In 2009, Groot et al. published a case report in which a middle-aged man experienced an acute STEMI associated with diclofenac-induced anaphylaxis (6). The patient's coronary angiography was negative. The patient was treated using i.v. adrenaline and clemastine. Alongside the statement "NSAIDs are the second most commonly implicated medications causing anaphylaxis," the report concluded that early treatment with antihistamines, adrenaline, and anticholinergic must begin, in addition to coronary intervention for a desirable clinical outcome (6).

A second case published by Gunes et al. in 2017 reported yet another association between diclofenac potassium and acute anaphylactic STEMI (5). Despite a presentation strikingly similar to that of the patient reported by Groot et al., this patient's coronary angiography showed significant coronary artery occlusion (6). Other than balloon angioplasty, no other intervention was offered in this patient, and the patient was discharged; he was doing well at the follow-up visit 2 weeks later. The report concluded that prompt recognition and diagnosis are keys to diverting the clinician to an appropriate management plan, while simultaneously improving coronary circulation (5).

As the use of i.m. epinephrine in Kounis syndrome is controversial, management of anaphylaxis can be challenging. Administration of i.m. epinephrine can increase the risk of coronary vasospasm and worsen myocardial ischemia (7). Furthermore, Tummala et al. reported a case in which i.m. epinephrine administered for systemic anaphylaxis induced an ST-segment elevation myocardial infarction in the patient (8). However, the current evidence is insufficient to dissuade the use of epinephrine to treat anaphylaxis, including in the setting of Kounis syndrome.

Should acute coronary syndrome progress, it has been proposed that treatment with β-blockers should be avoided in the management of Kounis syndrome because of the risk of exacerbating coronary spasm by unopposed α-adrenergic activity (9).

WHY SHOULD AN EMERGENCY PHYSICIAN BE AWARE OF THIS?

Given that i.m. diclofenac is a commonly used drug in the emergency department, we urge emergency physicians to be aware that this potentially fatal reaction can occur shortly after administration. Diagnosis is largely made based on the clinical history and the sequence of events (ie, linking the time of exposure to the allergen, clinical symptoms, and findings on ECG and coronary angiogram). If Kounis syndrome is suspected, the emergency physician is advised to balance the benefit of epinephrine for the treatment of anaphylaxis with the small theoretical risk of increasing coronary vasospasm.

REFERENCES

1. Bally M, Beauchamp M-E, Abrahamowicz M, Nadeau L, Brophy JM. Risk of acute myocardial infarction with real-world NSAIDs depends on dose and timing of exposure. Pharmacoepidemiol Drug Saf 2017;27:69–77.
2. Kounis NG, Zavras GM. Histamine-induced coronary artery spasm: the concept of allergic angina. Br J Clin Pract 1991;45:121–8.
3. Gormel S, Ege T, Koklu M, Celik M, Yuksel UC. Acute lateral myocardial infarction secondary to tramadol-induced Kounis syndrome. J Cardiothorac Vasc Anesth 2015;29:1599–602.
4. Akboğa MK, Canpolat U, Akyel A, Aras D, Aydoğdu S. PP-062 Acute coronary syndrome due to diclofenac-induced anaphylaxis: type 1 Kounis syndrome. Am J Cardiol 2015;115:S125.
5. Gunes H, Turan F, Saritas A, Koksal Y. Kounis syndrome induced by oral intake of diclofenac potassium. Iran J Allergy Asthma Immunol 2017;16:565–8.
6. Groot JWBD, Gosselink ATM, Ottervanger JP. Acute ST-segment elevation myocardial infarction associated with diclofenac-induced anaphylaxis: case report. Am J Crit Care 2009;18:388. 386–387.
7. Fassio F, Losappio L, Antolin-Amerigo D, et al. Kounis syndrome: a concise review with focus on management. Eur J Intern Med 2016; 30:7–10.
8. Tummala K, Maniyal VK, Chandrashekaran R, Mathew N, Ganeshwala G. Cardiac anaphylaxis: a case of acute ST-segment elevation myocardial infarction after IM epinephrine for anaphylactic shock. Am J Emerg Med 2013;31:1157. e1–e3.
9. Kounis NG. Coronary hypersensitivity disorder: the Kounis syndrome. Clin Ther 2013;35:563–71.