ILLUSTRATIVE CASES OF CONTACT DERMATITIS

E. W. NETHERTON, M. D.

Contact dermatitis is a term used to designate the inflammatory reaction which occurs in the skin of individuals following contact with substances to which they are sensitive. The types of agents which may produce a contact dermatitis vary greatly, are innumerable, and are distinguished from common irritants in that most individuals are not affected by single or repeated contacts with them. The medical literature is replete with articles which list the various agents capable of producing a dermatitis and each year new items are added. With the development of industry, the hazard from contact with chemicals has greatly increased the incidence of occupational dermatoses. Likewise, the almost universal use of cosmetics is responsible for a large number of cases of contact dermatitis involving the face, neck, and upper portions of the trunk. Weber[1] has recently published a complete list of the irritants known to produce a dermatitis in susceptible individuals and his article is well worth the attention of anyone interested in this subject.

Since contact dermatitis is one of the most common of dermatological conditions, it would seem that a brief discussion of a few cases would be of interest.

Case 1: A married woman, 32 years of age, came to the Clinic because of an eruption in the axillae; this had been present for the preceding two months. Roentgen therapy and various topical applications had produced temporary relief, but she had continued to have recurrences and exacerbations of the eruption. The inflamed skin was so tender that she was unable to dress comfortably. Itching was also a troublesome symptom.

The past history, physical examination, and laboratory findings were unimportant. The eruption was symmetrical and limited to the axillae and adjacent skin (Fig. 1). Each axilla was surrounded by a fairly well demarcated, subacute, erythematous, vesicular, crusted dermatitis. The skin in the axillae was erythematous and crusted only in a few small areas. Each axillary region was involved by a large inflammatory plaque. The more inflammatory, vesicular, crusted periphery involved the anterior and posterior axillary folds, the under surfaces of the arms, and the subaxillary skin. The vesicles at the periphery of the plaques were large, superficial, and ruptured easily. The crusts which formed at the site of the ruptured vesicles were fairly adherent and were surrounded by erythematous, bullous areolae; consequently the surface epithelium could easily be removed well beyond the margins of the crust. Many of the individual lesions were impetiginous in type. The feet and groins were free from signs suggestive of an epidermophyton infection and fungi were not observed in material removed from the periphery of the dermatitis.

The patient had been troubled with hyperhidrosis of the axillae for several years. She denied using deodorants and astringents but had worn dress shields to protect her clothing. Patch tests were done with material from a shield

Downloaded from www.ccjm.org on June 6, 2013. For personal use only. All other uses require permission.

which she had worn to the Clinic. The results of the test were negative. Since this shield was old and had been washed several times, it was thought advisable to apply tests with material from a new shield.

The type of shield which she wore was, according to the manufacturer, made from pure Ceylon rubber compounded with insoluble pigments. The shield

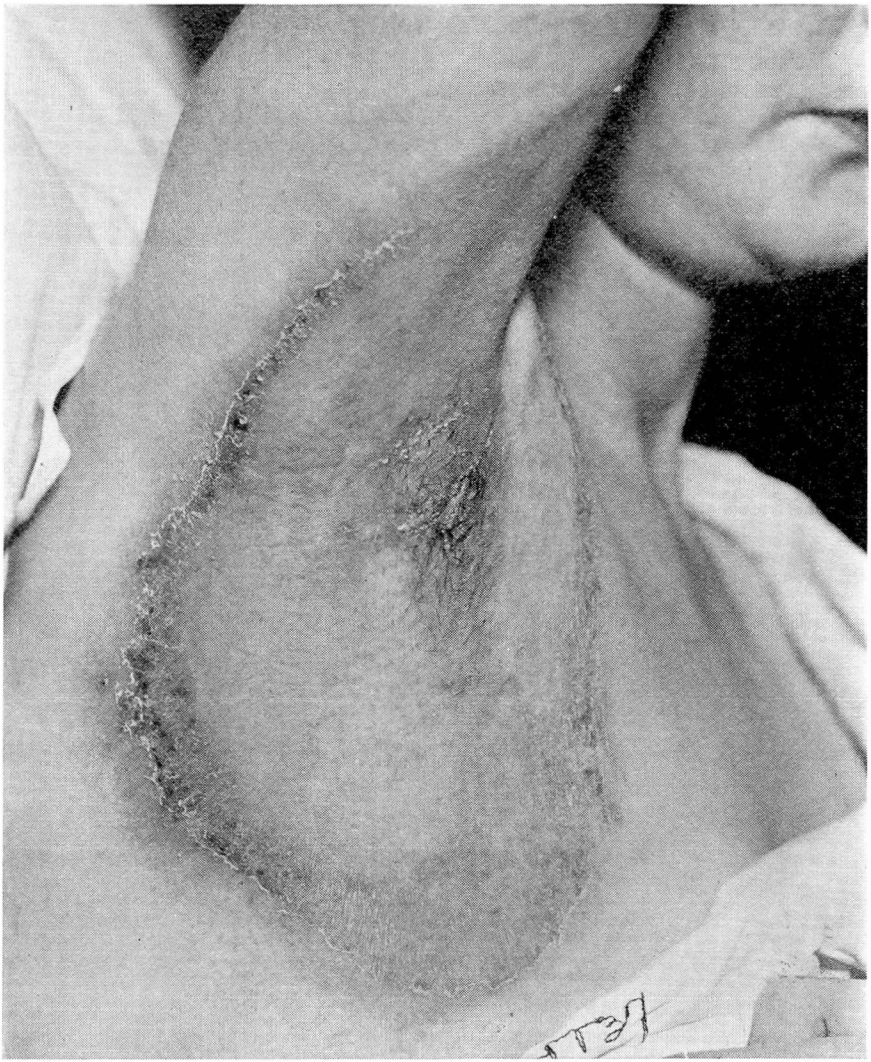

FIGURE 1: Photograph showing eruption limited to axilla and adjacent skin (Case 1).

gum was surfaced with pure cotton flock. Both the rubber sheet and the cloth covering of the new shield were used for patch tests. Each material produced a marked eczematoid dermatitis (Fig. 2). Apparently the noxious substances could be removed by washing the shield with soap and water.

The eruption responded well following the application of a bland boric and zinc oxide ointment. The patient was advised to either change to another

Downloaded from www.ccjm.org on June 6, 2013. For personal use only. All other uses require permission.

type of dress shield or to wash the new shields before wearing them. This patient lived out of the city and we were unable to make more detailed investigations. She promised to report if a recurrence developed, and since

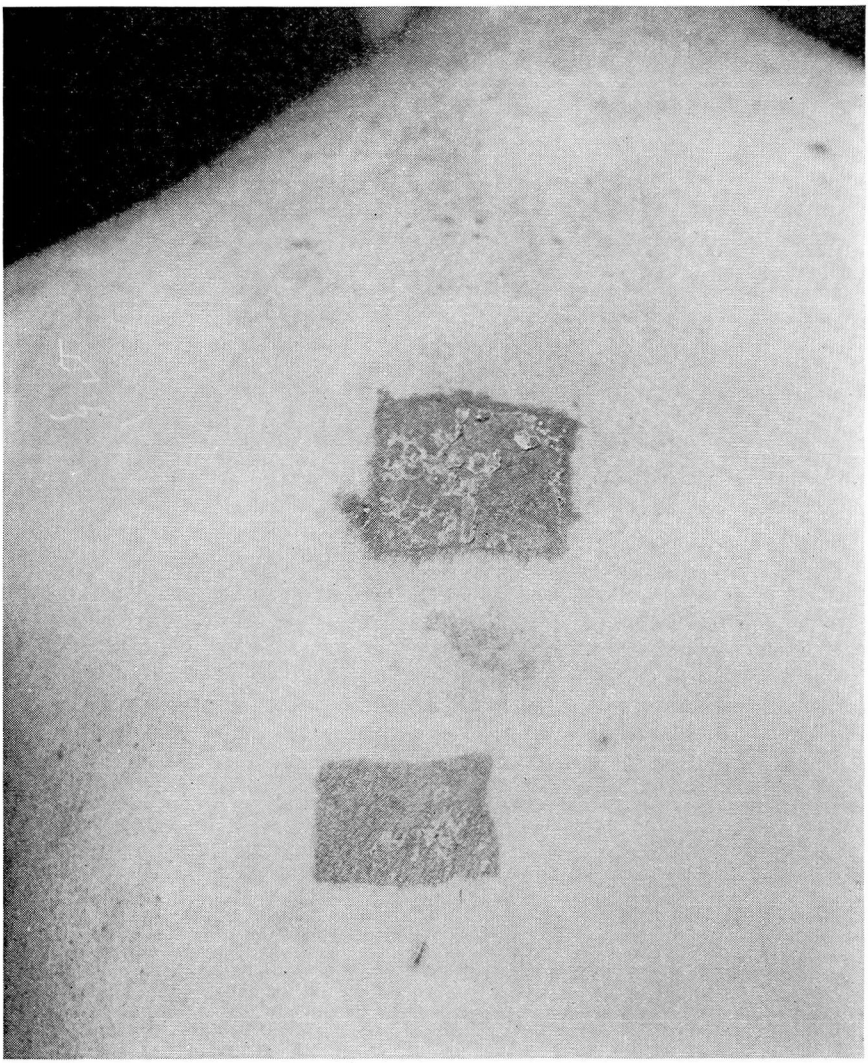

FIGURE 2: Marked eczematoid dermatitis produced by patch tests using rubber sheet and cloth covering from dress shield. Upper—rubber from shield. Lower—cloth from shield. Photograph taken five days after test patch was removed.

she has not been seen for more than five months, we assume that she has remained well.

Comment: This case should probably be classified as one of rubber sensitization. The well-defined inflammatory margins and the more or less clearing of the central portions of the areas of dermatitis readily

Downloaded from www.ccjm.org on June 6, 2013. For personal use only. All other uses require permission.

suggest the possibility of a ringworm infection, particularly since the axillae were involved. However, the impetiginous crusting and the large vesicles are not ordinarily seen in uncomplicated cases of ringworm infection of the axilla. The absence of lesions on the feet or in the groins and finally the failure to demonstrate fungi in the material from the lesions are points against the diagnosis of a fungous infection.

The more inflammatory reaction at the margins of the lesion was probably due to the concentration of the irritant at the periphery of the shield. The irritant which can be removed from the shield with soap and water is also soluble in perspiration and is carried in solution to the circumference of the shield by the force of gravitation.

The absence of impetiginous lesions beyond the periphery of the areas of dermatitis or elsewhere on the body is against the diagnosis of an impetiginous dermatitis.

Case 2: A married woman, 66 years of age, came to the Clinic on June 26, 1937. Except for discomfort due to an old fracture of the coccyx, her health had previously been good. She usually perspired freely during the warm summer months. On May 26, 1937, a red, itchy spot developed in the left axilla. This lesion continued to enlarge and in a few days a similar lesion appeared in the right axilla. The eruption continued to spread and soon involved the neck, chest, back, and posterior surface of the thighs. She had obtained some relief following the use of a lotion and powder which had been advised by her physician; however, with the advent of warm weather the eruption and itching had become much worse. Her symptoms were aggravated when she perspired.

There was a subacute, eczematoid dermatitis involving the axillae, neck, chest, back, the under surface of each arm, and the posterior surface of the thighs. The portions of the trunk which were covered by her girdle and brassiere were not involved. The eruption encircled the chest at the level of the axillae. The lower portion of the eruption was fairly well demarcated at the upper margin of the brassiere. In addition, there was a small band of dermatitis on the areas covered by the shoulder straps of the slip. The inflammatory reaction was more intense in the axillae, on the posterior surface of the thighs, and on the back, this being due to the hyperhidrosis and the close contact of the skin with the clothing in these areas (Figs. 3, 4, 5, and 6). In these areas, there was vesiculation, weeping, and crusting.

It seemed apparent that the dermatitis in this case was probably caused by the dye in the patient's clothing. A blue slip which she was wearing was the only new garment she had purchased for several months. She was also wearing a blue dress which she had had for several months. The dye of the slip faded while that of the dress remained fixed. A diagnosis of dermatitis venenata due to dye in the slip was made.

The following patch tests were applied:

1. Axillary portion of slip
2. Hem of slip
3. Axillary portion of dress
4. Hem of dress

Downloaded from www.ccjm.org on June 6, 2013. For personal use only. All other uses require permission.

The material from the dress gave a negative reaction while that from the slip produced edema, erythema, and vesiculation.

The eruption subsided rapidly after the slip was discarded. A bland ointment consisting of one per cent phenol and equal parts of boric acid and zinc oxide was advised.

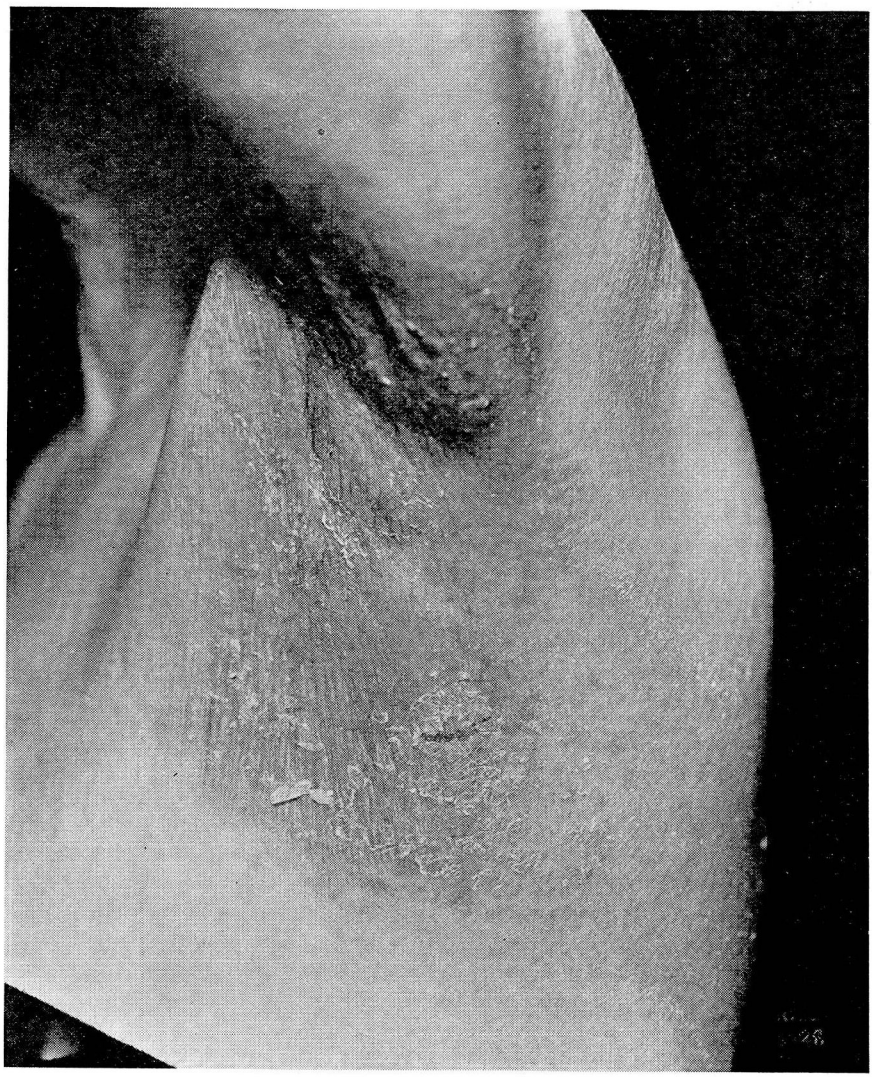

FIGURE 3: Eczematoid dermatitis involving the axilla (Case 2).

Comment: The characteristics of the eruption in this case were so striking that there could be little doubt that the dye of a garment was the causative irritant. Hyperhidrosis is considered to be a predisposing cause of this type of dermatitis and this is well illustrated by this case.

Downloaded from www.ccjm.org on June 6, 2013. For personal use only. All other uses require permission.

Case 3: A married woman, 20 years of age, came to the Clinic on May 25, 1937, complaining of an eruption about the eyes and in the axillae. In September, 1936, she had a dermatitis on the eyelids which was attributed to the use of cosmetics. After this cleared up, she remained well until March, 1937, when she had a recurrence of the eruption about the eyes. This disap-

FIGURE 4: Eczematoid dermatitis involving posterior surface of the thighs (Case 2).

peared in about three weeks. She then remained free from any eruption until one week before coming to the Clinic. At this time a dermatitis had developed in the axillae, on the chest, and there was a recurrence of the eruption on the face. The only cosmetic which she had used during the preceding three weeks was a lipstick; however, she had been applying "Quest" deodorant powder to the axillae. She had purchased two new navy blue dresses.

Downloaded from www.ccjm.org on June 6, 2013. For personal use only. All other uses require permission.

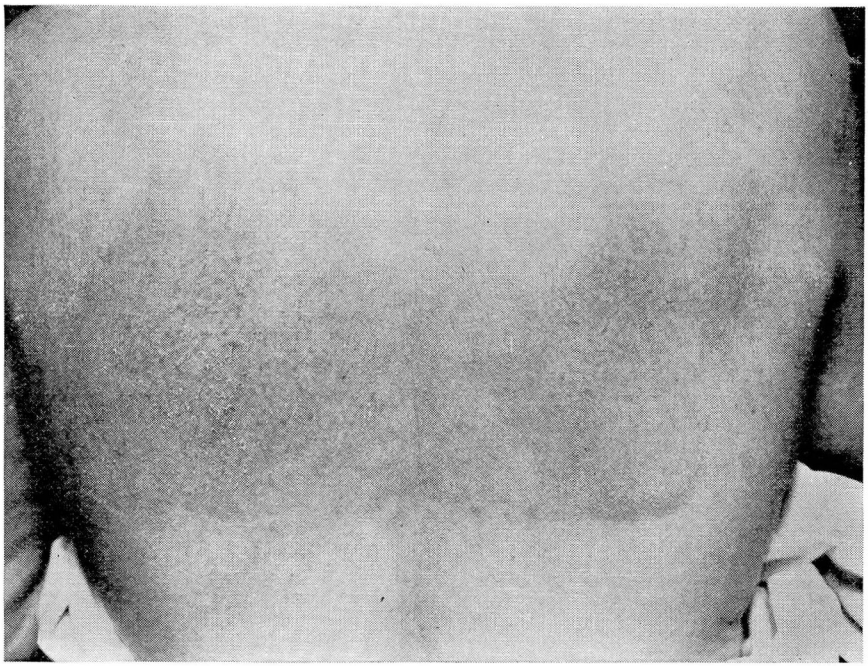

FIGURE 5: Eczematoid dermatitis involving the back (Case 2).

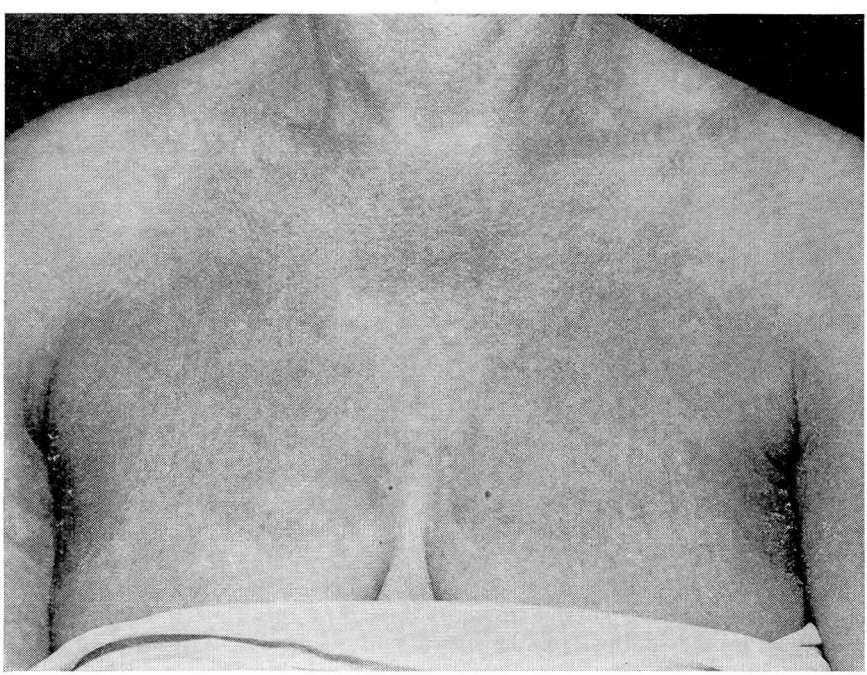

FIGURE 6: Demarcation of dermatitis at upper margin of brassiere and small band of dermatitis in area covered by straps of slip (Case 2).

Downloaded from www.ccjm.org on June 6, 2013. For personal use only. All other uses require permission.

There was a poorly demarcated, subacute, erythematous, scaly dermatitis on the face and about the eyes. The eyelids were edematous. The dermatitis on the chest and in the axillae was more acute and erythematous.

Various substances with which the patient came in contact were used for patch tests. At first the following results were obtained:

Rotogravure paper*	++++	Patient's rouge	+
Material from black dress	+	Scouring powder	—
Material from blue dress	—	"Quest" deodorant	—
Patient's face powder	—	Dust rag	—
Patient's lipstick	+		

The reaction to rotogravure paper was marked (Fig. 7). However, the results of these tests did not satisfactorily explain the presence of the dermatitis on the trunk. The patient was advised to stop wearing the black dress, to avoid rotogravure paper, and to change to a nonallergic brand of cosmetics. Following this, the dermatitis practically disappeared, but five weeks later a recurrence developed on the face, the upper portion of the trunk, and on the hands. This dermatitis was more severe than that experienced in the past. At this time, many small vesicles developed and the site of the previous patch test with rotogravure paper became eczematoid. The afternoon before this recurrence she had worn, for the second time, a new navy blue crepe dress. Otherwise her contacts had not changed. She was asked to bring in all colored dresses for patch testing. Patch tests with two navy blue dresses gave a strongly positive reaction. A black dress produced a slight erythematous dermatitis and a second test with rotogravure paper again produced a severe eczematoid reaction. The dermatitis completely disappeared following the applications of moist packs of an aqueous solution of aluminum acetate (1:20 solution) and calomine liniment. The patient has not returned for further observation.

Comment: This patient had a multiple sensitization and it is probable that other irritants not yet determined may have been factors in the causation of the recurrences of dermatitis. In both this case and the previous one, the dermatitis was due to a blue dye. These cases are similar to the ones reported by Bonnevie and Genner[3] who collected 15 cases of eczema due to dyed clothing. In nine of their cases, a blue dye was shown to be the cause of the dermatitis. They emphasized that hyperhidrosis is a predisposing factor in this type of eczema. These authors observed that eczema, due to dyed garments, frequently became chronic and remained for several months after the noxious clothing had been discarded.

Case 4: A single woman, 25 years of age, came to the Clinic on July 15, 1937. For three months she had had a dry, thickened, scaly plaque limited to the left palm. She had never had a fungous infection on her feet. Three days prior to our first observations, stomatitis and an eruption about the mouth and on the lateral surfaces of the fingers of the right hand developed.

There was a poorly demarcated, brownish red, scaly and slightly thickened plaque in the central portion of the left palm. The scales were dry and adherent. The plaque was not indurated and there were no fissures along

*Oliver[2] has reported dermatitis to rotogravure ink.

Downloaded from www.ccjm.org on June 6, 2013. For personal use only. All other uses require permission.

the normal markings of the palm. On the lateral surfaces of the fingers of the right hand and on the webs between the fingers, there was a more acute erythematous, vesicular dermatitis. The vesicles were small and superficial. The dermatitis about the corners of the mouth was similar to that

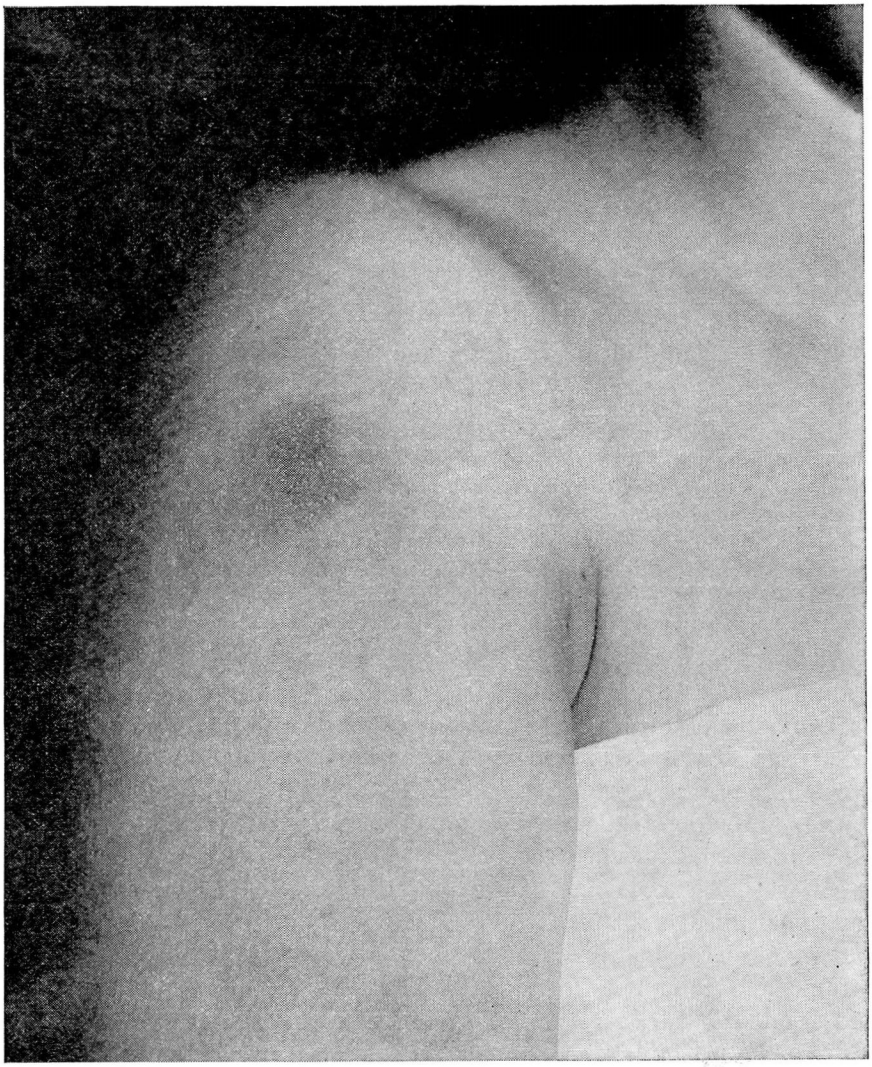

FIGURE 7: Patch test showing marked reaction to rotogravure paper (Case 3).

on the right hand. The gums were acutely inflamed. The presence of an acute dermatitis on the right hand and about the mouth suggested the possibility of a dermatitis venenata while, in the differential diagnosis of the chronic dermatitis of the left palm, the possibility of ringworm infection or a contact dermatitis had to be considered.

The history revealed that three months prior to the appearance of the eruption on the left palm, the patient had changed her dentifrice and during

Downloaded from www.ccjm.org on June 6, 2013. For personal use only. All other uses require permission.

this time she had used a nationally advertised tooth powder (Pepsodent). She had used this dentifrice three months before the lesion appeared in the left palm and about six months before the stomatitis and acute dermatitis about the mouth and on the right hand developed. In using this dentifrice, she placed the powder in the left hand and brushed it up with a wet tooth brush which she held in her right hand. While she was cleansing her teeth, some of the powder and water usually trickled onto the fingers of the right hand.

It was apparent that all the lesions in this case could be caused by this dentifrice. Powder from the container which the patient had used for some time was used for patch testing. The powder produced an erythematous, vesicular dermatitis when it was applied to the flexor surface of the forearm (Fig. 8).

FIGURE 8: Patch test showing marked reaction to tooth powder (Case 4).

The manufacturer of this dentifrice was kind enough to send us samples of the soluble and insoluble ingredients. The patient was tested with each ingredient and all of them failed to produce a dermatitis. We had no explanation for this discrepancy. It seemed that either the manufacturer failed to send samples of all ingredients or that the ingredients in solution were not in the strength used in the manufactured product. It was suggested that a product of a chemical reaction between the ingredients might be the causative irritant. Therefore a paste made by mixing all of the ingredients which were obtained from the manufacturer was applied as a patch test. At the end of 48 hours when the patch was removed, there was a positive but much less intense reaction.

Following this investigation, a new can of this dentifrice was purchased and a second patch test was applied. The test was strongly positive.

The stomatitis and all the cutaneous lesions in this case disappeared when the use of the tooth powder was discontinued.

Comment: It was not difficult to make the diagnosis in this case when the patient first came under observation; however, it is very doubtful

Downloaded from www.ccjm.org on June 6, 2013. For personal use only. All other uses require permission.

whether the correct diagnosis would have been made during the time when the eruption was limited to the left palm.

If the cause of the dermatitis can be determined and eliminated, the results are excellent and the patient is, of course, very grateful. However, this frequently is not obtained as easily as one would expect. In some cases the causative agents may be determined in a comparatively short period while at other times a prolonged search is necessary before all the etiologic factors can be elicited. In some cases the cutaneous reaction has been so severe as to terminate in a generalized exfoliative dermatitis which may not disappear for several weeks after the primary irritant has been removed. Patients suffering from a contact dermatitis of an occupational origin are frequently confronted with the additional problem of changing their occupations. Unfortunately, this can seldom be done easily or without material loss. It is well to remember that the dermatitis due to certain chemicals, particularly dyes, is apt to become chronic and last for weeks after contact with the chemical has been discontinued.

As previously stated, a person with a contact dermatitis is sensitive to the causative irritant. Why some individuals become sensitive to a substance which other individuals tolerate with impunity is unknown. This sensitization is acquired usually after repeated contact with the substance.

The sensitizing properties of agents or allergens vary considerably. It is conceivable that some individuals may develop a sensitization to any chemical. The number of exposures, the interval between the contacts, and the appearance of the dermatitis also vary with different individuals and with different allergens. These important facts must be kept in mind if one is to avoid being influenced by the statements and arguments of the patient. Frequently, patients will insist that a certain substance could not be the cause of the dermatitis because their friends use or come in contact with the same substance without suffering any ill effects, or that they have used a certain preparation, such as a cosmetic for instance, for several weeks or months without trouble.

The successful management of the type of patient under consideration necessitates a careful evaluation of the clinical characteristics of the eruption and an accurate, detailed history. The history is very important and unless the physician can obtain the cooperation of the patient, the solution of some cases becomes extremely difficult.

A dermatitis due to an external irritant is usually limited to or is more marked on the face, neck, hands, and arms or the exposed portions of the body. In instances where the covered portions of the body are involved, the distribution and arrangement of the eruption is such as to

Downloaded from www.ccjm.org on June 6, 2013. For personal use only. All other uses require permission.

suggest the possibility of some external irritant. For example, limitation of the eruption to the skin just beneath the trouser or shirt pocket suggests the possibility of a match dermatitis; limitation of a plaque to the skin of the thigh which comes in contact with the metal supporter of a girdle suggests the possibility of nickel as the irritant. The presence of a symmetrical eruption limited to the feet and legs which are covered by the socks points to the dye of the socks as the causative agent. The dermatitis produced by the varnish on the toilet seat is another familiar type of contact dermatitis which may occur on portions of the body which are usually covered with clothing. Many other examples could be cited but these are sufficient to emphasize the importance of carefully noticing the distribution of an eruption. This is particularly important in patients with contact dermatitis.

The clinical manifestations of dermatitis venenata vary considerably and are not characteristic for any particular type of irritant. The inflammatory reaction may be mild, severe, acute, subacute, or chronic. The eruption is eczematoid in type, consisting of erythema and edema, and accompanied by vesiculation, weeping, scaling, and crusting. In the more chronic type of dermatitis, the papular lesions predominate and the skin may become lichenified. Oftentimes the lesions have a predilection for the follicles of the skin. This is because the irritant can more easily penetrate and become lodged within the cutaneous follicles. The eruption as a rule is poorly demarcated and the intensity of the inflammatory reaction at the periphery of the dermatitis usually fades gradually into the adjacent normal skin. Itching is generally a prominent symptom.

The physician should in most cases be able to determine whether a diagnosis of contact dermatitis is tenable if he has carefully and systematically observed the distribution and characteristics of the eruption. The next and most important procedure is to obtain a careful history. This cannot be accomplished in a few minutes. The physician must have patience and a cooperative patient. The age, sex, social status, and occupation serve as initial leads for the history. The possibility of contacts with substances which are commonplace, with additional information pertaining to contacts relative to the patient's environment and habits, will usually give clues which lead to the ultimate discovery of the causative irritant. Information obtained from the history will suggest certain irritants which may be the cause of the dermatitis. The next step is to test the patient for susceptibility to these irritants. This is done by using the patch test method devised by Jadassohn. The irritant to be tested is applied to a small piece of white linen and applied to the normal skin. This is covered with a piece of cellophane and the patch is held in place with broad pieces of

Downloaded from www.ccjm.org on June 6, 2013. For personal use only. All other uses require permission.

adhesive tape. Preparations such as face powder, cold cream, rouge, etc., are applied unchanged. When testing a suspected chemical such as soap, which under ordinary circumstances does not remain on the patient's skin for any length of time, it is best to start the investigations with weak dilutions of the substance. Control tests should be done on normal individuals when testing for substances which have not been shown to be common irritants. The patch test is held in contact with the normal skin for 24 or preferably 48 hours. At the end of this period, the patches are removed and the degree of inflammatory reaction observed. An eczematoid reaction with erythema, edema, and vesiculation is classified as a four plus reaction. Further details of the technic of the patch test method such as substitutes for adhesive tape in persons sensitive to the adhesive cannot be discussed here. Suffice it to say that the patch test is a comparatively simple procedure which can be used safely by any physician.

References

1. Weber, L. F.: External causes of dermatitis; list of irritants, Arch. Dermat. & Syph., 35:129-179, (January) 1937.
2. Oliver, E. A.: Rotogravure ink dermatitis, J.A.M.A., 91:870-874, (September 22) 1928.
3. Bonnevie, P. and Genner, V.: Eczema due to dyed clothing; report of fifteen cases, Arch. Dermat. & Syph., 34:220-227, (August) 1936.

Downloaded from www.ccjm.org on June 6, 2013. For personal use only. All other uses require permission.