American Journal of Case Reports

Received: 2018.09.21
Accepted: 2018.11.03
Published: 2019.02.13

e-ISSN 1941-5923
© Am J Case Rep, 2019; 20: 189-193
DOI: 10.12659/AJCR.913319

A Case of Eosinophilic Gastroenteritis Associated with Eosinophilic Ascites Diagnosed by Full-Thickness Biopsy of the Small Intestine

Authors' Contribution:
Study Design A
Data Collection B
Statistical Analysis C
Data Interpretation D
Manuscript Preparation E
Literature Search F
Funds Collection G

ABDEF 1 Haneen Thabit Salah
ABDEF 2 Hussa Fahad Al-Hussaini
ABEF 3 Abdullah Mohammed Alqaraawi
BEF 4 Khulud Muhammed Alanazi

1 College of Medicine, AlFaisal University, Riyadh, Saudi Arabia
2 Department of Pathology and Laboratory Medicine, King Faisal Specialist Hospital and Research Center, Riyadh, Saudi Arabia
3 Department of Medicine, King Faisal Specialist Hospital and Research Center, Riyadh, Saudi Arabia
4 College of Medicine, King Saud University, Riyadh, Saudi Arabia

Corresponding Author: Hussa Fahad Al-Hussaini, e-mail: Halhussaini@kfshrc.edu.sa
Conflict of interest: None declared

Patient: Male, 28
Final Diagnosis: Eosinophilic gastroentritis
Symptoms: Abdominal and/or epigastric pain • ascites
Medication: —
Clinical Procedure: Full-thickness biopsy
Specialty: Diagnostics, Laboratory

Objective: Unusual clinical course

Background: Eosinophilic gastroenteritis is a rare disease, characterized by infiltrates of eosinophils in the intestinal mucosa, muscularis propria, and serosa. Eosinophilic gastroenteritis is due to Type 1 hypersensitivity and can be associated with other atopic diseases. The clinical course of eosinophilic gastroenteritis varies depending on the location, extent, and depth of eosinophilic infiltration of the gastrointestinal tract, which can make the diagnosis challenging. A case of eosinophilic gastroenteritis associated with eosinophilic ascites is presented that emphasizes the importance of full-thickness intestinal biopsy, which includes the muscularis propria, to allow the definitive diagnosis to be made.

Case Report: A 28-year-old man presented with vague abdominal pain, nonspecific gastrointestinal symptoms, unintentional weight loss, and progressive ascites during the previous several months. A diagnosis of eosinophilic gastroenteritis was made after the exclusion of other possible causes, which was confirmed by histopathology of a full-thickness intestinal biopsy. The patient was treated with steroids. At one-month follow-up, the patient reported reduced abdominal pain.

Conclusions: A case of eosinophilic gastroenteritis associated with eosinophilic ascites is presented that emphasizes the importance of full-thickness intestinal biopsy, which includes the muscularis propria, to allow the definitive diagnosis to be made.

MeSH Keywords: Ascitic Fluid • Gastroenteritis • Pathological Conditions, Anatomical

Full-text PDF: https://www.amjcaserep.com/abstract/index/idArt/913319

1826 1 4 11

This work is licensed under Creative Common Attribution-NonCommercial-NoDerivatives 4.0 International (CC BY-NC-ND 4.0)

Indexed in: [PMC] [PubMed] [Emerging Sources Citation Index (ESCI)] [Web of Science by Clarivate]

Background

The gastrointestinal tract consists of four layers, the mucosa, the submucosa, the muscularis propria, and the adventitia or serosa. Eosinophilic gastroenteritis is a rare disease that may have a varied presentation and is characterized by eosinophilic infiltration of the gastrointestinal tract that may involve some or all of the layers of these layers [1,2]. Eosinophilic gastroenteritis is characterized histologically by the presence of a dense and diffuse infiltrate of eosinophils of the lamina propria of more than 20 eosinophils per high power field [3]. A recent prospective study of patients presenting with lower abdominal symptoms showed that the prevalence of eosinophilic gastroenteritis was 2.6% [3].

Eosinophilic gastroenteritis is a form of Type 1 hypersensitivity disease that can be associated with other atopic diseases [2]. Personal and family history of food allergy and atopy can be found in up to 50% of cases, with an increased incidence of eosinophilic gastroenteritis in patients with a history of other atopic diseases, including asthma, and allergic rhinitis [2,4]. The clinical presentation of eosinophilic gastroenteritis varies depending on the extent of involvement of the gastrointestinal tract, and the depth of infiltration of the gastrointestinal wall [4]. Klein et al. classified eosinophilic gastroenteritis according to the depth of eosinophilic infiltration into the mucosa, muscularis propria, and serosa [2].

The diagnosis of eosinophilic gastroenteritis requires a high index of suspicion, as it can present with a wide range of symptoms and signs, and can present with no specific findings on clinical history and physical examination [2]. Eosinophilic gastroenteritis can have a variable clinical course. Following steroid treatment, a subset of patients will have no recurrence, while others undergo repeated and long courses of steroidal therapy due to frequent recurrences [4]. There remains no agreement regarding the ideal treatment for eosinophilic gastroenteritis, but systemic steroid therapy remains the standard therapeutic approach [3]. Other treatments for eosinophilic gastroenteritis include mast cell inhibitors, antihistamines, or leukotriene receptor antagonists [4]. Serosal eosinophilic infiltrates are present in 10% of the cases of eosinophilic gastroenteritis, and a hallmark if this subtype is peripheral eosinophilia and ascites [5].

A case of eosinophilic gastroenteritis associated with eosinophilic ascites is presented that emphasizes the importance of full-thickness intestinal biopsy, which includes the muscularis propria, to allow the definitive diagnosis to be made.

Case Report

A 28-year-old man presented with severe epigastric and abdominal pain, nausea, vomiting, diarrhea, loss of appetite, and unintentional weight loss of 32 kg during the previous six months. He had a history of seasonal bronchial asthma. None months previously, he presented with intermittent episodes of epigastric and abdominal pain, nausea, vomiting, and diarrhea, and was diagnosed and treated as a case of *Helicobacter pylori* with an initial improvement of his symptoms.

On this hospital admission, the initial differential diagnosis included inflammatory bowel disease (IBD), gastroenteritis due to nonsteroidal anti-inflammatory drugs (NSAIDs), primary gastrointestinal malignancy, lymphoma, and infectious disease, including tuberculosis (TB). Laboratory investigations included a QuantiFERON test for TB, measurement of fecal calprotectin, Brucella agglutination titer, serology for human immunodeficiency virus (HIV), and measurement of the erythrocyte sedimentation rate (ESR), and C-reactive protein (CRP). All the laboratory tests were normal. The patient underwent computed tomography (CT) enterography, colonoscopy, and esophagogastroduodenoscopy (EGD).

CT enterography showed diffuse edema of the intestinal wall with increased imaging enhancement of the intestinal mucosa with nodularity involving a 20-cm segment in the left upper quadrant of the small bowel, mild ascites, and omental enhancement. EGD showed severe gastritis, hiatal hernia, and polypoid duodenitis.

The patient was treated with a proton pump inhibitor (PPI) for one month with no significant improvement. Colonoscopy was performed that showed external hemorrhoids and a sessile adenomatous polyp. The patient was diagnosed with Crohn's disease, and was discharged from hospital on the anti-inflammatory agent, mesalamine. Two weeks later, the patient reported minimal improvement.

On examination at the most recent hospital admission, his abdomen was distended, with diffuse tenderness that was worse in the epigastric area. Rectal examination showed no external or internal hemorrhoids, anal fissures, skin tags, or fistulas. Paracentesis was performed, and a sample of ascitic fluid was sent for cytological examination. The ascitic fluid was negative for malignant cells, but showed numerous eosinophils mixed with reactive histiocytes (Figure 1). The cytology of the ascites fluid raised the possibility of a diagnosis of eosinophilic gastroenteritis, and full thickness intestinal biopsy was advised for histopathology. The complete blood count (CBC) and differential cell count showed marked peripheral eosinophilia (22.6%).

This work is licensed under Creative Common Attribution-NonCommercial-NoDerivatives 4.0 International (CC BY-NC-ND 4.0)
Indexed in: [PMC] [PubMed] [Emerging Sources Citation Index (ESCI)] [Web of Science by Clarivate]

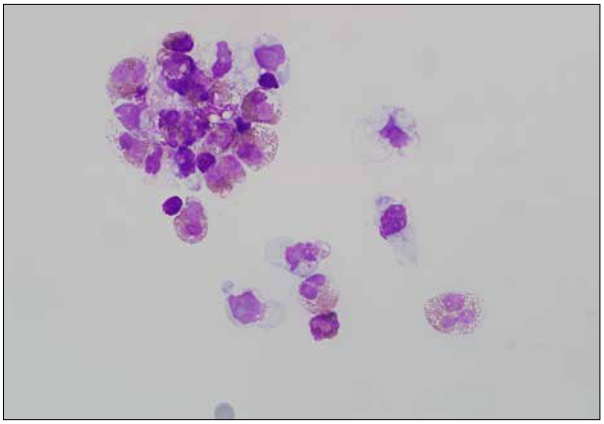

Figure 1. Photomicrograph of the cytology of the ascitic fluid. The ascitic fluid contains abundant eosinophils. Diff-Quick stain. Magnification ×60.

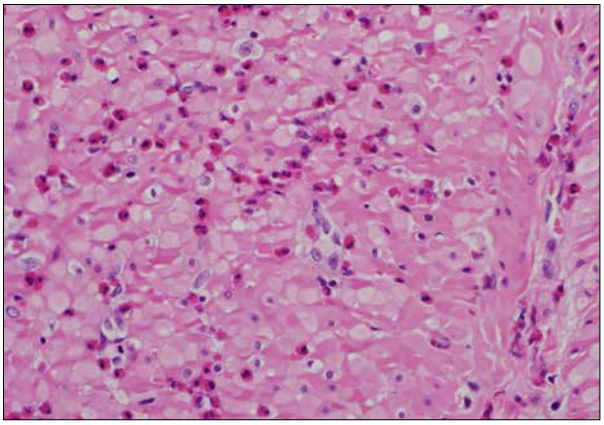

Figure 2. Photomicrograph of the histology of the biopsy of the small intestine. Eosinophils are shown to infiltrate the intestinal muscularis propria. Hematoxylin and eosin (H&E). Magnification ×40.

EGD was planned to obtain the intestinal biopsies. The histology of the initial proximal biopsies showed mild chronic focal gastritis and focal chronic esophagitis. There was minimal and focal eosinophilic cell infiltration in the proximal esophageal biopsies that was not adequate for the diagnosis of eosinophilic gastroenteritis. Because the EGD biopsy results were inconclusive, the patient underwent a diagnostic laparoscopy and full-thickness small bowel Tru-cut needle biopsy that included all layers of the small bowel wall.

Histopathology of the intestinal biopsy showed dense eosinophil cell infiltrates predominantly involving the muscularis propria and serosa and included small foci of eosinophil microabscesses, as shown in Figures 2 and 3. Histopathology also showed that the muscularis propria layer of the small intestine was less involved and showed few scattered eosinophils (Figure 4). On histology, the eosinophil count of the muscularis propria and serosa was >15 eosinophils per high power field.

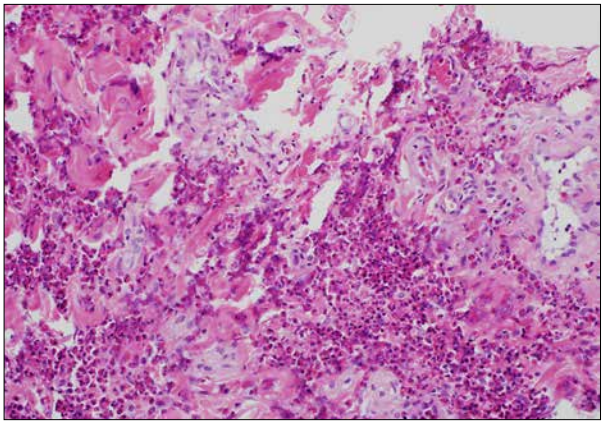

Figure 3. Photomicrograph of the histology of the biopsy of the small intestine. The serosa is heavily infiltrated by eosinophils with the formation of eosinophil microabscesses. Hematoxylin and eosin (H&E). Magnification ×40.

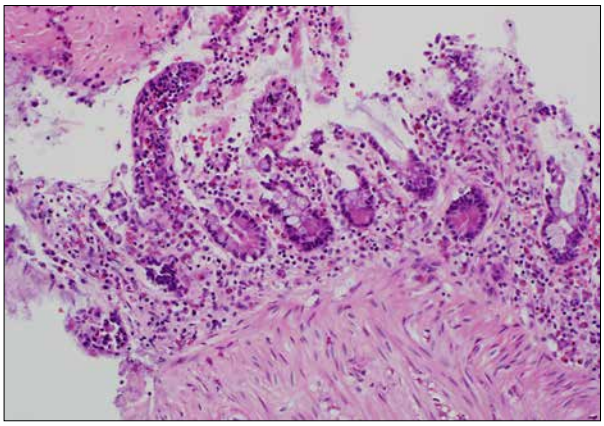

Figure 4. Photomicrograph of the histology of the biopsy of the small intestine. The mucosal surface of the small bowel shows fewer eosinophil infiltrates. Hematoxylin and eosin (H&E). Magnification ×20.

Given that the patient's CBC and differential showed marked peripheral eosinophilia, he underwent a bone marrow biopsy and peripheral blood smear to exclude hematological malignancy and hypereosinophilic syndrome (HES). However, no clonal abnormalities and or features of malignancy or blasts were found. After exclusion of all other possible causes, the diagnosis of eosinophilic gastroenteritis was made. The diagnosis was based on the presence of persistent peripheral eosinophilia (22.6%), eosinophilia on cytology of the ascitic fluid, and eosinophilic infiltration of the muscularis propria and serosal layers of the small intestine on full-thickness biopsy.

The patient was treated with prednisone (40 mg) for three weeks, followed by tapering down of the dose. The patient reported reduced abdominal pain after one month of steroid

This work is licensed under Creative Common Attribution-NonCommercial-NoDerivatives 4.0 International (CC BY-NC-ND 4.0)

Indexed in: [PMC] [PubMed] [Emerging Sources Citation Index (ESCI)] [Web of Science by Clarivate]

Table 1. Klein histological classification of eosinophilic gastroenteritis [10].

Type	Clinical presentation	Pathology
Mucosa	Abdominal pain, nausea, vomiting, diarrhea, hemorrhage, protein-losing enteropathy, anemia, weight loss	Mucosal eosinophils with degranulation, crypt abscesses, and variable villous blunting
Muscularis mucosa	Abdominal pain, obstruction, colicky abdominal pain	Thickened wall, muscularis mucosa and serosal and eosinophilic infiltrates, edema
Serosa	Peritoneal irritation, Abdominal pain, bloating, ascites, peritonitis, perforation, intussusception	Eosinophils and edema limited to serosa, and ascitic fluid with abundant eosinophils

therapy. He was scheduled for immunological follow-up at the allergy clinic to identify a possible associated food allergy.

Discussion

Eosinophilic gastroenteritis is commonly associated with gastrointestinal symptoms and is diagnosed histologically by eosinophil infiltration of the intestinal wall without evidence of extra-intestinal disease [6]. Eosinophilic gastroenteritis is more common in the pediatric population, young adults, and adults between the third and fifth decade of life [7].

The recently reported incidence of eosinophilic gastroenteritis is estimated to be 28 per 100,000 per year, and studies have shown an increased prevalence during the past 16 years [3]. The pathogenesis of eosinophilic gastroenteritis involves a Type 1 hypersensitivity reaction, and many patients will have a history of atopy [8]. The associated allergic disorders, including asthma, allergic rhinitis, and atopic eczema are present in between 54–63% of reported cases of eosinophilic gastroenteritis [7]. Also, immunoglobulin E (IgE) levels are reported to be elevated in patients with eosinophilic gastroenteritis [5]. Elimination of antigen triggers of atopy and treatment with corticosteroids are the mainstay of patient management and lead to improvement in up to 90% of patients [2]. Second-line treatment includes mast cell stabilizers, antihistamines, and leukotriene antagonists [5].

The classification of eosinophilic gastrointestinal disease is based on the histological findings, and is based on the Klein classification, according to the predominance of eosinophils in the layers of the intestinal wall, the mucosa, muscularis propria, and serosa, and results in a wide range of clinical presentations, as summarized in Table 1 [9,10]. Compared with other subtypes, mucosal eosinophilic gastroenteritis is the most common, presenting mainly with nonspecific symptoms that include abdominal pain, nausea, diarrhea, and vomiting, and may mimic other gastrointestinal disorders [5]. More rarely, patients may present with severe with blood in the stool, iron deficiency anemia, or protein-losing enteropathy [5].

The recent increase in the reported incidence of mucosal eosinophilic gastroenteritis may be because it is an easier diagnosis to make by from routine endoscopic biopsy [2]. Eosinophilic gastroenteritis that involves the muscularis propria is the second most commonly reported subtype [5]. Infiltration of eosinophils that mainly involves the muscularis propria causes thickening of the intestinal wall and can present with symptoms of intestinal obstruction [5].

The serosal subtype of eosinophilic gastroenteritis is often associated with peripheral eosinophilia and with eosinophilia of the ascitic fluid in between 45–90% of cases [2,11]. However, eosinophilic ascites is a rare presentation of eosinophilic gastroenteritis and is most commonly seen with the serosal subtype [4]. It has been reported that the serosal subtype has a better response to steroid therapy, without a chronic course [2,4].

The diagnosis of eosinophilic gastroenteritis requires the presence of three main features that include gastrointestinal symptoms, eosinophilia of one or more areas of the gastrointestinal tract on histology, and the exclusion of other causes of tissue eosinophilia, including intestinal tuberculosis, parasitosis, and malignancy [5,7]. Although the clinical history and physical examination are important, the definitive diagnosis of eosinophilic gastroenteritis is made histologically, which requires gastrointestinal biopsy [8]. To confirm the histological diagnosis, at least 15–20 eosinophils per high power microscopic field are required [5]. Endoscopic findings suggestive of eosinophilic gastroenteritis include an erythematous and friable mucosa, pseudopolyps, polyps, and ulcers, but none of these findings is sensitive or specific, and endoscopic biopsies are required to establish the diagnosis [4]. The pathology of eosinophilic gastroenteritis usually follows a patchy distribution, which requires multiple biopsies from normal and abnormal sites during endoscopy [7].

A recently published prospective study showed that 92.9% of patients with eosinophilic gastroenteritis had a normal endoscopic appearance during colonoscopy and if biopsies were taken only from abnormal appearing areas, 92.2% of cases of eosinophilic gastroenteritis would have been missed [3].

This work is licensed under Creative Common Attribution-NonCommercial-NoDerivatives 4.0 International (CC BY-NC-ND 4.0)
Indexed in: [PMC] [PubMed] [Emerging Sources Citation Index (ESCI)] [Web of Science by Clarivate]

The preferred method of obtaining biopsies is during laparoscopy, particularly for muscular and serosal types, which provides an inclusive full-thickness specimen for accurate histopathology diagnosis [7]. According to the clinical guidelines published in 2014 by the Japanese Ministry of Health, Labor and Welfare, negative endoscopic mucosal biopsies cannot exclude the muscularis propria or serosal subtypes of eosinophilic gastroenteritis, and so full-thickness biopsies obtained at laparoscopy are essential to establish the diagnosis [5].

Conclusions

This case report has shown that when there is a clinical suspicion of eosinophilic gastroenteritis, prompt histopathological evaluation of a full thickness biopsy should be performed to prevent treatment delay. In this case, the predominance of eosinophilic infiltrates in the muscularis propria and the serosal layers, and the minimal number of eosinophils found in the mucosa meant that an initial superficial biopsy obtained at endoscopy would be unlikely to make the diagnosis, leading to a delay in the definitive diagnosis. In this case, indicators for histological evaluation of a full-thickness biopsy of the small intestine included the findings of eosinophilia on cytology of the ascitic fluid and peripheral blood eosinophilia.

Department and Institution where work was done

Department of Pathology and Laboratory Medicine, King Faisal Specialist Hospital and Research Center, Riyadh, Saudi Arabia

Conflict of increase

None.

References:

1. Munjal A, Al-Sabban A, Bull-Henry K: Eosinophilic enteritis: A delayed diagnosis. J Investig Med High Impact Case Rep, 2017; 5(4): 2324709617734246
2. Shifflet A, Forouhar F, Wua G: Eosinophilic digestive diseases: Eosinophilic esophagitis, gastroenteritis, and colitis. J Formos Med Assoc, 2009; 108(11): 834–43
3. Hui CK, Hui NK: A Prospective study on the prevalence, extent of disease and outcome of eosinophilic gastroenteritis in patients presenting with lower abdominal symptoms. Gut Liver, 2018; 12(3): 288–96
4. Lourenço LC, Horta DV, Reis J: Eosinophilic ascites: Uncommon presentation of eosinophilic gastroenteritis in a young adult male. GE Port J Gastroenterol, 2017; 24(4): 206–8
5. Santos C, Morgado F, Blanco C et al: Ascites in a young woman: A rare presentation of eosinophilic gastroenteritis. Case Rep Gastrointest Med, 2018; 2018: 1586915
6. Chaudhry R, Singh B, Patnaik PK et al: Eosinophilic gastrenteritis (a report of two cases). Med J Armed Forces India, 1997; 53(4): 309–10
7. Abou Rached A, El Hajj W: Eosinophilic gastroenteritis: Approach to diagnosis and management. World J Gastrointest Pharmacol Ther, 2016; 7(4): 513–23
8. López-Medina G, Gallo M, Prado A et al: Eosinophilic gastroenteritis: Case report and review in search for diagnostic key points. Case Rep Gastrointest Med, 2015; 2015: 239506
9. Hsu YQ, Lo CY: A case of eosinophilic gastroenteritis. Hong Kong Med J, 1998; 4(2): 226–28
10. Klein NC, Hargrove RL, Sleisenger MH, Jeffries GH: Eosinophilic gastroenteritis. Medicine (Baltimore), 1970; 49: 299–319
11. Taş A, Çelık H: An unusual cause of ascites in a young patient. Turk J Gastroenterol, 2013; 24(1): 79–80

This work is licensed under Creative Common Attribution-NonCommercial-NoDerivatives 4.0 International (CC BY-NC-ND 4.0)

Indexed in: [PMC] [PubMed] [Emerging Sources Citation Index (ESCI)] [Web of Science by Clarivate]