Check for updates

Received: 11 March 2023 | Revised: 24 May 2023 | Accepted: 25 May 2023

DOI: 10.1111/cod.14359

ORIGINAL ARTICLE

CONTACT DERMATITIS WILEY

It is not always chlorhexidine: Identification of benzoxonium chloride and lauramine oxide as culprit allergens in a popular antiseptic in Switzerland

Héloïse Wüthrich[1] | Ahmad Yatim[1] | Julie Di Lucca[1] | Anna Walker[1] | Sarah Ventejou[1] | Marie-Anne Morren[1] | An Goossens[2] | Ella Dendooven[3,4] | Olivier Aerts[3,4] | Michel Gilliet[1,5] | Teofila Seremet[1]

[1]Department of Dermatology and Venereology, Lausanne University Hospital (CHUV), Lausanne, Switzerland

[2]Department of Dermatology, University Hospitals KU Leuven, Leuven, Belgium

[3]Department of Dermatology, University Hospital Antwerp (UZA), Antwerp, Belgium

[4]Research Group Immunology, University of Antwerp, Antwerp, Belgium

[5]Faculty of Biology and Medicine, University of Lausanne, Lausanne, Switzerland

Correspondence
Teofila Seremet, Department of Dermatology, Lausanne University Hospital (CHUV), Avenue de Beaumont 29, 1011 Lausanne, Switzerland, VD.
Email: teofila.caplanusi@chuv.ch

Abstract

Background: A popular antiseptic spray in Switzerland (Merfen spray), containing chlorhexidine digluconate, benzoxonium chloride and lauramine oxide, is frequently used to treat skin wounds. However, it is also increasingly reported as a major cause of adverse skin reactions, including allergic contact dermatitis (ACD).

Objectives: To investigate the contact allergens responsible for ACD from this antiseptic.

Patients/Methods: Patch tests were performed on seven patients with a clinical history compatible with contact dermatitis from this antiseptic mixture.

Results: All patients presented with acute eczematous reactions following contact with either Merfen spray alone, or with multiple products including this spray. Patients showed positive reactions to this product in both patch tests and repeated open application tests (ROATs). Four patients showed dose-dependent reactions to both benzoxonium chloride and lauramine oxide. One patient showed a dose-dependent reaction to the former and a non-dose-dependent reaction to the latter. Finally, two subjects showed responses only to lauramine oxide. One patient reacted to chlorhexidine digluconate 0.5% aq. in addition to both other allergens.

Conclusions: Two commercially unavailable allergens, that is, benzoxonium chloride and/or lauramine oxide were identified as major causes of ACD from Merfen antiseptic spray, whereas chlorhexidine digluconate was a contributing culprit in only one patient.

KEYWORDS

allergic contact dermatitis, antiseptics, benzoxonium chloride, CAS 1643-20-5, CAS 19379-90-9, CAS 55-56-1, case series, children, chlorhexidine, lauramine oxide

This is an open access article under the terms of the Creative Commons Attribution-NonCommercial-NoDerivs License, which permits use and distribution in any medium, provided the original work is properly cited, the use is non-commercial and no modifications or adaptations are made.
© 2023 The Authors. *Contact Dermatitis* published by John Wiley & Sons Ltd.

1 | INTRODUCTION

Antiseptics are often applied to treat small wounds or for field cleansing prior to minor interventions, such as ear piercing. Chlorhexidine is one of the most frequently used antiseptics[1] in this regard, yet may provoke both type I and IV allergies.[1–5] In Switzerland, and also Israel, a colourless spray that, besides chlorhexidine (0.5%), also contains benzoxonium chloride (0.1%) (CAS 19379-90-9) and lauramine oxide (CAS 1643-20-5) (company proprietary undisclosed %), has become very popular in the treatment of small wounds.[6] The first compound belongs to the group of quaternary ammonium salts (QUATS) that are widely used as antiseptics and disinfectants because of their high antimicrobial activity, low toxicity and thermal stability. It is commercially available in the form of gargle solutions, lozenges and oral sprays against, for example, buccopharyngeal pathogens, often in combination with lidocaine.[7]

The second compound, lauramine oxide (lauryldimethylamine oxide) is a clear, pale-yellow liquid derived from coconut and is a nonionic surfactant in neutral aqueous solutions that can transition to a cationic surfactant in acid solutions. It is a surfactant widely used as a foam builder, stabiliser, viscosity enhancer, emollient and hair conditioner, which can be found in personal care products, such as shampoos, facial cleansers, body washes, sunscreens and a variety of other products, such as dishwasher detergents.[8–12]

2 | PATIENTS AND METHODS

Seven patients (one adult and six children) were referred to the Department of Dermatology and Venereology, CHUV, Lausanne, Switzerland between January 2020 and November 2022, for investigation of cutaneous reactions related to the use of Merfen spray (Verfora, Villars-sur-Glâne, Switzerland). The adult patient was patch tested with the European baseline, cosmetic, preservative and excipient series (Chemotechnique Diagnostics, Vellinge, Sweden and AllergEAZE, SmartPractice, Calgary, Canada) and the children (all under 13 years of age) with an abbreviated (paediatric) baseline series and chlorhexidine digluconate 0.5% aq. (AllergEAZE). The Merfen spray and various other antiseptics containing chlorhexidine digluconate and/or benzoxonium chloride were tested 'as is' (Vita-hexin, Vita-merfen, Bepanthen plus, Hibidil, Mebucaspray spray—Table 1). Later, the individual components, that is, benzoxonium chloride and lauramine oxide, kindly supplied by the manufacturer of Merfen spray, were prepared in-house by the hospital pharmacy: the solvent was water for both benzoxonium chloride and lauramine oxide, with respective concentrations of 0.01%, 0.05%, 0.1% and 0.5% for the former, and 0.1%, 0.3%, 1% and 3% for the latter. The concentration of the former in Merfen spray was 0.1%, but the concentration of the latter was not provided by the manufacturer. Allergens were applied in IQ Ultra chambers (Chemotechnique Diagnostics). On day (D) 2, the patches were removed, and readings were performed on D2 and D4,

TABLE 1 Patch test results observed in patients with suspicion of allergic contact dermatitis from Merfen spray.

	Pat1	Pat2	Pat3	Pat4	Pat5	Pat6	Pat7
Chlorhexidine digluconate 0.5% aq.	−	−	−	−	−	−	+
Lanolin	NT	−	+	−	−	NT	NT
Merfen spray (chlorhexidine digluconate 0.5%, benzoxonium chloride 0.1%, lauramine oxide [unknown %])	++	− (a)	++	+	NT (b)	+	++
Vita-merfen solution (chlorhexidine digluconate 0.5%, benzoxonium chloride 0.1%)	NT	NT	NT	+	+	+	+++
Vita-hexin pommade (chlorhexidine gluconate, 0.5% adeps lanae [lanolin])	−	−	+++	NT	−	+	+++
Bepanthen plus cream (chlorhexidine dihydrochloride 0.5%, adeps lanae [lanolin])	−	−	+	−	−	−	+++
Hibidil solution (chlorhexidine digluconate 0.5%, azorubine, purified water, ethanol, gluconolactone, nonoxinol 9, sodium hydroxyde)	−	−	−	−	−	−	−
Mebucaspray spray (benzoxonium chloride 0.2%)	+	−	+++	−	+	+	+++
Benzoxonium chloride 0.01% aq.	−	−	−	−	+++	−	+
Benzoxonium chloride 0.05% aq.	−	−	?+	−	++	+	+
Benzoxonium chloride 0.1% aq.	?+	−	+	−	+++	++	++
Benzoxonium chloride 0.5% aq.	?+	−	+	−	+++	+	++
Lauramine oxide 0.1% aq.	?+	−	−	?+	+	+	+++
Lauramine oxide 0.3% aq.	?+	+	−	++	++	++	+++
Lauramine oxide 1% aq.	+	+	+	+++	++	+	+++
Lauramine oxide 3% aq.	+	+	+	+++	+++	+	+++

Note: The first column shows the different substances/products tested. (a) ROAT positive. (b) ROAT positive, the patient preferred not to be patch tested with Merfen spray.

16000536, 2023, 4, Downloaded from https://onlinelibrary.wiley.com/doi/10.1111/cod.14359 by CochraneItalia, Wiley Online Library on [09/11/2023]. See the Terms and Conditions (https://onlinelibrary.wiley.com/terms-and-conditions) on Wiley Online Library for rules of use; OA articles are governed by the applicable Creative Commons License

TABLE 2 Patient's characteristics.

No.	Age (years)	Gender	Reason for antiseptic use	ROAT Merfen	Application of products containing chlorhexidine without any skin reaction
1	9	M	Traumatic injuries	Positive	Yes
2	12	F	Earlobe piercing	Positive	Yes
3	8	F	Impetigo	Positive	Yes
4	12	F	Traumatic injuries	Positive	Yes
5	56	F	Earlobe piercing	Positive	Yes
6	10	F	Traumatic injuries	Not done	Yes
7	13	M	Insect bites	Not done	Unknown

Note: Demographic characteristics and clinical presentation following Merfen spray application.
Abbreviation: ROAT, repeated open application test.

according to ESCD recommendations. For the ROAT the patients applied the product twice daily on the same area on the flexor part of the forearm until the appearance of erythema +/− oedema (we recommended the application for a maximum of 14 days if no reaction was present earlier than 14 days). Additional data were collected from the patient's files including gender, age, occupation, atopic comorbidities and presence of eczema following Merfen spray application. Written informed consent was obtained (parents' consent for children under 18 years old) for the photographs and medical information to be published in print and online and with the understanding that this information may be publicly available.

3 | RESULTS

Among the 7 patients, 2 were male and 5 were female, with a mean age of 17 years and a median age of 12 (range: 8–56 years). All of them (repeatedly) presented with acute eczematous reactions in skin areas for which either Merfen spray alone, or multiple products including Merfen spray, had been applied. The patients 'characteristics are detailed in Table 2. Secondary infection was observed twice in case 3 and three times in case 4, for which a combination of topical corticosteroids and oral antibiotics had to be prescribed, the other patients being treated with topical corticosteroids and moisturizers alone.

All patients showed a positive reaction to Merfen spray, that is, five patients on patch testing and two patients with a positive repeated open application test (ROAT), one of the latter having a negative patch test reaction to it, while the other one is not willing to be further patch tested with the culprit spray (Table 1, Figure 1).

Only one patient showed a positive reaction to 0.5% aq. chlorhexidine digluconate (AllergEAZE) (Table 1). In this case, Hibidil (chlorhexidine digluconate 0.5% without benzoxonium chloride nor lauramine oxide) patch tested unexplainably negative, so we performed a ROAT with it, which showed a positive response compatible with a contact-allergic reaction. This patient did have positive patch test reactions to other commercial products containing chlorhexidine (Vita merfen, Vita-hexin and Bepanthen plus).

Patient 3 also reacted to two wound healing creams, that is, Vita-hexin and Bepanthen Plus, both labelled with chlorhexidine and *Adeps lanae* (lanolin), the latter being the causal agent (Table 1).

Five patients contact allergic to Merfen spray showed positive tests to Mebucaspray spray that contains benzoxonium chloride (but no chlorhexidine), as well as dose-dependent reactions to this QUAT.

Moreover, all patients ($n = 7$) reacting to Merfen spray responded positively to lauramine oxide (Table 1, Figure 1 and Figure S1).

Of note, two other patients with suspected contact allergy to Merfen spray probably suffered from irritant contact dermatitis, because they did not react to it on the patch, nor to chlorhexidine, benzoxonium chloride and lauramine oxide test solutions; additional ROATs were not performed, though. Moreover, five additional controls tested negative to Merfen spray and to all concentrations of benzoxonium and lauramine oxide, which suggests that the positive reactions observed in the seven patients described were not irritant in nature.

4 | DISCUSSION

Allergic contact dermatitis from Merfen spray in all seven patients was caused by benzoxonium chloride and/or lauramine oxide, two allergens not present in the commercial patch test series. Only one of the patients reacted also to chlorhexidine, a widely used but notorious and often suspected culprit sensitizer.

In contrast, contact allergy to benzoxonium chloride and lauramine oxide is less well documented, although several cases regarding the former compound, in particular, have been described in the literature for roughly 40 years.[13–15] More recently, Hsieh et al. also reported two cases of ACD from Merfen spray due to benzoxonium chloride,[16] one of them also with a doubtful reaction to 0.5% aq. chlorhexidine digluconate (Chemotechnique Diagnostics), becoming negative on subsequent patch testing. Nevertheless, no other products containing chlorhexidine digluconate were tested, nor was a ROAT performed, which would have been interesting, as shown in our case 7 (Table 1).

16000536, 2023, 4, Downloaded from https://onlinelibrary.wiley.com/doi/10.1111/cod.14359 by CochraneItalia, Wiley Online Library on [09/11/2023]. See the Terms and Conditions (https://onlinelibrary.wiley.com/terms-and-conditions) on Wiley Online Library for rules of use; OA articles are governed by the applicable Creative Commons License

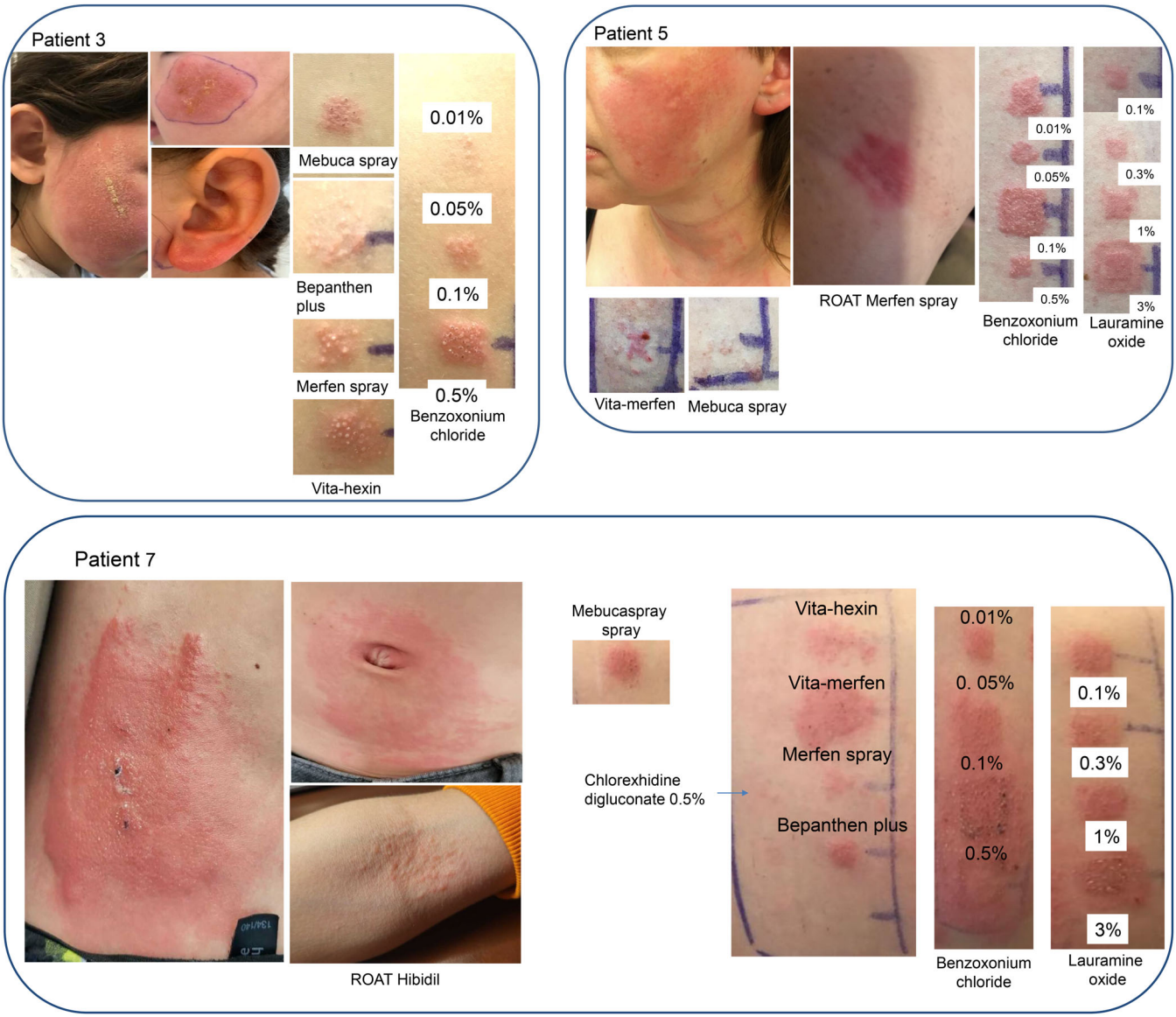

FIGURE 1 Clinical presentation of patients with allergic contact dermatitis following Merfen spray application, positive repeated open application test (ROAT) and patch tests. Three representative cases (Patients 3, 5 and 7) illustrate the clinical manifestations after using Merfen spray and positive relevant reactions on patch tests and ROAT confirming allergic contact dermatitis to Merfen spray.

Furthermore, data are scarce regarding the cross-reactivity between benzoxonium chloride and other quaternary ammonium salts mainly for benzalkonium chloride. In our series, benzalkonium chloride showed negative reactions in four patients and three patients were not tested for this allergen (data not shown).

Concerning lauramine oxide, it has probably been tested rarely but in a retrospective series of 17 367 patients tested between 1990 and 2013, 21 suffered from ACD and showed a positive patch test reaction to it, which was due to its presence in an antiseptic that also contained chlorhexidine.[17]

Contact-allergic reactions to antiseptics are not always due to the main antiseptic agent present. Recently, Beaumont et al. published a retrospective study on patients with contact dermatitis to CBB—an aqueous antiseptic widely used in France containing the mixture chlorhexidine digluconate/benzalkonium chloride/benzyl alcohol.[18] In their series, approximately 1/3 of patients were polysensitised (to two or even all three components) and 2/3 were mono sensitised. As in our series, most positive reactions were not caused by chlorhexidine digluconate. A previous case report to this published series showed sensitization to the three components of the same antiseptic in a child; the authors hypothesised that the sensitization was caused by the use of this antiseptic for maternity care of the umbilical cord.[19] Additional reports reinforced the hypothesis that sensitization in children takes place during umbilical cord care.[20,21] No information about this route of sensitization is available for our case series. Nevertheless, as this is the most popular antiseptic in Switzerland, it can be assumed that it is also used by mothers at home for umbilical cord care.

16000536, 2023, 4, Downloaded from https://onlinelibrary.wiley.com/doi/10.1111/cod.14359 by CochraneItalia, Wiley Online Library on [09/11/2023]. See the Terms and Conditions (https://onlinelibrary.wiley.com/terms-and-conditions) on Wiley Online Library for rules of use; OA articles are governed by the applicable Creative Commons License

Our case series further illustrates that not always the active antiseptic ingredient but also (a) non-active ingredient(s) may be the culprit allergen(s) and that to identify the sensitizer(s) in a mixture, all components should be tested individually. In general, and as also observed in the case series of Beaumont C et al.,[18] patch tests to a suspected culprit antiseptic mixture ('as is') may occasionally remain negative (e.g., our case 2), whereas a ROAT can still turn out positive, as well as patch tests to (an) individual component(s).

5 | CONCLUSION

Two allergens not available as commercial patch test preparations were found responsible for several cases of ACD from Merfen spray in Switzerland, that is, benzoxonium chloride (antiseptic) and lauramine oxide (surfactant). Concomitant sensitization to chlorhexidine digluconate, which is the main component of Merfen spray and an often suspected culprit, was observed in only one patient. This study encourages a thorough search for the causative allergen(s) in case of suspicion of ACD from an antiseptic mixture. The inclusion of benzoxonium chloride and lauramine oxide in commercial batteries could be a diagnostic asset.

AUTHOR CONTRIBUTIONS

Héloïse Wüthrich: Investigation; writing – original draft. **Ahmad Yatim:** Investigation; methodology; conceptualization. **Julie Di Lucca:** Conceptualization; methodology; investigation. **Anna Walker:** Investigation; methodology. **Sarah Ventejou:** Investigation. **Marie-Anne Morren:** Investigation; methodology. * **Goossens:** Writing – review and editing; validation; visualization. **Ella Dendooven:** Writing – review and editing; visualization; validation. **Olivier Aerts:** Validation; visualization; writing – review and editing. **Michel Gilliet:** Conceptualization; validation; visualization. **Teofila Seremet:** Conceptualization; investigation; methodology; validation; writing – original draft; project administration; supervision; data curation.

ACKNOWLEDGEMENT

Open access funding provided by Universite de Lausanne.

CONFLICT OF INTEREST STATEMENT

The authors have no conflicts of interest to report.

DATA AVAILABILITY STATEMENT

The data that support the findings of this study are available from the corresponding author upon reasonable request.

INFORMED CONSENT

Discussed patients gave consent (parents' consent for children under 18 years old) for the photographs and medical information to be published in print and online and with the understanding that this information may be publicly available.

ORCID

Héloïse Wüthrich https://orcid.org/0000-0003-1104-9988
Ahmad Yatim https://orcid.org/0000-0002-4859-4085
Julie Di Lucca https://orcid.org/0000-0001-5451-868X
Anna Walker https://orcid.org/0000-0002-9857-3004
Sarah Ventejou https://orcid.org/0000-0001-8474-9446
Marie-Anne Morren https://orcid.org/0000-0002-4860-5194
An Goossens https://orcid.org/0000-0002-9805-3439
Ella Dendooven https://orcid.org/0000-0002-3489-8010
Olivier Aerts https://orcid.org/0000-0002-0076-2887
Michel Gilliet https://orcid.org/0000-0002-4609-3762
Teofila Seremet https://orcid.org/0000-0002-3789-6256

REFERENCES

1. Gf C. Chlorhexidine hypersensitivity: a critical and updated review. *J Aller Ther*. 2013;4(4):1000141. doi:10.4172/2155-6121.1000141
2. Rose MA, Garcez T, Savic S, Garvey LH. Chlorhexidine allergy in the perioperative setting: a narrative review. *Br J Anaesth*. 2019;123(1):e95-e103. doi:10.1016/j.bja.2019.01.033
3. Watts TJ, Li PH, Ue KL, Haque R. Chronic allergic contact dermatitis due to chlorhexidine. *J Allergy Clin Immunol Pract*. 2018;6(1):254-255. doi:10.1016/j.jaip.2017.08.002
4. Goon ATJ, White IR, Rycroft RJG, McFadden JP. Allergic contact dermatitis from chlorhexidine. *Dermatitis*. 2004;15(1):45-47. doi:10.2310/6620.2004.20438
5. Lahouel I, Ben Salah N, Ben Fadhel N, et al. Contact urticaria caused by chlorhexidine in hydroalcoholic gel. *Contact Dermatitis*. 2021;84(5):338-339. doi:10.1111/cod.13735
6. Merfen—Drugs.com. Accessed August 19, 2022. https://www.drugs.com/international/merfen.html
7. Benzoxonium—Search results. Page 1 of about 5 results. Accessed August 19, 2022. https://www.drugs.com/search.php?searchterm=benzoxonium
8. Holmberg K. Surfactants. *Ullmann's Encyclopedia of Industrial Chemistry*. John Wiley & Sons, Ltd; 2019:1-56. doi:10.1002/14356007.a25_747.pub2
9. Kosswig K. Surfactants. In: Wiley-VCH Verlag GmbH & Co. KGaA, ed. Ullmann's Encyclopedia of Industrial Chemistry. Wiley-VCH Verlag GmbH & Co. KGaA; 2000:a25_747. doi:10.1002/14356007.a25_747
10. PubChem. Lauramine oxide. Accessed August 18, 2022. https://pubchem.ncbi.nlm.nih.gov/compound/15433
11. Ríos F, Lechuga M, Fernández-Arteaga A, Jurado E, Fernández-Serrano M. Anaerobic digestion of amine-oxide-based surfactants: biodegradation kinetics and inhibitory effects. *Biodegradation*. 2017;28(4):303-312. doi:10.1007/s10532-017-9797-6
12. Ríos F, Lechuga M, Fernández-Serrano M, Fernández-Arteaga A. Aerobic biodegradation of amphoteric amine-oxide-based surfactants: effect of molecular structure, initial surfactant concentration and pH. *Chemosphere*. 2017;171:324-331. doi:10.1016/j.chemosphere.2016.12.070
13. Díaz-Ramón L, Aguirre A, Ratón-Nieto JA, de Miguel M. Contact dermatitis from benzoxonium chloride. *Contact Dermatitis*. 1999;41(1):53-54. doi:10.1111/j.1600-0536.1999.tb06219.x
14. Bruynzeel DP, de Groot AC, Weyland JW. Contact dermatitis to lauryl pyridinium chloride and benzoxonium chloride. *Contact Dermatitis*. 1987;17(1):41-42. doi:10.1111/j.1600-0536.1987.tb02642.x
15. de Groot AC, Conemans J, Liem DH. Contact allergy to benzoxonium chloride (Bradophen). *Contact Dermatitis*. 1984;11(5):324-325. doi:10.1111/j.1600-0536.1984.tb01027.x
16. Hsieh A, Sorg O, Piletta PA. Allergic contact dermatitis to benzoxonium chloride contained in an antiseptic solution. *Contact Dermatitis*. 2022;87(4):363-365. doi:10.1111/cod.14160
17. Goossens RA. Allergic contact dermatitis from the vehicle components of topical pharmaceutical products. *Immunol Allergy Clin North Am*. 2014;34(3):663-670, ix-x. doi:10.1016/j.iac.2014.04.010

16000536, 2023, 4, Downloaded from https://onlinelibrary.wiley.com/doi/10.1111/cod.14359 by CochraneItalia, Wiley Online Library on [09/11/2023]. See the Terms and Conditions (https://onlinelibrary.wiley.com/terms-and-conditions) on Wiley Online Library for rules of use; OA articles are governed by the applicable Creative Commons License

18. Beaumont C, Darrigade AS, Barbaud A, et al. Multiple cases of sensitization to an antiseptic containing chlorhexidine digluconate/benzalkonium chloride/benzyl alcohol with different profiles of sensitization in adults and children. *Contact Dermatitis*. 2022;87(1):62-70. doi:10.1111/cod.14085
19. Galadari A, Darrigade AS, Boralevi F, Milpied B. A child polysensitized to all constituents of Biseptine. *Contact Dermatitis*. 2020;82(1):65-66. doi:10.1111/cod.13393
20. Le Corre Y, Barbarot S, Frot AS, Milpied B. Allergic contact dermatitis to chlorhexidine in a very young child. *Pediatr Dermatol*. 2010;27(5):485-487. doi:10.1111/j.1525-1470.2010.01257.x
21. Darrigade A, Léauté-Labrèze C, Boralevi F, Taïeb A, Milpied B. Allergic contact reaction to antiseptics in very young children. *J Eur Acad Dermatol Venereol*. 2018;32(12):2284-2287. doi:10.1111/jdv.15140

SUPPORTING INFORMATION

Additional supporting information can be found online in the Supporting Information section at the end of this article.

How to cite this article: Wüthrich H, Yatim A, Di Lucca J, et al. It is not always chlorhexidine: Identification of benzoxonium chloride and lauramine oxide as culprit allergens in a popular antiseptic in Switzerland. *Contact Dermatitis*. 2023;89(4):284-289. doi:10.1111/cod.14359

16000536, 2023, 4, Downloaded from https://onlinelibrary.wiley.com/doi/10.1111/cod.14359 by CochraneItalia, Wiley Online Library on [09/11/2023]. See the Terms and Conditions (https://onlinelibrary.wiley.com/terms-and-conditions) on Wiley Online Library for rules of use; OA articles are governed by the applicable Creative Commons License