Flexible microsensor technology for real-time navigation tracking in balloon sinus ostial dilation

Kent Lam, M.D.,[1,2] Jo-Lawrence Bigcas, M.D.,[1] Amber Luong, M.D., Ph.D.,[1] William Yao, M.D.,[1] and Martin J. Citardi, M.D.[1]

ABSTRACT

Background: *Microsensor navigation has the potential to aid balloon sinus ostial dilation by providing real-time tracking of balloon devices within the complex anatomy of the sinonasal cavities.*

Objective: *This feasibility study evaluated the incorporation of a new microsensor technology into a flexible guidewire for use with current instruments in balloon sinus ostial dilation.*

Methods: *A retrospective study was conducted to include seven men and one woman (age range, 33–68 years), who underwent balloon sinus ostial dilation with flexible microsensor navigation in the operating room setting. All the procedures were performed at target sinuses with the patient under general anesthesia, in conjunction with subsequent endoscopic sinus surgery.*

Results: *Balloon dilation was attempted at the maxillary (n = 3), frontal (n = 14), and sphenoid (n = 1) sinuses. In all the cases, the surgical navigation system displayed the flexible wire tip as it was advanced to the target sinus ostia; this visual feedback for wire position guided the balloon placement. Successful balloon dilation with assistance of flexible microsensor navigation was performed on most sinuses, except a single frontal sinus with adjacent type 2 frontal cells.*

Conclusion: *Flexible navigation technology may be combined with balloon sinus technology to facilitate localization of instruments in the sinus anatomy. Additional optimization of both the device and software technology is warranted.*

(Allergy Rhinol 8:e20–e24, 2017; doi: 10.2500/ar.2017.8.0193)

Balloon sinus ostial dilation has gained increasing popularity as an effective and minimally invasive procedure.[1–4] The procedure requires precise placement of the balloon devices in the outflow tracts of the target sinuses. The location of the balloon devices within the sinuses is commonly confirmed by transillumination, especially after cannulation of the maxillary and frontal sinuses. Transillumination, however, does not indicate the path of the device within the nose and paranasal sinuses. Surgical navigation may expedite appropriate device placement, but, until recently, surgical navigation and sinus balloon devices have not been completely integrated.

At our institution, we have begun using flexible microsensor technology (GuideWire; Fiagon, Austin, TX), which is tracked through an electromagnetic navigation system and correlates device location with preoperative computed tomography imaging (Fig. 1). The microsensor, with an outer diameter of 0.5 mm and length of 8 mm, is incorporated into a flexible guidewire that may then be passed through a balloon sinus dilation system. The microsensor is capable of providing real-time tracking during placement of the balloon devices. We reported on the utility of the flexible microsensor technology as a novel aid.

METHODS

All patients who underwent image-guided balloon dilation (IG-BD) with flexible microsensor technology, from January 2015 to December 2015, were reviewed. The procedures were conducted at a tertiary rhinology referral center for patients with chronic rhinosinusitis who were undergoing planned endoscopic sinus surgery while under general anesthesia. Approval to conduct this study was obtained from the institutional review board committee at the University of Texas Health Science Center at Houston. Before IG-BD, the surgical navigation system was registered by using a

From the [1]Department of Otorhinolaryngology—Head and Neck Surgery, University of Texas McGovern Medical School, Houston, Texas, and [2]Department of Otolaryngology—Head and Neck Surgery, Eastern Virginia Medical School, Norfolk, Virginia

A. Luong is supported by the Center for Clinical and Translational Sciences, which is funded by National Institutes of Health Clinical and Translational Award UL1 TR000371 and KL2 TR000370 from the National Center for Advancing Translational Science

M.J. Citardi serves as a consultant for Acclarent, Biosense Webster, and Medtronic ENT. A. Luong serves as a consultant for ENTvantage, receives industry research funding from Intersect ENT, Mallinckrodt Pharmaceuticals, and Amgen. The remaining authors have no conflicts of interest pertaining to this article

Address correspondence to Martin J. Citardi, M.D., Department of Otorhinolaryngology—Head and Neck Surgery, University of Texas McGovern Medical School at Houston, 6431 Fannin Street, MSB 5.036, Houston, TX 77030

E-mail address: martin.j.citardi@uth.tmc.edu

This work is published and licensed by OceanSide Publications, Inc. The full terms of this license are available at https://www.allergyandrhinology.com/terms and incorporate the Creative Commons License Deed: (Attribution – Non-Commercial – NoDerivs 4.0 Unported (CC BY-NC-ND 4.0). By accessing the work you hereby accept the terms. Non-commercial uses of the work are permitted without any further permission from OceanSide Publications, Inc., provided the work is properly attributed. Any use of the work other then as authorized under this license or copyright law is prohibited. Copyright © 2017, OceanSide Publications, Inc., U.S.A.

Delivered by Ingenta to: University of Liverpool IP: 154.59.124.102 On: Thu, 27 Apr 2017 13:56:17
Copyright (c) Oceanside Publications, Inc. All rights reserved.
For permission to copy go to https://www.oceansidepubl.com/permission.htm

Figure 1. GuideWire navigation device (image provided by Fiagon).

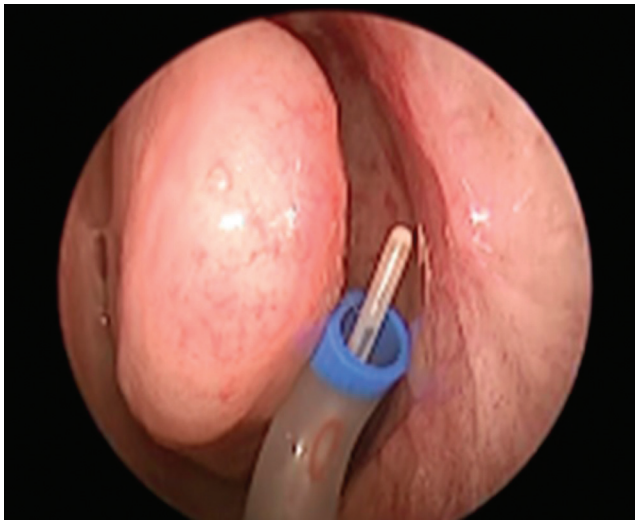

Figure 2. The location of GuideWire is shown at the tip of balloon sinus ostial dilation device; navigational tracking of the catheter tip is unique in demonstrating the path needed to deliver the balloon device from the external nares to the target sinuses.

contour-based protocol, which established at least 2-mm accuracy for all cases. The balloon device (Relieva Spin; Acclarent, Irvine, CA) was used in accordance with the manufacturer's guidelines, except that the microsensor guidewire was substituted for the standard guidewire (Fig. 2). IG-BD was performed on frontal sinuses, sphenoid sinuses, or maxillary sinus ostia, which were selected by preoperative signs of inflammation. The primary outcome measurement was the surgeon's ability to place and deploy the balloon device through the target sinus ostia.

RESULTS

A total of eight patients who met the study criteria were identified. This group consisted of seven men and one woman, with a mean age of 57.0 years (range, 33–68 years). Of the eight patients, five (62.5%) were diagnosed with chronic rhinosinusitis without nasal polyposis, whereas the remaining three (37.5%) had chronic rhinosinusitis with nasal polyposis. Two patients with chronic rhinosinusitis without nasal polyposis and one patient with chronic rhinosinusitis with nasal polyposis had previous balloon sinuplasty or endoscopic sinus surgery at outside facilities. IG-BD was successfully completed for 13 of 14 frontal sinuses (92.8%), 3 of 3 maxillary sinuses (100%), and 1 of 1 sphenoid sinus (100%). Before balloon dilation, device placement in a target sinus was confirmed through tracking of the flexible microsensor (Fig. 3). Of the 14 frontal sinuses, 1 was not successfully dilated due to the presence of type 2 frontal cells that prevented the direct cannulation of the frontal outflow tract without a preceding dissection (Fig. 4). After IG-BD of the tested frontal sinuses, additional frontal recess dissection with tissue removal was performed on 11 of 14 sides to improve ostial patency but was not performed to facilitate balloon device placement.

DISCUSSION

The success of balloon sinus ostial dilation requires the precise placement of balloon devices into target sinuses, but the intrinsic anatomic configuration of the sinonasal cavities commonly impedes device placement. Tomazic *et al.*[3] highlighted challenges in passing balloon devices at the frontal recess, where the device may need to pass a 90° turn, and, at the maxillary sinus, which may include an accessory maxillary ostium that is more easily cannulated than the true maxillary ostium. The inflammatory burden of the sinonasal mucosa may further restrict facile guidance of balloon devices into target sinuses.

Leventhal *et al.*[5] first reported the concept of using image-guidance tracking during balloon procedures in 2007. Their technique described the use of the Stryker Optical Universal Tracker (Stryker-Leibinger, Kalamazoo, MI), which was placed on the proximal ends of balloon devices, to provide information about the intraoperative location of devices relative to preoperative diagnostic images.[5] Electromagnetic sensors have most recently been incorporated into the handle of the NuVent EM Balloon Sinus Dilation System (Medtronic ENT, Jacksonville, FL),[6] which allows for direct tracking of the balloon catheter while it is directed through the sinonasal cavities. In the NuVent system, the electromagnetic sensor is built into the rigid handle of the integrated balloon seeker.

Delivered by Ingenta to: University of Liverpool IP: 154.59.124.102 On: Thu, 27 Apr 2017 13:56:17
Copyright (c) Oceanside Publications, Inc. All rights reserved.
For permission to copy go to https://www.oceansidepubl.com/permission.htm

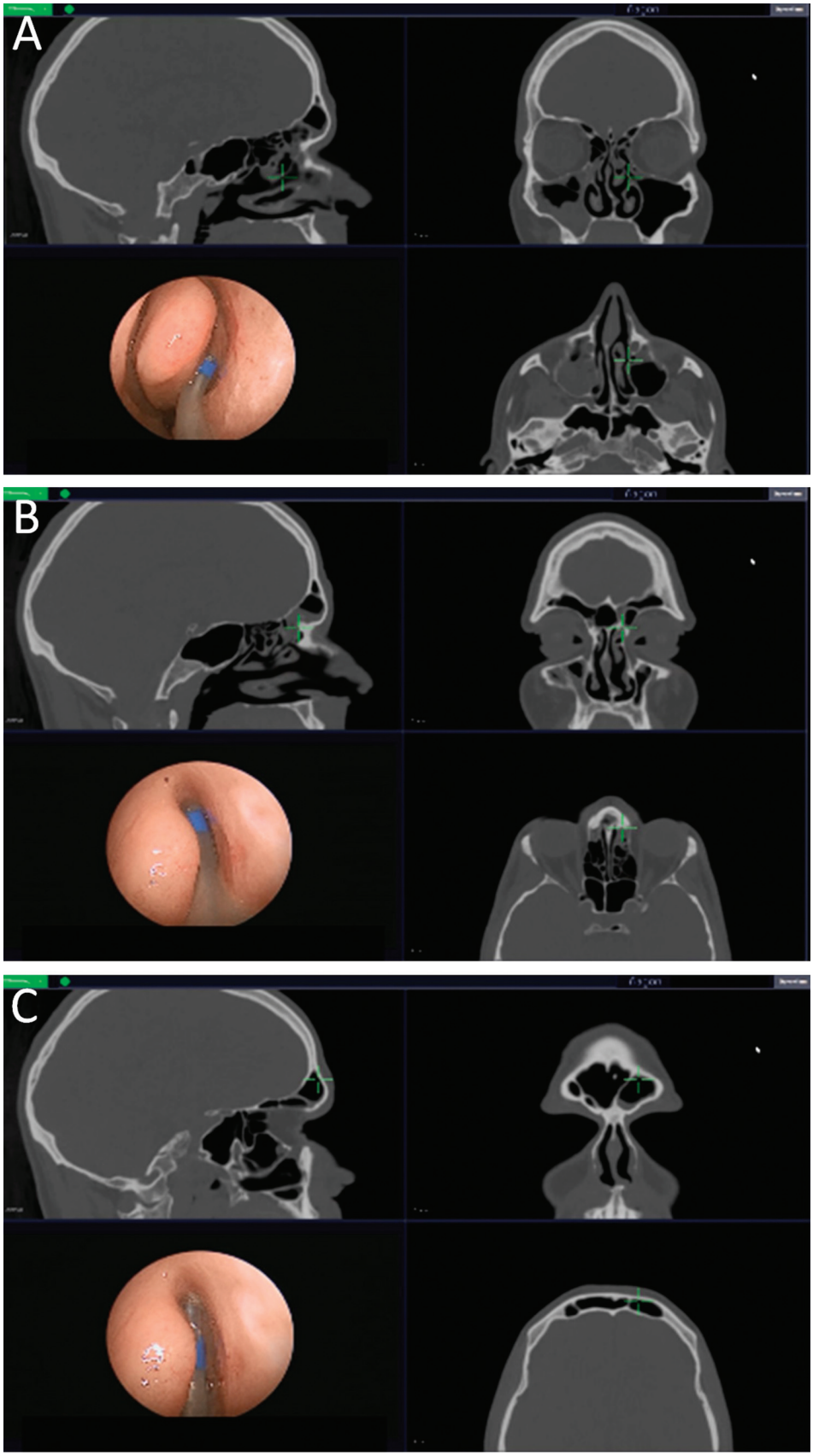

Figure 3. *Endoscopic demonstration of left frontal sinus cannulation and balloon dilation by using microsensor navigation. (A) The frontal sinus balloon device, which contains the microsensor guidewire at its tip, is visualized in the endoscopic view, obtained with a 30° telescope, and depicted by the green crosshairs in the coronal, sagittal, and axial slices of the corresponding computed tomography scan; the tip of the device was introduced into the middle meatus. (B) The device is advanced toward the frontal sinus outflow tract, while the surgeon monitors the wire sensor position on the navigation system. (C) After placement of the device is confirmed through the frontal ostium, the balloon is inflated.*

Delivered by Ingenta to: University of Liverpool IP: 154.59.124.102 On: Thu, 27 Apr 2017 13:56:17
Copyright (c) Oceanside Publications, Inc. All rights reserved.
For permission to copy go to https://www.oceansidepubl.com/permission.htm

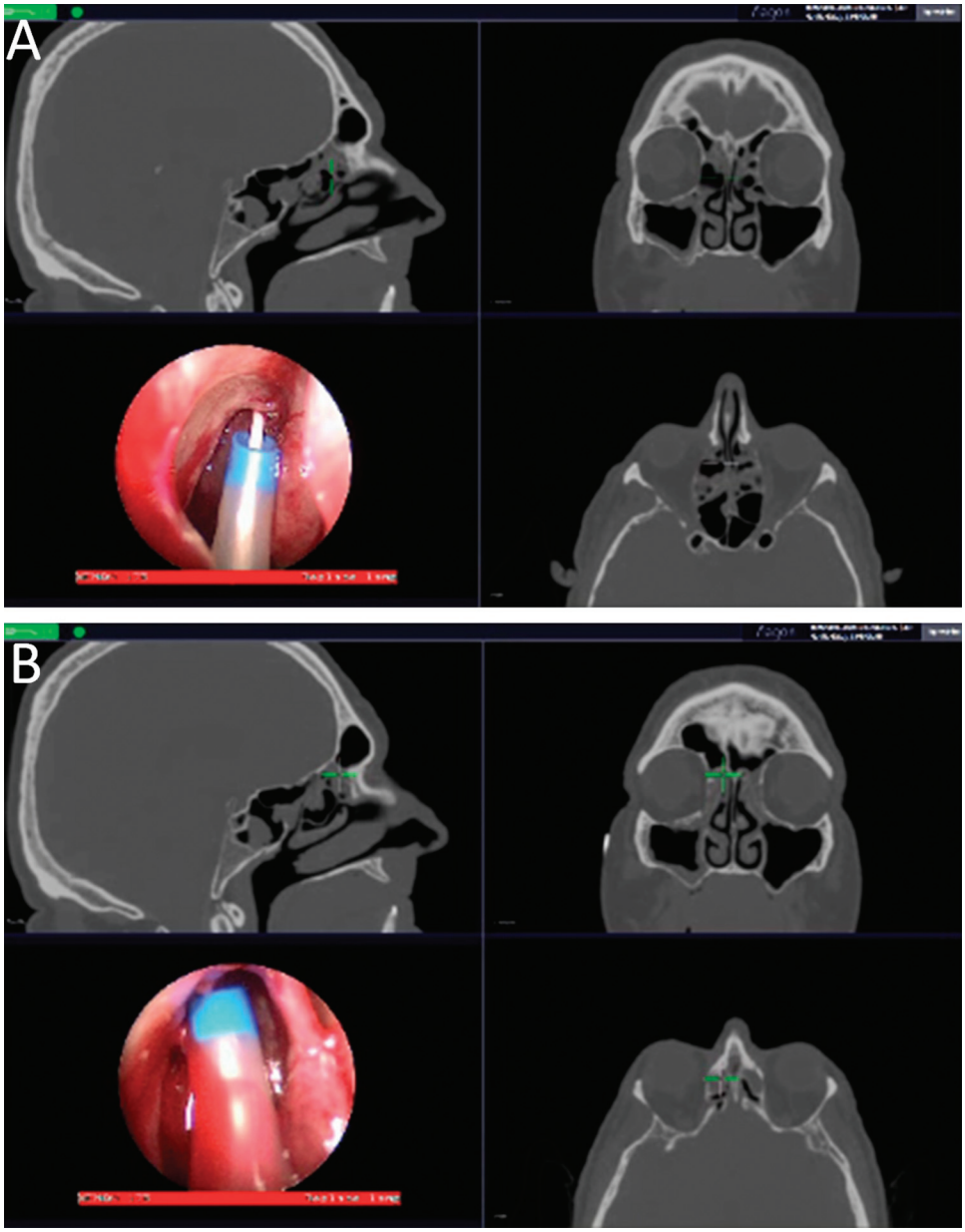

Figure 4. *(A) Endoscopic demonstration of the right frontal sinus that was not successfully cannulated, despite use of microsensor navigation during this series is shown. (B) The frontal recess is obstructed by the presence of type 2 frontal cells, which limited the movement of the microsensor guidewire in the outflow tract of the target frontal sinus.*

The flexible microsensor technology, as described in this study, is unique in its incorporation of a small precalibrated microsensor into a flexible guidewire, which can then be passed endoluminally through a balloon device. The microsensor tracking point, therefore, can be positioned at or distal to the tip the balloon catheter, thereby affording continuous tracking of the catheter tip as the flexible microsensor and balloon device are introduced as a unit into the sinonasal cavities. In all eight evaluated patients in this study, the flexible microsensor provided an adequate roadmap for the surgeon to observe and monitor the trajectory of the balloon devices to all tested frontal, maxillary, and sphenoid sinuses, which highlighted both the intended destination and path to the targeted sinuses.

In addition to the capacity to provide surgical navigation, the distinct value of the presented microsensor guidewire is rooted in its flexible nature. Compared with currently available rigid balloon devices with tracking capacities, the flexible microsensor is more easily maneuvered through the complex anatomy of the sinonasal cavities. The balloon device can then be passed over the microsensor guidewire once the thinner, more-flexible guidewire confirms the location in target sinuses. This assisted placement of balloon devices prevents unintended mucosal injury and surgical creation of a false tract. Because the flexible microsensor may be separated from balloon devices, the potential exists to apply the flexible microsensor technology in other hand instruments intended for endoscopic procedures, in-

Delivered by Ingenta to: University of Liverpool IP: 154.59.124.102 On: Thu, 27 Apr 2017 13:56:17
Copyright (c) Oceanside Publications, Inc. All rights reserved.
For permission to copy go to https://www.oceansidepubl.com/permission.htm

cluding suctioning catheters, sharp dissectors, and microdebrider systems.

We offered several suggestions to improve the technology for future use. Modifications for the flexible wire should focus on its durability because use of the guidewires was limited to three patients under routine sterilization protocols. The guidewire also was prone to kinking as it was advanced through the maxillary sinus introduction catheter. Although the size of the currently available microsensor is sufficiently small to pass through select balloon dilation systems, passage through the introduction sheath for the maxillary sinus was problematic due to its sharp angulation. Furthermore, the distal tip of the microsensor wire should have a small degree of angulation so that the surgeon can steer it to target sinuses.

Future studies with larger sample sizes and varied settings are needed to better understand the optimal applications of the present technologies. The setting of this study was conducted at a tertiary rhinology referral clinic, which potentially impacted patient selection toward more-advanced stages of sinonasal inflammation. In addition, it may be helpful in further studies to define a patient population for which IG-BD may be used as an alternative to traditional procedures performed in, not only the operation room, but also the in-office setting.

CONCLUSION

Flexible microsensor technology may assist balloon sinus dilation by providing real-time tracking of the tips of balloon catheter systems. Intraoperative applications of the microsensor technology for IG-BD are effective at the frontal, maxillary, and sphenoid sinuses, but additional refinements are necessary to maximize the utility of incorporating microsensor navigation into balloon sinus dilatation devices.

REFERENCES

1. Bolger WE, Brown CL, Church CA, et al. Safety and outcomes of balloon catheter sinusotomy: A multicenter 24-week analysis in 115 patients. Otolaryngol Head Neck Surg 137:10–20, 2007.
2. Weiss RL, Church CA, Kuhn FA, et al. Long-term outcome analysis of balloon catheter sinusotomy: Two-year follow-up. Otolaryngol Head Neck Surg 139(Suppl. 3):S38–S46, 2008.
3. Tomazic PV, Stammberger H, Braun H, et al. Feasibility of balloon sinuplasty in patients with chronic rhinosinusitis: The Graz experience. Rhinology 51:120–127, 2013.
4. Luong A, Batra PS, Fakhri S, and Citardi MJ. Balloon catheter dilatation for frontal sinus ostium stenosis in the office setting. Am J Rhinol 22:621–624, 2008.
5. Leventhal D, Heffelfinger R, and Rosen M. Using image guidance tracking during balloon catheter dilation of sinus ostia. Otolaryngol Head Neck Surg 137:341–342, 2007.
6. Available online at http://www.medtronic.com/us-en/healthcare-professionals/products/ear-nose-throat/balloon-sinus-dilation/nuvent-em-balloon-sinus-dilation-system.html; accessed January 2, 2017. □

Delivered by Ingenta to: University of Liverpool IP: 154.59.124.102 On: Thu, 27 Apr 2017 13:56:17
Copyright (c) Oceanside Publications, Inc. All rights reserved.
For permission to copy go to https://www.oceansidepubl.com/permission.htm