Check for updates

Received: 6 June 2022 | Revised: 7 October 2022 | Accepted: 16 November 2022

DOI: 10.1111/phpp.12845

LETTER

Photodermatology, Photoimmunology & Photomedicine WILEY

An unusual case of solar urticaria exacerbated by clothing: Confirmation through phototesting

1 | INTRODUCTION

Solar urticaria can be induced by different wavelengths of light, specially in normally unexposed zones covered by clothing.[1] We present an unusual case of solar urticaria in a patient, which is exacerbated in areas covered by white clothing.

2 | CASE REPORT

A 42-year-old male patient was referred to the Medical Research Center at the University of Malaga, Spain, for a photobiology study. The patient had no prevalent diseases and not use of medications, which causes photosensitivity. He reported typical urticaria lesions after sun exposure with nonaffected face and hands. The patient mentioned that skin exposed to the sun in the morning did not develop lesions later in the day and that he sometimes experienced redness more intense on areas covered by clothing than on uncovered skin, always white color (Figure 1). Blood, urine, IgE, ANA, and porphyrin tests were normal.

FIGURE 1 Picture apported by the patient with image of the leg after sun exposure with a white short. An erythema is observed in the area covered by the white shorts (lower part of the image) that delimits the normal skin (adjacent photoexposed thigh). The area covered by double fabric delimiting the pocket was not affected).

2.1 | Phototesting

2.1.1 | Visible light

Response to visible light (VL) was tested by exposing areas of 1.13 cm^2 in the upper shoulder area to six incremental doses of light (1.26/2.55/5.04/7.56/10.08/12.6 J/cm^2) emitted by a 4000 K (daylight) light-emitting diode (LED) spotlight (SMD 1050 P-10 W; Miled Lighting). No abnormal responses were observed.

2.1.2 | UVB

Shoulder was tested to 6 Ultraviolet B (UVB) doses (6.08/12.16/18.24/27.36/36.48/54.72 mJ/cm^2) using a Dermalight 80-UVB device (Dr Hönle Medizintechnik GmbH). No lesions were observed immediately and the minimal erythemal dose after 24 h was low (18 mJ/cm^2, normal dose with broadband UVB lamp for phototype III is 25–35 mJ/cm^2).[2]

2.1.3 | UVA

Response to Ultraviolet A (UVA) was tested using a Philips HB-404-400 W lamp (Philips Co.) positioned at a distance of 20 cm from the patient's back. First, areas of 1.13 cm^2 in the upper shoulder area were exposed to six incremental doses (1.35/2.70/5.40/8.1/10.8/13.5 J/cm^2). Another area of 10 cm × 10 cm, in the upper shoulder below UVA

This is an open access article under the terms of the Creative Commons Attribution-NonCommercial-NoDerivs License, which permits use and distribution in any medium, provided the original work is properly cited, the use is non-commercial and no modifications or adaptations are made.
© 2022 The Authors. *Photodermatology, Photoimmunology & Photomedicine* published by John Wiley & Sons Ltd.

phototest areas, was irradiated by a dose of 5 J/cm^2 with the objective of irradiating a larger area of skin. Immediate erythema was observed only in the large irradiated surface, but no abnormal response was observed after 24 h. It has to be considered that high-pressure UVA lamp emission has a 29% of high-energy blue radiation (400–440 nm), and therefore, we considered to name it UVA high-energy blue lamp.

2.1.4 | Full-spectrum

Since UVB and UVA responses were null and very weak, respectively, the lateral trunk was exposed to 25.2 J/cm^2 under a polychromatic (from UVA to Infra-red [IR]) metal halide bulb (Phoenix-MH-150 W/TD/NDL, Phoenix Lamps Co. Bangladesh). The patient developed mild erythema in the irradiated area immediately after exposure. Similar to UVA test, no wheals were observed.

The spectral characteristics of the different illumination systems as well as the irradiance were performed by means of a double monochromator spectroradiometer Macam SR9910-SR (Irradian Co.) coupled to an Ulbrich-type sensor.

2.2 | Phototesting with clothing

Because the patient had reported erythema and wheals under clothes, we exposed bigger areas of his body (trunk and ankle) to the UVA source and to a higher dose with respect to noncovered skin (13.5 J/cm^2) through the clothing he was wearing (a 100% cotton white T-shirt), on the second day.

2.2.1 | Trunk

Under the T-shirt, the patient developed numerous wheals that coalesced to form a plaque in irradiated areas of the lateral trunk except in those that had been exposed to light from the polychromatic bulb the previous day. We attribute this to a hardening phenomenon (tolerance induced by light irradiation) (Figure 2A). It is noteworthy that the skin reaction produced after irradiating through the patient's shirt was much more intense (numerous wheals) than the reaction seen the day before, when skin had been directly exposed to the light (mild erythema).

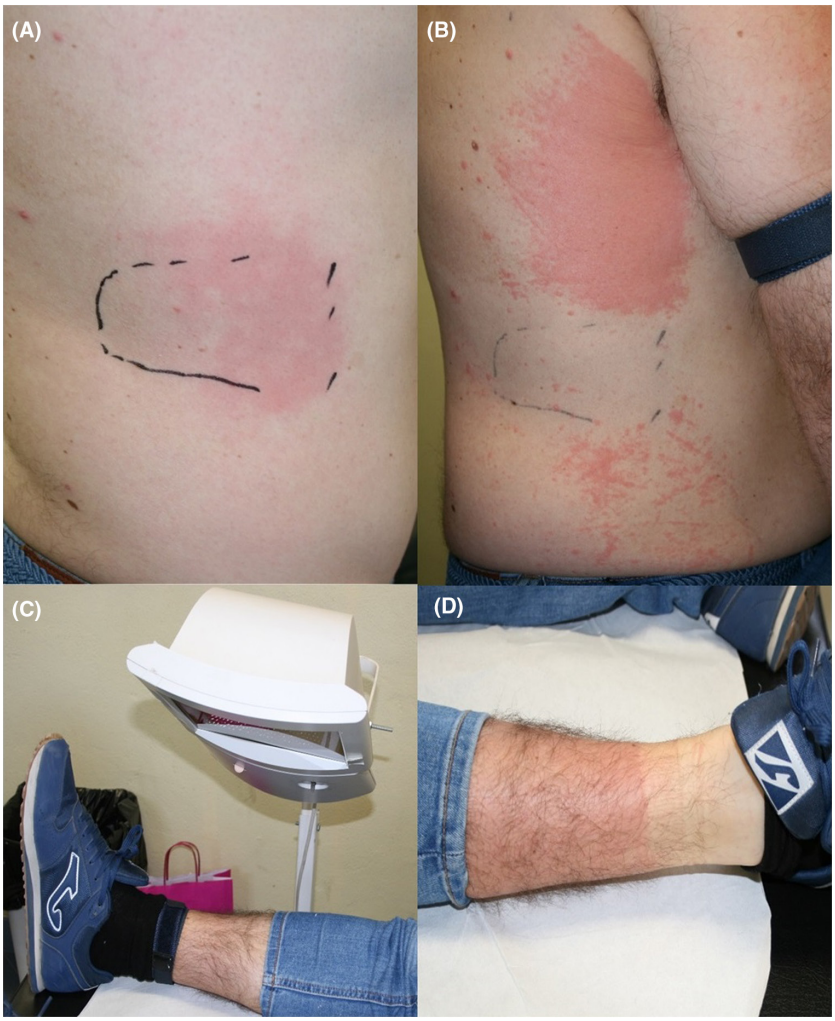

FIGURE 2 Urticarial lesions on the lateral trunk following phototesting. (A) Direct irradiation with a full-spectrum lamp resulting in immediate erythema. (B) The same area 24 h after irradiation through a white T-shirt. Note the erythematous-edematous urticarial plaque. No lesions occurred in areas exposed the previous day (hardening). (C) Phototesting through black sock. (D) Note the erythema on the exposed skin and the absence of lesions in the area protected by the sock.

16000781, 2023, 4, Downloaded from https://onlinelibrary.wiley.com/doi/10.1111/phpp.12845 by CochraneItalia, Wiley Online Library on [24/08/2023]. See the Terms and Conditions (https://onlinelibrary.wiley.com/terms-and-conditions) on Wiley Online Library for rules of use; OA articles are governed by the applicable Creative Commons License

2.2.2 | Ankle

Irradiation of the ankle area resulted in erythema in the exposed area and no reaction in the area covered by a black sock (Figure 2B).

The diagnosis was solar urticaria induced by UVA and high-energy blue light.

3 | DISCUSSION

The etiological and pathogenic mechanisms underlying solar urticaria are unknown, although it is thought that exposure to light might activate chromophores, which acting like photoallergens, would trigger an IgE-mediated reaction, causing mastocytes to release histamine.[3]

The patient in the current case explained that skin exposed to early morning sun did not react when exposed later in the day. We confirmed this "hardening" effect through phototesting, as irradiation of the lateral trunk with UVA only produced wheals in areas that had not been exposed to a full spectrum the previous day. Our patient also had a low minimal erythema dose (MED), which is not surprising considering that solar urticaria tends to be associated with other photodermatoses.[4,5]

Although protective clothing is recommended for the prevention of photodermatoses, our patient reported that he sometimes experienced worse lesions in covered areas. We confirmed this with after irradiation through a white T-shirt that produced wheals on the lateral trunk, while only mild erythema was observed in directly exposed skin. This would be attributed to the spectral characteristics of the transmitted light across white fabric, limited to UVA and high-energy blue radiation. The blue region of visible light from LED corresponds to higher wavelengths than 440 nm (data not shown) and could be inhibitory wavelengths for this patient. UVA transmittance across cotton white T-shirt was of 9% for UVA, while visible light in the blue part of spectrum was of around 40%.

We found just one other case of solar urticaria exacerbated by clothing (white) in our review of the literature,[6] attributed to the presence of optical brighteners capable of absorbing UV radiation and transforming it to visible light. We have also observed the transmission of visible light, specially in the higher energy part of blue spectrum, that can be also obtained after UVA radiation dispersion effect across the white fabrics (data not shown). Absence of color pigments in the white fabric also facilitates the transmittance of higher percentage of photons.[7]

In our patient, the black sock he was wearing protected the ankle area against irradiation; however, we cannot compare the effect of black with white, since the fabrics of the shirt and the sock were very different (sock had thicker and elastic fibers), so determining more opaque material.

In conclusion, solar urticaria exacerbated by clothing is possible in a patient that could be attributed to two main causes: (first), the patient showed clear photohardening after exposed in the same day or the day before to light, with no lesions after irradiation of this pre-exposed skin and (second), in parts of the skin nonpreviously exposed, after exposure to light with a white T-shirt, the transmitted UVA plus blue photons were able to promote skin reactions while normally pre-exposed noncovered parts do not react.

AUTHOR CONTRIBUTIONS

MVDG participated in the design of the study and data collection and interpretation of results; JA participated in data collection and data analysis; ENDG participated in data collection; CSR participated in data collection; FJNT participated in data collection and interpretation of results; EHC participated in the design of the study and interpretation of the results; all authors contributed to the manuscript writing.

FUNDING INFORMATION

This work has been supported by the project no. PID2020-117224RB-100 of Spanish Ministry of Science and Innovation. Funding for open access charge: Universidad de Málaga/CBUA.

KEYWORDS

clothing, phototest, solar urticaria, UVA radiation, visible radiation

CONFLICT OF INTEREST

The authors have no conflict of interest to declare.

DATA AVAILABILITY STATEMENT

The data that support the findings of this study are available from the corresponding author upon reasonable request.

Maria V. de Gálvez[1]
José Aguilera[1]
Enrique Navarrete-de Gálvez[2]
Cristina Sánchez-Roldán[1]
Francisco J. Navarro-Triviño[3]
Enrique Herrera-Ceballos[1]

[1]*Photobiological Dermatology Laboratory, Medical Research Center, Department of Dermatology and Medicine, Faculty of Medicine, University of Malaga, Málaga, Spain*
[2]*Project Engineering Area, Department of Graphic Expression Design and Projects. School of Industrial Engineering, University of Málaga, Málaga, Spain*
[3]*Unit of Eccema and Immunoallergy, Dermatology, University Hospital San Cecilio, Granada, Spain*

Correspondence
José Aguilera, Photobiological Dermatology Laboratory, Medical Research Center, Department of Dermatology and Medicine, Faculty of Medicine, University of Malaga, Málaga 29190, Spain.
Email: jaguilera@uma.es

ORCID

Maria V. de Gálvez https://orcid.org/0000-0002-5863-495X
José Aguilera https://orcid.org/0000-0002-1911-111X

16000781, 2023, 4, Downloaded from https://onlinelibrary.wiley.com/doi/10.1111/phpp.12845 by CochraneItalia, Wiley Online Library on [24/08/2023]. See the Terms and Conditions (https://onlinelibrary.wiley.com/terms-and-conditions) on Wiley Online Library for rules of use; OA articles are governed by the applicable Creative Commons License

Enrique Navarrete-de Gálvez https://orcid.org/0000-0002-0938-5643
Cristina Sánchez-Roldán https://orcid.org/0000-0003-3390-544X
Francisco J. Navarro-Triviño https://orcid.org/0000-0002-5454-3671
Enrique Herrera-Ceballos https://orcid.org/0000-0003-3654-4344

REFERENCES

1. Du-Thanh A, Debu A, Lalheve P, Guillot B, Dereure O, Peyron JL. Solar urticaria: a time-extended retrospective series of 61 patients and review of literature. *Eur J Dermatol*. 2013;23:202-207.
2. Pérez Ferriols A, Aguilera J, Aguilera P, et al. Determination of minimal erythema dose and anomalous reactions to UVA radiation by skin phototype. *Actas Dermosifiliogr*. 2014;105:780-788.
3. Beattie PE, Dawe RS, Ibbotson SH, Ferguson J. Characteristic and prognosis of idiopathic solar urticaria: a cohort of 87 cases. *Arch Dermatol*. 2003;139:1149-1154.
4. Monfrecola G, Nappa P, Pinni D. Solar urticaria with delayed onset: a case report. *Photodermatol*. 1988;5:103-104.
5. de Gálvez MV, Aguilera J, Sánchez-Roldán C, Herrera-Ceballos E. Delayed-onset solar urticaria with generalized wheals caused by UVB associated with polymorphic light eruption caused by UVA. *Photodermatol Photoimmunol Photomed*. 2015;31:107-110.
6. Gardeazabal J, González-Pérez R, Bilbao I, Alvarez-Hernández MI, Aguirre A, Díaz-Pérez JL. Solar urticaria enhanced through clothing. *Photodermatol Photoimmunol Photomed*. 1998;14:164-166.
7. Aguilera J, de Galvez MV, Sanchez-Roldán C, Herrera-Ceballos E. New advances in protection against solar ultraviolet radiation in textiles for summer clothing. *Photochem Photobiol*. 2014;90:1199-1206.

16000781, 2023, 4, Downloaded from https://onlinelibrary.wiley.com/doi/10.1111/phpp.12845 by CochraneItalia, Wiley Online Library on [24/08/2023]. See the Terms and Conditions (https://onlinelibrary.wiley.com/terms-and-conditions) on Wiley Online Library for rules of use; OA articles are governed by the applicable Creative Commons License