REVIEW ARTICLE

MECHANISMS OF DISEASE

IgG4-Related Disease

John H. Stone, M.D., M.P.H., Yoh Zen, M.D., Ph.D., and Vikram Deshpande, M.D.

IgG4-related disease is a newly recognized fibroinflammatory condition characterized by tumefactive lesions, a dense lymphoplasmacytic infiltrate rich in IgG4-positive plasma cells, storiform fibrosis, and, often but not always, elevated serum IgG4 concentrations. The disease was not recognized as a systemic condition until 2003, when extrapancreatic manifestations were identified in patients with autoimmune pancreatitis.[1] Autoimmune pancreatitis had been linked to elevated serum IgG4 concentrations as early as 2001,[2] and pancreatic specimens from patients with this condition were found to contain large numbers of IgG4-positive plasma cells. This disease is now considered to encompass two separate disorders: type 1, which is associated with IgG4-related disease; and type 2, which has substantial clinical overlap with type 1 but distinctive pathological features.[3]

IgG4-related disease has been described in virtually every organ system: the biliary tree, salivary glands, periorbital tissues, kidneys, lungs, lymph nodes, meninges, aorta, breast, prostate, thyroid, pericardium, and skin.[1,4-7] The histopathological features bear striking similarities across organs, regardless of the site of disease. IgG4-related disease is therefore analogous to sarcoidosis, another systemic disease in which diverse organ manifestations are linked by the same histopathological characteristics.

The nomenclature for IgG4-related disease continues to evolve. In a consensus meeting, Japanese investigators[8] recommended the adoption of "IgG4-related disease" among many suggested names.[9] IgG4-related disease is the name we have chosen to use.

Many medical conditions that have long been viewed as conditions confined to single organs are part of the spectrum of IgG4-related disease (Table 1). Mikulicz's syndrome, Küttner's tumor, and Riedel's thyroiditis — names embedded in the medical literature for more than a century in some cases — may now be replaced by designations that describe a key pathological feature and perhaps provide more insight into the pathophysiology. However, much remains unknown about the behavior of IgG4 in vivo, the participation of this molecule in disease, and whether its role in IgG4-related disease is primary or secondary. We describe the clinical, pathological, and radiologic features of IgG4-related disease; review potential disease mechanisms; and discuss early observations related to treatment.

From Harvard Medical School (J.H.S., V.D.) and the Departments of Medicine (Division of Rheumatology, Allergy, and Immunology) (J.H.S.) and Pathology (V.D.), Massachusetts General Hospital — both in Boston; and the Institute of Liver Studies, King's College Hospital, London (Y.Z.). Address reprint requests to Dr. Stone at the Rheumatology Unit, Massachusetts General Hospital, 55 Fruit St., Yawkey 2C, Boston, MA 02114, or at jhstone@partners.org.

N Engl J Med 2012;366:539-51.
Copyright © 2012 Massachusetts Medical Society.

THE IgG4 MOLECULE

IgG4 is a unique antibody in both structure and function.[10,11] This molecule accounts for less than 5% of the total IgG in healthy persons and is the least abundant IgG subclass.[10] In contrast to IgG1, IgG2, and IgG3, serum IgG4 concentrations among ostensibly healthy people vary by a factor of more than 100 (normal range, 0.01 to 1.4 mg per milliliter), but IgG4 concentrations within individual persons are generally stable.[11,12] Although the constant domains of IgG4 heavy chains share

The New England Journal of Medicine
Downloaded from nejm.org at BIBLIOSAN remote cilea clas on March 19, 2012. For personal use only. No other uses without permission.
Copyright © 2012 Massachusetts Medical Society. All rights reserved.

Table 1. Previously Recognized Conditions Now Acknowledged to Fall within the Spectrum of IgG4-Related Disease.

Mikulicz's syndrome (affecting the salivary and lacrimal glands)
Küttner's tumor (affecting the submandibular glands)
Riedel's thyroiditis
Eosinophilic angiocentric fibrosis (affecting the orbits and upper respiratory tract)
Multifocal fibrosclerosis (commonly affecting the orbits, thyroid gland, retroperitoneum, mediastinum, and other tissues and organs)
Inflammatory pseudotumor (affecting the orbits, lungs, kidneys, and other organs)
Mediastinal fibrosis
Retroperitoneal fibrosis (Ormond's disease)
Periaortitis and periarteritis
Inflammatory aortic aneurysm
Idiopathic hypocomplementemic tubulointerstitial nephritis with extensive tubulointerstitial deposits

more than 95% homology with those of other IgG subclasses, amino acid differences within the second constant domain lead to weak or negligible binding of IgG4 to both C1q and Fcγ receptors.[13,14] Thus, in theory, IgG4 does not activate the classical complement pathway effectively and has been traditionally considered to play only a limited role in immune activation.

A unique characteristic of IgG4 is its half-antibody exchange reaction, also referred to as fragment antigen-binding (Fab)–arm exchange.[15] IgG4 easily forms disulfide bonds within the heavy chains in its hinge region because, in contrast to the other IgG subclasses, the disulfide bonds between the heavy chains of the IgG4 molecule are unstable (Fig. 1).[16] As a result, approximately 50% of IgG4 molecules (estimated by in vitro methods) consist of heavy chains linked weakly by noncovalent forces.[17] The remainder of the IgG4 molecules presumably retain intact disulfide bonds between the heavy chains in vivo, but the actual percentages of intrachain isomers may vary according to local conditions (e.g., pH).[10] In an IgG4 molecule without disulfide bonds between the heavy chains, dissociations of the noncovalent bonds permit the chains to separate and recombine randomly, such that asymmetric antibodies with two different antigen-combining sites are formed.[18] The resulting bispecific (functionally monovalent) IgG4 molecules are unable to cross-link antigens, thereby losing the ability to form immune complexes (Fig. 1).[11,15]

In some circumstances, IgG4 has rheumatoid-factor activity and can bind the Fc portion of other IgG antibodies, particularly other IgG4 molecules.[10,11,19] In contrast to classic rheumatoid factor, which binds by means of variable domains, this interaction between IgG4 and IgG occurs between Fc constant domains.[20] The Fc interaction between IgG4 molecules is a potential transient intermediate of the Fab-arm exchange reaction and may contribute to the molecule's antiinflammatory function.[19]

Physiologic IgG4 responses can be induced by prolonged or repeated antigen exposures.[10] IgG4 production, like IgE production, is controlled primarily by type 2 helper T (Th2) cells.[10,11] Th2 cytokines such as interleukin-4 and interleukin-13 enhance the production of both IgG4 and IgE. In contrast, interleukin-10, interleukin-12, and interleukin-21 shift the balance between IgG4 and IgE,[21,22] favoring IgG4.[10] This finding is consistent with the theory that production of IgG4 in vivo is induced preferentially in the setting of a Th2-cell–dominant immune reaction, characterized by the activation of regulatory T cells that produce interleukin-10.[11] This selective IgG4 induction is referred to as the modified Th2 response.

IgG4 in Other Diseases

Despite the traditional view of IgG4 as an antiinflammatory immunoglobulin, this molecule is assumed to play a central role in certain immune-mediated conditions. The formation of cutaneous blisters in patients with pemphigus vulgaris and those with pemphigus foliaceus is mediated predominantly by IgG4 antibodies against desmoglein 1.[23,24] In addition, autoantibodies against the M-type phospholipase A2 receptor found on the podocytes, that are now linked strongly to the occurrence of idiopathic membranous glomerulonephritis, are primarily IgG4 antibodies.[25] In a subset of cases of childhood membranous glomerulonephritis, the renal glomeruli are damaged by IgG4-containing immune complexes that develop in situ.[26] Finally, IgG4 autoantibodies directed against the metalloproteinase ADAMTS13 (a disintegrin and metalloproteinase with a thrombospondin type 1 motif, member 13) are believed to play a major role in thrombotic thrombocytopenic purpura.[27] The condition now known as IgG4-related disease is clinically, pathologically, and serologically distinct from these other disorders.

The New England Journal of Medicine
Downloaded from nejm.org at BIBLIOSAN remote cilea clas on March 19, 2012. For personal use only. No other uses without permission.
Copyright © 2012 Massachusetts Medical Society. All rights reserved.

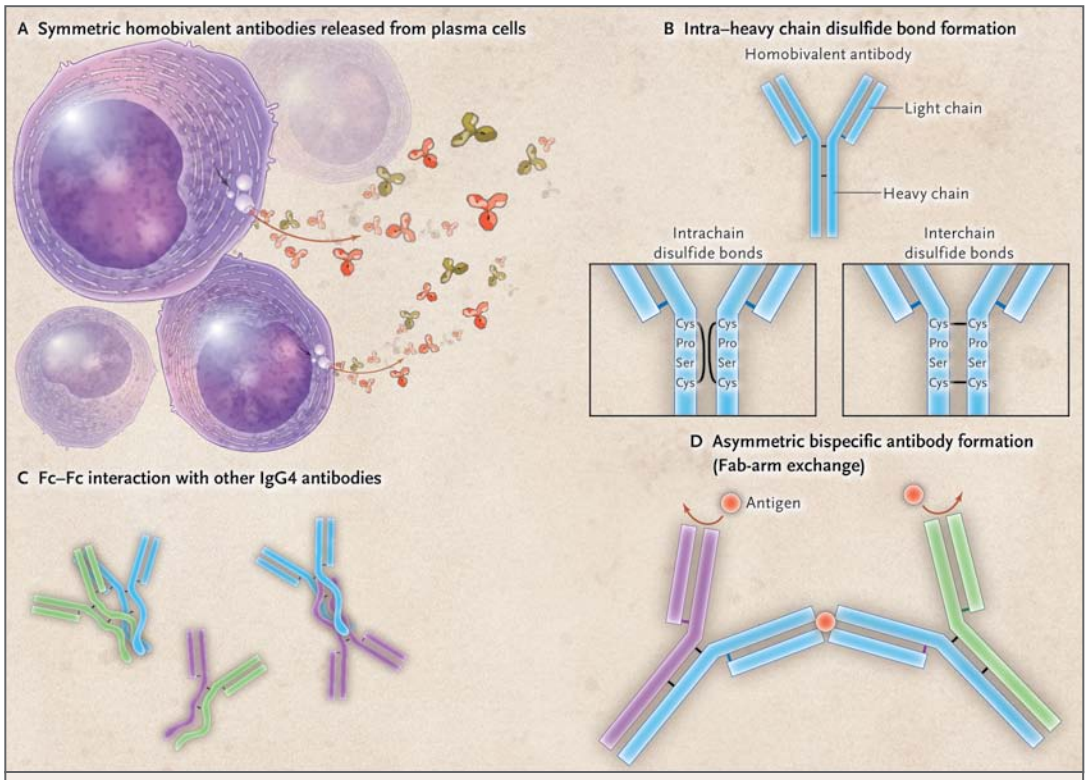

Figure 1. Biologic Characteristics of IgG4.

IgG4 molecules are released from plasma cells as symmetric homobivalent antibodies (Panel A). Because of the instability of the disulfide bonds between heavy chains of IgG4, some IgG4 antibodies form intrachain disulfide bonds in the hinge region and consist of heavy chains linked by noncovalent interaction (Panel B). In vitro analyses suggest that Fc interactions between IgG4 molecules are an intermediate stage preceding Fab-arm exchange (Panel C). These interactions may prevent inflammatory responses by shielding Fc portions from other immune-related molecules. IgG4 is transformed to an asymmetric, bispecific antibody by exchanging half-molecules with other IgG4 molecules (Panel D). IgG4 with two different antigen-combining sites behaves as a monovalent antibody. Fab-arm exchange results in the loss of the antibody's ability to cross-link antigens and to form immune complexes, leading to ineffective immune-complex formation with other IgG4 antibodies and other antibody isotypes.

PATHOLOGICAL FEATURES OF IGG4-RELATED DISEASE

Histopathological analysis of biopsy specimens remains the cornerstone in the diagnosis of IgG4-related disease. Elevated concentrations of IgG4 in tissue and serum are helpful in diagnosing IgG4-related disease, but neither one is a specific diagnostic marker.[28,29] Correlation with specific histopathological findings is essential, regardless of the serum IgG4 concentration, the number of IgG4-positive plasma cells in tissue, or the ratio of IgG4 to IgG in tissue. Misdiagnoses of IgG4-related disease are increasingly common because of excessive emphasis on moderate elevations of serum IgG4 concentration and overreliance on the finding of IgG4-positive plasma cells in tissue.

The key morphologic features of IgG4-related disease are a dense lymphoplasmacytic infiltrate that is organized in a storiform (i.e., matted and irregularly whorled) pattern, obliterative phlebitis, and a mild-to-moderate eosinophil infiltrate (Fig. 2).[3,30] In glandular organs, the infiltrate tends to aggregate around ductal structures.[3] The inflammatory lesion frequently forms a tumefactive mass that may destroy the involved organ. Destruction of osseous tissue in the craniofacial skeleton has also been described.[31] Neutrophils are detected only rarely, in association with mucosal erosions or some pulmonary manifestations of IgG4-related disease.[32,33] Granulomas are also distinctly unusual. The histologic appearance of IgG4-related disease, though highly characteristic, requires immunohistochemical confirmation with IgG4

The New England Journal of Medicine
Downloaded from nejm.org at BIBLIOSAN remote cilea clas on March 19, 2012. For personal use only. No other uses without permission.
Copyright © 2012 Massachusetts Medical Society. All rights reserved.

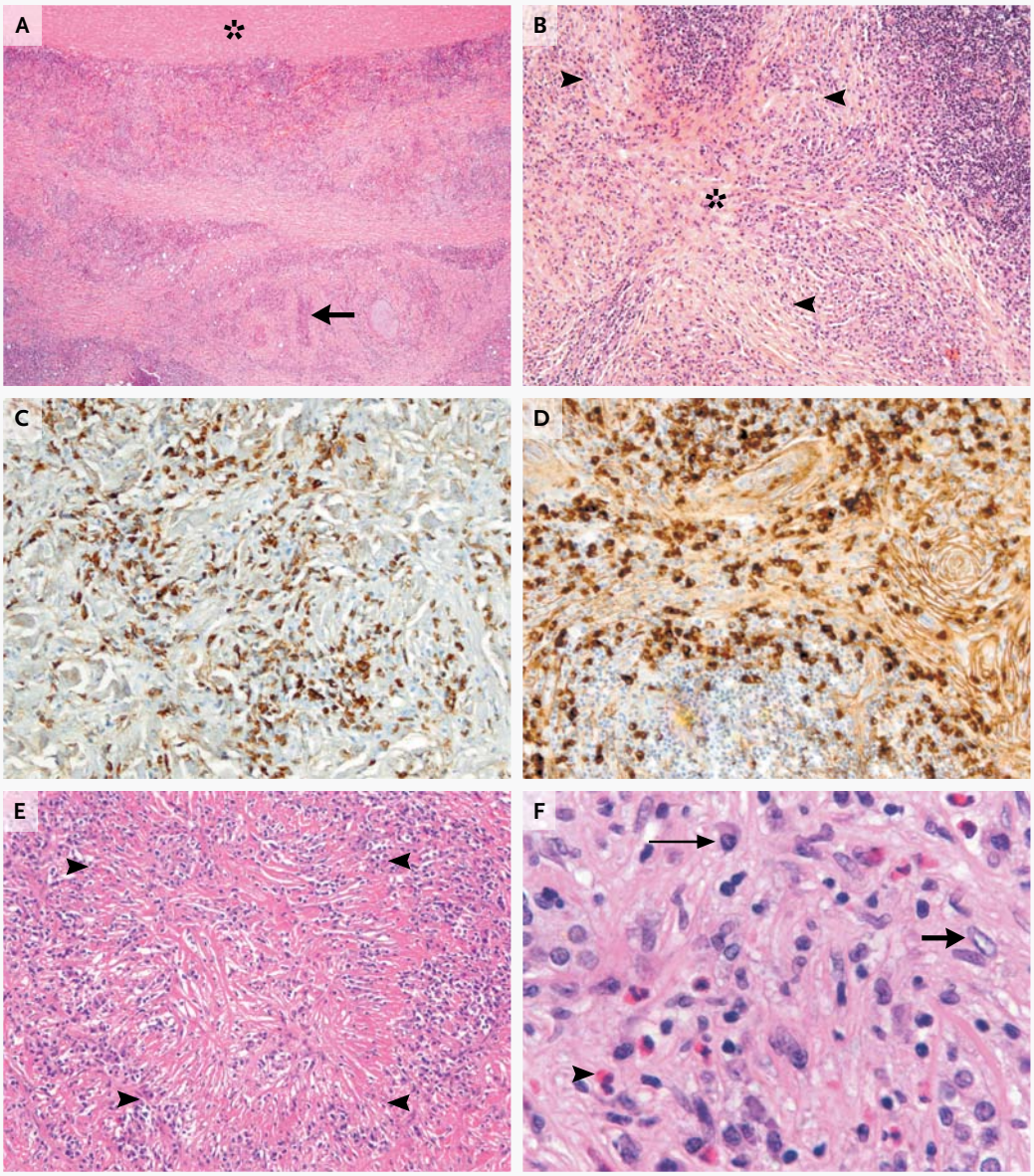

Figure 2. Histopathological Features of IgG4-Related Disease.

A tissue specimen from a patient with IgG4-related aortitis shows virtually the entire wall of the aorta (Panel A, hematoxylin and eosin). Although the media (inner layer, asterisk) is relatively unaffected, a dense lymphoplasmacytic infiltrate is present on the adventitial aspect (outer layer) of the aorta, and a vein obliterated by inflammation is indicative of obliterative phlebitis (arrow). Storiform fibrosis (Panel B, hematoxylin and eosin) is characteristic of IgG4-related disease, such as IgG4-related dacryoadenitis. The pattern is often likened to a cartwheel, with the bands of fibrosis (arrowheads) emanating from the center (asterisk) representing the spokes of the wheel. On immunoperoxidase staining, nearly all the plasma cells in specimens from a patient with IgG4-related aortitis (Panel C) and a patient with IgG4-related dacryoadenitis (Panel D) are strongly positive for IgG4, whereas the small lymphocytes are negative. A specimen of a venous channel (Panel E, hematoxylin and eosin) is characterized by total obliteration (i.e., obliterative phlebitis). Arrowheads mark the periphery of the vein. A high-power image of the specimen shown in Panel E (Panel F) shows lymphocytes, plasma cells (long arrow), eosinophils (arrowhead), and fibroblasts (short arrow).

The New England Journal of Medicine
Downloaded from nejm.org at BIBLIOSAN remote cilea clas on March 19, 2012. For personal use only. No other uses without permission.
Copyright © 2012 Massachusetts Medical Society. All rights reserved.

immunostaining. Moreover, there are subtle variations among some organs. For example, the obliterative phlebitis is always present in the pancreas and the submandibular glands but is observed much less often in the lacrimal glands.

The inflammatory infiltrate is composed of an admixture of T and B lymphocytes. Whereas B cells are typically organized in germinal centers, T cells are distributed diffusely throughout the lesion. All immunoglobulin subclasses may be represented within involved tissue, but IgG4 predominates. The presence of IgG4-bearing plasma cells is required for a diagnosis of IgG4-related disease, but IgG4-positive cells are found in a wide variety of inflammatory infiltrates, and the detection of substantial numbers of IgG4-positive plasma cells is therefore not diagnostic of IgG4-related disease.

Semiquantitative analysis of IgG4 immunostaining helps to distinguish IgG4-related disease from other conditions. A variety of cutoff points, ranging from more than 10 to more than 50 IgG4-positive plasma cells per high-power field, has been proposed.[34-36] The ratio of IgG4-bearing plasma cells to IgG-bearing plasma cells further assists in confirming the diagnosis of IgG4-related disease: a ratio higher than 50% is very suggestive of the diagnosis. IgG4-related disease is more difficult to diagnose in the late phase of organ involvement, when fewer plasma cells are present and fibrosis may predominate in some tissues (e.g., the retroperitoneum). The pattern of fibrosis and the ratio of IgG4 to total IgG provide crucial information in this context.

The closest histopathological mimickers of IgG4-related disease are lymphomas. Clonality studies are necessary to rule out these cancers. An early clue to the diagnosis of B-cell lymphoma is the presence of a predominantly B-cell infiltrate. In contrast, the lymphoid inflammatory infiltrate in IgG4-related disease is composed primarily of T cells. A thornier issue is the distinction between infiltrates caused by IgG4-related disease and other inflammatory infiltrates, such as those adjacent to neoplastic lesions. Tissues from patients with IgG4-related disease show diffuse infiltrates of IgG4-bearing plasma cells, in contrast to the focal aggregates of IgG4-bearing cells that are detected in most other inflammatory mimickers of this condition. A diffuse plasma-cell infiltrate with more than 30 IgG4-positive cells per high-power field and a ratio of IgG4 to IgG that is higher than 50% provides compelling evidence of IgG4-related disease, particularly in conjunction with the characteristic histopathological appearance. A lower cutoff point for IgG4-positive cells is acceptable in cases with the characteristic morphologic features. The clinical significance of isolated elevations in tissue and serum IgG4 concentrations, such as those observed in primary sclerosing cholangitis, inflammatory bowel disease, and Hashimoto's thyroiditis, remains uncertain, but these disorders do not appear to be part of the spectrum of IgG4-related disease.

PATHOPHYSIOLOGICAL MECHANISMS

Multiple immune-mediated mechanisms contribute to the fibroinflammatory process of IgG4-related disease (Fig. 3). We divide the following discussion into two sections: one focused on potential initiating mechanisms, and the other on specific disease pathways.

POTENTIAL INITIATING MECHANISMS

Genetic Risk Factors

Genetic studies of IgG4-related disease are in their infancy. Among several of the genetic susceptibility factors for IgG4-related disease, the HLA serotypes DRB1*0405 and DQB1*0401 increase the susceptibility to IgG4-related disease in Japanese populations, whereas DQβ1-57 without aspartic acid is associated with disease relapse in Korean populations.[37,38] Non-HLA genes in which single-nucleotide polymorphisms are involved in disease susceptibility or recurrence encode proteins that include cytotoxic T-lymphocyte–associated antigen 4, tumor necrosis factor α, and Fc receptor–like 3.[39-41]

Bacterial Infection and Molecular Mimicry

Substantial homology exists between human carbonic anhydrase II and the α-carbonic anhydrase of *Helicobacter pylori*.[42] The homologous segments contain the binding motif of the HLA molecule DRB1*0405.[42] Homology also exists between the plasminogen-binding protein of *H. pylori* and the ubiquitin-protein ligase E3 component n-recognin 2, which is expressed in pancreatic acinar cells.[43] One study showed that a majority of patients with

The New England Journal of Medicine
Downloaded from nejm.org at BIBLIOSAN remote cilea clas on March 19, 2012. For personal use only. No other uses without permission.
Copyright © 2012 Massachusetts Medical Society. All rights reserved.

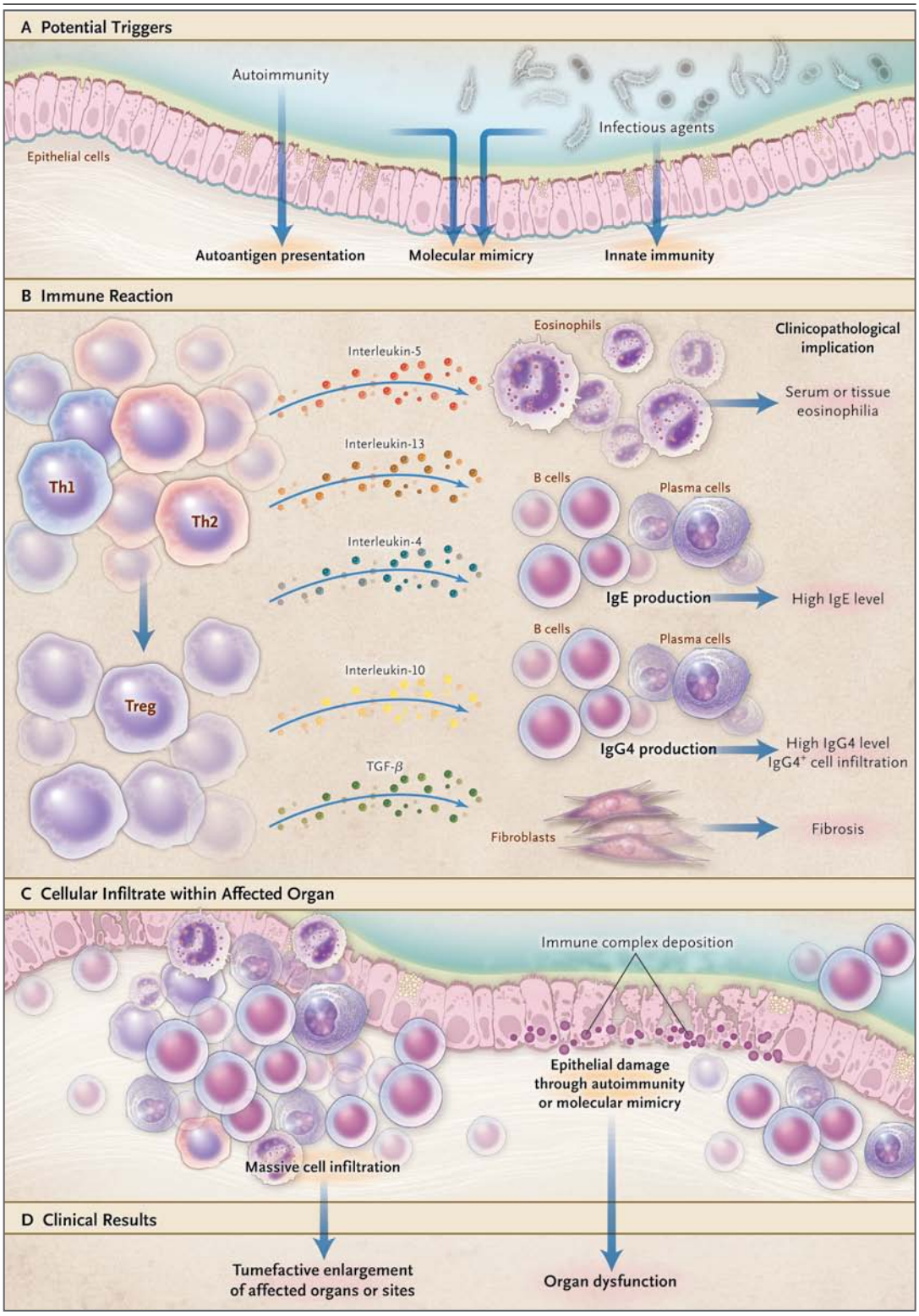

The New England Journal of Medicine
Downloaded from nejm.org at BIBLIOSAN remote cilea clas on March 19, 2012. For personal use only. No other uses without permission.
Copyright © 2012 Massachusetts Medical Society. All rights reserved.

Figure 3 (facing page). Pathogenetic Mechanisms in IgG4-Related Disease and Clinical Implications.
Autoimmunity and infectious agents are potential immunologic triggers in IgG4-related disease (Panel A). Interleukins 4, 5, 10, and 13 and transforming growth factor β (TGF-β) are overexpressed through an immune reaction in which type 2 helper T (Th2) cells predominate, followed by activation of regulatory T (Treg) cells (Panel B). These cytokines contribute to the eosinophilia, elevated serum IgG4 and IgE concentrations, and progression of fibrosis that are characteristic of IgG4-related disease. Massive infiltration by inflammatory cells results in organ damage (Panel C). The inflammatory-cell infiltrate leads to tumefactive enlargement of the affected sites and organ dysfunction (Panel D). Epithelial damage may result from tissue inflammation and immune-complex deposition.

autoimmune pancreatitis have antibodies against the plasminogen-binding protein of *H. pylori*.[43] In theory, antibodies directed against these bacterial components could behave as autoantibodies by means of molecular mimicry in genetically predisposed persons. The study appears to have included both type 1 and type 2 cases of autoimmune pancreatitis, however, and the findings still require confirmation.

A study of one patient with IgG4-related disease showed that stimulation with toll-like receptor ligands induces the production of both IgG4 and interleukin-10 from peripheral-blood mononuclear cells (PBMCs),[44] raising the possibility that various species of bacteria induce production of IgG4 through innate immunity. If this scenario is correct, the immunologic reactions could be similar among patients, even if the causative factors differ.

Autoimmunity

Although the claim has not been proved, autoimmunity is widely regarded as the initial immunologic stimulus for the Th2-cell immune response that is associated with IgG4-related disease. Serum IgG4 from patients with IgG4-related disease binds to the normal epithelia of the pancreatic ducts, bile ducts, and salivary-gland ducts. Potential autoantigens at these sites include carbonic anhydrases, lactoferrin, pancreatic secretory trypsin inhibitor, and trypsinogens.[45-47] Antibodies directed against such antigens, some of which are expressed in various exocrine organs, may be related to systemic manifestations of IgG4-related disease. However, these autoantibodies are neither specific for IgG4-related disease nor known to be of the IgG4 subclass.[46] Thus, their role in IgG4-related disease, if any, is unclear.

A proteomics study of immune complexes in serum samples from patients with IgG4-related disease identified a potential autoantigen (a 13.1-kD protein), but the identity of this protein requires further study.[48] Ultrastructural examinations have identified electron-dense granular deposits at the basement membrane of renal tubules and pancreatic ducts in patients with IgG4-related disease.[35,49,50] These deposits consist primarily of IgG4 and C3, with minor components of IgG1, IgG2, and IgG3.[51] It is unclear whether these deposits are involved in immune complex–mediated tissue damage or are a bystander phenomenon. The degree to which the Fab-arm exchange and the Fc interaction between IgG4 and IgG are involved in the formation of these immune deposits has yet to be elucidated.

SPECIFIC DISEASE PATHWAYS

Th2 Cells and Regulatory Immune Reaction

Th2-cell responses are predominantly activated at affected sites.[44,52-55] Tissue messenger RNA (mRNA) expression levels of Th2 cytokines, including interleukin-4, interleukin-5, interleukin-10, and interleukin-13, are substantially higher than in classic autoimmune conditions.[52,53] Many lymphocytes expressing interleukin-4 or interleukin-10 are identifiable in affected organs by in situ hybridization.[52] PBMCs that are collected from patients and stimulated principally produce Th2-type cytokines, indicating that the peripheral-blood T-cell phenotype is also shifted toward Th2 responses (Fig. 3).[53-55] Eosinophilia and elevated serum IgE levels, both observed in approximately 40% of patients with IgG4-related disease, are also mediated by Th2 cytokines.[56]

Another immunologic characteristic of IgG4-related disease is the activation of regulatory T (Treg) cells.[52,57] This marks an important contrast to classic autoimmune conditions, in which the function of Treg cells is impaired.[58] The activation of Treg cells in IgG4-related disease is indicated by a higher expression level of the forkhead box P3 (FOXP3) mRNA in tissue, as compared with the expression level in classic autoimmune and

The New England Journal of Medicine
Downloaded from nejm.org at BIBLIOSAN remote cilea clas on March 19, 2012. For personal use only. No other uses without permission.
Copyright © 2012 Massachusetts Medical Society. All rights reserved.

other conditions, as well as larger infiltrates of CD4+CD25+ Treg cells at affected sites and increased numbers of CD4+CD25^{high} Treg cells in the blood.[52,57] In addition to interleukin-10, which can be produced by Treg cells as well as by Th2 lymphocytes, transforming growth factor β (TGF-β) appears to be overexpressed in IgG4-related disease.[50,52] TGF-β may play a central role in the promotion of fibrosis in IgG4-related disease (Fig. 3).[50] These cytokines may be also produced by other cell populations, including regulatory B cells.

Role of IgG4 Antibodies

There are two possible explanations for the overabundance of IgG4 antibodies. First, the antibodies may behave as tissue-destructive immunoglobulins. Second, the excess of IgG4 may simply be an overexpression of these antibodies in response to an unknown primary inflammatory stimulus. The purported tendency of IgG4 antibodies to fulfill antiinflammatory functions and the fact that disease-specific IgG4 autoantibodies have not been identified in IgG4-related disease suggest that they are a response to an inflammatory stimulus.

A major gap in the understanding of IgG4-related disease pertains to the extent of Fab-arm exchange in patients with this condition. The high percentage of IgG4 antibodies that have become bispecific immunoglobulins through the Fab-arm exchange would render such antibodies unlikely to participate in a tissue-destructive immune response. However, the degree to which this bispecificity is fulfilled in patients with active IgG4-related disease is unclear. It is possible that a high percentage of IgG4 antibodies retain monospecificity and hence retain their potential to bind antigens and contribute to destructive inflammation.

EPIDEMIOLOGIC CHARACTERISTICS

Few population-based studies of IgG4-related disease have been performed, and the epidemiology of the disease remains poorly described, but certain striking demographic features are evident. The majority of patients are men (62 to 83%) and older than 50 years of age.[43,59] A national study of autoimmune pancreatitis in Japan suggested a ratio of male to female patients of approximately 2.8:1.[60] Even more striking male predominance (nearly 90%) has been reported for IgG4-related disease involving the kidney and retroperitoneum, but these reports include no more than several dozen cases.[61,62] This male predominance contrasts starkly with other autoimmune diseases that mimic IgG4-related disease, such as Sjögren's syndrome and primary biliary cirrhosis, which have markedly female predominance.[63]

Few data exist on the global incidence and prevalence of IgG4-related disease. Virtually all studies pertaining to the epidemiology of the disease come from Japan and focus on autoimmune pancreatitis. The estimated prevalence of autoimmune pancreatitis is 0.8 cases per 100,000 persons in Japan,[60] where this disorder is believed to account for up to 6% of all cases of chronic pancreatitis.[64-66] In a Mayo Clinic series of 245 patients who underwent pancreatic resection for benign indications, autoimmune pancreatitis was found in 11% of the patients.[67] Challenges in diagnosis stemming from a lack of familiarity with IgG4-related disease have probably led to underestimates of its prevalence.

CLINICAL FEATURES OF ORGAN-SYSTEM INVOLVEMENT

The major symptoms and differential diagnoses of each organ lesion are summarized in the table in the Supplementary Appendix, available with the full text of this article at NEJM.org. Some of the major clinical presentations are shown in Figure 4. IgG4-related disease usually presents subacutely, and most patients are not constitutionally ill. Fevers and elevations of C-reactive protein levels are unusual. The disorder is often identified incidentally through radiologic findings or unexpectedly in pathological specimens.

Some patients have disease that is confined to a single organ for many years. Others present with either known or subclinical involvement of other organs, in addition to the major organ involvement. Patients with autoimmune pancreatitis may have pancreatic disease as the major focus of their illness, but additional examination reveals that 30% also have tubulointerstitial nephritis, indicated by a distinctive radiologic appearance and the presence of mild proteinuria and nonglomerular hematuria.[62-68]

Multiorgan disease may be evident at diagnosis but can also evolve metachronously, over months to years. Spontaneous improvement, sometimes leading to clinical resolution of certain organ-system manifestations, is reported in a minority

The New England Journal of Medicine
Downloaded from nejm.org at BIBLIOSAN remote cilea clas on March 19, 2012. For personal use only. No other uses without permission.
Copyright © 2012 Massachusetts Medical Society. All rights reserved.

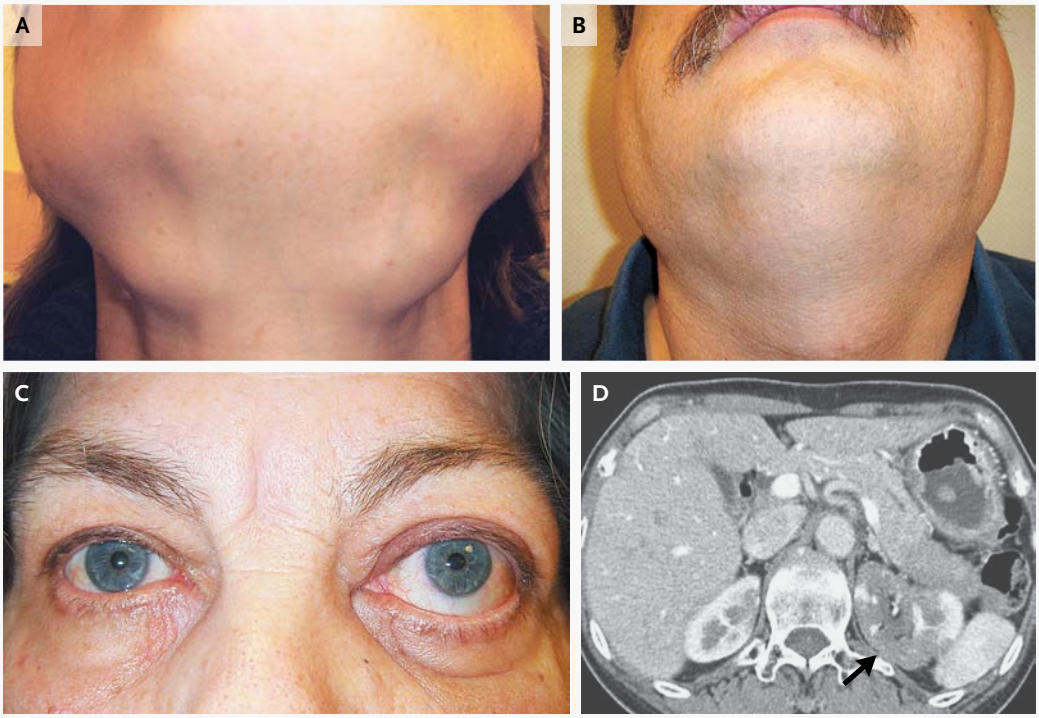

Figure 4. Clinical and Radiologic Features of Selected Manifestations of IgG4-Related Disease.
Panel A shows bilateral enlargement of the submandibular glands in a 45-year-old woman. Her serum IgG4 concentration was 240 mg per deciliter (normal level, <121). Panel B shows bilateral enlargement of the parotid gland in a 54-year-old man, who also had asthma, marked enlargement of the extraocular muscles, swelling of the left fifth cranial nerve, and abnormal soft tissue extending from his left orbit through the left greater palatine foramen into the pterygomaxillary cistern, causing proptosis. His serum IgG4 concentration was 1560 mg per deciliter. Panel C shows proptosis of the left eye, caused by enlargement of the lacrimal gland, in a 62-year-old man. His serum IgG4 concentration was 30 mg per deciliter, indicating that patients can have classic histopathological and immunohistochemical features of IgG4-related disease within tissue yet have normal serum IgG values. Panel D shows a computed tomographic scan of a diffusely enlarged pancreas and an irregular, low-attenuation area (arrow) in the left kidney. These radiologic findings correspond to autoimmune pancreatitis and tubulointerstitial nephritis, with histopathological and immunohistochemical-staining features of IgG4-related disease.

of cases.[69] A condition identified in the 1960s as multifocal fibrosclerosis[70] is now regarded more appropriately in most cases as IgG4-related disease.

Two common findings in IgG4-related disease are tumefactive lesions and allergic disease. IgG4-related disease appears to account for a substantial proportion of tumorous swellings in many organ systems.[4-6,33,71,72] Many patients with IgG4-related disease have allergic features such as atopy, eczema, asthma, and modest peripheral-blood eosinophilia.[56] Up to 40% of patients with IgG4-related disease have allergic diseases such as bronchial asthma or chronic sinusitis.[56]

IgG4-related disease often causes major tissue damage and can lead to organ failure, but it generally does so subacutely. Untreated IgG4-related cholangitis can lead to hepatic failure within months.[73] Similarly, IgG4-related aortitis can cause aneurysms and aortic dissections and is believed to be associated with between 10 and 50% of cases of inflammatory aortitis.[74-76] The natural history of IgG4-related tubulointerstitial nephritis has not been defined comprehensively, but substantial renal dysfunction and even renal failure can ensue.[62,68] Destructive bone lesions that mimic granulomatous polyangiitis (formerly Wegener's granulomatosis) or tumors in the sinuses, head, and middle-ear spaces have been reported,[31] but less aggressive lesions are the rule in most organs.

The New England Journal of Medicine
Downloaded from nejm.org at BIBLIOSAN remote cilea clas on March 19, 2012. For personal use only. No other uses without permission.
Copyright © 2012 Massachusetts Medical Society. All rights reserved.

IMAGING FEATURES

Imaging findings of IgG4-related disease are summarized in the table in the Supplementary Appendix. The appearance in images varies considerably, particularly in the lung and kidney.[77] The imaging features are generally nonspecific and do not permit reliable distinctions between IgG4-related disease and cancer. In the pancreas, the presence of a peripancreatic halo and diffuse narrowing of the pancreatic duct correspond, respectively, to a fibroinflammatory process extending into peripancreatic adipose tissue and to nonocclusive periductal inflammation.[78] Arterial lesions are characterized on computed tomography by homogeneous wall thickening and enhancement in the late phases after the administration of contrast material, corresponding to sclerosing inflammation involving the adventitia.[79]

SEROLOGIC FINDINGS

The majority of patients with IgG4-related disease have elevated serum IgG4 concentrations, but the range varies widely. Approximately 30% of patients have normal serum IgG4 concentrations, despite classic histopathological and immunohistochemical findings.[29] Early studies of serum IgG4 concentrations in patients with autoimmune pancreatitis are confounded by the fact that two subsets of autoimmune pancreatitis are now recognized.[3,80] In one study of type 1 autoimmune pancreatitis, the estimated prevalence of serum IgG4 elevation was 80%.[81] However, heterogeneity among other studies suggests that further investigations are needed to understand fully the sensitivity, specificity, and positive and negative predictive values of elevated serum IgG4 concentrations in patients with autoimmune pancreatitis. Data on the test characteristics of serum IgG4 concentrations in patients with extrapancreatic IgG4-related disease are scarce.

Data regarding the use of serial measurements of IgG4 concentration as indicators of disease activity are mixed.[2,82,83] Although IgG4 concentrations become lower with glucocorticoid treatment in the great majority of patients in whom they are elevated at baseline, they remain above normal values in most patients.[29] A multicenter study from Japan showed that IgG4 levels failed to normalize in 115 of 182 patients (63%) treated with glucocorticoids.[69] That study also showed that the disease remained in remission in some patients, despite persistent elevations of serum IgG4 concentrations.[69] Only 30% of patients with persistent elevation of serum IgG4 concentrations had relapses.[69] However, most studies of the predictive value of serum IgG4 concentrations for disease relapse suffer from limited follow-up periods.

Monitoring of IgG4 concentrations identifies early relapse in some patients. However, disease relapse occurs in 10% of patients with IgG4 concentrations that remain normal.[69] In a Mayo Clinic cohort of patients with autoimmune pancreatitis, the proportion of patients who had normalized levels of serum IgG4 did not differ between patients who did and those who did not have relapses.[84]

TREATMENT

Although no randomized treatment trials have been conducted, several points about treatment are clear. When vital organs are involved, aggressive treatment is needed because IgG4-related disease can lead to serious organ dysfunction and failure. However, not all manifestations of the disease require immediate treatment. For example, IgG4-related lymphadenopathy is often asymptomatic; indolent cases of lymphadenopathy persisting for decades have been reported.[85,86] Watchful waiting is therefore prudent in some cases. Another important point is that the correlation between the extent of disease and the need for treatment is imperfect. Some patients with IgG4-related disease in several organ systems may not require systemic therapy, yet urgent treatment is critical for some patients who have the disease in a single organ.

Glucocorticoids are typically the first line of therapy. A consensus statement from 17 referral centers in Japan suggested treating patients initially with prednisolone at a dose of 0.6 mg per kilogram of body weight per day for 2 to 4 weeks.[87] The authors suggested further that the prednisolone be tapered over a period of 3 to 6 months to 5.0 mg per day, and then continued at a dose between 2.5 and 5.0 mg per day for up to 3 years. Another approach has been to discontinue glucocorticoids entirely within 3 months.[69,84] Glucocorticoids appear to be effective (initially, at least) in the majority of patients with IgG4-related disease, but disease flares are common.[69] Azathioprine, mycophenolate mofetil, and methotrexate are used frequently as glucocorticoid-sparing agents or remission-maintenance drugs after glucocorticoid-

The New England Journal of Medicine
Downloaded from nejm.org at BIBLIOSAN remote cilea clas on March 19, 2012. For personal use only. No other uses without permission.
Copyright © 2012 Massachusetts Medical Society. All rights reserved.

induced remissions, but their efficacy has never been tested in clinical trials.

For patients with recurrent or refractory disease, B-cell depletion with rituximab appears to be a useful approach.[76,88] Swift clinical responses have been observed, with a striking targeting of the serum IgG4 level. In patients treated with rituximab, IgG4 concentrations decline sharply, although concentrations of other IgG subclasses remain stable. This decline is associated with clinical improvement within weeks.[76,88]

A major determinant of treatment responsiveness is the degree of fibrosis within the affected organs. Untreated IgG4-related disease often progresses from lymphoplasmacytic inflammation to extensive fibrosis. Patients in whom fibrosis has become well established are less likely to have a response to glucocorticoids and rituximab, but treatment responses have been reported in some patients with apparently widespread fibrosis.[62]

CONCLUSIONS

IgG4-related disease is a recently recognized condition with pathological features that are consistent across a wide range of organ systems. This condition unifies a large number of medical disorders previously regarded as confined to single organ systems. The precise links among the full histopathological picture of IgG4-related disease, the frequent serum IgG4 elevations, and the finding of increased quantities of IgG4-bearing plasma cells in tissue remain to be fully ascertained. A more comprehensive understanding of the IgG4 molecule, the diverse facets of IgG4-related disease, and the response of this disease to treatment, particularly B-cell depletion, may yield important insights into the immune system and other conditions now known to be associated with IgG4.

Disclosure forms provided by the authors are available with the full text of this article at NEJM.org.

REFERENCES

1. Kamisawa T, Funata N, Hayashi Y, et al. A new clinicopathological entity of IgG4-related autoimmune disease. J Gastroenterol 2003;38:982-4.
2. Hamano H, Kawa S, Horiuchi A, et al. High serum IgG4 concentrations in patients with sclerosing pancreatitis. N Engl J Med 2001;344:732-8.
3. Deshpande V, Gupta R, Sainani NI, et al. Subclassification of autoimmune pancreatitis: a histologic classification with clinical significance. Am J Surg Pathol 2011;35:26-35.
4. Stone JH, Khosroshahi A, Hilgenberg A, Spooner A, Isselbacher EM, Stone JR. IgG4-related systemic disease and lymphoplasmacytic aortitis. Arthritis Rheum 2009;60:3139-45.
5. Dahlgren M, Khosroshahi A, Nielsen GP, Deshpande V, Stone JH. Riedel's thyroiditis and multifocal fibrosclerosis are part of the IgG4-related systemic disease spectrum. Arthritis Care Res (Hoboken) 2010;62:1312-8.
6. Saeki T, Saito A, Hiura T, et al. Lymphoplasmacytic infiltration of multiple organs with immunoreactivity for IgG4: IgG4-related systemic disease. Intern Med 2006;45:163-7.
7. Kamisawa T, Takuma K, Egawa N, Tsuruta K, Sasaki T. Autoimmune pancreatitis and IgG4-related sclerosing disease. Nat Rev Gastroenterol Hepatol 2010;7:401-9.
8. The Reports of the grant from Intractable Diseases, Health and Labor Sciences Research Grants from the Ministry of Health, Labor and Welfare (H21-Nanchi-Ippann-112, representative Umehara H). (In Japanese.)
9. Khosroshahi A, Stone JH. IgG4-related systemic disease: the age of discovery. Curr Opin Rheumatol 2011;23:72-3.
10. Aalberse RC, Stapel SO, Schuurman J, Rispens T. Immunoglobulin G4: an odd antibody. Clin Exp Allergy 2009;39:469-77.
11. Nirula A, Glaser SM, Kalled SL, Taylor FR. What is IgG4? A review of the biology of a unique immunoglobulin subtype. Curr Opin Rheumatol 2011;23:119-24.
12. Aucouturier P, Danon F, Daveau M, et al. Measurement of serum IgG4 levels by a competitive immunoenzymatic assay with monoclonal antibodies. J Immunol Methods 1984;74:151-62.
13. Tao MH, Smith RI, Morrison SL. Structural features of human immunoglobulin G that determine isotype-specific differences in complement activation. J Exp Med 1993;178:661-7.
14. Canfield SM, Morrison SL. The binding affinity of human IgG for its high affinity Fc receptor is determined by multiple amino acids in the CH2 domain and is modulated by the hinge region. J Exp Med 1991;173:1483-91.
15. van der Neut Kolfschoten M, Schuurman J, Losen M, et al. Anti-inflammatory activity of human IgG4 antibodies by dynamic Fab arm exchange. Science 2007;317:1554-7.
16. Schuurman J, Perdok GJ, Gorter AD, Aalberse RC. The inter-heavy chain disulfide bonds of IgG4 are in equilibrium with intra-chain disulfide bonds. Mol Immunol 2001;38:1-8.
17. Aalberse RC, Schuurman J. IgG4 breaking the rules. Immunology 2002;105:9-19.
18. Rispens T, Ooijevaar-de Heer P, Bende O, Aalberse RC. Mechanism of immunoglobulin G4 Fab-arm exchange. J Am Chem Soc 2011;133:10302-11.
19. Rispens T, Ooievaar-De Heer P, Vermeulen E, Schuurman J, van der Neut Kolfschoten M, Aalberse RC. Human IgG4 binds to IgG4 and conformationally altered IgG1 via Fc-Fc interactions. J Immunol 2009;182:4275-81.
20. Kawa S, Kitahara K, Hamano H, et al. A novel immunoglobulin-immunoglobulin interaction in autoimmunity. PLoS One 2008;3(2):e1637.
21. Wood N, Bourque K, Donaldson DD, et al. IL-21 effects on human IgE production in response to IL-4 or IL-13. Cell Immunol 2004;231:133-45.
22. de Boer BA, Kruize YC, Rotmans PJ, Yazdanbakhsh M. Interleukin-12 suppresses immunoglobulin E production but enhances immunoglobulin G4 production by human peripheral blood mononuclear cells. Infect Immun 1997;65:1122-5.
23. Rock B, Martins CR, Theofilopoulos AN, et al. The pathogenic effect of IgG4 autoantibodies in endemic pemphigus foliaceus (fogo selvagem). N Engl J Med 1989;320:1463-9.
24. Warren SJ, Arteaga LA, Rivitti EA, et al. The role of subclass switching in the pathogenesis of endemic pemphigus foliaceus. J Invest Dermatol 2003;120:104-8.
25. Beck LH Jr, Salant DJ. Membranous nephropathy: recent travels and new roads ahead. Kidney Int 2010;77:765-70.
26. Debiec H, Lefeu F, Kemper MJ, et al. Early-childhood membranous nephropathy due to cationic bovine serum albu-

The New England Journal of Medicine
Downloaded from nejm.org at BIBLIOSAN remote cilea clas on March 19, 2012. For personal use only. No other uses without permission.
Copyright © 2012 Massachusetts Medical Society. All rights reserved.

min. N Engl J Med 2011;364:2101-10. [Erratum, N Engl J Med 2011;365:477.]
27. Ferrari S, Mudde GC, Rieger M, Veyradier A, Kremer Hovinga JA, Scheiflinger F. IgG subclass distribution of anti-ADAMTS13 antibodies in patients with acquired thrombotic thrombocytopenic purpura. J Thromb Haemost 2009; 7:1703-10.
28. Strehl JD, Hartmann A, Agaimy A. Numerous IgG4-positive plasma cells are ubiquitous in diverse localised non-specific chronic inflammatory conditions and need to be distinguished from IgG4-related systemic disorders. J Clin Pathol 2011;64:237-43.
29. Sah RP, Chari ST. Serologic issues in IgG4-related systemic disease and autoimmune pancreatitis. Curr Opin Rheumatol 2011;23:108-13.
30. Zen Y, Nakanuma Y. IgG4-related disease: a cross-sectional study of 114 cases. Am J Surg Pathol 2010;34:1812-9.
31. Pace C, Ward S. A rare case of IgG4-related sclerosing disease of the maxillary sinus associated with bone destruction. J Oral Maxillofac Surg 2010;68:2591-3.
32. Zen Y, Inoue D, Kitao A, et al. IgG4-related lung and pleural disease: a clinicopathologic study of 21 cases. Am J Surg Pathol 2009;33:1886-93.
33. Kawa S, Okazaki K, Kamisawa T, Shimosegawa T, Tanaka M. Japanese consensus guidelines for management of autoimmune pancreatitis: II. Extrapancreatic lesions, differential diagnosis. J Gastroenterol 2010;45:355-69.
34. Dhall D, Suriawinata AA, Tang LH, Shia J, Klimstra DS. Use of immunohistochemistry for IgG4 in the distinction of autoimmune pancreatitis from peritumoral pancreatitis. Hum Pathol 2010; 41:643-52.
35. Deshpande V, Chicano S, Finkelberg D, et al. Autoimmune pancreatitis: a systemic immune complex mediated disease. Am J Surg Pathol 2006;30:1537-45.
36. Chari ST. Diagnosis of autoimmune pancreatitis using its five cardinal features: introducing the Mayo Clinic's HISORt criteria. J Gastroenterol 2007;42: Suppl 18:39-41.
37. Kawa S, Ota M, Yoshizawa K, et al. HLA DRB10405-DQB10401 haplotype is associated with autoimmune pancreatitis in the Japanese population. Gastroenterology 2002;122:1264-9.
38. Park DH, Kim MH, Oh HB, et al. Substitution of aspartic acid at position 57 of the DQbeta1 affects relapse of autoimmune pancreatitis. Gastroenterology 2008; 134:440-6.
39. Chang MC, Chang YT, Tien YW, et al. T-cell regulatory gene CTLA-4 polymorphism/haplotype association with autoimmune pancreatitis. Clin Chem 2007;53: 1700-5.
40. Umemura T, Ota M, Hamano H, et al. Association of autoimmune pancreatitis with cytotoxic T-lymphocyte antigen 4 gene polymorphisms in Japanese patients. Am J Gastroenterol 2008;103:588-94.
41. Umemura T, Ota M, Hamano H, Katsuyama Y, Kiyosawa K, Kawa S. Genetic association of Fc receptor-like 3 polymorphisms with autoimmune pancreatitis in Japanese patients. Gut 2006;55:1367-8.
42. Guarneri F, Guarneri C, Benvenga S. Helicobacter pylori and autoimmune pancreatitis: role of carbonic anhydrase via molecular mimicry? J Cell Mol Med 2005; 9:741-4.
43. Frulloni L, Lunardi C, Simone R, et al. Identification of a novel antibody associated with autoimmune pancreatitis. N Engl J Med 2009;361:2135-42.
44. Akitake R, Watanabe T, Zaima C, et al. Possible involvement of T helper type 2 responses to Toll-like receptor ligands in IgG4-related sclerosing disease. Gut 2010; 59:542-5.
45. Aparisi L, Farre A, Gomez-Cambronero L, et al. Antibodies to carbonic anhydrase and IgG4 levels in idiopathic chronic pancreatitis: relevance for diagnosis of autoimmune pancreatitis. Gut 2005;54: 703-9.
46. Asada M, Nishio A, Uchida K, et al. Identification of a novel autoantibody against pancreatic secretory trypsin inhibitor in patients with autoimmune pancreatitis. Pancreas 2006;33:20-6.
47. Löhr JM, Faissner R, Koczan D, et al. Autoantibodies against the exocrine pancreas in autoimmune pancreatitis: gene and protein expression profiling and immunoassays identify pancreatic enzymes as a major target of the inflammatory process. Am J Gastroenterol 2010;105: 2060-71.
48. Yamamoto M, Naishiro Y, Suzuki C, et al. Proteomics analysis in 28 patients with systemic IgG4-related plasmacytic syndrome. Rheumatol Int 2010;30:565-8.
49. Cornell LD, Chicano SL, Deshpande V, et al. Pseudotumors due to IgG4 immune-complex tubulointerstitial nephritis associated with autoimmune pancreatocentric disease. Am J Surg Pathol 2007;31:1586-97.
50. Detlefsen S, Sipos B, Zhao J, Drewes AM, Kloppel G. Autoimmune pancreatitis: expression and cellular source of profibrotic cytokines and their receptors. Am J Surg Pathol 2008;32:986-95.
51. Detlefsen S, Brasen JH, Zamboni G, Capelli P, Kloppel G. Deposition of complement C3c, immunoglobulin (Ig)G4 and IgG at the basement membrane of pancreatic ducts and acini in autoimmune pancreatitis. Histopathology 2010;57:825-35.
52. Zen Y, Fujii T, Harada K, et al. Th2 and regulatory immune reactions are increased in immunoglobin G4-related sclerosing pancreatitis and cholangitis. Hepatology 2007;45:1538-46.
53. Miyake K, Moriyama M, Aizawa K, et al. Peripheral CD4+ T cells showing a Th2 phenotype in a patient with Mikulicz's disease associated with lymphadenopathy and pleural effusion. Mod Rheumatol 2008;18:86-90.
54. Kudo-Tanaka E, Nakatsuka S, Hirano T, et al. A case of Mikulicz's disease with Th2-biased cytokine profile: possible feature discriminable from Sjögren's syndrome. Mod Rheumatol 2009;19:691-5.
55. Kanari H, Kagami S, Kashiwakuma D, et al. Role of Th2 cells in IgG4-related lacrimal gland enlargement. Int Arch Allergy Immunol 2010;152:Suppl 1:47-53.
56. Kamisawa T, Anjiki H, Egawa N, Kubota N. Allergic manifestations in autoimmune pancreatitis. Eur J Gastroenterol Hepatol 2009;21:1136-9.
57. Miyoshi H, Uchida K, Taniguchi T, et al. Circulating naive and CD4+CD25high regulatory T cells in patients with autoimmune pancreatitis. Pancreas 2008;36:133-40.
58. Sakaguchi S, Ono M, Setoguchi R, et al. Foxp3+CD25+CD4+ natural regulatory T cells in dominant self-tolerance and autoimmune disease. Immunol Rev 2006; 212:8-27.
59. Raina A, Yadav D, Krasinskas AM, et al. Evaluation and management of autoimmune pancreatitis: experience at a large US center. Am J Gastroenterol 2009; 104:2295-306.
60. Nishimori I, Tamakoshi A, Otsuki M. Prevalence of autoimmune pancreatitis in Japan from a nationwide survey in 2002. J Gastroenterol 2007;42:Suppl 18:6-8.
61. Zen Y, Onodera M, Inoue D, et al. Retroperitoneal fibrosis: a clinicopathologic study with respect to immunoglobulin G4. Am J Surg Pathol 2009;33:1833-9.
62. Raissian Y, Nasr SH, Larsen CP, et al. Diagnosis of IgG4-related tubulointerstitial nephritis. J Am Soc Nephrol 2011; 22:1343-52.
63. Yamamoto M, Harada S, Ohara M, et al. Clinical and pathological differences between Mikulicz's disease and Sjögren's syndrome. Rheumatology (Oxford) 2005; 44:227-34.
64. Sah RP, Pannala R, Chari ST, et al. Prevalence, diagnosis, and profile of autoimmune pancreatitis presenting with features of acute or chronic pancreatitis. Clin Gastroenterol Hepatol 2010;8:91-6.
65. Shimosegawa T, Kanno A. Autoimmune pancreatitis in Japan: overview and perspective. J Gastroenterol 2009;44:503-17.
66. Akahane C, Takei Y, Horiuchi A, Kawa S, Nishimori I, Ikeda S. A primary Sjögren's syndrome patient with marked swelling of multiple exocrine glands and sclerosing pancreatitis. Intern Med 2002; 41:749-53.
67. Yadav D, Notahara K, Smyrk TC, et al. Idiopathic tumefactive chronic pancreatitis: clinical profile, histology, and natural history after resection. Clin Gastroenterol Hepatol 2003;1:129-35.

The New England Journal of Medicine
Downloaded from nejm.org at BIBLIOSAN remote cilea clas on March 19, 2012. For personal use only. No other uses without permission.
Copyright © 2012 Massachusetts Medical Society. All rights reserved.

68. Tsubata Y, Akiyama F, Oya T, et al. IgG4-related chronic tubulointerstitial nephritis without autoimmune pancreatitis and the time course of renal function. Intern Med 2010;49:1593-8.
69. Kamisawa T, Shimosegawa T, Okazaki K, et al. Standard steroid treatment for autoimmune pancreatitis. Gut 2009;58:1504-7.
70. Comings DE, Skubi KB, Van Eyes J, Motulsky AG. Familial multifocal fibrosclerosis: findings suggesting that retroperitoneal fibrosis, mediastinal fibrosis, sclerosing cholangitis, Riedel's thyroiditis, and pseudotumor of the orbit may be different manifestations of a single disease. Ann Intern Med 1967;66:884-92.
71. Levy MJ, Wiersema MJ, Chari ST. Chronic pancreatitis: focal pancreatitis or cancer? Is there a role for FNA/biopsy? Autoimmune pancreatitis. Endoscopy 2006;38:Suppl 1:S30-S35.
72. Kamisawa T, Okamoto A. Autoimmune pancreatitis: proposal of IgG4-related sclerosing disease. J Gastroenterol 2006;41:613-25.
73. Björnsson E. Immunoglobulin G4-associated cholangitis. Curr Opin Gastroenterol 2008;24:389-94.
74. Stone JH, Khosroshahi A, Deshpande V, Stone JR. IgG4-related systemic disease accounts for a significant proportion of thoracic lymphoplasmacytic aortitis cases. Arthritis Care Res (Hoboken) 2010;62:316-22.
75. Kasashima S, Zen Y, Kawashima A, et al. Inflammatory abdominal aortic aneurysm: close relationship to IgG4-related periaortitis. Am J Surg Pathol 2008;32:197-204.
76. Khosroshahi A, Carruthers M, Deshpande V, Unizony S, Bloch DB, Stone JH. Rituximab for the treatment of IgG4-related disease: lessons from ten consecutive patients. Medicine (Baltimore) 2012;91:57-66.
77. Takahashi N, Kawashima A, Fletcher JG, Chari ST. Renal involvement in patients with autoimmune pancreatitis: CT and MR imaging findings. Radiology 2007;242:791-801.
78. Sahani DV, Kalva SP, Farrell J, et al. Autoimmune pancreatitis: imaging features. Radiology 2004;233:345-52.
79. Inoue D, Zen Y, Abo H. Immunoglobulin G4-related periaortitis and periarteritis: CT findings in 17 patients. Radiology 2011;251:625-33.
80. Chari ST, Kloeppel G, Zhang L, Notohara K, Lerch MM, Shimosegawa T. Histopathologic and clinical subtypes of autoimmune pancreatitis: the Honolulu consensus document. Pancreas 2010;39:549-54.
81. Ghazale A, Chari ST, Smyrk TC, et al. Value of serum IgG4 in the diagnosis of autoimmune pancreatitis and in distinguishing it from pancreatic cancer. Am J Gastroenterol 2007;102:1646-53.
82. Umemura T, Zen Y, Hamano H, Kawa S, Nakanuma Y, Kiyosawa K. Immunoglobin G4-hepatopathy: association of immunoglobin G4-bearing plasma cells in liver with autoimmune pancreatitis. Hepatology 2007;46:463-71.
83. Nishino T, Toki F, Oyama H, Shimizu K, Shiratori K. Long-term outcome of autoimmune pancreatitis after oral prednisolone therapy. Intern Med 2006;45:497-501.
84. Ghazale A, Chari ST, Zhang L, et al. Immunoglobulin G4-associated cholangitis: clinical profile and response to therapy. Gastroenterology 2008;134:706-15.
85. Cheuk W, Yuen HK, Chu SY, Chiu EK, Lam LK, Chan JK. Lymphadenopathy of IgG4-related sclerosing disease. Am J Surg Pathol 2008;32:671-81.
86. Sato Y, Kojima M, Takata K, et al. Multicentric Castleman's disease with abundant IgG4-positive cells: a clinical and pathological analysis of six cases. J Clin Pathol 2010;63:1084-9.
87. Kamisawa T, Okazaki K, Kawa S, et al. Japanese consensus guidelines for management of autoimmune pancreatitis. III. Treatment and prognosis of AIP. J Gastroenterol 2010;45:471-7.
88. Khosroshahi A, Bloch DB, Deshpande V, Stone JH. Rituximab therapy leads to rapid decline of serum IgG4 levels and prompt clinical improvement in IgG4-related systemic disease. Arthritis Rheum 2010;62:1755-62.

Copyright © 2012 Massachusetts Medical Society.

CLINICAL TRIAL REGISTRATION

The *Journal* requires investigators to register their clinical trials in a public trials registry. The members of the International Committee of Medical Journal Editors (ICMJE) will consider most reports of clinical trials for publication only if the trials have been registered. Current information on requirements and appropriate registries is available at www.icmje.org/faq_clinical.html.

The New England Journal of Medicine
Downloaded from nejm.org at BIBLIOSAN remote cilea clas on March 19, 2012. For personal use only. No other uses without permission.
Copyright © 2012 Massachusetts Medical Society. All rights reserved.