CASE REPORT
Iran J Allergy Asthma Immunol
December 2005; 4(4): 193-195

Allergic Fungal Sinusitis Presenting as a Paranasal Sinus Tumor

Mohammad Javad Ashraf[1], Negar Azarpira[1], Mehrzad Pourjafar[2], and Bijan Khademi[3]

[1] *Department of Pathology, School of Medicine, Shiraz University of Medical Sciences, Shiraz, Iran*
[2] *Department of Neurology, School of Medicine, Shiraz University of Medical Sciences, Shiraz, Iran*
[3] *Department of Otolaryngology, School of Medicine, Shiraz University of Medical Sciences, Shiraz, Iran*

ABSTRACT

We present a case of allergic fungal sinusitis (AFB) in a 20-year old man with few months' history of bilateral nasal obstruction and discharge with unilateral proptosis that underwent maxillary antrostomy due to the mass in paranasal sinuses. Histological examination of tissue showed branching fungal hyphae interspersed with allergic mucin without fungal invasion to soft tissue. The patient received local steroid for 4 months and had no problem during follow up. Fungal culture was performed and Bipolaris fungus grew.

Although most dematiaceous fungal infections occur in immunocompetent patients, the incorrect diagnosis and insufficient treatment may be life threatening.

Key words: Allergy; Fungal; Sinusitis; Tumor

INTRODUCTION

Four distinct histologic categories of fungal sinusitis (FS) have been recognized: allergic, noninvasive fungal colonization (mycetoma or "fungus ball"); chronic invasive; and acute fulminant. Histological features, which were highly sensitive and specific for the diagnosis of allergic FS, included: eosinophilic mucin with Charcot-Leyden crystals and collections of degenerating eosinophils. Allergic mucin is very characteristic but not pathognomonic for allergic fungal sinusitis.

In chronic noninvasive fungal sinusitis, the fungi themselves consist of hyphae without spores and show septation with branching at 45° angles. These fungal balls are easily identifiable by Hematoxylin and Eosin staining (H&E) and do not invade mucosal tissue in any case. In contrast to the case of allergic fungal sinusitis, mucin is scant or absent in these cases.

In chronic invasive fungal sinusitis a nonspecific, non necrotizing granulomas, which interestingly contains eosinophils is commonly seen, no fungal hyphae are found within these mucosal granulomas.

In acute invasive fungal sinusitis vascular invasion by numerous fungal hyphae are present.

Thus special stains for fungi should always be performed when allergic mucin is seen, which reveals fungal hyphae in ≤85% of cases.[1-5]

We present here a case of allergic fungal sinusitis (AFB), who underwent maxillary antrostomy due to the mass in paranasal sinuses.

CASE REPORT

A 20-year old man from Shiraz presented with 6 months history of bilateral nasal obstruction with discharge and a 3 week history of painless proptosis in the left eye. He had no past history of asthma or atopy but had an elevated IgE level (more than 200 IU, normal range: less than 100 IU).

Corresponding Author: Negar Azarpira, MD;
Department of Pathology, Transplant Research Center, Nemazi Hospital, Shiraz University of Medical Sciences, P.O.Box: 71935-1119, Shiraz, Iran. Tel-Fax: (+98 711) 627 6211, E-mail: negarazarpira@yahoo.com

Copyright © 2005, IRANIAN JOURNAL OF ALLERGY, ASTHMA AND IMMUNOLOGY. All rights reserved.

A magnetic resonance imaging (MRI) of paranasal sinuses showed an expansile mass with ring enhancement present in the left maxillary sinuses with extension to ethmoidal and frontal sinuses. Left sided retro orbital space was involved with proptosis of the left eye. (Figure 1). Because of the possibility of a tumoral lesion, the patient referred to otolaryngologist and underwent maxillary antrostomy and specimen was sent for culture and histological examination. Grossly the specimen composed of fragments of gray-brown color tissue with gelatinous cut surface, measuring 2×2×2 cm. The histological features showed mucosal tissue with edema and chronic inflammation, which was composed of eosinophils, plasma cells, lymphocytes in various combination and rare neutrophils. Eosinophilic mucin with charcot-leyden crystals and collection of degenerating eosiniphils that are sensitive and specific for diagnosis of allergic fungal sinusitis were presented in this case (Figures 2 and 3).

Fragmented fungal hyphea was obvious in H&E stain that was confirmed by Periodic acid Schiff stain (PAS) (Figure 4). Culture of tissue material revealed Dematiaceous Bipolaris. The patient underwent endoscopic surgery and the clearance of all affected sinuses was performed. Medical treatment comprised of local and systemic corticosteroids.

In the clinical follow-up, total serum IgE level had decreased. The patient has done well, with no evidence of recurrent disease.

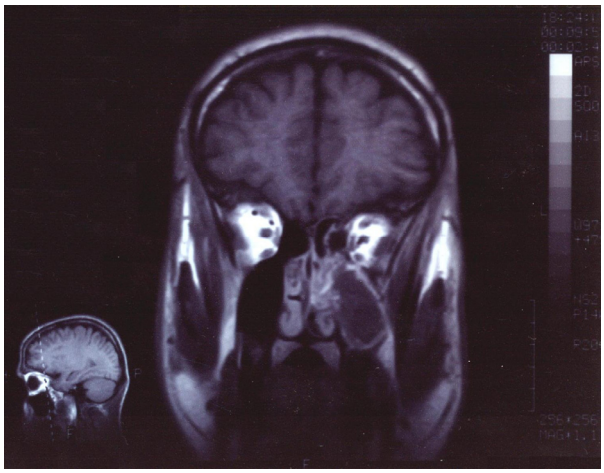

Figure 1. Magnetic resonance image showing a large nonhomogenous hypoechoic mass with enhancement after gadolinium injection in left maxillary sinus with some cortical bone erosion.

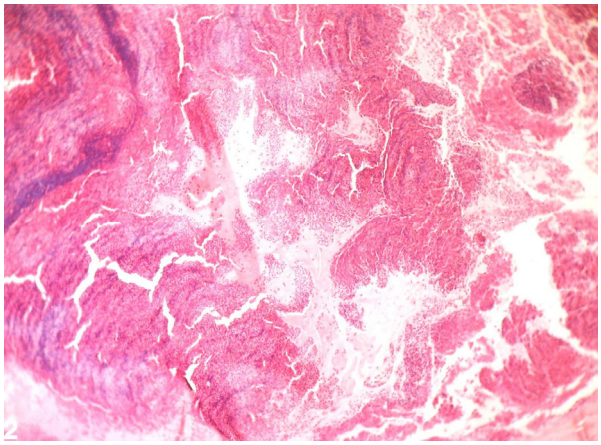

Figure 2. So called allergic mucin with characteristic lamination pattern of eosinophils and nuclear debris embedded in mucin material. (Hematoxylin- Eosin ×200)

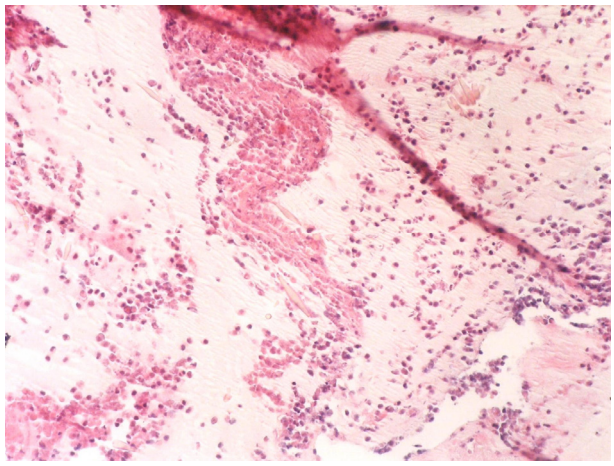

Figure 3. Many Charcot Leyden crystals in allergic mucin. (Hematoxylin- Eosin ×400)

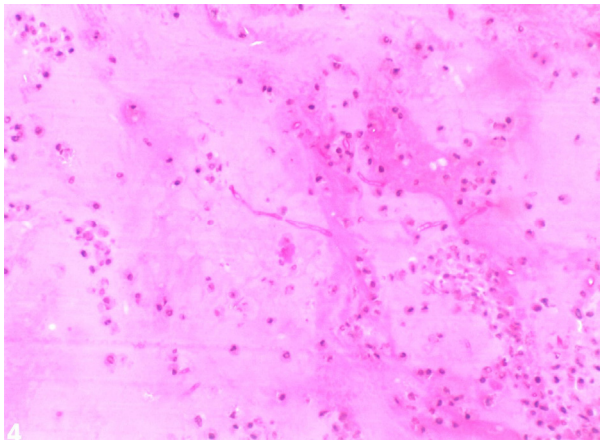

Figure 4. Septated fungal hyphea. (Periodic acid Schiff stain ×400)

DISCUSSION

Four distinct histologic categories of fungal sinusitis have been recognized: allergic, noninvasive fungal colonization (mycetoma or "fungus ball"); chronic invasive; and acute fulminant. Histological features, which were highly sensitive and specific for the diagnosis of allergic FS, included: eosinophilic mucin with Charcot-Leyden crystals and collections of degenerating eosinophils. Allergic mucin is very characteristic but not pathognomonic for allergic fungal sinusitis.

In chronic noninvasive fungal sinusitis, the fungi themselves consist of hyphae without spores and show septation with branching at 45° angles. These fungal balls are easily identifiable by H&E staining and do not invade mucosal tissue in any case. In contrast to the case of allergic fungal sinusitis, mucin is scant or absent in these cases.

In chronic invasive fungal sinusitis a nonspecific, non necrotizing granulomas, which interestingly contains eosinophils is commonly seen, no fungal hyphae are found within these mucosal granulomas.

In acute invasive fungal sinusitis vascular invasion by numerous fungal hyphae are present.

Thus special stains for fungi should always be performed when allergic mucin is seen, which that reveals fungal hyphae in ≤85% of cases.[1-5]

The role of fungal culture in the diagnosis of fungal sinusitis is not established. Culture is needed to identify fungal species, because in tissue sections fungi are either scanty or morphologically nonspecific.[1] The culture results have shown that the fungi most often identified in allergic fungal sinusitis are dematiaceous types, but Aspergillus is most commonly isolated in mycetoma.[1]

The dematiaceous (brown-pigmented) fungi are a large and heterogeneous group of moulds that cause a wide range of diseases including phaeohyphomycosis, chromoblastomycosis, and eumycotic mycetoma. Among the more important human pathogens are Alternaria species, Bipolaris species, Cladophialophora Bantiana,and Curvularia species. These organisms are widespread in the environment, being found in soil, wood, and decomposing plant debris. Cutaneous, subcutaneous, and corneal infections with dematiaceous fungi occur worldwide, but are more common in tropical and subtropical climates.[8]

The Fontana masson stain distinguishes dematiaceous fungus from aspergillus or zygomycetes due to melanin pigment in the former.[2,6,7]

It is important for patient management that not only that fungal sinusitis is diagnosed as a cause of chronic sinusitis but that specific histologic category is identified.

As well invasive fungal sinusitis, usually found in immunosuppressed or diabetic patients, can be fatal and necessitates vigorous systemic antifungal therapy. In contrast, allergic fungal sinusitis does not require antifungal medication but should be treated aggressively for the underlying allergy, perhaps including postoperative corticosteroids and total serum IgE monitoring, to reduce the clinical symptoms and prevent frequent recurrence.[8,9] Anti-leukotrienes are also being used for allergic fungal sinusitis.[10]

REFERENCES

1. Granville L, Chirala M, Cernoch P, Ostrowski M, Truong LD. Fungal sinusitis: histologic spectrum and correlation with culture. Hum Pathol 2004; 35(4):474-81.
2. Torres C, Ro JY, el-Naggar AK, Sim SJ, Weber RS, Ayala AG. Allergic fungal sinusitis: a clinicopathologic study of 16 cases. Hum Pathol 1996; 27(8):793-9.
3. Lara JF, Gomez JD. Allergic mucin with and without fungus: A comparative clinicopathologic analysis. Arch Pathol Lab Med 2001; 125(11):1442-7.
4. DeShazo RD, Swain RE. Diagnostic criteria for allergic fungal sinusitis. J Allergy Clin Immunol 1995; 96(1):24-35.
5. Ponikau JU, Sherris DA, Kern EB, Homburger HA, Frigas E, Gaffey TA, et al. The diagnosis and incidence of allergic fungal sinusitis. Mayo Clin Proc 1999; 74(9):877-84.
6. Brandwein M. Histopathology of sinonasal fungal disease. Otolaryngol Clin North Am 1993; 26(6):949-81.
7. Chang WJ, Shields CL, Shields JA, DePotter PV, Schiffman R, Eagle RC Jr, et al. Bilateral orbital involvement with massive allergic fungal sinusitis. Arch Ophthalmol 1996; 114(6):767-8.
8. Schubert MS, Goetz DW. Evaluation and treatment of allergic fungal sinusitis. I. Demographics and diagnosis. J Allergy Clin Immunol 1998; 102(3):387-94
9. Schubert MS, Goetz DW. Evaluation and treatment of allergic fungal sinusitis. II Treatment and follow-up. J Allergy Clin Immunol 1998; 102(3): 395-402
10. Schubert MS. Antileukotriene therapy for allergic fungal sinusitis. J Allergy Clin Immunol 2001; 108(3):466-7.