UC Davis
Dermatology Online Journal

Title
Crohn disease-associated neutrophilic urticarial dermatosis: report and literature review of neutrophilic urticarial dermatosis

Permalink
https://escholarship.org/uc/item/3mq1b1cx

Journal
Dermatology Online Journal, 23(11)

Authors
Hou, Zhe
Hinds, Brian R
Cohen, Philip R

Publication Date
2017-01-01

License
CC BY-NC-ND 4.0

Peer reviewed

eScholarship.org Powered by the California Digital Library
University of California

Volume 23 Number 11 | November 2017
23 (11): 13

Crohn disease-associated neutrophilic urticarial dermatosis: report and literature review of neutrophilic urticarial dermatosis

Zhe Hou MD PhD, Brian R Hinds MD, Philip R Cohen MD

Affiliations: Department of Dermatology, University of California San Diego, La Jolla, California

Corresponding Authors: Philip R. Cohen MD, 10991 Twinleaf Court, San Diego, CA 92131, Email: mitehead@gmail.com; Zhe Hou MD PhD, 8899 University Center Lane, Suite 350, San Diego, CA 92122, Email: z5hou@ucsd.edu

Abstract

Neutrophilic urticarial dermatosis (NUD) is a useful diagnostic term for urticarial lesions that are less pruritic and more painful than conventional urticaria. The histopathologic features include neutrophilic infiltrates in the interstitial dermis with a higher density than idiopathic urticaria. NUD has been associated with several systemic conditions, which are predominantly autoimmune and autoinflammatory in nature. A woman with Crohn disease who developed NUD is described. Literature reports of other conditions in which neutrophilic urticarial dermatosis have been observed are also reviewed and summarized. NUD has not only been described in the setting of inflammatory bowel disease, but also in patients who have systemic lupus erythematosus, adult-onset Still disease, and IgA gammopathy. NUD is usually associated with an underlying disease. Therapeutic agents that target neutrophils (such as dapsone and colchicine) and antagonists to interleukin-1 receptor (such as anakinra) may be effective modalities for affected patients. NUD can be added to the list of dermatologic manifestations associated with systemic inflammation, particularly inflammatory bowel disease.

Keywords: neutrophilic, dermatosis, urticarial, systemic, inflammation, Crohn disease, inflammatory bowel disease, lupus erythematosus

Introduction

Neutrophilic urticarial dermatosis (NUD) presents with urticarial lesions that exhibit clinical features that stray from conventional urticaria, typically with less pruritus, more pain, and recalcitrance to antihistamine therapy. Evanescent, edematous papules and plaques restricted to conventional urticaria are usually not a feature of NUD. Histopathologically, an interstitial neutrophilic infiltrate is the common denominator with variation in the density of inflammation and collagen alteration. NUD may occasionally exhibit leukocytoclasia, but vasculitis is not present [1-15]. The condition is often associated with several systemic diseases [1]. A woman with Crohn disease who developed neutrophilic urticarial dermatosis is described and the conditions associated with NUD are summarized.

Case Synopsis

A 31-year-old woman presented with an asymptomatic rash on her arms, hands, and thighs of two-weeks duration. Systemic symptoms associated with the onset of her skin lesions included fever, abdominal pain, nausea and vomiting, and joint pain. Her past medical history was significant for Crohn disease and dyskeratosis congenita, status-post bone marrow transplantation. She was not receiving immunomodulatory or systemic therapy.

Physical examination revealed erythematous smooth-topped papules and thin plaques scattered on the arms, dorsal hands, and proximal thighs. There was no associated scale, ulceration, or tenderness. Two small disciform erythematous plaques merged to form a larger plaque on her left proximal arm (**Figure 1**). Skin biopsies were performed on the right upper arm for microscopic examination and tissue culture.

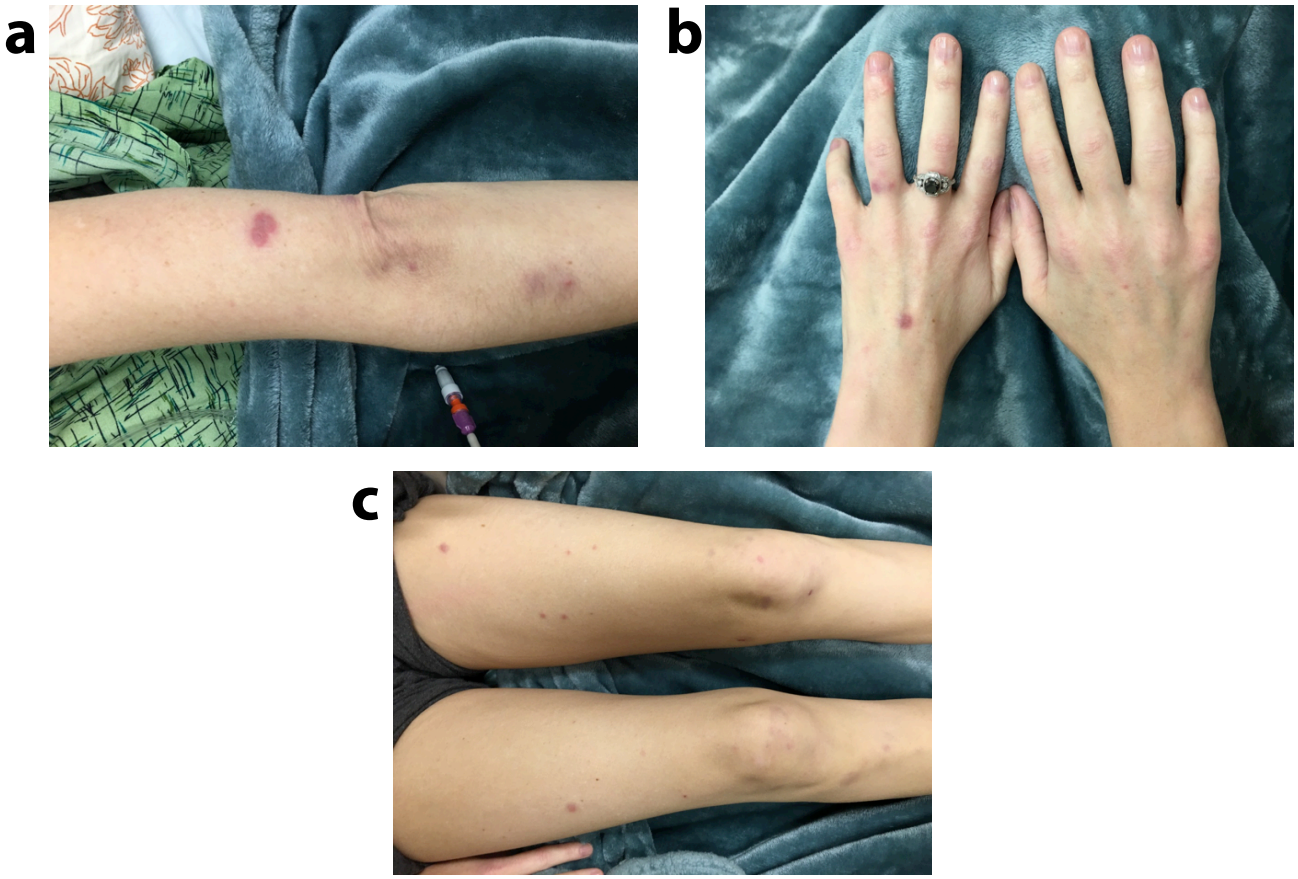

Figure 1. *Neutrophilic urticarial dermatosis presents as erythematous papules and plaques on arms A), dorsal hands B) and proximal thighs C) of a 31-year-old woman with Crohn disease.*

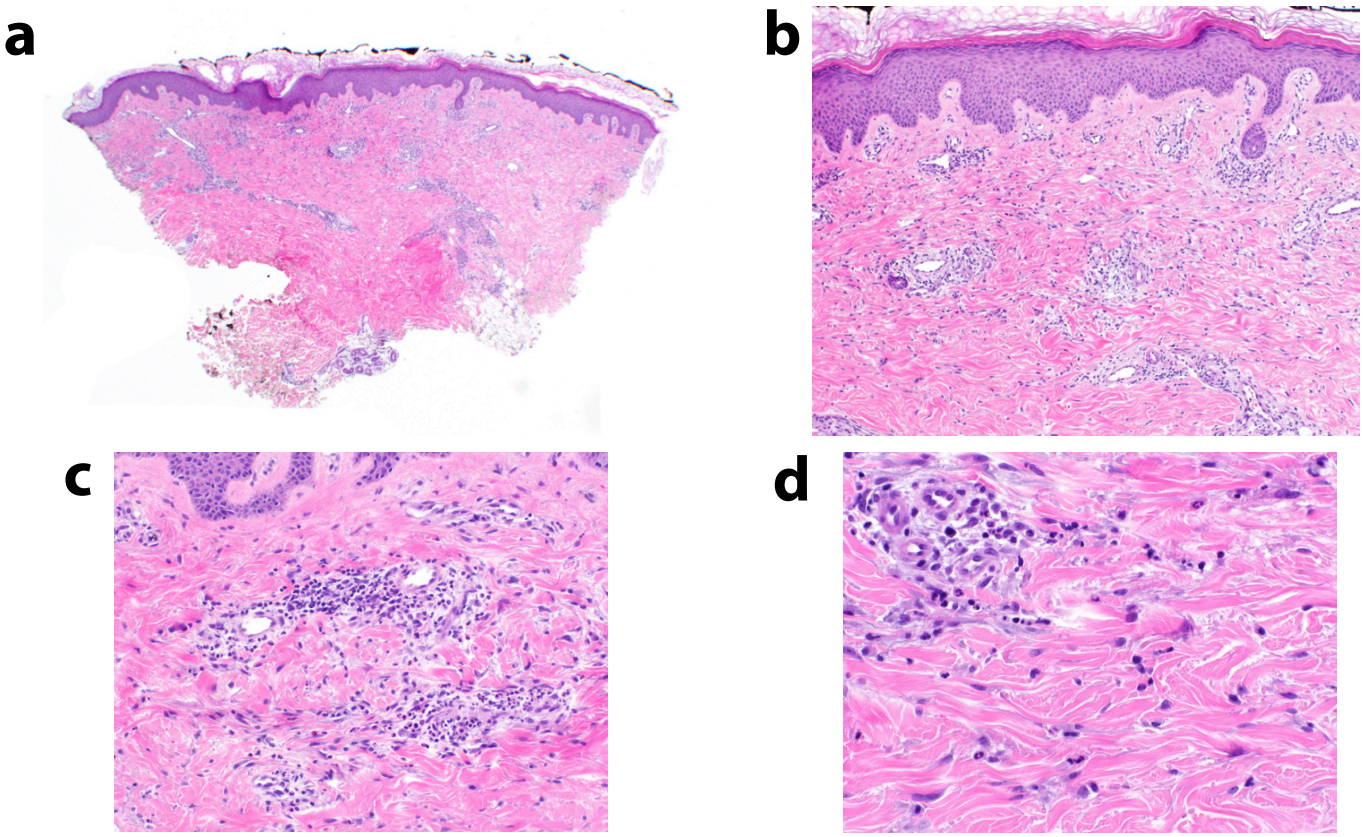

Figure 2. *Low A), medium B and C) and high D) magnification views of a lesional skin biopsy show interstitial pattern of neutrophilic infiltrate with mild leukocytoclasis. Neither dermal edema nor vasculitis is present (H&E, A, 2%; B, 10%; C, 20%; and D, 40%).*

Microscopic examination showed perivascular and interstitial neutrophilic infiltrates with focal leukocytoclasis and intercalation between collagen bundles, yet without vasculitis or pronounced extravasation of erythrocytes (**Figure 2**). Neutrophilic epitheliotropism was not present. Tissue culture was negative for bacteria, fungus, and mycobacteria. Correlation of the clinical history, lesion morphology, and pathologic changes established a diagnosis of Crohn disease-associated neutrophilic urticarial dermatosis.

Her gastrointestinal symptoms were consistent with a flare of her Crohn disease. She received a single oral dose of 40 mg prednisone. Her systemic symptoms, Crohn disease flare, and skin lesions all resolved within 4 days.

Case Discussion

The diagnostic term "neutrophilic urticarial dermatosis" was coined by Kieffer et al. in 2009 when they described this condition in 9 patients [1]. Subsequently, Belani et al. suggested a different diagnostic term for the same entity, "neutrophilic urticaria with systemic inflammation" (NUSI), based on two patients with systemic inflammation, but without known connective disease [2].

The association of lesions clinically presenting with features of urticaria and histologically demonstrating neutrophilic inflammation was described initially by Peters and Winkelman in 1985 [3]. Ultimately, the latter scenario reflects "neutrophilic urticaria," which is a term for conventional chronic urticaria that responds to antihistamines and features normocomplementemia, negative direct immunofluorescence, and a lack of systemic disease. NUD/NUSI is within a spectrum of parainflammatory neutrophilic dermatoses, as opposed to idiopathic chronic urticaria. The association of NUD with systemic disorders, including systemic lupus erythematosus, adult-onset Still disease, and Schnitzler syndrome, was recognized by Kieffer et al. [1]. Later Gusdorf et al. described neutrophilic urticarial dermatosis in 7 patients with lupus erythematosus [4].

NUD-associated systemic conditions are summarized in **Table 1** [1, 4-6, 8-15]. There are more than 39 individuals with this dermatosis reported in the literature to date. The most commonly associated condition is systemic lupus erythematosus. In these patients, the dermatosis presents in conjunction with constitutional symptoms, such as fever and joint pain, as well as renal involvement. The latter suggests underlying immune-complex mediated systemic inflammation. To our knowledge, NUD associated with inflammatory bowel disease has only been previously described in one other woman in the literature [5].

NUD may be polymorphous, but often presents with erythematous macules, papules, or plaques, some of which may be confluent. Importantly, in contrast to urticaria, the lesions lack pruritus or are only mildly pruritic, lack an annular configuration, and lack pronounced edema. The lesions most frequently occur on the trunk and extremities and may urticate, but patients lack facial swelling or angioedema. Similar to our patient, associated symptoms such as fever and joint pain may occur. The clinical differential diagnosis of NUD is listed in **Table 2**.

Histopathologic features observed in NUD lesions typically include interstitial and/or perivascular neutrophils with a density that is higher than idiopathic urticaria. Some authorities consider NUD to be a cutaneous reaction pattern sharing histopathologic attributes that reflect common denominators of neutrophilic urticaria (i.e. interstitial neutrophils) and urticarial vasculitis (i.e. leukocytoclasia and diapedesis of neutrophils). Leukocytoclasis may be seen in NUD and neutrophils often intercalate between collagen bundles in a linear fashion and occasionally permeate near the dermal epidermal junction with so-called neutrophilic epitheliotropism, the latter of which is a clue to NUD [5]. Neither dermal edema nor vacuolar interface changes are present. Necrobiotic collagen bundles have been noted in lesions from some individuals [1, 5]. Vasculitis with fibrinoid necrosis is absent, which helps to distinguish the condition from urticarial leukocytoclastic vasculitis. An absence of neutrophils in a periadnexal, or more specifically peri-eccrine pattern, helps to exclude cryopyrin-associated autoinflammatory disease [5].

The diagnosis of NUD requires careful correlation of not only the patient's clinical symptoms, but also the morphology and histopathology to arrive at the

Table 1. *Systemic diseases associated with neutrophilic urticarial dermatosis [1, 4-6, 8-15].*

Systemic disease associated with neutrophilic urticarial dermatosis	Reference
Chronic myelogenous leukemia	[8]
Cryopyrin-associated periodic syndrome	[5, 6, 9]
Inflammatory bowel disease	[5, current report]
Primary biliary cirrhosis	[5]
Rheumatoid arthritis	[10]
Schnitzler syndrome	[1, 5, 6, 11]
Sjögren syndrome	[5, 10]
Still disease	[1, 5, 12-14]
Systemic lupus erythematosus	[1, 4, 5, 10, 15]

Table 2. *Clinical differential diagnosis of neutrophilic urticarial dermatosis.*

Clinical differential diagnosis of neutrophilic urticarial dermatosis
Autoimmunity-related neutrophilic dermatosis
Sweet syndrome (acute febrile neutrophilic dermatosis)
Urticarial vasculitis

proper diagnosis. In patients for whom the diagnosis of NUD is established, evaluations for potential underlying systemic disease should commence. This should include anti-nuclear antibody, anti-mitochondrial antibody, anti-Sjögren syndrome A (Ro) and anti- Sjögren syndrome B (La) antibodies, urine and serum protein electrophoresis, erythrocyte sedimentation rate, C-reactive protein, and cryopyrin.

The pathogenesis of NUD may be mediated by mast cell interleukin-1, neutrophil interleukin-17, and epidermal antimicrobial proteins [6]. Individuals with neutrophilic urticarial dermatosis that was associated with either adult-onset Still disease or an unknown connective tissue disorder have responded to anakinra (an interleukin-1 receptor antagonist). Hence, interleukin-1 may be an important mediator in neutrophilic urticarial dermatosis [2, 6].

NACHT, LRR, and PYD domains-containing protein 3 (NLRP3) inflammasome mediates processing and release of interleukin-1. Mutation of the NLRP3 gene has been found in NUD with cryopyrin-associated periodic syndrome [7].

Dapsone and colchicine have been shown to be effective in treating systemic lupus erythematosus-associated NUD [4]. Coupled with the clinical response observed in patients after IL-1 blockade, the inflammatory cascade in NUD seems to be upregulated by neutrophils influenced by the inflammasome pathway.

Conclusion

NUD is a condition typically associated with systemic conditions. Systemic lupus erythematosus is the most commonly associated disorder. Our case represents the second patient with Crohn disease associated NUD in the literature, to our knowledge. Clinical features that stray from conventional urticaria (i.e. pain, arthritis) and histopathologic features showing interstitial neutrophilic infiltrates should trigger a search for underlying systemic diseases. When such a condition is identified in association with NUD, treatment should primarily address the systemic condition. Neutrophil-targeting agents such as dapsone and colchicine, as well as interleukin-1 receptor antagonists, may also be effective as primary or adjuvant treatment modalities.

References

1. Kieffer C, Cribier B, Lipsker D. Neutrophilic urticarial dermatosis: a variant of neutrophilic urticaria strongly associated with systemic disease. Report of 9 new cases and review of the literature. *Medicine (Baltimore)*. 2009;88(1):23-31. [PMID: 19352297].
2. Belani H, Gensler L, Bajpai U, Meinhardt E, Graf J, Pincus L, Leslie KS. Neutrophilic urticaria with systemic inflammation: a case series. *JAMA Dermatol.* 2013;149(4):453-8. [PMID: 23715523].
3. Peters MS, Winkelmann RK. Neutrophilic urticaria. *Br J Dermatol.* 1985;113(1):25-30. [PMID: 4015969].
4. Gusdorf L, Bessis D, Lipsker D. Lupus erythematosus and neutrophilic urticarial dermatosis: a retrospective study of 7 patients. *Medicine (Baltimore).* 2014;93(29):e351. [PMID: 25546692].
5. Broekaert SM, Böer-Auer A, Kerl K, Herrgott I, Schulz X, Bonsmann G, Brehler R, Metze D. Neutrophilic epitheliotropism is a histopathological clue to neutrophilic urticarial dermatosis. *Am J Dermatopathol.* 2016;38(1):39-49. [PMID: 26317390].
6. de Koning HD, van Vlijmen-Willems IM, Rodijk-Olthuis D, van der Meer JW, Zeeuwen PL, Simon A, Schalkwijk J. Mast-cell interleukin-1β, neutrophil interleukin-17 and epidermal antimicrobial proteins in the neutrophilic urticarial dermatosis in Schnitzler's syndrome. *Br J Dermatol.* 2015;173(2):448-56. Epub 2015/07/20. [PMID: 25904179].
7. Herbert VG, Ahmadi-Simab K, Reich K, Böer-Auer A. Neutrophilic urticarial dermatosis (NUD) indicating cryopyrin-associated periodic syndrome associated with a novel mutation of the NLRP3 gene. *J Eur Acad Dermatol Venereol.* 2016;30(5):852-3. [PMID: 25732894].
8. Ainechi S, Carlson JA. Neutrophilic dermatosis limited to lipo-lymphedematous skin in a morbidly obese woman on dasatinib therapy. Am J Dermatopathol. 2016;38(2):e22-6. [PMID: 26825166].
9. Kolivras A, Theunis A, Ferster A, Lipsker D, Sass U, Dussart A, André J. Cryopyrin-associated periodic syndrome: an autoinflammatory disease manifested as neutrophilic urticarial dermatosis with additional perieccrine involvement. *J Cutan Pathol*. 2011;38(2):202-8. Epub 2010/11/10. [PMID: 21062341].
10. Saeb-Lima M, Charli-Joseph Y, Rodríguez-Acosta ED, Domínguez-Cherit J. Autoimmunity-related neutrophilic dermatosis: a newly described entity that is not exclusive of systemic lupus erythematosus. *Am J Dermatopathol.* 2013;35(6):655-60. [PMID: 23518639].
11. Asahina A, Sakurai N, Suzuki Y, Narushima K. Schnitzler's syndrome with prominent neutrophil infiltration misdiagnosed as Sweet's syndrome: a typical example of urticarial neutrophilic dermatosis. *Clin Exp Dermatol.* 2010;35(4):e123-6. Epub 2009/11/19. [PMID: 19925486].
12. Hartig I, Schroeder JO, Mrowietz U. Neutrophilic urticarial dermatosis (NUD) in probable adult-onset Still disease responding to anakinra. *J Clin Rheumatol.* 2014;20(2):96-8. [PMID: 24561414].
13. Sokumbi O, Drage LA, Peters MS. Clinical and histopathologic review of Schnitzler syndrome: the Mayo Clinic experience (1972-2011). *J Am Acad Dermatol.* 2012;67(6):1289-95. Epub 2012/05/22. [PMID: 22627038].
14. Gambichler T, Paech V, Rotterdam S, Stücker M, Boms S, Altmeyer P. Hepatitis B-assocciated adult-onset Still's disease presenting with neutrophilic urticaria. *Eur J Med Res.* 2003;8(12):527-30. [PMID: 14711598].
15. Hau E, Vignon Pennamen MD, Battistella M, Saussine A, Bergis M, Cavelier-Balloy B, Janier M, Cordoliani F, Bagot M, Rybojad M, Bouaziz JD. Neutrophilic skin lesions in autoimmune connective tissue diseases: nine cases and a literature review. *Medicine (Baltimore).* 2014;93(29):e346. [PMID: 25546688].