[Downloaded free from http://www.lungindia.com on Saturday, November 3, 2018, IP: 94.34.4.137]

Review Article

Childhood allergic bronchopulmonary aspergillosis

Kana Ram Jat, Pankaj C Vaidya[1], Joseph L Mathew[1], Sunil Jondhale[2], Meenu Singh[1]

Department of Pediatrics, All India Institute of Medical Sciences, New Delhi, [1]Department of Pediatrics, Postgraduate Institute of Medical Education and Research, Chandigarh, [2]Department of Pediatrics, All India Institute of Medical Sciences, Raipur, Chhattisgarh, India

ABSTRACT

Allergic bronchopulmonary aspergillosis (ABPA) is a pulmonary disease caused by *Aspergillus* induced hypersensitivity. It usually occurs in immunocompetent but susceptible patients with bronchial asthma and cystic fibrosis. If ABPA goes undiagnosed and untreated, it may progress to bronchiectasis and/or pulmonary fibrosis with significant morbidity and mortality. ABPA is a well-recognized entity in adults; however, there is lack of literature in children. The aim of the present review is to summarize pathophysiology, diagnostic criteria, clinical features, and treatment of ABPA with emphasis on the pediatric population. A literature search was undertaken through PubMed till April 30, 2018, with keywords "ABPA or allergic bronchopulmonary aspergillosis" with limitation to "title." The relevant published articles related to ABPA in pediatric population were included for the review. The ABPA is very well studied in adults. Recently, it is increasingly being recognized in children. There is lack of separate diagnostic criteria of ABPA for children. Although there are no trials regarding treatment of ABPA in children, steroids and itraconazole are the mainstay of therapy based on studies in adults and observational studies in children. Omalizumab is upcoming therapy, especially in refractory ABPA cases. There is a need to develop the pediatric-specific cutoffs for diagnostic criteria in ABPA. Well-designed trials are required to determine appropriate treatment regimen in children.

KEY WORDS: Allergic bronchopulmonary aspergillosis, children, itraconazole, omalizumab, steroids

Address for correspondence: Dr. Pankaj C Vaidya, Department of Pediatrics, Postgraduate Institute of Medical Education and Research, Chandigarh - 160 012, India. E-mail: dr_pcv@yahoo.com

INTRODUCTION

A number of *Aspergillus* species, particularly *Aspergillus fumigatus,* cause diseases in humans.[1] Depending on quantity and virulence of inhaled *Aspergillus*, and host's genetic susceptibility and immunity, *Aspergillus* can cause saprophytic (e.g., aspergilloma), invasive (especially in immunocompromised patients), or allergic (*Aspergillus*-mediated asthma, hypersensitivity pneumonia and allergic bronchopulmonary aspergillosis [ABPA]) pulmonary diseases.[2] ABPA is a pulmonary disease caused by *Aspergillus*-induced hypersensitivity. It usually occurs in immunocompetent but susceptible patients with bronchial asthma and cystic fibrosis (CF).[3-5] If ABPA goes undiagnosed and untreated, it may progress to bronchiectasis and/or pulmonary fibrosis with significant morbidity and mortality. ABPA was first described by Hinson *et al*. in 1952 in asthmatic subjects.[6] Since then, there have been many advances in the understanding of pathophysiology and various treatment options for ABPA. ABPA is well-recognized entity in adults. It is increasingly being recognized in children in recent years. ABPA is one of reasons for poorly controlled asthma with significant morbidity in children. The use of oral steroids, the mainstay treatment of ABPA, may cause adverse effects in growing children. The aim of the present review is to summarize pathophysiology, diagnostic criteria, clinical features,

Access this article online

Quick Response Code:

Website: www.lungindia.com

DOI: 10.4103/lungindia.lungindia_216_18

This is an open access journal, and articles are distributed under the terms of the Creative Commons Attribution-NonCommercial-ShareAlike 4.0 License, which allows others to remix, tweak, and build upon the work non-commercially, as long as appropriate credit is given and the new creations are licensed under the identical terms.

For reprints contact: reprints@medknow.com

How to cite this article: Jat KR, Vaidya PC, Mathew JL, Jondhale S, Singh M. Childhood allergic bronchopulmonary aspergillosis. Lung India 2018;35:499-507.

[Downloaded free from http://www.lungindia.com on Saturday, November 3, 2018, IP: 94.34.4.137]

and treatment of ABPA with emphasis on the pediatric population.

METHODS

A literature search was undertaken through PubMed till August 31, 2016, with key words "ABPA or allergic bronchopulmonary aspergillosis" with limitation to "title," The search was repeated on April 30, 2018, for relevant new articles. The relevant published articles, especially related to ABPA in pediatric population, were studied for writing this review.

EPIDEMIOLOGY

Although *A. fumigatus* is mostly responsible for ABPA,[7] other species of *Aspergillus* (*Aspergillus niger*, *Aspergillus flavus,* etc.) and other fungi (*Stemphylium lanuginosum*, *Helminthosporium* species, *Candida* species, etc.) have been occasionally reported in association with ABPA.[8] The disease caused by fungi other than *Aspergillus* is known as allergic bronchopulmonary mycosis (ABPM) and Candida albicans is most common cause for ABPM.[9] Out of many fungi, only few (*Aspergillus, Candida* etc.) causes human diseases including ABPA and ABPM because these are thermotolerant fungi which can grow both in environment and at body temperature whereas mesophilic fungi (that are unable to grow at body temperature) and thermophilic fungi (that are unable to grow in environment) do not cause ABPM.[10]

Agarwal *et al*.,[11] in a systematic review and meta-analysis, reported the prevalence of *Aspergillus* sensitization (AS) and ABPA in asthmatic adults of 28% (95% confidence interval [CI] 24–34) and 12.9% (95% CI 7.9–18.9), respectively. With time, there is increasing trend of ABPA prevalence in adults which may be due to increased awareness about ABPA among physicians and ready availability of laboratory investigations.[11]

ABPA in asthmatic children is not as common as in adults and it may be due to lack of well-conducted epidemiological studies in children. Slavin *et al*.[12] probably reported the first pediatric case of ABPA in 1970. Since then, there are case reports and small case series in asthmatic children.[13-22] Imbeau *et al*.[21] described the three youngest (<2 years of age) asthmatic children with ABPA. The one of the first prevalence study of ABPA in children was from India where ABPA was reported in 15% of children with perennial asthma and in 6.5% of total asthmatic children screened.[21] Recently, a study from North India in children with poorly controlled asthma reported prevalence of AS and ABPA as 29% and 26%, respectively.[23] Shah *et al*.[24] reported familial occurrence of ABPA in 4.9% of 164 patients. However, ABPA in asthmatic children seems to be underdiagnosed as latent period up to 10 years before diagnosis had been reported.[14]

ABPA in CF patients is not uncommon, even in pediatric age group. A systematic review including 64 studies reported the prevalence of ABPA in CF of 8.9% (95% CI: 7.4%–0.7%), and it was more in adults as compared to children (10.1% vs. 8.9%; $P < 0.0001$).[25] The studies including mainly CF children had reported the prevalence of ABPA from 4.7% to 10.0%.[26-30] The probable youngest CF child with ABPA had symptoms from the age of 11 months, though she was diagnosed with ABPA at age of 3.5 years.[31] A study from India, reported ABPA in 18.2% (95% CI: 6.9%–35.4%) children with CF.[32]

Although sensitization to *Aspergillus* is common in asthmatic and CF patients (20%–25% of asthmatic patients and 31%–59% of CF patients), only a small percentage of these patients develop ABPA.[3-5] A few authors tried to identify the risk factors for ABPA in CF children. Jubin *et al*.[33] reported an association between long-term azithromycin therapy and *Aspergillus* colonization (odds ratio = 6.4, 95% CI: 2.1–19.5). Ritz *et al*.[34] showed that bronchial colonization with Stenotrophomonas maltophilia was a risk factor for ABPA and higher cumulative doses of inhaled corticosteroids, and longer duration of *Pseudomonas aeruginosa* colonization were risk factors for *A. fumigatus* sensitization in CF children. In study from India, age more than 12 years, low-cystic fibrosis score, and presence of atopy and eosinophilia were risk factors for ABPA in CF children.[32]

ABPA had been described very rarely in nonasthmatic, non-CF children. Amin *et al*.[35] reported a case of ABPA in nonasthmatic 18 years male. Boz *et al*.[36] reported ABPA in a 11-year-old girl following active pulmonary tuberculosis. Recently, two cases of ABPA in children were reported with non-CF bronchiectasis.[37]

PATHOPHYSIOLOGY

Although underlying pathophysiology of ABPA is not yet clearly understood, *Aspergillus* spores adhere to preactivated epithelium in genetically susceptible patients with asthma or CF and grow into hyphae. After bronchial penetration, *Aspergillus* antigens activate immune response resulting in bronchial/bronchiolar inflammation and destruction.[3] The CD4+ Th2 cells along with their cytokines (especially interleukin [IL]-4) play an important role in pathogenesis of ABPA.[38]

Genetic factors

The balance between human leukocyte antigen (HLA)-antigen D-related molecules associated with susceptibility to ABPA (DR2, DR5, and possibly, DR4 or DR7) and resistance to ABPA (HLA-DQ2) determine the course of ABPA in patients with asthma and CF.[39] A number of genetic factors have also been identified in association with ABPA including CF transmembrane conductor regulator gene mutations,[40] SP-A2 (genes encoding surfactant protein-A),[41] IL-4 alpha-chain receptor polymorphisms,[42]

[Downloaded free from http://www.lungindia.com on Saturday, November 3, 2018, IP: 94.34.4.137]

IL-10 polymorphisms,[43] toll-like receptor polymorphisms,[44] integrin β3 polymorphisms,[45] chitinase polymorphisms,[46] A disintegrin and metalloprotease 33 gene,[47] protocadherin 1 polymorphisms,[48] and mannan-binding lectin[49] polymorphism.

The host factor may also play a role in colonization and penetration of *Aspergillus* into respiratory epithelium, for example, impaired mucus clearance in CF may contribute to greater bronchial adherence of *Aspergillus*.[28]

Why does ABPA develop only in a proportion of *Aspergillus* sensitive asthmatic and CF patients? Knutsen *et al*.[38] hypothesized that ABPA develops in genetically susceptible patients with asthma and CF who have increased frequency and/or activity of *A. fumigatus* specific CD4+ Th2 cells.

Pathology of allergic bronchopulmonary aspergillosis

In ABPA, there is cylindrical bronchiectasis of central airways especially those to upper lobes.[3,5,28] Pathological bronchial specimens in ABPA, although not necessary for diagnosis, shows bronchial tree dilatation and lumen filled with mucus plugs containing eosinophils, macrophages, Charcot–Leyden crystals, and occasionally hyphal fragments.[3,5]

DIAGNOSIS OF ALLERGIC BRONCHOPULMONARY ASPERGILLOSIS

The diagnostic criteria for ABPA are described in adults, and the same is used in pediatrics as there are no separate criteria for children. In 1977, Rosenberg–Patterson criteria[50] were proposed for diagnosis of ABPA [Table 1]. The criteria for diagnosis of ABPA in asthmatic patients were later modified by Greenberger.[5] Recently, Agarwal *et al*. proposed new diagnostic criteria in 2013[51] and later modified in 2016 [Table 1].[52] The simple cutaneous sensitivity test (skin prick test) may be a useful screening test, as ABPA is very unlikely in patients with a negative skin test.[40] The cutoffs of total IgE for ABPA in children

Table 1: Changing diagnostic criteria for allergic bronchopulmonary aspergillosis in asthma with time

Rosenberg-Patterson criteria 1977[50]	Greenberger criteria 2002[5]		Agarwal *et al*., 2013[51]	Agarwal *et al*., 2016[52]
ABPA very likely if first 6 of 7 primary fulfilled. ABPA certain if all primary 7 present	ABPA-central bronchiectasis	ABPA-seropositive	ABPA is diagnosed if all of following criteria are met	ABPA is diagnosed if all of following criteria are met
Primary	**Essential criteria**	**Essential criteria**		
1.Asthma	1. Asthma	1. Asthma	1. Predisposing condition-Asthma or cystic fibrosis	1. Predisposing condition-Asthma or cystic fibrosis, COPD, post-TB fibrocavitary disease
2. Peripheral blood eosinophilia (>1.0×10^9/L)				
3. Immediate cutaneous reactivity to *Aspergillus* antigen	2. Immediate skin sensitivity to *Aspergillus* species or AF#	2. Immediate skin sensitivity to *Aspergillus* species or AF	2. Obligatory criteria 1- Immediate skin sensitivity to Aspergillus or increased IgE against AF (>0.35 kUA/L)	2. Obligatory criteria 1- Increased IgE against AF (>0.35 kUA/L) If this not available, Immediate skin sensitivity to AF may be considered
4. Precipitating antibodies against *Aspergillus* antigen	3.Elevated serum IgE and/or IgG against AF	3. Elevated serum IgE and/or IgG against AF		
5. Elevated total serum IgE (>1000 ng/mL)	4. Total serum IgE conc. (>417 kU/L or >1000 ng/mL)	4. Total serum IgE concentration >417 kU/L (1000 ng/mL)	3. Obligatory criteria 2- Total serum IgE >1000 IU/ml (2400 ng/mL)	3. Obligatory criteria 2- Total serum IgE>1000 IU/ml (2400 ng/mL)
6. Chest X-ray infiltrates (transient or fixed)				
7. Central bronchiectasis	5. Central bronchiectasis			
Secondary	**Nonessential criteria**		**4. Other criteria: At least 2 of three**	**4. Other criteria: At least 2 of three**
1. *Aspergillus* fumigatus in sputum (by culture or microscopy)	1. Chest X-ray infiltrates	1. Chest X-ray infiltrates	1. Radiographic findings consistent with ABPA*	1. Radiographic findings consistent with ABPA*
2. History of brown plugs in sputum	2. Serum precipitating antibodies to AF		2. Serum precipitating or IgG antibodies to AF	2. Serum IgG >27 mg_A/L against AF
3. Late (Arthus) skin reaction to *Aspergillus* antigen			3. Increased total eosinophils (>500) may be historical	3. Increased total eosinophils (>500) may be historical

AF: *Aspergillus fumigatus*, Total IgE: 1 kU/L=2.4 ng/mL, 1 kU/L=1 IU/ml, *Transient (nodules, consolidation, tram-track sign, fleeting opacities, finger in glove/toothpaste opacities) or fixed (ring shadows, bronchiectasis, or fibrosis). AF: *Aspergillus fumigatus*, ABPA: Allergic bronchopulmonary aspergillosis, CF: Cystic fibrosis, CT: Computerized tomography

[Downloaded free from http://www.lungindia.com on Saturday, November 3, 2018, IP: 94.34.4.137]

are not well defined. A pediatric study from India suggested a cutoff of total IgE of 1200 IU/ml for ABPA in children.[23] For ABPA in CF, Nelson *et al*.[53] proposed that at least five of the following seven criteria had to be present for diagnosing ABPA in CF patients, namely, wheezing, increased total serum IgE, positive specific IgE to *A. fumigatus*, serum *Aspergillus* IgG precipitins, positive skin test, radiological pulmonary infiltrates, and bronchiectasis. Recently, CF Foundation Consensus has laid down the diagnostic criteria of ABPA in CF as well as criteria for screening for ABPA in CF patients [Table 2].[28] Diagnosis of ABPA in CF patients may be difficult due to overlapping clinical features (frequent exacerbations with bronchial obstruction, pulmonary infiltrate, and bronchiectasis).[28] The central bronchiectasis, one of the diagnostic criteria for ABPA in asthma, cannot be used for CF patients as it is not uncommon in CF patients even without ABPA.

Patients with ABPA in asthma, in addition to diagnostic criteria, may have sputum containing *A. fumigatus*, mucus impactions, and peripheral blood eosinophilia.[5] Culture of *A. fumigatus* from the sputum is a nonspecific finding as many patients with asthma or CF without ABPA have *Aspergillus* on sputum cultures.[54]

Recombinant *Aspergillus fumigatus* allergens

About 22 recombinant *A. fumigatus* allergens (named from rAsp f 1 to rAsp f 22) had been identified.[3,5] *A. fumigatus* allergens, namely. rAsp f 1, rAsp f 2, rAsp f 3, rAsp f 4 and rAsp f 6 had mixed results in differentiating ABPA from sensitization both in asthmatic and CF patients.[55-57] A recent systematic review suggested that a combination of rAsp antigens may be more helpful than a single rAsp for diagnosis of ABPA, though grade of evidence was low to very low.[58] Therefore, to define the exact role of recombinant *A. fumigatus* allergens in diagnosing ABPA, especially in children, there is need for further research.

The thymus and activation-regulated chemokine[59] and basophil activation test (CD63 and CD203c)[60] were also found useful in differentiating ABPA from AS in CF patients.

RADIOLOGICAL FINDINGS

High-resolution computerized tomography (HRCT) is the investigation of choice to delineate lung lesions in ABPA. In ABPA, central bronchiectasis and fleeting shadows are the most common radiological findings both in children and adults.[19] Figure 1 shows a chest X-ray of child with advanced ABPA revealing bronchiectasis and fibrosis. Bronchiectasis in CT chest in a child with ABPA is shown in Figure 2. Other CT findings in ABPA include: tram-line shadow, dilated and totally occluded bronchi (bronchocele), glove-finger shadow, air-fluid levels within dilated bronchi, bronchial wall thickening, parallel-line shadows, ring shadow, toothpaste shadow, parenchymal abnormalities (homogeneous consolidation, collapse, and parenchymal scarring) with predilection for upper lobes, cavities, and mass-like lesion.[19,61,62] High-attenuation mucus (HAM), seen as opaque shadow in dilated bronchi that is denser than associated paraspinal muscle shadow, is considered almost pathognomonic for ABPA.[51] The hilar lymphadenopathy had also been reported in ABPA in children.[63] Recently, Dournes *et al*.[64] reported that inverted mucoid impaction signal (presence of mucus with high T1 and low T2 signal

Figure 1: Chest X-ray of a child with advanced allergic bronchopulmonary aspergillosis showing bronchiectasis and fibrosis; note that bronchiectasis is more in central part

Table 2: Diagnostic criteria for allergic bronchopulmonary aspergillosis in cystic fibrosis[28]

Classic case	Minimal diagnostic criteria	Screening for ABPA in CF
1. Acute/subacute clinical deterioration* not due to another etiology	1. Acute/subacute clinical deterioration* not due to another etiology	1. High index of suspicion for ABPA in patients >6 years of age
2. Serum total IgE concentration of >1000 IU/mL (2400 ng/mL)	2. Serum total IgE conc. of >500 IU/mL (1200 ng/mL)	2. Test total serum IgE conc.$annually. If it is >500 IU/mL, test for immediate cutaneous reactivity or IgE antibody to AF
3. Immediate cutaneous reactivity to *Aspergillus* or presence of serum IgE antibody to AF	3. Immediate cutaneous reactivity to *Aspergillus* or presence of serum IgE antibody to AF	3. If the total serum IgE conc. is 200-500 IU/mL, repeat the test if there is increased suspicion for ABPA (disease exacerbation)
4. Precipitating antibodies to AF or serum IgG antibody to AF	4. One of the criteria 4 or 5, mentioned under classic case	
5. New or recent abnormalities on chest X-ray or CT, not cleared with antibiotics and physiotherapy		

*Cough, wheeze, exercise intolerance, decline in pulmonary function, increased sputum, AF: *Aspergillus fumigatus*, ABPA: Allergic bronchopulmonary aspergillosis, CF: Cystic fibrosis, CT: Computerized tomography

[Downloaded free from http://www.lungindia.com on Saturday, November 3, 2018, IP: 94.34.4.137]

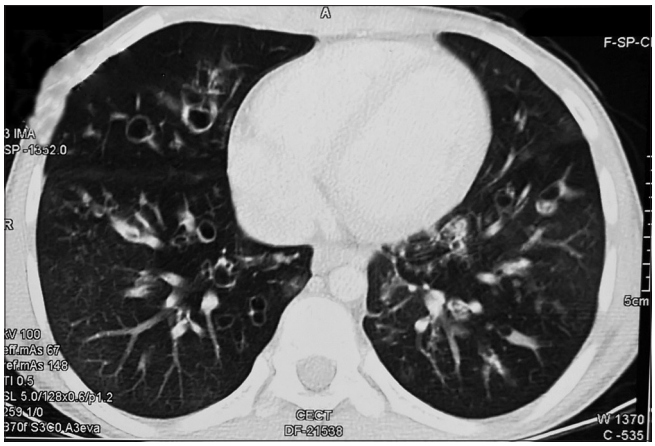

Figure 2: A computed tomography chest in child with allergic bronchopulmonary aspergillosis showing bronchiectasis

intensity) on noncontrast magnetic resonance imaging was 94% (95% CI: 73%–99%) sensitive and 100% specific (95% CI: 96%–100%) for diagnosing ABPA in CF patients.

LUNG FUNCTION TESTS

Kraemer *et al*.[65] reported severe progressive deterioration in all lung function parameters, volume of trapped gas, and effective airway resistance in CF children with ABPA.

CLINICAL FEATURES AND STAGES

ABPA patients, both children and adults, may present with poorly controlled asthma, wheezing, constitutional symptoms (fever, weight loss), mucopurulent expectoration, increased cough, dyspnea, chest pain, and hemoptysis.[3,5,14] ABPA in CF patients may be associated with exacerbation of symptoms, weight loss, and a marked increase in productive cough.[28] Even life-threatening presentation of ABPA in CF children has been reported.[66] Physical examination is usually not remarkable except for crackles and rhonchi. ABPA is frequently misdiagnosed initially for other diseases mainly tuberculosis, particularly in developing countries.[67] ABPA should be suspected in asthmatics who had difficult to control asthma despite good compliance to therapy. The diagnosis of ABPA should be suspected in children with CF who show wheezing, transient pulmonary infiltrates and had exacerbations responding poorly to antibiotics.

Patterson *et al*.[68] proposed five stages of ABPA progression: (1) acute; (2) remission; (3) exacerbation; (4) corticosteroid-dependent asthma; and (5) fibrosis (end stage). The acute stage has most of the features of disease and responds well to steroids. In remission stage, usually, there is no clinical or laboratory evidence of ABPA. The exacerbation stage has recurrence of acute stage of ABPA. The corticosteroid-dependent asthma stage is characterized by recurrent exacerbations of ABPA and severe asthma. Patients with fibrotic stage have severe dyspnea and cyanosis, and there is extensive bronchiectasis, cavitary lesions, and fibrosis in lungs, and they have poor prognosis. Kumar[69] divided patients with ABPA into three forms: mild (ABPA serologic positive; ABPA-S), moderate (ABPA with central bronchiectasis; ABPA-CB), and severe (ABPA with central bronchiectasis and other radiologic features; ABPA-CB-ORF). One more radiological classification based on HAM had been proposed by Agarwal *et al*.[70] that include ABPA-S, ABPA-CB, and ABPA-CB-HAM. Recently, Agarwal *et al*.[52] suggested the seven stages of ABPA: stage 0 (asymptomatic-ABPA criteria are fulfilled in a patient of controlled asthma), Stage 1 (Acute-ABPA criteria positive along with uncontrolled symptoms), Stage 2 (response-clinically better with total IgE decreased by >25% from baseline), Stage 3 (exacerbation-clinically worsened with total IgE increased >50% from baseline), Stage 4 (remission-clinically improved with total IgE at baseline or increase is <50%), Stage 5 (treatment dependent-≥2 exacerbations in 6 months or worsening on tapering steroids), and Stage 6 (advanced-extensive bronchiectasis and cor pulmonale). The ABPA in advanced stage may be complicated by cor pulmonale and pulmonary thromboembolism even in children.[71] There is no separate staging of ABPA for children. It has been suggested that early recognition and treatment may prevent the progression of ABPA from mild form to moderate and severe forms.[5]

TREATMENT OF ALLERGIC BRONCHOPULMONARY ASPERGILLOSIS

The goals in the treatment of ABPA should be: (1) suppression of inflammatory response using corticosteroids; (2) to eradicate colonization and/or proliferation of *A. fumigatus* in lungs using antifungal agents; (3) to limit ABPA exacerbations by high index suspicion and prompt investigation; and (4) to prevent end-stage fibrotic disease.[3,28,38] Thus, corticosteroids and antifungal agents are the two mainstay modalities of treatment for ABPA.

CORTICOSTEROIDS

Systemic (oral) corticosteroids, usually prednisolone, are the most effective treatment for the acute phase of ABPA both in asthma and CF.[3,5,28] In asthmatic patients with ABPA, the recommended dosage of prednisolone is 0.5 mg/kg/day for the first 2 weeks, followed by a progressive tapering over the next 12–16 weeks.[3,38] Another regimen for steroids include high dose that is prednisolone 0.75 mg/kg for 6 weeks, 0.5 mg/kg for another 6 weeks, and then tapering for total duration of 6–12 months. A RCT in adults with asthma had shown that medium and high dose of steroids were equally effective for ABPA, though high-dose steroids had more side effects.[72] Long-term steroid therapy is not recommended for ABPA except for stage

[Downloaded free from http://www.lungindia.com on Saturday, November 3, 2018, IP: 94.34.4.137]

IV (steroid-dependent asthma) where the minimal dose of steroids is required to stabilize the patient.

Higher dosage of corticosteroids had been recommended for ABPA in CF patients. For ABPA in CF patients, CF Foundation Consensus Conference report recommended an initial dose of prednisolone as 0.5–2.0 mg/kg/day (maximum 60 mg) for 1–2 weeks, then 0.5–2.0 mg/kg/day every other day for 1–2 weeks, and then taper in next 2–3 months.[28] Children on oral steroids should be monitored for side effects including cushingoid facies, hypertension, weight gain, height, and osteoporosis if used for long time or repeatedly.

Pulse methylprednisolone

Cohen-Cymberknoh *et al*.[73] used high-dose pulse methylprednisolone (10–15 mg/kg/d for 3 days per month) and itraconazole in nine patients with CF and ABPA (4 males, 5 females, age 7–36 years) with improvement in clinical and laboratory parameters and minor side effects. Thomson *et al*.[74] used pulse methylprednisolone to manage severe ABPA in four CF children out of which three children responded well although with troublesome side effects.

ANTIFUNGAL DRUG-ITRACONAZOLE

For allergic bronchopulmonary aspergillosis in asthma

A Cochrane meta-analysis, evaluating the role of azoles in ABPA in asthma, included three randomized controlled trials (RCT) and concluded that itraconazole improves clinical outcome in ABPA.[75] Adrenal suppression with inhaled corticosteroids and itraconazole is a potential concern. An RCT in adults compared monotherapy with steroids versus monotherapy with itraconazole in acute stage of ABPA and found that steroids were better.[76] There is hardly any study evaluating the efficacy of itraconazole for ABPA in asthmatic children, and it is difficult to recommend antifungal triazoles as first-line treatment with steroids in children with ABPA; though it used frequently based on data from adults. The itraconazole dose recommended for children include 5 mg/kg/day, maximum 400 mg/day (in two divided doses if total daily dose exceeds 200 mg).[28] The total duration of therapy should be 3–6 months.[28]

For allergic bronchopulmonary aspergillosis in cystic fibrosis patients

Skov *et al*.[77] reported 21 CF patients with ABPA (8–30 years of age, 17 were below 18 years) where the use of itraconazole (200–600 mg/day) with or without steroids decreased sputum culture for *Aspergillus*, precipitating antibodies and IgE levels, and increased FEV_1 without significant side effects. Lebeau *et al*.[78] used itraconazole (200 mg/day) in three CF children of ABPA (aged 8,10, and 11 years); two children responded but third child had liver abnormality requiring stoppage of treatment. There has been no RCT till date on the use of itraconazole in CF children with ABPA. The CF Foundation Consensus report recommended the use of itraconazole for ABPA in CF if there is a slow or poor response to steroids, for relapse of ABPA, in corticosteroid-dependent ABPA, and in cases of corticosteroid-induced toxicity.[28]

OMALIZUMAB (RECOMBINANT ANTI-IgE ANTIBODY)

For allergic bronchopulmonary aspergillosis in asthmatic patients

Aydin *et al*.[79] reported the benefits of omalizumab in 14 adult asthmatics with ABPA in the form of decreased exacerbations, lesser oral steroids use, and better pulmonary function. There is hardly any study of omalizumab use in asthmatic children with ABPA. A small RCT involving 13 adults patients with asthma and ABPA reported that the use of omalizumab resulted in significantly lower number of exacerbations as compared to placebo.[80]

Recently, an asthmatic women with refractory ABPA was successfully treated with a combination of omalizumab and mepolizumab (an anti-IL-5 monoclonal antibody).[81] There were two more adult cases who were treated successfully with mepolizumab.[82,83]

For allergic bronchopulmonary aspergillosis in cystic fibrosis patients

van der Ent *et al*.[84] first described the use of omalizumab in a 12-year-old CF girl with ABPA and there was a dramatic and rapid improvement of respiratory symptoms and lung function after a single dose. Nové-Josserand *et al*.[85] reported the steroid-sparing effect of omalizumab in 32 CF patients with ABPA (21 adults and 11 children) in a multicentric retrospective study. Li *et al*.[86] also reported the beneficial effect of omalizumab in patients with ABPA in a review of 102 cases from 40 published records that included both asthmatic and CF patients and both adults and children. A recent Cochrane review found only one RCT and that was also terminated prematurely and suggested further large trials of omalizumab in CF patients with ABPA.[87]

The role of other adjuvant therapies in ABPA is summarized in Table 3.

MONITORING FOR TREATMENT RESPONSE

The treatment of ABPA should be monitored by clinical features (including lung function tests), serum total IgE levels and chest imaging (X-ray or HRCT).[3,4] The total IgE level is a useful marker of disease activity in ABPA, and it can be used to monitor patients for "exacerbations." A study in adults with ABPA suggested that total IgE decreased at least 25% from baseline along clinical improvement after therapy and it increased by >50% with exacerbation.[98] The *Aspergillus*-specific IgE is not useful

[Downloaded free from http://www.lungindia.com on Saturday, November 3, 2018, IP: 94.34.4.137]

Table 3: Miscellaneous therapy for allergic bronchopulmonary aspergillosis

Name of therapy	Evidence	Comments
Amphotericin B	Two studies[88,89] in seven and three pediatric CF patients showed good response of nebulized amphotericin B A small pilot study in adults with asthma and ABPA in remission showed no benefit of nebulized amphotericin in primary outcome, though number of ABPA exacerbation (one of the secondary outcome) were less in nebulized amphotericin B group[90]	Needs more studies to establish benefit
Voriconazole	Two observational studies in CF with ABPA including children showed benefit,[91,92] however, there is no RCT	Needs more studies, but may be alternative to itraconazole
Isavuconazole (a new triazole)	It was used successfully to treat asthmatic women with ABPA who did not tolerate itraconazole and voriconazole[93]	Needs more studies
Vitamin D	An *in vitro* study demonstrated that vitamin D3 attenuates the Th2 responses to Aspergillus fumigatus mounted by CD4+ T-cells from CF patients with ABPA.[94] However, in a study in adults from India, Vitamin D deficiency was not different among controls, asthmatics, and asthmatic with ABPA suggesting that Vitamin D may not play an important role in ABPA[95]	There is no study in children
Bronchoscopy	Bronchoscopy (rarely rigid bronchoscopy) may be required to remove massive mucus plugs in ABPA[96]	Limited role in selected patients
Environmental factor	Seasonal variation of ABPA suggest that avoidance of places with high Aspergillus spores, for example, damp areas, basements, decaying vegetables etc., may be beneficial for patients with ABPA[38] A case-control questionnaire-based study in adults found no difference in environmental factors in asthmatics and asthmatic with ABPA[97]	It needs more studies, especially in children

ABPA: Allergic bronchopulmonary aspergillosis, CF: Cystic fibrosis, RCT: Randomized controlled trials

to monitor response to treatment.[98] Although there are no such studies in children.

CONCLUSIONS

ABPA in children with asthma is increasingly being recognized. The ABPA is not uncommon in children with CF. Early and aggressive treatment of ABPA is crucial for preventing the serious sequelae of central bronchiectasis, pulmonary fibrosis, severe impairment in lung function and cor pulmonale. Corticosteroids and azoles are mainstay of treatment for ABPA in asthma and CF, though there is lack of RCTs regarding usefulness of azoles for ABPA in children. Omalizumab may be a potential therapy for refractory ABPA in asthma and CF patients. There is not much evidence available for other adjuvant therapies for ABPA. Monitoring of patients with ABPA is recommended using clinical, laboratory (mainly total IgE), and radiological parameters.

There is need for more vigilance for diagnosing ABPA in asthmatic children. The role of itraconazole and voriconazole in asthmatic and CF children with ABPA is yet to be established. Future research, particularly RCTs, is needed for other adjuvant therapies before they can be used for ABPA.

Financial support and sponsorship
Nil.

Conflicts of interest
There are no conflicts of interest.

REFERENCES

1. Geiser DM, Klich MA, Frisvad JC, Peterson SW, Varga J, Samson RA, *et al*. The current status of species recognition and identification in *Aspergillus*. Stud Mycol 2007;59:1-10.
2. Soubani AO, Chandrasekar PH. The clinical spectrum of pulmonary aspergillosis. Chest 2002;121:1988-99.
3. Tillie-Leblond I, Tonnel AB. Allergic bronchopulmonary aspergillosis. Allergy 2005;60:1004-13.
4. Agarwal R. Allergic bronchopulmonary aspergillosis. Chest 2009;135:805-26.
5. Greenberger PA. Allergic bronchopulmonary aspergillosis. J Allergy Clin Immunol 2002;110:685-92.
6. Hinson KF, Moon AJ, Plummer NS. Broncho-pulmonary aspergillosis; a review and a report of eight new cases. Thorax 1952;7:317-33.
7. Latgé JP. *Aspergillus fumigatus* and aspergillosis. Clin Microbiol Rev 1999;12:310-50.
8. Lake FR, Tribe AE, McAleer R, Froudist J, Thompson PJ. Mixed allergic bronchopulmonary fungal disease due to *Pseudallescheria boydii* and *Aspergillus*. Thorax 1990;45:489-91.
9. Chowdhary A, Agarwal K, Kathuria S, Gaur SN, Randhawa HS, Meis JF, *et al*. Allergic bronchopulmonary mycosis due to fungi other than *Aspergillus*: A global overview. Crit Rev Microbiol 2014;40:30-48.
10. Woolnough K, Fairs A, Pashley CH, Wardlaw AJ. Allergic fungal airway disease: Pathophysiologic and diagnostic considerations. Curr Opin Pulm Med 2015;21:39-47.
11. Agarwal R, Aggarwal AN, Gupta D, Jindal SK. *Aspergillus* hypersensitivity and allergic bronchopulmonary aspergillosis in patients with bronchial asthma: Systematic review and meta-analysis. Int J Tuberc Lung Dis 2009;13:936-44.
12. Slavin RG, Laird TS, Cherry JD. Allergic bronchopulmonary aspergillosis in a child. J Pediatr 1970;76:416-21.
13. Chhabra SK, Sahay S, Ramaraju K. Allergic bronchopulmonary aspergillosis complicating childhood asthma. Indian J Pediatr 2009;76:331-2.
14. Schwerk N, Rochwalsky U, Brinkmann F, Hansen G. Don't forget other causes of wheeze. ABPA in a boy with asthma. A case report and review of the literature. Acta Paediatr 2011;100:307-10.
15. Ohshima M, Futamura M, Kamachi Y, Ito K, Sakamoto T. Allergic bronchopulmonary aspergillosis in a 2-year-old asthmatic boy with immune dysregulation, polyendocrinopathy, enteropathy, X-linked. Pediatr Pulmonol 2009;44:297-9.
16. Suzuki K, Iwata S, Iwata H. Allergic bronchopulmonary aspergillosis in a 9-year-old boy. Eur J Pediatr 2002;161:408-9.
17. Shah A, Bhagat R, Panchal N. Allergic bronchopulmonary aspergillosis with clubbing and cavitation. Indian Pediatr 1993;30:248-51.
18. Banerjee B, Joshi AP, Sarma PU, Roy S. Evaluation of clinico-immunological parameters in pediatric ABPA patients. Indian J Pediatr 1992;59:109-14.
19. Shah A, Pant CS, Bhagat R, Panchal N. CT in childhood allergic bronchopulmonary aspergillosis. Pediatr Radiol 1992;22:227-8.

[Downloaded free from http://www.lungindia.com on Saturday, November 3, 2018, IP: 94.34.4.137]

20. Bedi RS. Allergic bronchopulmonary aspergillosis. Indian Pediatr 1991;28:1520-4.
21. Chetty A, Bhargava S, Jain RK. Allergic bronchopulmonary aspergillosis in Indian children with bronchial asthma. Ann Allergy 1985;54:46-9.
22. Imbeau SA, Cohen M, Reed CE. Allergic bronchopulmonary aspergillosis in infants. Am J Dis Child 1977;131:1127-30.
23. Singh M, Das S, Chauhan A, Paul N, Sodhi KS, Mathew J, *et al*. The diagnostic criteria for allergic bronchopulmonary aspergillosis in children with poorly controlled asthma need to be re-evaluated. Acta Paediatr 2015;104:e206-9.
24. Shah A, Kala J, Sahay S, Panjabi C. Frequency of familial occurrence in 164 patients with allergic bronchopulmonary aspergillosis. Ann Allergy Asthma Immunol 2008;101:363-9.
25. Maturu VN, Agarwal R. Prevalence of *Aspergillus* sensitization and allergic bronchopulmonary aspergillosis in cystic fibrosis: Systematic review and meta-analysis. Clin Exp Allergy 2015;45:1765-78.
26. Feanny S, Forsyth S, Corey M, Levison H, Zimmerman B. Allergic bronchopulmonary aspergillosis in cystic fibrosis: A secretory immune response to a colonizing organism. Ann Allergy 1988;60:64-8.
27. Marchant JL, Warner JO, Bush A. Rise in total IgE as an indicator of allergic bronchopulmonary aspergillosis in cystic fibrosis. Thorax 1994;49:1002-5.
28. Stevens DA, Moss RB, Kurup VP, Knutsen AP, Greenberger P, Judson MA, *et al*. Allergic bronchopulmonary aspergillosis in cystic fibrosis – State of the art: Cystic fibrosis foundation consensus conference. Clin Infect Dis 2003;37 Suppl 3:S225-64.
29. Skov M, McKay K, Koch C, Cooper PJ. Prevalence of allergic bronchopulmonary aspergillosis in cystic fibrosis in an area with a high frequency of atopy. Respir Med 2005;99:887-93.
30. Simmonds EJ, Littlewood JM, Evans EG. Cystic fibrosis and allergic bronchopulmonary aspergillosis. Arch Dis Child 1990;65:507-11.
31. Mussaffi H, Greif J, Kornreich L, Ashkenazi S, Levy Y, Schonfeld T, *et al*. Severe allergic bronchopulmonary aspergillosis in an infant with cystic fibrosis and her asthmatic father. Pediatr Pulmonol 2000;29:155-9.
32. Sharma VK, Raj D, Xess I, Lodha R, Kabra SK. Prevalence and risk factors for allergic bronchopulmonary aspergillosis in Indian children with cystic fibrosis. Indian Pediatr 2014;51:295-7.
33. Jubin V, Ranque S, Stremler Le Bel N, Sarles J, Dubus JC. Risk factors for *Aspergillus* colonization and allergic bronchopulmonary aspergillosis in children with cystic fibrosis. Pediatr Pulmonol 2010;45:764-71.
34. Ritz N, Ammann RA, Casaulta Aebischer C, Schoeni-Affolter F, Schoeni MH. Risk factors for allergic bronchopulmonary aspergillosis and sensitisation to *Aspergillus fumigatus* in patients with cystic fibrosis. Eur J Pediatr 2005;164:577-82.
35. Amin MU, Mahmood R. Multiple bronchoceles in a non-asthmatic patient with allergic bronchopulmonary aspergillosis. J Pak Med Assoc 2008;58:514-6.
36. Boz AB, Celmeli F, Arslan AG, Cilli A, Ogus C, Ozdemir T, *et al*. A case of allergic bronchopulmonary aspergillosis following active pulmonary tuberculosis. Pediatr Pulmonol 2009;44:86-9.
37. De H, Azad SM, Giri PP, Pal P, Ghosh A, Maitra A, *et al*. Two cases of non-cystic fibrosis (CF) bronchiectasis with allergic bronchopulmonary aspergillosis. Respir Med Case Rep 2017;20:68-71.
38. Knutsen AP, Slavin RG. Allergic bronchopulmonary aspergillosis in asthma and cystic fibrosis. Clin Dev Immunol 2011;2011:843763.
39. Knutsen AP, Kariuki B, Santiago LA, Slvin RG, Wofford JD, Bellone C, *et al*. HLADR, IL-4RA, and IL-10: Genetic risk factors in allergic bronchopulmonary aspergillosis. Pediatr Asthma Allergy Immunol 2008;21:185-90.
40. Marchand E, Verellen-Dumoulin C, Mairesse M, Delaunois L, Brancaleone P, Rahier JF, *et al*. Frequency of cystic fibrosis transmembrane conductance regulator gene mutations and 5T allele in patients with allergic bronchopulmonary aspergillosis. Chest 2001;119:762-7.
41. Saxena S, Madan T, Shah A, Muralidhar K, Sarma PU. Association of polymorphisms in the collagen region of SP-A2 with increased levels of total IgE antibodies and eosinophilia in patients with allergic bronchopulmonary aspergillosis. J Allergy Clin Immunol 2003;111:1001-7.
42. Risma KA, Wang N, Andrews RP, Cunningham CM, Ericksen MB, Bernstein JA, *et al*. V75R576 IL-4 receptor alpha is associated with allergic asthma and enhanced IL-4 receptor function. J Immunol 2002;169:1604-10.
43. Brouard J, Knauer N, Boelle PY, Corvol H, Henrion-Caude A, Flamant C, *et al*. Influence of interleukin-10 on *Aspergillus fumigatus* infection in patients with cystic fibrosis. J Infect Dis 2005;191:1988-91.
44. Wang JE, Warris A, Ellingsen EA, Jørgensen PF, Flo TH, Espevik T, *et al*. Involvement of CD14 and toll-like receptors in activation of human monocytes by *Aspergillus fumigatus* hyphae. Infect Immun 2001;69:2402-6.
45. Weiss LA, Lester LA, Gern JE, Wolf RL, Parry R, Lemanske RF, *et al*. Variation in ITGB3 is associated with asthma and sensitization to mold allergen in four populations. Am J Respir Crit Care Med 2005;172:67-73.
46. Chatterjee R, Batra J, Das S, Sharma SK, Ghosh B. Genetic association of acidic mammalian chitinase with atopic asthma and serum total IgE levels. J Allergy Clin Immunol 2008;122:202-8, 208.e1-7.
47. Reijmerink NE, Kerkhof M, Koppelman GH, Gerritsen J, de Jongste JC, Smit HA, *et al*. Smoke exposure interacts with ADAM33 polymorphisms in the development of lung function and hyperresponsiveness. Allergy 2009;64:898-904.
48. Koppelman GH, Meyers DA, Howard TD, Zheng SL, Hawkins GA, Ampleford EJ, *et al*. Identification of PCDH1 as a novel susceptibility gene for bronchial hyperresponsiveness. Am J Respir Crit Care Med 2009;180:929-35.
49. Kaur S, Gupta VK, Shah A, Thiel S, Sarma PU, Madan T, *et al*. Elevated levels of mannan-binding lectin [corrected] (MBL) and eosinophilia in patients of bronchial asthma with allergic rhinitis and allergic bronchopulmonary aspergillosis associate with a novel intronic polymorphism in MBL. Clin Exp Immunol 2006;143:414-9.
50. Rosenberg M, Patterson R, Mintzer R, Cooper BJ, Roberts M, Harris KE, *et al*. Clinical and immunologic criteria for the diagnosis of allergic bronchopulmonary aspergillosis. Ann Intern Med 1977;86:405-14.
51. Agarwal R, Chakrabarti A, Shah A, Gupta D, Meis JF, Guleria R, *et al*. Allergic bronchopulmonary aspergillosis: Review of literature and proposal of new diagnostic and classification criteria. Clin Exp Allergy 2013;43:850-73.
52. Agarwal R, Sehgal IS, Dhooria S, Aggarwal AN. Developments in the diagnosis and treatment of allergic bronchopulmonary aspergillosis. Expert Rev Respir Med 2016;10:1317-34.
53. Nelson LA, Callerame ML, Schwartz RH. Aspergillosis and atopy in cystic fibrosis. Am Rev Respir Dis 1979;120:863-73.
54. de Vrankrijker AM, van der Ent CK, van Berkhout FT, Stellato RK, Willems RJ, Bonten MJ, *et al*. *Aspergillus fumigatus* colonization in cystic fibrosis: Implications for lung function? Clin Microbiol Infect 2011;17:1381-6.
55. Hemmann S, Menz G, Ismail C, Blaser K, Crameri R. Skin test reactivity to 2 recombinant *Aspergillus fumigatus* allergens in *A fumigatus*-sensitized asthmatic subjects allows diagnostic separation of allergic bronchopulmonary aspergillosis from fungal sensitization. J Allergy Clin Immunol 1999;104:601-7.
56. Fricker-Hidalgo H, Coltey B, Llerena C, Renversez JC, Grillot R, Pin I, *et al*. Recombinant allergens combined with biological markers in the diagnosis of allergic bronchopulmonary aspergillosis in cystic fibrosis patients. Clin Vaccine Immunol 2010;17:1330-6.
57. de Oliveira E, Giavina-Bianchi P, Fonseca LA, França AT, Kalil J. Allergic bronchopulmonary aspergillosis' diagnosis remains a challenge. Respir Med 2007;101:2352-7.
58. Muthu V, Sehgal IS, Dhooria S, Aggarwal AN, Agarwal R. Utility of recombinant *Aspergillus fumigatus* antigens in the diagnosis of allergic bronchopulmonary aspergillosis: A systematic review and diagnostic test accuracy meta-analysis. Clin Exp Allergy 2018. doi: 10.1111/cea.13216.
59. Latzin P, Hartl D, Regamey N, Frey U, Schoeni MH, Casaulta C, *et al*. Comparison of serum markers for allergic bronchopulmonary aspergillosis in cystic fibrosis. Eur Respir J 2008;31:36-42.
60. Katelari A, Tzanoudaki M, Noni M, Kanariou M, Theodoridou M, Kanavakis E, *et al*. The role of basophil activation test in allergic bronchopulmonary aspergillosis and *Aspergillus fumigatus* sensitization in cystic fibrosis patients. J Cyst Fibros 2016;15:587-96.
61. Panchal N, Bhagat R, Pant C, Shah A. Allergic bronchopulmonary aspergillosis: The spectrum of computed tomography appearances. Respir Med 1997;91:213-9.
62. Huppmann MV, Monson M. Allergic bronchopulmonary aspergillosis: A unique presentation in a pediatric patient. Pediatr Radiol 2008;38:879-83.
63. Shah A, Kala J, Sahay S. Allergic bronchopulmonary aspergillosis with hilar adenopathy in a 42-month-old boy. Pediatr Pulmonol 2007;42:747-8.
64. Dournes G, Berger P, Refait J, Macey J, Bui S, Delhaes L, *et al*. Allergic bronchopulmonary aspergillosis in cystic fibrosis: MR imaging of airway mucus contrasts as a tool for diagnosis. Radiology 2017;285:261-9.
65. Kraemer R, Deloséa N, Ballinari P, Gallati S, Crameri R. Effect of allergic

[Downloaded free from http://www.lungindia.com on Saturday, November 3, 2018, IP: 94.34.4.137]

bronchopulmonary aspergillosis on lung function in children with cystic fibrosis. Am J Respir Crit Care Med 2006;174:1211-20.
66. Skowronski E, Fitzgerald DA. Life-threatening allergic bronchopulmonary aspergillosis in a well child with cystic fibrosis. Med J Aust 2005;182:482-3.
67. Ragosta KG, Clayton JA, Cambareri CB, Domachowske JB. Allergic bronchopulmonary aspergillosis masquerading as pulmonary tuberculosis. Pediatr Infect Dis J 2004;23:582-4.
68. Patterson R, Greenberger PA, Radin RC, Roberts M. Allergic bronchopulmonary aspergillosis: Staging as an aid to management. Ann Intern Med 1982;96:286-91.
69. Kumar R. Mild, moderate, and severe forms of allergic bronchopulmonary aspergillosis: A clinical and serologic evaluation. Chest 2003;124:890-2.
70. Agarwal R, Khan A, Gupta D, Aggarwal AN, Saxena AK, Chakrabarti A, *et al*. An alternate method of classifying allergic bronchopulmonary aspergillosis based on high-attenuation mucus. PLoS One 2010;5:e15346.
71. Azad C, Jat KR, Aggarwal P. Bronchial asthma with ABPA presenting as PTE. Indian J Crit Care Med 2013;17:188-9.
72. Agarwal R, Aggarwal AN, Dhooria S, Singh Sehgal I, Garg M, Saikia B, *et al*. A randomised trial of glucocorticoids in acute-stage allergic bronchopulmonary aspergillosis complicating asthma. Eur Respir J 2016;47:490-8.
73. Cohen-Cymberknoh M, Blau H, Shoseyov D, Mei-Zahav M, Efrati O, Armoni S, *et al*. Intravenous monthly pulse methylprednisolone treatment for ABPA in patients with cystic fibrosis. J Cyst Fibros 2009;8:253-7.
74. Thomson JM, Wesley A, Byrnes CA, Nixon GM. Pulse intravenous methylprednisolone for resistant allergic bronchopulmonary aspergillosis in cystic fibrosis. Pediatr Pulmonol 2006;41:164-70.
75. Wark PA, Gibson PG, Wilson AJ. Azoles for allergic bronchopulmonary aspergillosis associated with asthma. Cochrane Database Syst Rev 2004;3:CD001108.
76. Agarwal R, Dhooria S, Singh Sehgal I, Aggarwal AN, Garg M, Saikia B, *et al*. A randomized trial of itraconazole vs. prednisolone in acute-stage allergic bronchopulmonary aspergillosis complicating asthma. Chest 2018;153:656-64.
77. Skov M, Høiby N, Koch C. Itraconazole treatment of allergic bronchopulmonary aspergillosis in patients with cystic fibrosis. Allergy 2002;57:723-8.
78. Lebeau B, Pelloux H, Pinel C, Michallet M, Goût JP, Pison C, *et al*. Itraconazole in the treatment of aspergillosis: A study of 16 cases. Mycoses 1994;37:171-9.
79. Aydın Ö, Sözener ZÇ, Soyyiğit Ş, Kendirlinan R, Gençtürk Z, Mısırlıgil Z, *et al*. Omalizumab in the treatment of allergic bronchopulmonary aspergillosis: One center's experience with 14 cases. Allergy Asthma Proc 2015;36:493-500.
80. Voskamp AL, Gillman A, Symons K, Sandrini A, Rolland JM, O'Hehir RE, *et al*. Clinical efficacy and immunologic effects of omalizumab in allergic bronchopulmonary aspergillosis. J Allergy Clin Immunol Pract 2015;3:192-9.
81. Altman MC, Lenington J, Bronson S, Ayars AG. Combination omalizumab and mepolizumab therapy for refractory allergic bronchopulmonary aspergillosis. J Allergy Clin Immunol Pract 2017;5:1137-9.
82. Terashima T, Shinozaki T, Iwami E, Nakajima T, Matsuzaki T. A case of allergic bronchopulmonary aspergillosis successfully treated with mepolizumab. BMC Pulm Med 2018;18:53.
83. Oda N, Miyahara N, Senoo S, Itano J, Taniguchi A, Morichika D, *et al*. Severe asthma concomitant with allergic bronchopulmonary aspergillosis successfully treated with mepolizumab. Allergol Int 2018. pii: S1323-8930(18)30038-8.
84. van der Ent CK, Hoekstra H, Rijkers GT. Successful treatment of allergic bronchopulmonary aspergillosis with recombinant anti-igE antibody. Thorax 2007;62:276-7.
85. Nové-Josserand R, Grard S, Auzou L, Reix P, Murris-Espin M, Brémont F, *et al*. Case series of omalizumab for allergic bronchopulmonary aspergillosis in cystic fibrosis patients. Pediatr Pulmonol 2017;52:190-7.
86. Li JX, Fan LC, Li MH, Cao WJ, Xu JF. Beneficial effects of omalizumab therapy in allergic bronchopulmonary aspergillosis: A synthesis review of published literature. Respir Med 2017;122:33-42.
87. Jat KR, Walia DK, Khairwa A. Anti-IgE therapy for allergic bronchopulmonary aspergillosis in people with cystic fibrosis. Cochrane Database Syst Rev 2018;3:CD010288.
88. Proesmans M, Vermeulen F, Vreys M, De Boeck K. Use of nebulized amphotericin B in the treatment of allergic bronchopulmonary aspergillosis in cystic fibrosis. Int J Pediatr 2010;2010:376287.
89. Laoudi Y, Paolini JB, Grimfed A, Just J. Nebulised corticosteroid and amphotericin B: An alternative treatment for ABPA? Eur Respir J 2008;31:908-9.
90. Ram B, Aggarwal AN, Dhooria S, Sehgal IS, Garg M, Behera D, *et al*. A pilot randomized trial of nebulized amphotericin in patients with allergic bronchopulmonary aspergillosis. J Asthma 2016;53:517-24.
91. Glackin L, Leen G, Elnazir B, Greally P. Voriconazole in the treatment of allergic bronchopulmonary aspergillosis in cystic fibrosis. Ir Med J 2009;102:29.
92. Hilliard T, Edwards S, Buchdahl R, Francis J, Rosenthal M, Balfour-Lynn I, *et al*. Voriconazole therapy in children with cystic fibrosis. J Cyst Fibros 2005;4:215-20.
93. Jacobs SE, Saez-Lacy D, Wynkoop W, Walsh TJ. Successful treatment of allergic bronchopulmonary aspergillosis with isavuconazole: Case report and review of the literature. Open Forum Infect Dis 2017;4:ofx040.
94. Kreindler JL, Steele C, Nguyen N, Chan YR, Pilewski JM, Alcorn JF, *et al*. Vitamin D3 attenuates Th2 responses to *Aspergillus fumigatus* mounted by CD4+T cells from cystic fibrosis patients with allergic bronchopulmonary aspergillosis. J Clin Invest 2010;120:3242-54.
95. Agarwal R, Sehgal IS, Dhooria S, Aggarwal AN, Sachdeva N, Bhadada SK, *et al*. Vitamin D levels in asthmatic patients with and without allergic bronchopulmonary aspergillosis. Mycoses 2018;61:344-9.
96. Agarwal R, Aggarwal AN, Gupta N, Gupta D. A rare cause of acute respiratory failure – Allergic bronchopulmonary aspergillosis. Mycoses 2011;54:e223-7.
97. Agarwal R, Devi D, Gupta D, Chakrabarti A. A questionnaire-based study on the role of environmental factors in allergic bronchopulmonary aspergillosis. Lung India 2014;31:232-6.
98. Agarwal R, Aggarwal AN, Sehgal IS, Dhooria S, Behera D, Chakrabarti A, *et al*. Utility of IgE (total and *Aspergillus fumigatus* specific) in monitoring for response and exacerbations in allergic bronchopulmonary aspergillosis. Mycoses 2016;59:1-6.