Respiratory Medicine Case Reports 26 (2019) 292–295

Contents lists available at ScienceDirect

Respiratory Medicine Case Reports

journal homepage: www.elsevier.com/locate/rmcr

Case report

Rapid effects of benralizumab on severe asthma during surgery for residual tumor after advanced lung squamous cell carcinoma treatment with pembrolizumab

Takehiro Izumo[a,*], Yuriko Terada[b], Mari Tone[a], Minoru Inomata[a], Naoyuki Kuse[a], Nobuyasu Awano[a], Atsuko Moriya[a], Tatsunori Jo[a], Hanako Yoshimura[a], Yoshiaki Furuhata[b]

[a] Department of Respiratory Medicine, Japanese Red Cross Medical Center, 4-1-22 Hiroo, Shibuya-ku, Tokyo 150-8935, Japan
[b] Department of Thoracic Surgery, Japanese Red Cross Medical Center, 4-1-22 Hiroo, Shibuya-ku, Tokyo 150-8935, Japan

ARTICLE INFO

Keywords:
Interleukin-5 receptor α monoclonal antibody
Immune checkpoint inhibitor
Lung cancer
Severe uncontrolled asthma
Video-assisted thoracic surgery

ABSTRACT

Severe bronchial asthma is a chronic disorder of the airways that may be accompanied by comorbid diseases. Invasive treatment, including surgery, in patients with severe asthma has limitations depending on the degree of control of the asthma. A 71-year-old woman was diagnosed with squamous cell carcinoma with high programmed death-ligand 1 (PD-L1) expression and cT3N0M1a. After 13 cycles of pembrolizumab every 3 weeks, chest computed tomography (CT) revealed a dramatic decrease in the lesion size in the left upper lobe, but the size of the lesion in the right lower lobe was significantly increased. The pathological findings of the right residual tumor by CT-guided transthoracic needle biopsy (CTNB) revealed squamous cell carcinoma with no PD-L1 expression, and right lower lobectomy was recommended. However, because the patient had frequent asthma attacks and cough, surgery was considered risky. Increased blood eosinophil count was observed, and benralizumab was administered for asthma control. The symptoms disappeared 2 days after benralizumab administration, and peak flow increased. Surgery was performed 5 days after benralizumab administration. There was a marked reduction in the eosinophil count of the surgical tissue compared with the preoperative CTNB tissue. No asthma attacks were observed during and after surgery, and the control of asthma and lung cancer was stable. Benralizumab is considered promising for the treatment of eosinophilic severe uncontrolled asthma.

1. Introduction

Bronchial asthma is a major chronic disorder affecting the airways that is characterized by inflammation, reversible airflow obstruction, and bronchial hyperresponsiveness [1]. Because underlying inflammation is central to the disease process, the mainstays of bronchial asthma therapy include inhaled corticosteroids (ICS) and systemic corticosteroids to prevent and treat exacerbations and reduce symptoms [2]. Recently, there has been increasing recognition of patients whose asthma control is refractory to steroids, which has led to the delineation of contrasting asthma phenotypes [3].

Bronchial asthma is occasionally associated with comorbid diseases [4]. For instance, lung cancer is one of the important pulmonary diseases and has a high mortality rate. Owing to advances in immune checkpoint inhibitors (ICIs) and molecular targeted inhibitors, the number of cases of advanced lung cancer that can be treated by radiation therapy or surgery is expected to increase [5,6]. One of the best treatments for lung cancer is surgical resection, but sometimes surgery cannot be performed in patients with severe asthma because of the high risks associated with surgery and general anesthesia [7].

We herein report for the first time resection of residual tumor in a patient with stage IV squamous cell carcinoma complicated with severe bronchial asthma who was treated with benralizumab after administration of pembrolizumab, an ICI.

2. Case report

A 71-year-old woman presented with a chest computed tomography (CT) finding of left upper (Fig. 1A) and right lower (Fig. 1B) lung field nodules. Left upper lung field nodule was diagnosed by endobronchial ultrasound with a guide sheath as squamous cell carcinoma with high programmed death-ligand 1 (PD-L1) expression (70%) (Fig. 2A). 18F-fluoro-2-deoxyglucose positron emission tomography showed uptake in both nodules. The cancer stage was determined as cT3N0M1a. After 13

* Corresponding author.
E-mail address: izumo_takehiro@med.jrc.or.jp (T. Izumo).

https://doi.org/10.1016/j.rmcr.2019.02.015
Received 7 February 2019; Received in revised form 16 February 2019; Accepted 16 February 2019
2213-0071/ © 2019 The Authors. Published by Elsevier Ltd. This is an open access article under the CC BY-NC-ND license (http://creativecommons.org/licenses/BY-NC-ND/4.0/).

Abbreviations

ADCC	antibody-dependent cell-mediated cytotoxicity
CT	computed tomography
CTNB	computed tomography-guided transthoracic needle biopsy
EBUS-GS	endobronchial ultrasound with a guide sheath
FEV1	forced expiratory volume in 1.0 second
ICI	immune checkpoint inhibitor
ICS	inhaled corticosteroids
IL-5	interleukin 5
LABA	long-acting beta-agonist
OCS	oral corticosteroid
PD-L1	programmed death-ligand 1
VC	vital capacity

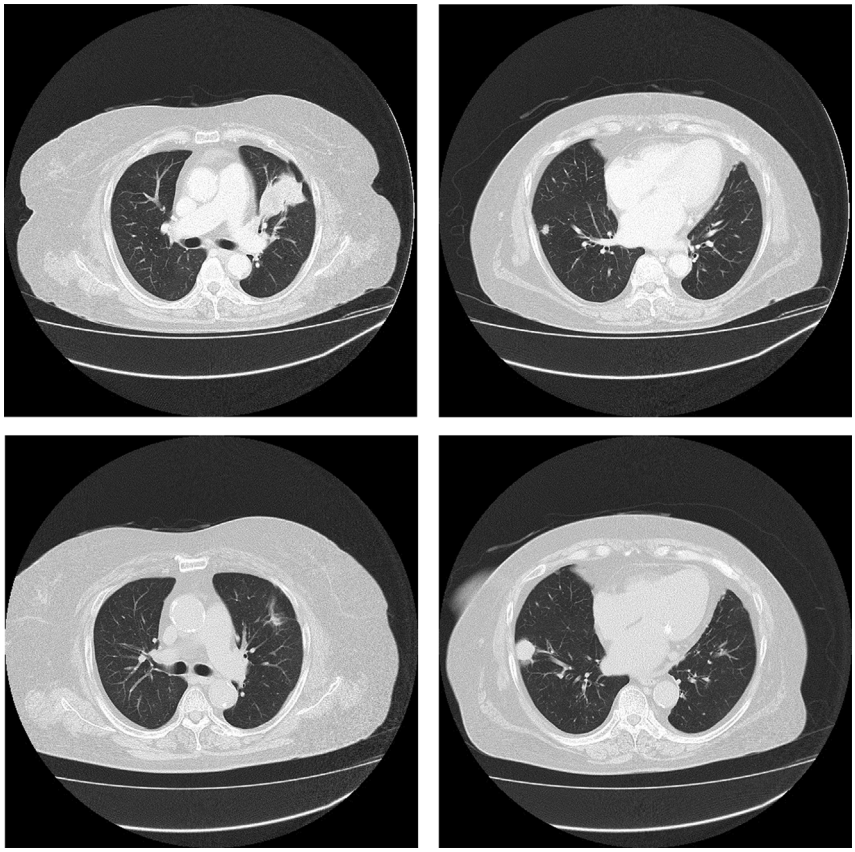

Fig. 1. Findings of chest computed tomography (CT) before and after treatment with pembrolizumab. (A) Chest CT shows a 60-mm irregularly shaped peripheral mass in the left upper lobe. (B) Chest CT shows a 10-mm irregularly shaped peripheral nodule in the right lower lobe. (C, D) After treatment with pembrolizumab for 13 cycles, the size of the left lesion dramatically decreased, but the size of the right lesion significantly increased.

cycles of pembrolizumab every 3 weeks, chest CT revealed a dramatic decrease in the size of the lesion in the left upper lobe (Fig. 1C), but the size of the lesion in the right lower lobe was significantly increased (Fig. 1D). Because the treatment effect differed between the bilateral lung lesions, a definitive right lower lung nodule diagnosis was obtained with CT-guided transthoracic needle biopsy (CTNB) (Fig. 2B).

Samples were obtained from the right lower lesion by CTNB. Pathological findings revealed squamous cell carcinoma with non-expression of PD-L1. Therefore, treatment of the right lower nodule was ineffective because of PD-L1 nonexpression. Following discussion with the cancer board, right lower lobectomy was recommended.

However, although surgery was recommended in this case, the patient's bronchial asthma was severe. She had with a history of refractory asthma for approximately 20 years. She was treated with ICS, long-acting beta-agonists (LABA), long-acting muscarinic antagonists, and antiallergic drug therapy. She was occasionally treated with oral or systemic corticosteroids for exertional dyspnea.

These treatments were all determined to be insufficient if the patient was to undergo lung surgery. On physical examination, her peripheral arterial blood oxygen saturation was 95% in room air, but chest auscultation revealed diffuse expiratory wheezing. The maximum blood eosinophil count was 680/μL. The forced expiratory volume in 1.0 second (FEV1) was 1280 mL (%FEV1, 76.3%), vital capacity (VC) was 2080 mL (%VC, 94.8%), and peak flow was 196 L/min in a pulmonary function test.

Benralizumab was administered before surgery. No adverse events occurred. Two days after benralizumab administration, her asthma symptoms (wheezing, cough, and dyspnea) disappeared. Pulmonary function tests and eosinophil count were performed again 4 days after benralizumab administration. Her peak flow was improved from 196 to 210 L/min, and her eosinophil count was reduced to 0/μL. Surgical resection by video-assisted thoracic surgery was performed 5 days after benralizumab administration. The eosinophil count in surgical tissue was markedly reduced compared with that in preoperative CTNB tissue (Fig. 3A and B). No severe asthma attacks occurred after surgical resection and benralizumab administration, and the patient was discharged from the hospital. Respiratory function tests 6 weeks after surgery showed FEV1 of 1120 mL (%FEV1, 70.9%), VC of 1740 mL (%VC, 80.0%), and peak flow of 240 L/min. The patient was administered benralizumab continuously after surgery, and no asthma attacks or cancer recurrence occurred for 6 months after surgery.

3. Discussion

To our knowledge, this is the first case report on the rapid effect of benralizumab for surgical resection of lung cancer in a patient with severe asthma. The report evaluated eosinophilic infiltration of the pulmonary airways before and after administration of benralizumab.

In recent years, a certain number of severe and poor control asthma are present even by treatment based on guidelines [8]. The costs of treatment of patients with severe asthma, who are estimated to be 5%–10% of all asthma patients, is estimated to account for as much as 50% of all costs of asthma treatment [9]. Establishment of therapy for severe asthma is essential. Understanding of the phenotypes and endotypes of bronchial asthma has progressed, and bronchial asthma has come to be considered a heterogeneous disease rather than a single syndrome. Particularly in severe bronchial asthma, multiple mechanisms affect the severity of the disease, and selection of treatment according to the characteristics of the asthma is necessary [3].

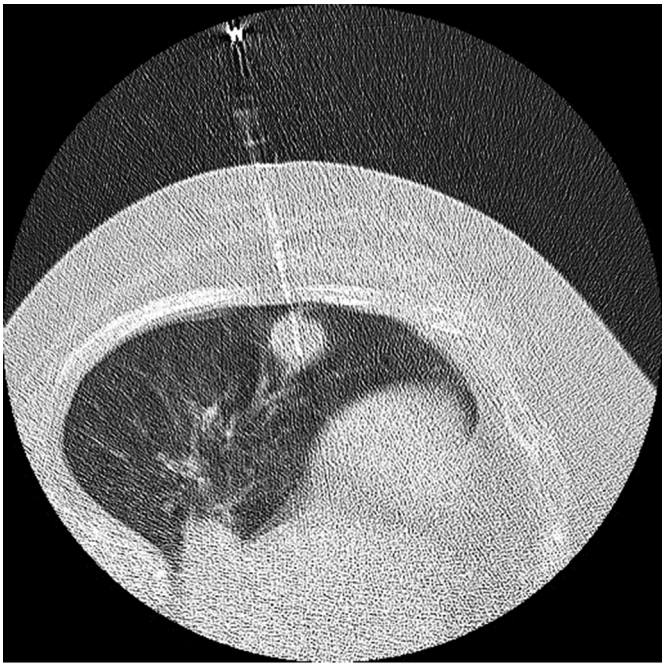

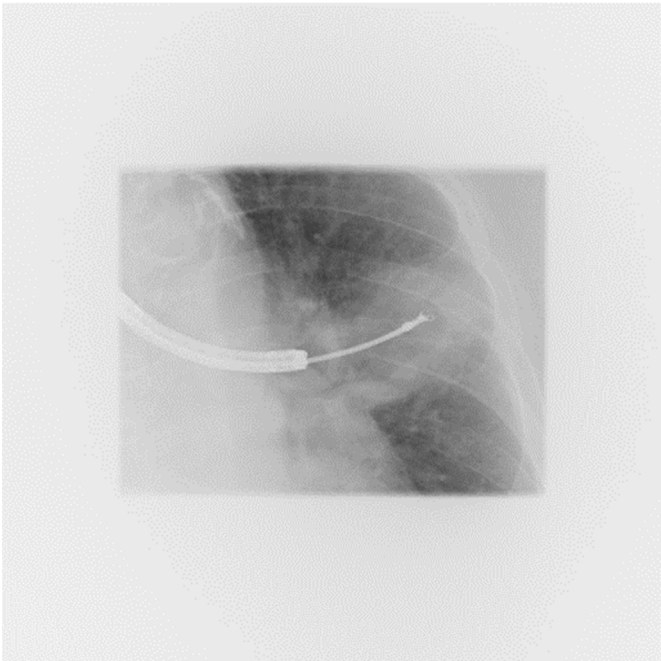

Fig. 2. Endobronchial ultrasound with a guide sheath (EBUS-GS) and computed tomography-guided transthoracic needle biopsy (CTNB). (A) EBUS-GS was performed on the left upper lesion under X-ray fluoroscopy guidance. (B) CTNB was performed on the right lower lesion.

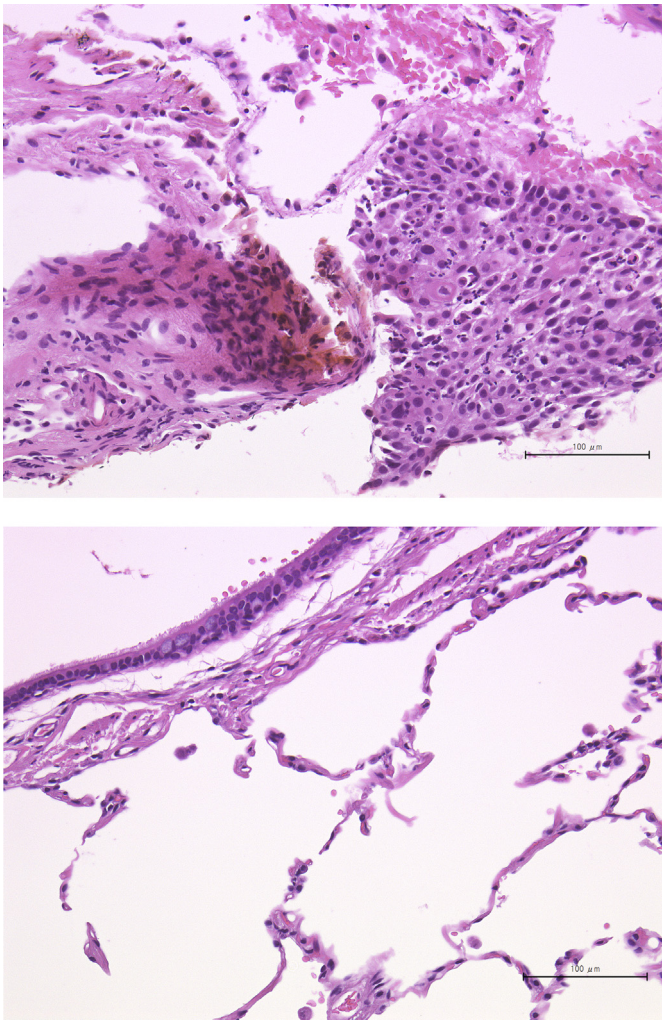

Fig. 3. Pathological specimens from computed tomography-guided transthoracic needle biopsy (CTNB) and surgical procedure. (A) Photomicrographs of the CTNB right lower lesion specimens show squamous cell carcinoma with marked eosinophilic infiltration. (B) Surgically operated right lower lesion specimens after treatment with benralizumab show markedly reduced eosinophilic infiltration.

Eosinophilic asthma, which is characterized by eosinophilic airway inflammation, accounts for approximately half of severe asthma cases. Patients with asthma with high eosinophil counts have a strong predisposition to allergies, low respiratory function, and a high frequency of exacerbation [10].

Benralizumab is a humanized, a fucosylated, monoclonal antibody that targets the interleukin 5 (IL-5) α receptor [11]. In contrast to anti-IL-5 monoclonal antibodies, benralizumab exerts its effect by inducing direct, rapid, and nearly complete depletion of blood eosinophils through enhanced antibody-dependent cell-mediated cytotoxicity (ADCC), an apoptotic process of eosinophil elimination involving natural killer cells [12]. Lack of a fucose sugar moiety on the oligosaccharide core enhances the binding affinity of benralizumab to FcγRIIIα and augments ADCC, inducing apoptosis of target cells [11]. Airway eosinophils (in tissue and sputum) are also extensively depleted [13].

A past study evaluated the safety profile of benralizumab and its effects on eosinophils in the airways, sputum, bone marrow, and peripheral blood in subjects with eosinophilic asthma. In this study, no eosinophils were observed at day 84 in benralizumab-treated subjects [13]. One other case report indicated that eosinophils disappeared from the sputum immediately after benralizumab administration [14].

Patients with asthma also suffer from various diseases [1]. Treatment of lung cancer has advanced considerably, primarily because of the use of ICIs [15]. Survival of patients with lung cancer has improved with these new treatments [5,6]. However, treatment options are limited in patients with severe complications. In our patient, stage IV lung squamous cell carcinoma was diagnosed, and she was treated with an ICI (pembrolizumab). The size of the tumor in the left lung was markedly decreased following pembrolizumab administration, but the size of the tumor in the right lung was increased. Therefore, CTNB was performed on the right lung tumor during pembrolizumab treatment and demonstrated that PD-L1 expression differed between the right and left lungs. The difference in PD-L1 expression is considered to have caused the difference in the therapeutic effect of pembrolizumab between the right and left lungs. Surgery is the best treatment for lung cancer [15]. However, the asthma condition in this patient was not good, and the patient experienced frequent asthma attacks. The patient's blood eosinophil count was high, and we believed that surgery would be possible if we could control eosinophilic inflammation with benralizumab. The asthma symptoms disappeared after 2 days of benralizumab administration. The blood eosinophil count was reduced to 0/μL, and surgery was performed on the right lung tumor. Pathological findings of the right lung tumor showed marked eosinophilic infiltration before administration of benralizumab and a marked decrease in eosinophilic infiltration in lung and airway tissues obtained by surgery 5 days after administration of benralizumab.

In conclusion, we described the rapid removal of eosinophils in the lung and airway tissues after benralizumab administration and the clinical effects of benralizumab in a patient with severe uncontrolled asthma. Benralizumab can effectively treat eosinophilic inflammation in patients with severe asthma undergoing surgery without causing severe complications. Benralizumab is promising for the treatment of severe uncontrolled eosinophilic asthma.

Funding

None.

Conflicts of interest

All authors have no conflicts of interest to disclose.

References

[1] T. To, S. Stanojevic, G. Moores, A.S. Gershon, E.D. Bateman, A.A. Cruz, et al., Global asthma prevalence in adults: findings from the cross-sectional world health survey, BMC Public Health 12 (2012) 204.
[2] T.W. Harrison, J. Oborne, S. Newton, A.E. Tattersfield, Doubling the dose of inhaled corticosteroid to prevent asthma exacerbations: randomised controlled trial, Lancet 363 (2004) 271–275.
[3] E. Israel, H.K. Reddel, Severe and difficult-to-treat asthma in adults, N. Engl. J. Med. 377 (2017) 965–976.
[4] S. Baldacci, M. Simoni, S. Maio, A. Angino, F. Martini, G. Sarno, et al., Prescriptive adherence to GINA guidelines and asthma control: an Italian cross sectional study in general practice, Respir. Med. 146 (2019) 10–17.
[5] J. Brahmer, K.L. Reckamp, P. Baas, L. Crino, W.E. Eberhardt, E. Poddubskaya, et al., Nivolumab versus docetaxel in advanced squamous-cell non-small-cell lung cancer, N. Engl. J. Med. 373 (2015) 123–135.
[6] M. Reck, D. Rodriguez-Abreu, A.G. Robinson, R. Hui, T. Csoszi, A. Fulop, et al., Pembrolizumab versus chemotherapy for PD-L1-positive non-small-cell lung cancer, N. Engl. J. Med. 375 (2016) 1823–1833.
[7] J.C. Garzon, C.S. Ng, A.D. Sihoe, A.V. Manlulu, R.H. Wong, T.W. Lee, et al., Video-assisted thoracic surgery pulmonary resection for lung cancer in patients with poor lung function, Ann. Thorac. Surg. 81 (2006) 1996–2003.
[8] K.F. Chung, S.E. Wenzel, J.L. Brozek, A. Bush, M. Castro, P.J. Sterk, et al., International ERS/ATS guidelines on definition, evaluation and treatment of severe asthma, Eur. Respir. J. 43 (2014) 343–373.
[9] C. Nunes, A.M. Pereira, M. Morais-Almeida, Asthma costs and social impact, Asthma Res. Pract. 3 (2017) 1.
[10] A. Berry, W.W. Busse, Biomarkers in asthmatic patients: has their time come to direct treatment? J. Allergy Clin. Immunol. 137 (2016) 1317–1324.
[11] R. Kolbeck, A. Kozhich, M. Koike, L. Peng, C.K. Andersson, M.M. Damschroder, et al., MEDI-563, a humanized anti-IL-5 receptor alpha mAb with enhanced antibody-dependent cell-mediated cytotoxicity function, J. Allergy Clin. Immunol. 125 (2010) 1344–1353.
[12] T.H. Pham, G. Damera, P. Newbold, K. Ranade, Reductions in eosinophil biomarkers by benralizumab in patients with asthma, Respir. Med. 111 (2016) 21–29.
[13] M. Laviolette, D.L. Gossage, G. Gauvreau, R. Leigh, R. Olivenstein, R. Katial, et al., Effects of benralizumab on airway eosinophils in asthmatic patients with sputum eosinophilia, J. Allergy Clin. Immunol. 132 (2013) 1086–1096.
[14] D. Minami, H. Kayatani, K. Sato, K. Fujiwara, T. Shibayama, Effectiveness of benralizumab for allergic and eosinophilic predominant asthma following negative initial results with omalizumab, Respirol. Case Rep. 7 (2019) e00388.
[15] F.R. Hirsch, G.V. Scagliotti, J.L. Mulshine, R. Kwon, W.J. Curran Jr., Y.L. Wu, et al., Lung cancer: current therapies and new targeted treatments, Lancet 389 (2017) 299–311.