[Downloaded free from http://www.lungindia.com on Tuesday, August 26, 2014, IP: 160.80.2.8] || Click here to download free Android application for this journal

Case Report

Miliary nodules: An unusual presentation of allergic bronchopulmonary aspergillosis

Pooja Aneja, Urvinder Pal Singh, Balwinder Kaur, Kalpesh Patel

Department of Pulmonary Medicine, Government Medical College, Patiala, Punjab, India

ABSTRACT

Allergic bronchopulmonary aspergillosis (ABPA) is an immune-mediated inflammatory disease caused by hypersensitivity to *Aspergillus fumigatus*. A wide spectrum of plain radiographic appearances has been described in ABPA, though none are pathognomonic of ABPA. The common radiological abnormalities encountered are fleeting pulmonary opacities, bronchiectasis, and mucoid impaction. Uncommon radiological findings encountered in ABPA include pulmonary masses, perihilar opacities simulating hilar adenopathy, and pleural effusions. However, miliary nodules as a radiological presentation of ABPA are very rare and only one case has been reported in literature. It is often misdiagnosed and mismanaged as tuberculosis; thus, the clinician should be vigilant enough to diagnose this very rare entity.

KEY WORDS: Allergic bronchopulmonary aspergillosis, miliary, radiology, tuberculosis

Address for correspondence: Dr. Urvinder Pal Singh, 22, Baba Srichand Marg, Opposite Government Press, Sirhind road, Patiala, Punjab, India.
E-mail: singhurvinderpal@hotmail.com

INTRODUCTION

Allergic bronchopulmonary aspergillosis (ABPA) is a disorder caused by a hypersensitivity reaction to antigens of the *Aspergillus* species (most frequently *Aspergillus fumigatus*). ABPA was first described in 1952 by Hinson *et al*.[1] The pathogenesis of ABPA is complex with immune and genetic factors on the part of the host being implicated. It usually affects patients with allergic diseases, including steroid-dependent asthma or cystic fibrosis (CF).[2] ABPA can occur anywhere that has increased levels of airborne mould spores and can trigger severe asthmatic reactions, for example, compost heaps, damp buildings, and even the outside air in some places at particular times of the year. The various risk factors implicated are chronic obstructive pulmonary disease,[3] low body mass index,[4] use of immunosuppressive agents, long term use of corticosteroids, lowered immune resistance as with certain cancers, chemotherapy or after organ transplantation.[5] ABPA is characterized by a considerably variable radiographic appearance with the most common findings being atelectasis, transient pulmonary infiltrates, proximal bronchiectasis, and signs of mucoid impaction. We report a case of a previously healthy male, who visited our department and was initially suspected as a case of miliary tuberculosis but was subsequently diagnosed as a case of ABPA.

Access this article online

Quick Response Code:

Website: www.lungindia.com

DOI: 10.4103/0970-2113.135784

CASE HISTORY

A 22-year-old male visited our hospital with complaints of cough with minimal mucoid expectoration and breathlessness of 1 month duration. He was initially managed by his general physician who on the basis of chest radiograph labelled him as a case of miliary tuberculosis. There was no history of hemoptysis, chest pain, wheeze, fever, anorexia, or weight loss. There was no history of any significant illness. The patient also denied any drug intake, addictions, or any recent travel history. On examination, the patient was normotensive with a heart rate of 84 beats per minute and a respiratory rate of 22 breaths per minute. Chest was normal on auscultation and examination of other systems was unremarkable. Chest radiograph showed small nodular opacities in both lung fields [Figures 1 and 2].

On investigations, the patient had a total leukocyte count (TLC) of 25,300 cells/mm^3 with 24% neutrophils, 20% lymphocytes, and 56% eosinophils. Stool examination was normal. Sputum smear for acid fast bacilli was

[Downloaded free from http://www.lungindia.com on Tuesday, August 26, 2014, IP: 160.80.2.8] || Click here to download free Android application for this journal

negative. His coagulation profile was also normal. Other biochemical tests were within normal limits. Enzyme-linked immunosorbent assay for human immunodeficiency virus was negative. Electrocardiography of the patient did not reveal any abnormality. Ultrasonography of the abdomen was normal.

High-resolution computed tomography (HRCT) of the chest [Figure 3] showed randomly scattered nodular opacities distributed throughout both the lung fields. The patient was subjected to bronchoscopy and bronchoscopic lung biopsy. Cytological analysis of the bronchoalveolar lavage fluid did not reveal any abnormality but there was growth of *A. fumigatus.* The bronchoscopic lung biopsy revealed findings of eosinophilic pneumonia [Figure 4].

Subsequently, intradermal tests with *A. fumigatus spp.* elicited strong type I hypersensitivity reaction. Total serum Immunoglobulin E (IgE) level estimated using fully automated chemiluminiscence system was 19304 IU/mL (N~100 IU/mL). Specific IgE against *A. fumigatus* was >100 kU/L (N~0.24 kU/L), while specific IgG levels against *A. fumigatus* were 278 IU/mL (N~40 IU/mL). Sputum cultures yielded no growth of *Aspergillus* species. Spirometry was normal, with a forced vital capacity (FVC) of 2.97 L (82% of predicted), a forced expiratory volume in 1 s (FEV_1) of 2.52 L (85% of predicted), and an FEV_1/FVC ratio of 85%, there was insignificant bronchodilatation after administering a bronchodilator. Postexercise spirometry was normal. Methacholine challenge test was not performed as patient denied consent.

A diagnosis of ABPA without bronchial asthma was thus made as the patient fulfilled majority of the criteria given by Rosenberg *et al.*[6] He was treated with prednisolone 0.75 mg/kg for 6 weeks, 0.5 mg/kg for next 6 weeks, then tapered by 5 mg every 6 week to continue for a total duration of 9 months. The patient showed marked improvement in his condition and there was marked clearing in his chest radiograph [Figure 5] after 3 months of treatment. TLC decreased markedly to 11,400 cells/mm^3 with 61% neutrophils, 29% lymphocytes, and 10% eosinophils. The total serum IgE after 3 months of treatment decreased to 4784 IU/mL. The patient is under follow-up and no symptoms or signs of asthma have appeared till date.

DISCUSSION

ABPA is an inflammatory pulmonary disorder known to complicate the course of bronchial asthma and CF. The disorder occurs secondary to the immune response against antigens released by *A. fumigatus*, which colonize the airways of these patients.[7]

New criteria for diagnosis of ABPA have been proposed,[8] but still the Rosenberg-Patterson criteria are the most widely used for diagnosis of ABPA and include eight major (asthma, fleeting pulmonary opacities on chest radiograph, type I skin test reaction to *A. fumigatus* antigen, eosinophilia, serum

Figure 1: Chest radiograph showing ill-defined nodular opacities in both lung fields

Figure 2: Chest radiograph showing ill-defined nodular opacities more prominent on left side

Figure 3: CT scan of chest showing bilateral nodular opacities that are randomly scattered

[Downloaded free from http://www.lungindia.com on Tuesday, August 26, 2014, IP: 160.80.2.8] || Click here to download free Android application for this journal

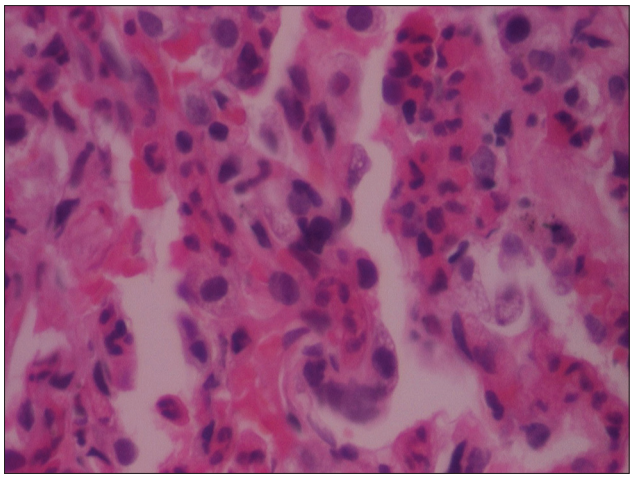

Figure 4: Photomicrograph showing fibrin with eosinophilic infiltrate consistent with eosinophilic pneumonia

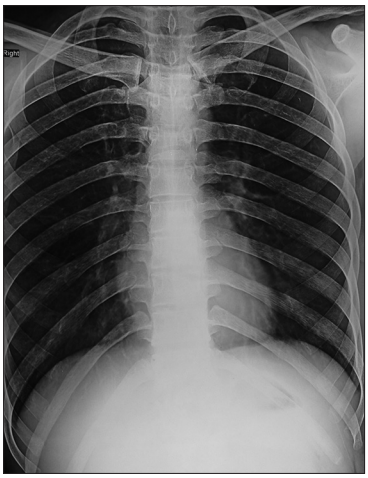

Figure 5: Chest radiograph after steroid therapy that is essentially normal

precipitins against *A. fumigatus*, elevated serum total IgE levels, central bronchiectasis, and elevated levels of serum IgG and/or IgE against *A. fumigatus*) and three minor criteria (growth of *A. fumigatus* in sputum, expectoration of brownish-black mucous plugs, and type III skin reaction to *A. fumigatus* antigen). If six of the eight major criteria are met, the diagnosis is said to be made with certainty.[6]

The allergic reaction to *A. fumigatus* results in an immune-mediated damage to the large central airways and small airways where the reaction occurs, and also in the adjacent lung. This leads to diverse chest radiographic manifestations. The chest radiographic findings also depend on the clinical presentation of the disease.[7]

A characteristic feature of ABPA is the variable radiographic appearances usually in relation to the stage of the disease. During acute exacerbations of the disease, transient and fleeting opacities are characteristically found, whereas fixed abnormalities are encountered in chronic stages of the disease.[7] The most common chest radiographic finding noted is a normal chest radiograph. Consolidation is considered to be the most frequent chest radiographic abnormality of ABPA.[9] Other chest radiographic features include transient pulmonary infiltrates (mainly in the upper and lower lobes), atelectasis, band-like opacities (the gloved finger sign), bronchiectasis, and less frequently areas of poor vascular pattern, cavities, and signs of fibrosis.[2] HRCT of the chest has replaced bronchography as the investigation of choice in ABPA. The usual findings of ABPA noted on HRCT include central bronchiectasis, mucoid impaction, mosaic attenuation, and presence of centrilobular nodules. High-attenuation (80-110 HU) mucoid impaction is a highly characteristic finding encountered in patients with ABPA. Currently, the presence of high-attenuation mucus (HAM) is considered pathognomonic of ABPA.[10] The immunological activity and outcomes of ABPA could be predicted on HRCT chest finding of HAM, a marker of inflammatory activity. Central broncheictasis and HAM are independent predictors of recurrent relapses in ABPA.[11] Rare findings on HRCT include pleural effusion, perihilar bronchoceles mimicking adenopathy, miliary nodules, and unilateral lung collapse.[12-16]

Among the atypical presentations of ABPA, Berkin *et al.*,[17] in 1982 described four patients with complete or partial atelectasis without a history of asthma in whom the final diagnosis was ABPA. In 2001, Sanchez-Alcaros *et al.*,[18] described a 65-year-old male smoker without a history of asthma who had undergone thoracotomy due to suspected lung cancer, which revealed the presence of dilated bronchi filled with mucus and was diagnosed as ABPA. In 2006, Agarwal *et al.*,[15] described a case of a 60-year-old female evaluated due to the widening of the left hilum on a chest X-ray later diagnosed as ABPA. Aggarwal *et al.*,[12] have described the only case of military mottling which was finally diagnosed as a case of ABPA. This is the second such case.

In areas with a high prevalence of pulmonary tuberculosis (PTB), patients with ABPA having atypical radiological presentations are often misdiagnosed with PTB. In some Indian studies, ABPA was misdiagnosed as PTB in as high as 17%-50% cases and treated with antitubercular drugs for a long time.[19] Our case was also labelled as a case of miliary tuberculosis and advised antitubercular treatment.

Primary treatment for ABPA is with systemic corticosteroids to suppress the allergic response rather than with antifungal therapy targeted at the fungal organism. Oral corticosteroids are still the therapy of choice for ABPA. Itraconazole may have a role in therapy, but controlled studies are needed. At this time, itraconazole should be limited to cases where oral corticosteroids are contraindicated or refused by the patient. In patients requiring large doses of oral steroids, itraconazole may allow a reduction in dose but should not replace the need to treat with oral corticosteroids.[20]

It should be noted that not all the diagnostic criteria of ABPA are always fulfilled, which makes establishment of

[Downloaded free from http://www.lungindia.com on Tuesday, August 26, 2014, IP: 160.80.2.8] || Click here to download free Android application for this journal

the final diagnosis difficult. ABPA can present with diverse radiological manifestations, and a high index of suspicion should be maintained, especially in high-prevalence areas.

To conclude, although tuberculosis is the most common cause of miliary mottling in our country but when confronted with a case who presents with miliary mottling along with eosinophilia and atypical symptoms, the clinician should be vigilant enough to look for other diagnosis. Early diagnosis and management of ABPA in such cases will help to prevent the development of end-stage pulmonary fibrosis.

ACKNOWLEDGEMENT

The authors would like to thank Dr. Vishal Chopra, associate profressor, department of pulmonary medicine, government medical college patiala, for doing bronchoscopy and Dr. Moushumi Suryavanshi for doing histopathological examination.

REFERENCES

1. Hinson KF, Moon AJ, Plummer NS. Broncho-pulmonary aspergillosis; a review and a report of eight new cases. Thorax 1952;7:317-33.
2. Nowicka U, Wiatr E, Jakubowska L, Polubiec-Kownacka M. Allergic bronchopulmonary aspergillosis mimicking lung cancer in a non-asthmatic female patient: A case report. Pneumonol Alergol Pol 2012;80:77-81.
3. Agarwal R, Hazarika B, Gupta D, Aggarwal AN, Chakrabarti A, Jindal SK. Aspergillus hypersensitivity in patients with chronic obstructive pulmonary disease: COPD as a risk factor for ABPA? Med Mycol 2010;48:988-94.
4. Jubin V, Ranque S, Stremler Le Bel N, Sarles J, Dubus JC. Risk factors for Aspergillus colonization and allergic bronchopulmonary aspergillosis in children with cystic fibrosis. Pediatr Pulmonol 2010;45:764-71.
5. Gangneux JP, Camus C, Philippe B. Epidemiology of and risk factors for invasive aspergillosis in nonneutropenic patients. Rev Mal Respir 2008;25:139-53.
6. Rosenberg M, Patterson R, Mintzer R, Cooper BJ, Roberts M, Harris KE. Clinical and immunologic criteria for the diagnosis of allergic bronchopulmonary aspergillosis. Ann Intern Med 1977;86:405-14.
7. Agarwal R. Allergic bronchopulmonary aspergillosis: Lessons for the busy radiologist. World J Radiol 2011;3:178-81
8. Agarwal R, Chakrabarti A, Shah A, Gupta D, Meis JF, Guleria R, *et al*. ABPA complicating asthma ISHAM working group. Allergic bronchopulmonary aspergillosis: Review of literature and proposal of new diagnostic and classification criteria. Clin Exp Allergy 2013;43:850-73.
9. Agarwal A, Khan A, Gupta D. Chest radiographic and computed tomographic manifestations in allergic bronchopulmonary aspergillosis. World J Radiol 2012;4:141-50.
10. Webb RW, Muller NL, Naidich DP. High-resolution computed tomography findings of lung disease. In: Webb RW, Muller NL, Naidich DP, editors. High-Resolution CT of The Lung, 4th ed. Philadelphia: Lippincott Williams and Wilkins; 2009. p. 65-176.
11. Agarwal R, Khan A, Gupta D, Aggarwal AN, Saxena AK, Chakarbarti A. An alternate method of classifying allergic bronchopulmonary aspergillosis based on high attenuation mucus. PLoS One 2010;5:el 5346.
12. Agarwal R, Aggarwal AN, Gupta D, Bal A, Das A. Case report: A rare cause of miliary nodules: Allergic bronchopulmonary aspergillosis. Br J Radiol 2009;82:e151-4.
13. Lynch DA. Imaging of asthma and allergic bronchopulmonary mycosis. Radiol Clin North Am 1998;36:129-42.
14. O'Connor TM, O'Donnell A, Hurley M, Bredin CP. Allergic bronchopulmonary aspergillosis a rare cause of pleural effusion. Respirology 2001;6;361-3.
15. Agarwal R, Reddy C, Gupta D. An unusual cause of hilar lymphadenopathy. Lung India 2006;23:90-2.
16. Agarwal R, Aggarwal AN, Gupta N, Gupta D. A rare cause of acute respiratory failure - allergic bronchopulmonary aspergillosis. Mycoses 2011;54:e223-7.
17. Berkin KE, Vernon DR, Kerr JW. Lung collapse caused by allergic bronchopulmonary aspergillosis in non-asthmatic patients. Br Med J 1982;285:552-3.
18. Sanchez-Alcaros JM, Martinez-Cruz R, Ortega L, Calle M, Rodriguez Hermosa JL, Alvarez-Sala JL. ABPA mimiking bronchogenic cancer. Allergy 2001;56:80-1.
19. Bedi RS. Allergic Bronchopulmonary Aspergillosis: Indian Perspective. Indian J Chest Dis Allied Sci 2009;51:73-4.
20. Leon EE, Craig TJ. Antifungals in the treatment of allergic bronchopulmonary aspergillosis. Ann Allergy Asthma Immunol 1999;82:511-6.

How to cite this article: Aneja P, Singh UP, Kaur B, Patel K. Miliary nodules: An unusual presentation of allergic bronchopulmonary aspergillosis. Lung India 2014;31:285-8.

Source of Support: Nil, **Conflict of Interest:** None declared.