A novel mutation in the CD40 ligand gene in a Chinese boy with X-linked hyper-IgM syndrome

Po-ning Liu,[1] Hong Li,[2] Qiang Li,[1] Zhong-wei Yin,[2] Chen-yan Zhou,[1] Ming-yan Jiang[1] and Xia Guo[1]

Summary

X-linked hyper-IgM Syndrome (XHIGM) is caused by a mutation of CD40 ligand (*CD40L*), which is normally expressed on activated CD4+ T cells and is responsible for immunoglobulin class switching. A 7-year-old boy with recurrent sino-pulmonary infections since the age of 3 months had normal CD3+, CD4+, CD8+T lymphocytes, and CD19+B lymphocytes and NK cells, but significantly elevated IgM and extremely decreased IgG and IgA. Sequencing of genomic DNA revealed that the patient had a 34 base deletion in intron 3 and exon 4 of *CD40L*(g.8172_8205del34bp), which lead to the entire deletion of exon 4 in cDNA (c.347_409del63bp, i.e.,exon 4 skipping) and an in-frame deletion of 21 amino acids in CD40L protein. Moreover, the patient had negligible CD40L expression on activated CD3+CD8- T lymphocytes. His mother and sister were carriers of the *CD40L* mutation. Our studies demonstrated a novel mutation in *CD40L*, which, to our knowledge, has not been reported previously. *(Asian Pac J Allergy Immunol 2014;32:270-4)*

Key words: *CD40 ligand, molecular diagnosis, novel mutation, recurrent infection, X-linked hyper-IgM Syndrome*

From 1. Department of Pediatric Hematology/Immunology, West China Second University Hospital, Sichuan University, Chengdu, China

2. Key Laboratory of Obstetric & Pediatric Diseases and Birth Defects of Ministry of Education, West China Second University Hospital, Sichuan University, Chengdu, China

Corresponding author: Qiang Li

E-mail: lqcm2000@yahoo.com.cn

Submitted date: 29/3/2013

Accepted date: 23/8/2013

Case report

A 7-year-old boy experienced recurrent fever fluctuating between 39°C to 40°C, severe cough, and tachypnea for three months. He was suspected of having immunodeficiency and transferred to our hospital for further diagnosis. The child had a history of recurrent sino-respiratory infections which had occurred about 20 times since the age of 3 months, including acute otitis media, sinusitis, bronchitis and pneumonia, all of which responded to antibiotics. He was also very vulnerable to diarrhea, about 3 or 4 times a year; the stool usually contained mucus and blood for several days and could be cured by oral antibiotics, such as gentamycin and cephalosporins. He was born after a normal pregnancy and delivery and received routine vaccine inoculations with no obvious complications. His parents were not consanguineous and he had a healthy sister, but his brother had died of diarrhea with bloody mucopurulent stool at the age of 2 years (additional details are unknown).

Physical examination revealed that he had stable vital signs. The superficial lymph nodes were palpable but tiny. The pharynx was hyperemic and both tonsils were tumescent. Auscultation of both lungs revealed rough breath sound but no moist rales. The liver and spleen were not palpable. There was no arthritis of the extremities. The CNS examination was normal.

Laboratory findings were as follows: blood routine examinations showed WBC, 3.58~9.8×10^9/L (normal:3.6~9.8×10^9/L); neutrophils, 1.22 ~4.74×10^9/L (normal: 0.88×10^9/L ~5.7×10^9/L); lymphocytes, 2.15~3.98×10^9/L (normal:1.22×10^9/L ~4.26×10^9/L); Hb, 84~103g/L (normal:110g/L~146g/L); platelets, 333 ~448×10^9/L (normal: 100×10^9/L ~ 450×10^9/L). Blood culture and sputum culture were negative and serum antibodies (both IgM and IgG) to cytomegalovirus, Epstein-Barr virus, coxsackie virus, respiratory syncytial virus and adenovirus were not detected by double-antibody sandwich ELISA. The IgM and IgG to Chlamydia pneumoniae were negative by the method of chemiluminescence and there was no mycoplasma pneumoniae infection, as assessed by the method of quick culture

Downloaded from http://apjai.digitaljournals.org. For personal use only. No other uses without permission.

of pharyngeal swabs. The chest radiograph showed right lower lobe pneumonia. Immunologic studies revealed that the patient had normal levels of CD3+,CD4+ and CD8+T lymphocytes, mildly decreased CD19+Blymphocyte (7.5%, normal:10%~31%), normal NK cells, and normal complement C3 and C4, while his serum IgM was significantly elevated (2.599g/L, normal:1.2g/L~2.26g/L) and IgG (0.363g/L, normal: 7.91g/L~13.07g/L),IgA(0.077g/L, normal: 0.85g/L~1.71g/L) and IgE (1.1U/ml, normal: <100 U/ml) were extremely decreased. Based on his clinical manifestations, family history, chest radiograph and immunological results, the patient was diagnosed as having pneumonia and HIGM was suspected. Antibiotics (Cefoxitin plus Piperacillin/ Sulbactam) and immunoglobulin were given intravenously to him with rapid improvement in his condition.

Informed consent was obtained from his parents for the determination of a molecular diagnosis. This study was also approved by the Ethic Committee of West China Second University Hospital. Peripheral blood was collected (EDTA-coagulated) from a healthy volunteer, the patient, his sister and his parents. The genomic DNA was extracted, and all 5 exons and exon/intron boundaries in the *CD40L* gene were separately amplified using PCR and specific oligonucleotide primers (available on request). Besides, total RNA isolated from activated PBMC (described below) was reverse-transcribed into cDNA according to the manufacturer's instructions and the full-length cDNA of *CD40L* was amplified using two oligonucleotide primers (available on request). The PCR products were examined by 2% agarose gel electrophoresis, purified and directly sequenced using the ABI Big Dye Terminator mix (Applied Biosystems) and 3730XL a DNA sequencer (Applied Biosystems). The results were analyzed using Sequencing Analysis Software (Applied Biosystems). The agarose gel electrophoresis (Figure 1) revealed that there were differences in both the genomic DNA (Figure 1a.) and cDNA (Figure 1b.) amplified fragments of *CD40L* exon 4 in the patient and his family members. Sequence analysis confirmed that the patient had a 34 base deletion in intron 3 (from -5 to -1) and exon 4 (29bp) of *CD40L* genomic DNA(g.8172_8205delTTCAGGTGATCAGAATC CTCAAATTGCGGCACAT) (Version:NC_0000 23.10), which lead to a deletion of entire exon 4 (63 bps in cDNA of *CD40L*(c.347_409del GTGATCAGAATCCTCAAATTGCGGCACATGT CATAAGTGAGGCCAGCAGTAAAACAACATC TG, i.e., exon 4 skipping) and an in-frame deletion of 21 amino acids in *CD40L* protein (p.G116-GDQNPQIAAHVISEASSKTTS). His father was normal but his mother and sister were carriers of *CD40L* mutation (figure not shown).

To further verify whether or not the mutation of the *CD40L* gene affected the expression of CD40L on activated T lymphocytes, three-color flow cytometry was used to detect the expression of CD40L on activated CD4+ T cells. Peripheral blood mononuclear cells (PBMC) from the patient, his sister and his parents were isolated from fresh whole blood (Heparin-coagulated) and activated with phorbol myristate acetate (PMA, 50 ng/ml final, Sigma) and calcium ionophore (ionomycin, 1000 ng/ml final, Sigma). The cells were incubated at 37℃ for 10 hours, washed, and then stained with antibodies to CD3 (Mouse IgG1, κ, PB), CD8 (Mouse IgG1, κ, APC-CY7), CD40L (Mouse IgG1, κ, FITC). The expression of CD40L on CD3+CD8- cells was detected by flow cytometry (Callios Beckman coulter). As shown in Figure 2, expression of CD40L on activated CD3+CD8- cells from the patient was negligible, while his father had normal expression of CD40L. His mother and sister had obviously decreased expression of CD40L, which further demonstrated that they were carriers of *CD40L* mutation.

Discussion

The Hyper-IgM Syndrome (HIGM) is a rare primary immunodeficiency disorder. According to the underlying genetic defect, HIGM is classified into 7 phenotypes,[4] and the case we are reporting is HIGM1 (XHIGM), which is caused by a *CD40L* mutation.

XHIGM, firstly recognized in 1961 in two brothers,[5] is a rare primary immunodeficiency disorder with immunoglobulin class switching due to a *CD40L* mutation. Clinically, patients with XHIGM presented with recurrent sino-pulmonary and gastrintestinal infection and the pathogens responsible include not only bacteria but also opportunistic pathogens, such as *pneumocystis carinii*,[6] *fugus*[7,8] and *Cryptosporidium*.[7] More than 50% of patients with HIGM display chronic or intermittent neutropenia, often associated with oral ulcers.[9] Neuroendocrine carcinoma may be associated with XHIGM.[10] Our patient clinically presented as recurrent sino-pulmonary infection and diarrhea which is similar to previous reports,

Downloaded from http://apjai.digitaljournals.org. For personal use only. No other uses without permission.

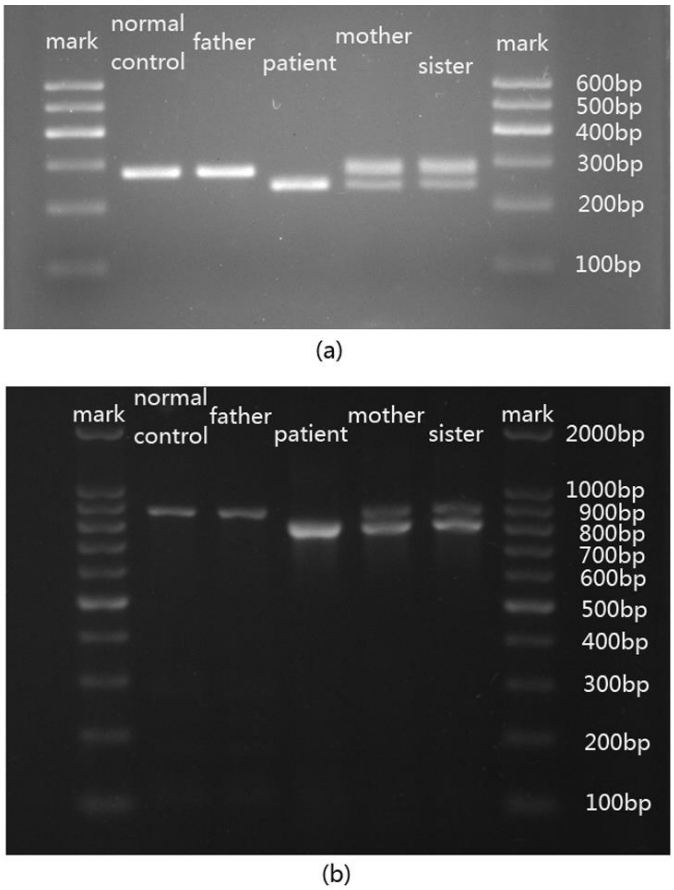

Figure 1. The agarose electrophoretogram of DNA-PCR, and RT-PCR. (a). The agarose electrophoretogram of DNA-PCR. The patient had only one short band due to deletion of 34 bp in genomic DNA,while the healthy volunteer and his father had one longer band. The mother and the sister of the patient had two bands with the longer one just same as the healthy volunteer and his father, while the shorter one same as the patient. (b). The agarose electrophoretogram of RT-PCR. The patient had only one short band due to deletion of 63bp in cDNA while the healthy volunteer and his father had one longer band. The mother and sister of the patient had two bands with the longer one just same as the father, while the shorter one same as the patient.

but there was no evidence that he had suffered from opportunistic infection, because he could be cured each time without antifungal or antiprotozoal drugs.

XHIGM is caused by a mutation in *CD40L* which encodes CD40L on activated CD4+ T lymphocytes. CD40L interacts with CD40 on B lymphocytes to induce immunoglobulin class-switching and the engagement of *CD40L*/*CD40* promotes germinal center formation and production of long-lived plasma cells and memory B cells. CD40L on activated T cells also can interact with CD40 on macrophages and dendritic cells to induce the secretion of IL-12 to enhance cellular immunity.[11]

The CD40L monomer consists of 261 amino acids and is composed of four distinct structural domains.[12] According to the *CD40L* mutation database (http://bioinf.uta.fi/CD40Lbase/), the number of mutations in the *CD40L* gene is more than 130, including missense, nonsense, insert and deletion mutations.

In the present study, we report that our patient had an unusual 34 bp deletion in intron 3(from -5 to -1) and exon 4 (29bp) in *CD40L* genomic DNA, which lead to 63 bp deletion in cDNA of *CD40L*. It is interesting to find that the position +3 of the donor splice site of intron 3 (IVS 3 (+3)) is the same as that of intron 4 (IVS 4 (+3)), while the

Downloaded from http://apjai.digitaljournals.org. For personal use only. No other uses without permission.

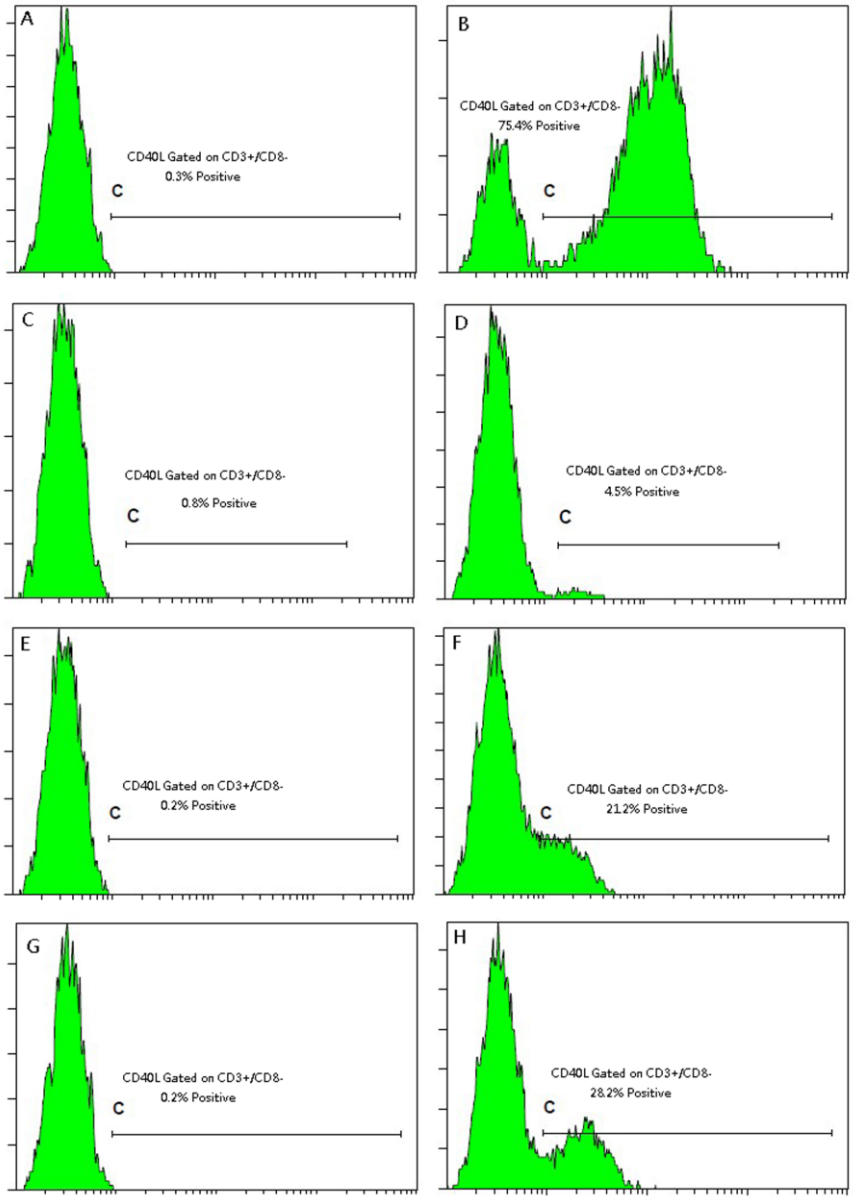

Figure 2. *CD40L* expression on unactivated and activated T cells of the patient and his family members by flow cytometry. The left side of figures were unactivated T cells as control (A: father; C: patient; E: mother; G: sister), and the right side of figures showed the expression of *CD40L* on CD3+CD8-T cells activated with PMA and ionomycin (B: father; D: patient; F: mother; H: sister).

position -3 of the acceptor splice site of intron 3 (IVS 3 (-3)) is identical with that of intron 4 (IVS 4 (-3)) as well, which makes exon 5 directly connect to exon 3 when splcing (i.e.,exon 4 skipping).This mutation caused a 21 amino acids deletion in the ECU and TNFH domains of CD40L. We also studied the expression of CD40L on activated CD3+CD8- T cells by three-color flow cytometry and demonstrated that the patient only had a negligible CD40L expression. Most studies have reported the detection of CD40L on activated CD4+ T cells by gating CD3+CD4+T cells,[13-15] but O'Gorman et al. reported that the expression of CD4 on PBMC would decrease after they were cultured and activated with PMA and ionomycin in vitro,[16] and we demonstrated the same in our experiments. Therefore, the activated CD3+CD8- T cells were gated to detect the expression of CD40L in our study.

In conclusion, we repor an unusual mutation in *CD40L*, which, to our knowledge, has not been reported previously.

Downloaded from http://apjai.digitaljournals.org. For personal use only. No other uses without permission.

Conflict of interest

The authors declare no conflict of interest.

Acknowledgements

This study was supported by grants from the Department of Science and Technology of Sichuan Province, China (No.2008JY0029-1) and research funds from the program for Changjiang Scholars and Innovative-Research Teams in Universities (No.IRT0935).We deeply thank the patient, his parents and his sister for their cooperation.

References

1. Notarangelo LD, Hayward AR. X-linked immunodeficiency with hyper-IgM(XHIM). Clin Exp Immunol. 2000;120:399-405.
2. Winkelstein JA, Marino MC, Ochs H, Fuleihan R, Scholl PR, Geha R, et al. The X-linked hyper-IgM syndrome: clinical and immunologic features of 79 patients. Medicine. 2003;82:373-84.
3. Prasad ML, Velickovic M, Weston SA, Benson EM. Mutational screening of the CD40 ligand (CD40L) gene in patients with X linked hyper-IgM syndrome (XHIM) and determination of carrier status in female relatives. J Clin Pathol. 2005;58:90-2.
4. Jesus AA, Duarte AJ, Oliveira JB. Autoimmunity in hyper-IgM syndrome. J Clin Immunol. 2008;28 (Suppl 1):S62-6.
5. Lin SC, Shyur SD, Lee WI, Ma YC, Huang LH. X-linked hyper-immunoglobulin M syndrome: molecular genetic study and long-time follow-up of three generations of a Chinese family. Int Arch Allergy Imm. 2006;140:1-8.
6. Mílledge J, Kakakios A, Gillis J, Fitzgerald DA. Pneumocystis carinii pneumonia as a presenting feature of X-linked hyper-IgM syndrome.J Paediatr Child Health. 2003;39:704-6.
7. Jo EK, Kim HS, Lee MY, Iseki M, Lee JH, Song CH, Park JK, Hwang TJ, Kook H. X-linked hyper-IgM syndrome associated with Cryptosporidium parvum and Cryptococcus neoformans infections: the first case with molecular diagnosis in Korea.J Korean Med Sci. 2002;17:116-20.
8. Sripa C, Mitchai J, Thongsri W, Sripa B. Diagnostic cytology and morphometry of Penicillium marneffei in the sputum of a hypogammaglobulinemia with hyper-IgM patient.J Med Assoc Thai. 2010;93 Suppl 3:S69-72.
9. Conley ME, Notarangelo LD, Etzioni A. Diagnostic Criteria for Primary Immunodeficiencies. Clin Immunol. 1999;93:190-7.
10. Erdos M, Garami M, Rakoczi E, Zalatnai A, Steinbach D, Baumann U, et al. Neuroendocrine carcinoma associated with X-linked hyper-immunoglobulin M syndrome: report of four cases and review of the literature. Clin Immunol. 2008;129:455-61.
11. Elgueta R, Benson MJ, de Vries VC, Wasiuk A, Guo Y, Noelle RJ. Molecular mechanism and function of CD40/CD40L engagement in the immune system. Immunol Rev. 2009;229:152–72.
12. Thusberg J, Vihinen M. The structural basis of hyper IgM deficiency - CD40L mutations. Protein Eng Des Sel. 2007;20:133-41.
13. Huang CF, Wang CL, Huang YF, Hsieh KS, Yang KD. Hyper-IgM Syndrome Complicated with Interstitial Pneumonia and Peritonitis. Chang Gung Med J. 2003;26:53-9.
14. Ma YC, Lee WI, Shyur SD, Lin SC, Huang LH, Wu JY. De Novo Mutation Causing X-linked Hyper-IgM Syndrome: A Family Study in Taiwan. Asian Pac J Allergy Immunol. 2005;23:53-9.
15. Rangel-Santos A, Wakim VL, Jacob CM, Pastorino AC, Cunha JM, Collanieri AC, et al. Molecular characterization of patients with X-linked Hyper-IgM syndrome: description of two novel CD40L mutations. Scand J Immunol. 2009;69:169-73.
16. O'Gorman MR, Zaas D, Paniagua M, Corrochano V, Scholl PR, Pachman LM. Development of a Rapid Whole Blood FlowCytometry Procedure for the Diagnosis of X-Linked Hyper-IgM Syndrome Patients and Carriers. Clin Immunol Immunopathol. 1997;85:172–81.

Downloaded from http://apjai.digitaljournals.org. For personal use only. No other uses without permission.