Asia Pac Allergy. 2018 Jul;8(3):e26
https://doi.org/10.5415/apallergy.2018.8.e26
pISSN 2233-8276·eISSN 2233-8268

Asia Pacific allergy

Case Report

Check for updates

An unusual dual hypersensitivity reaction to moxifloxacin in a patient

Semra Demir[1,*], **Derya Unal**[1], **Muge Olgac**[1], **Nilgun Akdeniz**[2], **Esin Aktas-Cetin**[2], **Asli Gelincik**[1], **Bahauddin Colakoglu**[1], **and Suna Buyukozturk**[1]

[1]Division of Immunology and Allergic Diseases, Department of Internal Medicine, Istanbul Faculty of Medicine, Istanbul University, Istanbul, Turkey
[2]Department of Immunology, Istanbul University, Institute of Experimental Medicine (DETAE), Istanbul, Turkey

OPEN ACCESS

Received: Mar 5, 2018
Accepted: Jul 13, 2018

***Correspondence to**
Semra Demir
Division of Immunology and Allergic Diseases, Department of Internal Medicine, Istanbul Faculty of Medicine, Istanbul University, Millet Street, Capa Istanbul, Turkey.
Tel: +90-212-414-2000
Fax: +90-212-532-4208
E-mail: ertansemra@yahoo.com

Copyright © 2018. Asia Pacific Association of Allergy, Asthma and Clinical Immunology. This is an Open Access article distributed under the terms of the Creative Commons Attribution Non-Commercial License (https://creativecommons.org/licenses/by-nc/4.0/) which permits unrestricted non-commercial use, distribution, and reproduction in any medium, provided the original work is properly cited.

ORCID iDs
Semra Demir
https://orcid.org/0000-0003-3449-5868

Author Contributions
Conceptualization: Semra Demir, Nilgun Akdeniz, Esin Aktas-Cetin, Asli Gelincik. Data curation: Semra Demir, Derya Unal, Muge Olgac, Nilgun Akdeniz, Esin Aktas-Cetin. Formal analysis: Semra Demir, Nilgun Akdeniz, Esin Aktas-Cetin, Suna Buyukozturk. Investigation: Semra Demir, Derya Unal, Muge Olgac, Nilgun Akdeniz, Esin Aktas-Cetin. Project administration: Semra Demir, Asli Gelincik, Bahauddin Colakoglu, Suna Buyukozturk. Resources: Semra Demir,

ABSTRACT

Both immediate and nonimmediate type hypersensitivity reactions (HRs) with a single dose of quinolone in the same patient have not been previously reported. A 47-year-old female patient referred to us because of the history of a nonimmediate type HR to radio contrast agent and immediate type HR to clarithromycin. She experienced anaphylaxis in minutes after the second dose of 50 mg when she was provocated with moxifloxacin. She was treated immediately with epinephrine, fluid replacement and methylprednisole and pheniramine. On the following day she came with macular eruptions, and she was treated with methylprednisolone. The positive patch test performed with moxifloxacin as well as the lymphocyte transformation test proved the T-cell mediated HR. In order to prove the immediate type HR, basophil activation test was performed but was found negative. This case report presents for the first time the 2 different types of HRs in a patient with a test dose of quinolone.

Keywords: Dual hypersensitivity reaction; Moxifloxacin; Anaphylaxis; Macular eruption; *In vitro* test

INTRODUCTION

In general, drug hypersensitivity reactions (DHR) are classified as immediate type reactions when occur in 1 hour after drug intake and are mostly IgE mediated such as urticaria and anaphylaxis. Nonimmediate type hypersensitivity reactions (HRs) including maculopapular eruptions and fixed drug eruptions which are mediated by T cells occur in one or more hours after drug ingestion [1]. Immunologically, the pathogenic mechanism differs and, by producing different types of cytokines, T cells play a major role in all types of HRs either by regulating IgE production or acting as effector cells [2].

Immediate or nonimmediate type HRs due to different drugs in different times can be experienced. According to some authors, an IgE-mediated reaction might be followed by a T-cell-mediated reaction but they concluded that an IgE and T-cell mediated reactions cannot be experienced together [3].

Generated by KOMIT PRESS

Asli Gelincik, Bahauddin Colakoglu, Suna Buyukozturk. Supervision: Asli Gelincik, Bahauddin Colakoglu, Suna Buyukozturk. Validation: Semra Demir, Derya Unal, Muge Olgac, Nilgun Akdeniz, Esin Aktas-Cetin, Asli Gelincik, Bahauddin Colakoglu, Suna Buyukozturk. Writing - original draft: Semra Demir, Derya Unal, Muge Olgac, Nilgun Akdeniz, Esin Aktas-Cetin, Asli Gelincik, Bahauddin Colakoglu, Suna Buyukozturk. Writing - review & editing: Semra Demir, Bahauddin Colakoglu, Suna Buyukozturk.

HRs to quinolones which are widely used antimicrobial agents display the same pattern of most drug reactions consisting of immediate and nonimmediate DHRs [4].

Here, we report an unusual case who experienced both immediate and nonimmediate types of HRs due to a test dose of moxifloxacin.

CASE REPORT

A 47-year-old female patient referred to us because of a history of a nonimmediate type HR to radio contrast media that occurred 3 years previously and immediate type HRs to clarithromycin at 2 different times in order to identify safe alternative antibiotics. We started drug allergy work-up with the confirmation of the clarithromycin hypersensitivity which is relatively rare [5]. The prick test performed with clarithromycin was positive [6]. Because claritromycin can lead to false positive result due to irritation effect we offered drug provocation test but the patient refused. Then in order to identify safe alternative antibiotics we performed the skin prick and intradermal tests with moxifloxacin as previously suggested which were negative [7]. Delayed reading of intradermal tests were negative as well. She was then challenged in a single blind placebo controlled manner with moxifloxacin orally. It was planned to give the drug with incremental doses of 5-50-100-100-150 mg with 30 minutes intervals. After the second dose of 50 mg, pruritus and mild erythema on her body occurred in minutes and followed by dizziness. Patient's pulse was very weakly palpable, tachycardic and the blood pressure was very low that could not be measured. She was treated immediately with 0.5 mg of epinephrine, fluid replacement, 40 mg of methylprednisolone (intravenous) and 45.5 mg of pheniramine (intravenous). On the following day she returned with macular eruptions on the trunk and on the proximal extremities which had started with pruritus approximately 20 hours after the drug ingestion (**Fig. 1A**). Her biochemical tests and differential blood counts were normal. She did not consume any other drugs concomitantly and she had no signs or symptoms of infections. She was treated with methylprednisolone and approximately in 10 days eruptions resolved. A patch test performed with moxifloxacin diluted in petrolatum to obtain the drug concentration of 30% was applied on the upper back approximately 2 months later, after the resolution of signs and symptoms, was found positive (**Fig. 1B**), confirming nonimmediate type HR reaction

Fig. 1. (A) Macular eruptions developed 20 hours after drug ingestion. (B) Positive patch test performed with moxifloxacin.

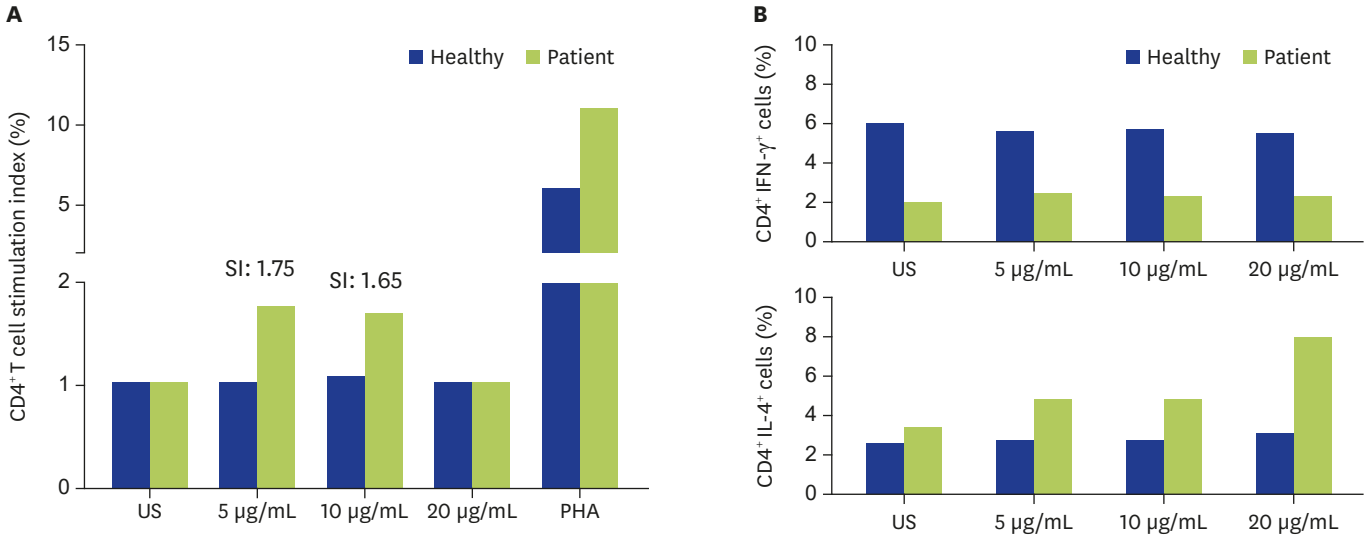

Fig. 2. (A) Proliferation of CD4+ T cells in response to moxifloxacin: demonstrates the expansion of CD4+ T cells during culture with doses of 5- and 10-μg/mL moxifloxacin. (B) Intracellular interleukin-4 level was higher and interferon-γ level was lower in CD4+ T cells than the levels of the healthy subject. Both results proved that the hypersensitivity reaction was mediated by CD4+ T cells. SI, stimulation index; US, unstimulated; PHA, phytohaemagglutinin.

to moxifloxacin [7]. To check the possible irritation effect of the drug, we performed patch test with the drug in 5 patients who were known to tolerate moxifloxacin and all they were negative. In order to support the diagnosis of immediate and nonimmediate type reactions, lymphocyte transformation test (LTT) and intracellular interleukin (IL)-4 and interferon-gamma (IFN-γ) levels and basophil activation test (BAT) were performed as described in the literature [8]. A stimulation index for LTT was defined as proliferation ratio of moxifloxacin-specific CD4+ T cell to unstimulated cells and result of BAT was interpreted as positive when the percentage of CD63 was 5% above the negative control [8]. BAT was negative while the CD4+ T-cell proliferation stimulation indexes were found 1.75 and 1.65 in doses of 5- and 10-μg/mL moxifloxacin, respectively. Moreover, intracellular IL-4 level was high and IFN-γ level was low in CD4+ T cells when compared with a healthy subject (**Fig. 2**). She was subsequently able to tolerate clindamycin.

DISCUSSION

This case report describes both an immediate and a nonimmediate type of HR occurring consecutively due to a test dose of quinolone. Although *in vitro* diagnostic tests partially support the diagnosis, the clinical observations confirm the possibility of consequent occurrence of these reactions in only 20 hours.

Nonimmediate HRs to quinolones which are widely used antibiotics, are less frequent than immediate reactions and maculopapular exanthemas and fixed drug eruptions are the more commonly reported nonimmediate HRs to quinolones [4].

To the best of our knowledge, our case is the first one presenting with both immediate and nonimmediate reactions with the test dose of a drug in 20 hours. As methylprednisolone and antihistamine were used without any adverse event for the patient's previous drug reactions, they were not implicated for the macular eruptions in the late phase.

The negative BAT and skin test results failed to confirm an IgE-mediated mechanism. BAT can be very useful in supporting diagnosis of drug induced severe immediate type of HRs [9, 10]. However, it has been previously reported that in quinolone hypersensitivity both skin testing and BAT can be found negative [5].

Additionally, although the stimulation index in LTT was low, intracellular cytokine responses supported the activation of $CD4^+$ T cells. Regarding these *in vivo* and *in vitro* test results we can hypothesize 3 explanations: (1) Since we could only show a T-cell mechanism, it could be an accelerated T-cell response with an early starting T-cell mediated reaction which mostly appears as urticaria and has been reported especially with beta lactams [11]. However our case did not fit into this type of reaction especially in the context of her clinical features. (2) It could be both immediate and nonimmeditae type of sensitizations to the same drug although we could not confirm an IgE-mediated sensitization. (3) Lastly, it could be a biphasic T-cell driven HR, starting like an immediate reaction than evolving to a nonimmediate type HR. In 80's van Loveren et al. [12] described an early component of delayed type hypersensitivity mediated by T cells and mast cells. They showed that mast cell activation was caused by a T-cell derived antigen binding factor suggesting a biphasic HR mediated both by T cells and T-cell dependent mast cells and this reaction was not elicited in mast cell deficient mice in their animal study [12]. Although biphasic reactions were classically induced by proteins and to date any biphasic reactions were not reported with a drug, this pathogenic mechanism might explain our patient's reaction.

In conclusion, this is the first case report which presents a HR starting as anaphylaxis in minutes and progressing into macular eruptions in 20 hours after intake of a single dose of moxifloxacin. Although it is uncommon, clinicians must be aware that drugs can cause such unusual HRs.

REFERENCES

1. Gómez E, Torres MJ, Mayorga C, Blanca M. Immunologic evaluation of drug allergy. Allergy Asthma Immunol Res 2012;4:251-63.
   PUBMED | CROSSREF
2. Torres MJ, Mayorga C, Blanca-López N, Blanca M. Hypersensitivity reactions to beta-lactams. EXS 2014;104:165-84.
   PUBMED | CROSSREF
3. Pichler WJ, Daubner B, Kawabata T. Drug hypersensitivity: flare-up reactions, cross-reactivity and multiple drug hypersensitivity. J Dermatol 2011;38:216-21.
   PUBMED | CROSSREF
4. Blanca-López N, Andreu I, Torres Jaén MJ. Hypersensitivity reactions to quinolones. Curr Opin Allergy Clin Immunol 2011;11:285-91.
   PUBMED | CROSSREF
5. Seitz CS, Bröcker EB, Trautmann A. Suspicion of macrolide allergy after treatment of infectious diseases including Helicobacter pylori: results of allergological testing. Allergol Immunopathol (Madr) 2011;39:193-9.
   PUBMED | CROSSREF
6. Rouzaire P, Nosbaum A, Denis L, Bienvenu F, Bérard F, Cozon G, Bienvenu J. Negativity of the basophil activation test in quinolone hypersensitivity: a breakthrough for provocation test decision-making. Int Arch Allergy Immunol 2012;157:299-302.
   PUBMED | CROSSREF
7. Barbaud A, Gonçalo M, Bruynzeel D, Bircher AEuropean Society of Contact Dermatitis. Guidelines for performing skin tests with drugs in the investigation of cutaneous adverse drug reactions. Contact Dermatitis 2001;45:321-8.
   PUBMED | CROSSREF

8. Demir S, Gelincik A, Akdeniz N, Aktas-Cetin E, Olgac M, Unal D, Ertek B, Coskun R, Colakoğlu B, Deniz G, Buyukozturk S. Usefulness of *in vivo* and *in vitro* diagnostic tests in the diagnosis of hypersensitivity reactions to quinolones and in the evaluation of cross-reactivity: a comprehensive study including the latest quinolone gemifloxacin. Allergy Asthma Immunol Res 2017;9:347-59.
PUBMED | CROSSREF
9. Lee HS, Song WJ, Lee JW, Cho YY, Park HK, Kang MG, Cho SH, Sohn SW. Chlorpheniramine-induced anaphylaxis diagnosed by basophil activation test. Asia Pac Allergy 2015;5:177-80.
PUBMED | CROSSREF
10. Song WJ, Chang YS. Recent applications of basophil activation tests in the diagnosis of drug hypersensitivity. Asia Pac Allergy 2013;3:266-80.
PUBMED | CROSSREF
11. Gómez E, Blanca-Lopez N, Salas M, Canto G, Campo P, Torres MJ, Mayorga C, Blanca M. Induction of accelerated reactions to amoxicillin by T-cell effector mechanisms. Ann Allergy Asthma Immunol 2013;110:267-73.
PUBMED | CROSSREF
12. van Loveren H, Meade R, Askenase PW. An early component of delayed-type hypersensitivity mediated by T cells and mast cells. J Exp Med 1983;157:1604-17.
PUBMED | CROSSREF