Check for updates

Received: 31 December 2021 | Revised: 11 April 2022 | Accepted: 13 April 2022

DOI: 10.1111/cea.14148

RESEARCH LETTER

WILEY

A novel gain-of-function mutation in *STAT5B* is associated with treatment-resistant severe atopic dermatitis

To the Editor,

Janus kinase (JAK) and signal transducer and activator of transcription (STAT) pathways are among the major cellular pathways that integrates signals from cytokines, growth factors and hormones to regulate proliferation, survival, differentiation, as well as apoptosis.[1] STAT proteins are critical mediators of cytokine signals that regulate gene expression programs underlying key processes involved in the immune system. STAT5B is a cytosolic protein involved in signal transduction in response to several cytokines, including IL-2, IL-7 and IL-15. STAT5 signalling promotes T cell proliferation and survival, maintain FOXP3+ regulatory T (Treg) cells, and expand Treg cells that promote cancers by inhibiting the antitumor activity and leading to the progression of tumours. Consistent with these findings, exaggerated STAT5B activity is often linked to malignancies.[2] Somatic heterozygous gain-of-function mutations (GOF) in STAT5B, N642H mutation, have been described in multiple leukaemias and lymphomas in humans.[2–4] Increased STAT5 signalling has also been shown to cause allergic and myeloproliferative phenotypes in murine models.[5,6] Interestingly, in correlation with these findings, somatic heterozygous GOF STAT5B N642H mutation has been reported in two independent children with neonatal-onset urticaria, diarrhoea, granulomatous skin lesions and some infectious episodes but without any signs of neoplasm. It was also noteworthy that there were markedly elevated levels of eosinophils.[7] Since there are only two described patients with an identical mutation in the *STAT5B* gene with nonneoplastic phenotype, we expand the repertoire of such mutations reporting a patient with a novel heterozygous *STAT5B* mutation presenting with treatment-resistant severe atopic dermatitis, urticarial rash and hair loss.

A 7-year-old girl born to non-consanguineous parents presented with treatment-resistant atopic dermatitis, urticarial rash, hair loss, multiple food allergies, allergic rhinitis and allergic asthma was admitted to hospital. She was a full-term born baby with no complaints up to 1-month-old who was later found to have atopic eczema with cow's milk, egg and nuts allergies. She had recurrent otitis at 2–3 years of age, atopic dermatitis with hair loss, and angioedema attacks with walnut by 5 years of age. Partial response was seen with dietary elimination of cow's milk, egg and nuts until 3 years of age and dietary elimination continues with nuts. She has been using topical corticosteroids, calcineurin inhibitors and intermittent systemic corticosteroid for more than 4 years. The patient's allergic asthma is under control with inhaler corticosteroid prophylaxis. She has no respiratory tract infections, abscesses or diarrhoea. Her family history was significant for atopic diseases as her father has atopic dermatitis and seborrheic dermatitis and multiple paternal relatives has atopic dermatitis, allergic rhinitis and allergic asthma. There was no family history of consanguinity, autoimmunity, immunodeficiency, haematological malignancy or unexplained deaths (Figure 1A).

Physical examination revealed eczematous lesions on the hands, back of the knees, elbows, face, around the eyes, trunk and ankles, and her score of atopic dermatitis (SCORAD) was 86 (Figure 1B). Her height and weight were in 50th percentile, and aside from the dermatological symptoms, physical examination was normal. Laboratory findings revealed eosinophilia (7600/mm^3) and immunoglobulin E (IgE) elevation (17,818 IU/kl). Other immunoglobulins (IgG, IgA, IgM) and antibody responses to childhood immunizations were normal. She was also evaluated for autoantibodies, such as anti-neutrophil antibodies, anti-thyroid antibodies, and the results were negative. Lymphocyte subgroup analyses were within normal limits according to age-matched reference values except for elevated effector memory CD4+ T cells and terminal effector memory (TEMRA) CD8+ T cells.

Next-generation sequencing analysis was performed on genomic DNA from peripheral blood mononuclear cells (PBMCs) using SOPHiA Clinical Exome Solution that covers the coding regions (±5 bp of intronic regions) of 4490 genes (target region of 12 Mb) related to rare inherited diseases including the hyper IgE syndromes (DOCK8, STAT3, PGM3, etc.) and the genetic causes of the hypereosinophilic syndromes and no pathogenic mutations were identified for these syndromes. Heterozygous STAT5B c.650 G>A p.Arg217His mutation was identified and this variant was not registered in the following genetic public database: HGMD, LOVD, NCBI ClinVar, dbSNP and ExAC. To determine pathogenicity *in silico* of this variant we used online prediction programs: Mutation Taster, PolyPhen (Figure 1C). Sanger sequencing of parents for STAT5B determined that her father had the same mutation. He had milder eczema with severe alopecia and a history of refractory childhood dermatitis like his daughter. The mutation lies in the coiled-coiled region of STAT5B; however, it appears to be conserved across species (Figure 1D,E).

The pathogenic GOF mutations described up to now lie in the Src homology 2 (SH2) domain of the protein, which governs interactions with phosphotyrosines.[3] Others, however, described a heterozygous dominant negative mutation in the coiled-coiled region (p.Gln177Pro substitution).[8] p.Gln177Pro variant did not impact STAT5 phosphorylation, rather reduced STAT5B nuclear localization, the patient thus presented with short stature and mild immune dysregulation.[8]

To assess whether the mutation is a gain of function in our patient, basal and cytokine induced STAT5 phosphorylation was studied. At the basal level without stimulation, the patient and the father's samples showed significantly increased STAT5

 © 2022 John Wiley & Sons Ltd

13652222, 2022, 7, Downloaded from https://onlinelibrary.wiley.com/doi/10.1111/cea.14148 by University Of Liverpool, Wiley Online Library on [22/01/2023]. See the Terms and Conditions (https://onlinelibrary.wiley.com/terms-and-conditions) on Wiley Online Library for rules of use; OA articles are governed by the applicable Creative Commons License

phosphorylation (pSTAT5-PE (Y694)) compared with healthy controls supporting that the mutation could lead to gain of function (Figure 1F,G). Since STAT5 mediated signalling is important in Treg cell expansion and function, their numbers were assessed in the patient and controls. Treg cell frequency among CD4+ T cells were higher than those of healthy control in samples taken from the patient at different times (Figure 2A). Such increase has not been reported in the case by Ma et al.,[7] which may perhaps be attributed to the location of the mutation in STAT5B (coiled-coiled domain vs. SH2 domain). Additionally, to test whether Treg cells are deficient in production of cytokines that mediate suppression, CD3+CD4+CD25+ Treg cells were sort purified and *IL10* and *TGFβ* expression was quantified by real-time qPCR (Figure 2A). *IL10* expression was comparable across the patient, father and the control. *TGFβ* expression was significantly higher in the Treg cells of the father, and perhaps may explain the milder phenotype of the father. In response to different T cell mitogens CD3, CD28, PHA, PMA-Ionomycin, and IL-2 stimulation, the T cells belonging to healthy control proliferated more efficiently (Figure 2B,C). Although total proliferation by the patient's T cells was slightly reduced, more detailed examination of highly or moderately proliferating fraction revealed a more dramatic difference. While highly proliferating fraction was less, moderately proliferating cells were higher among the patient's T cells, which was inverted in the healthy control and the father (Figure 2B,C).

To better understand the mechanism of eczema in the patient, IL-4 cytokine production by PBMCs were investigated (Figure 2A). No detectable differences were observed between the patient, father and healthy control samples, ruling out an IL-4 mediated mechanism for the pathogenesis of atopy. Skin biopsy samples from the patient, the father and an unrelated control (taken from healthy skin region of an actinic keratosis patient) were investigated with respect to the expression of *RORC*, *FOXP3*, *IL-22*, *AREG*,

Key messages

- Heterozygous STAT5B c.650 G>A p.Arg217His mutation led to gain of function, and was correctable by ruxolitinib in vitro.
- This germline variant was associated with severe treatment-resistant or mild eczema in the daughter and father, respectively.
- Skin inflammation was marked by elevated IL22 or IL5 in the daughter and father, respectively.

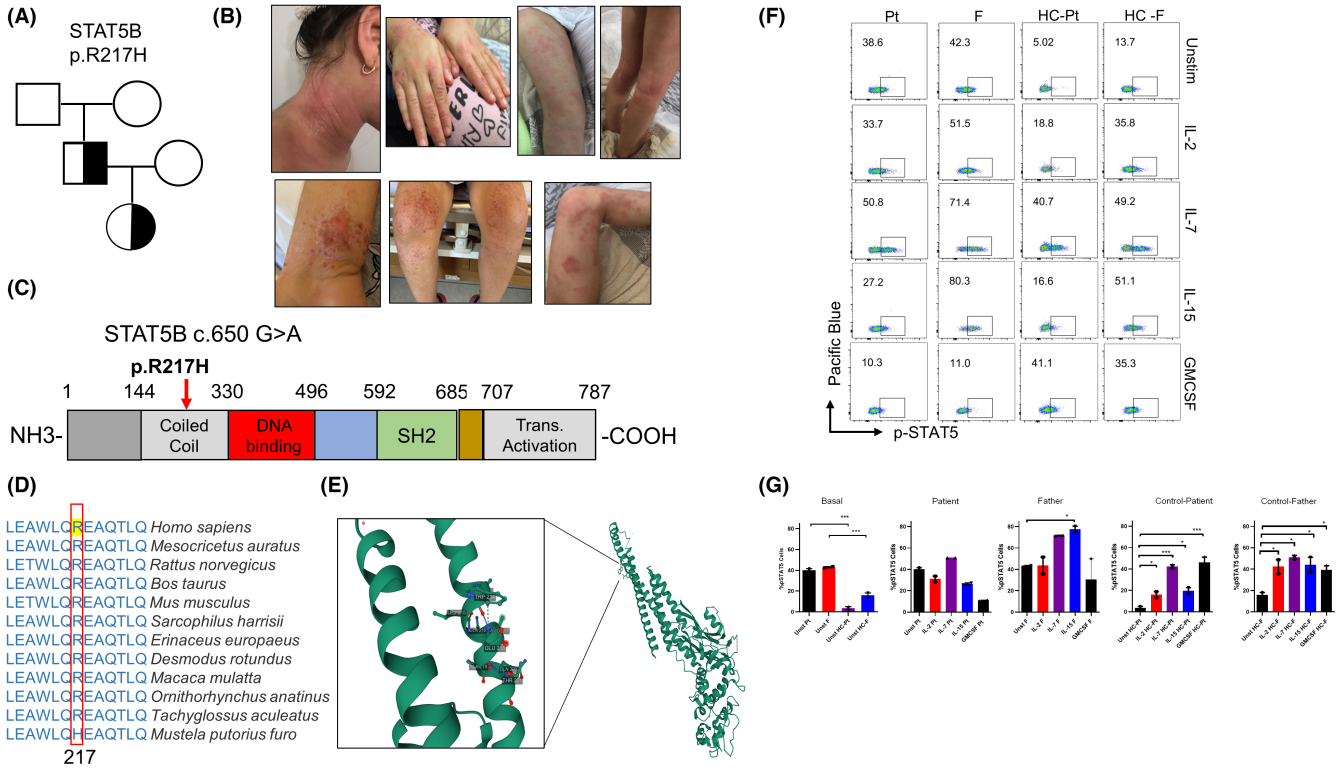

FIGURE 1 (A) The pedigree of the patient. (B) Physical examination revealed eczematous lesions on the hands, back of the knees, elbows, face, around the eyes, trunk and ankles, and her SCORAD was 86. (C) Cartoon of STAT5B domains. *STAT5B* c.650 G>A p.Arg217His mutation was detected. Sanger sequencing of parents for *STAT5B* revealed that her father had the same mutation but only mild eczema. (D) Alignment of STAT5B amino acid sequences around the mutation site (p.217) across different species' 3D structure of STAT5B Protein. (E) Three-dimensional ribbon diagram of STAT5B and the location of the mutation in the coiled-coiled domain. (F) pSTAT5-PE (Y694) levels in lymphocytes prior to and after 20 min of stimulation with IL-2 and IL-7, IL-15 and GM-CSF cytokines a representative flow plots were shown, their quantification with 2–3 technical replicates in (G). For *p*-values *<.05, **<.01, ***<.001

13652222, 2022, 7, Downloaded from https://onlinelibrary.wiley.com/doi/10.1111/cea.14148 by University Of Liverpool, Wiley Online Library on [23/01/2023]. See the Terms and Conditions (https://onlinelibrary.wiley.com/terms-and-conditions) on Wiley Online Library for rules of use; OA articles are governed by the applicable Creative Commons License

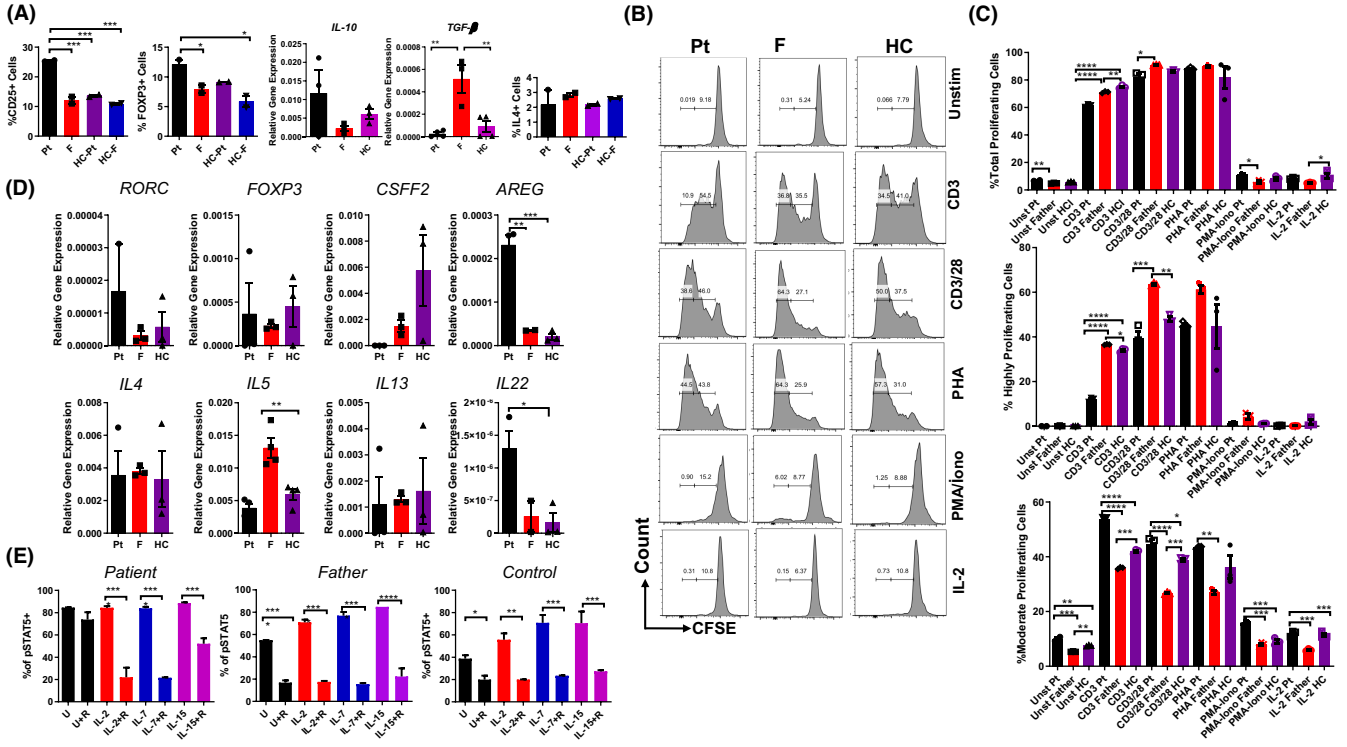

FIGURE 2 (A) Treg cells frequency was shown by both CD25 and FOXP3 staining. IL-4 cytokine production by CD3+CD4+ T cells was quantified upon stimulation with PMA/Ionomycin, three technical replicates were used. (B) Decreased proliferation of patient's T cells in response to mitogens compared to the control and father. (C) Representative flow plots and quantified percentages. (D) Gene expression of *IL4*, *IL5*, *IL13*, *IL22*, *Amphiregulin (AREG)*, *RORC*, *FOXP3*, *CSF2* in skin biopsies of the patient, father and a control. (E) The PBMCs from the patient, father and control were pretreated with 5 μg/ml ruxolitinib or not treated for 2 h in the serum-free media, then stimulated with IL-2, IL-7 and IL-15 for 20 min in the presence or absence of ruxolitinib and then, fixed, permeabilized and stained for pSTAT5. For *p*-values *<.05, **<.01, ***<.001

IL4, *IL5*, *IL13*, *CSF2* genes by real-time qPCR (Figure 2D). IL4 expression was similar across the patient, the father, and the control, supporting the intracellular cytokine staining results. Additionally, *RORC*, *FOXP3*, *IL13*, *CSF2* expression was comparable between the patient, father, and the control (Figure 2D). Father, however, had elevated *IL5* expression compared with the patient and the control. Interestingly, in the patients' skin biopsies significantly elevated *IL22*, and amphiregulin expression were detected. These results underline a few important points in the management of the disease: The patient may not benefit from IL-4, IL-5 or IL-13 blockers. The mild case of eczema in the father may benefit from IL-5 blockers, but other first line therapies are currently sufficient. Lastly, given the critical role of IL-22 in atopic dermatitis, IL-22 blockade in the patient may be beneficial in treating her severe eczema in the patient.[9]

Due to severe, worsening symptoms unresponsive to standard treatments, the patient received intravenous immunoglobulin replacement therapy and showed significant benefit. For this patient, due to increased baseline STAT5B activity, treatment with JAK inhibitors[10] will likely be a good option in future follow-up. Indeed, pretreatment with ruxolitinib of PBMCs from the patient, father and controls in vitro was able to reduce STAT5 phosphorylation to various degrees (Figure 2E).

In conclusion, our results provide novel information regarding STAT5B-GOF disease, expand the limited number of patients described in this context, and show that a patient with a novel STAT5B GOF mutation may present with severe atopic dermatitis, neonatal-onset urticarial rash, hair loss and show a non-malignant phenotype unlike other phenotypes previously described.[2–5] Further validation by insertion of the mutation or correction in T cell lines or primary T cells will shed more light on the definitive role of the p.R217H mutation. STAT5B GOF is a newly identified primary immunodeficiency with an unknown clinical spectrum. Identifying the molecular cause of such presentations increases the potential for targeted therapeutic interventions.

ACKNOWLEDGEMENTS

We thank the donors and GENKOK administrative personnel.

CONFLICT OF INTEREST

The authors declare no competing interests.

AUTHOR CONTRIBUTIONS

NK, AE conceptualized the study. NK, AE, KA, OC wrote the manuscript. AE, HC, KA performed the experiments. NK, LTK, HB, OC, MA cared for patients, provided samples, intellectually contributed

13652222, 2022, 7, Downloaded from https://onlinelibrary.wiley.com/doi/10.1111/cea.14148 by University Of Liverpool, Wiley Online Library on [22/01/2023]. See the Terms and Conditions (https://onlinelibrary.wiley.com/terms-and-conditions) on Wiley Online Library for rules of use; OA articles are governed by the applicable Creative Commons License

to the manuscript and discussions. All authors read the manuscript, contributed to the revision and discussions.

ETHICAL APPROVAL

All the experiments were performed according to relevant guidelines and regulations. The experimental procedures were approved by Erciyes University Institutional Review Board #2021/17.

DATA AVAILABILITY STATEMENT

Additional information about study methods is available in the following repository 10.5281/zenodo.5809618, 10.5281/zenodo.5812231.

Nurhan Kasap[1]
Kubra Aslan[2]
Leman Tuba Karakurt[1]
Hayrunnisa Bozkurt[1]
Halit Canatan[2]
Ozlem Cavkaytar[1]
Ahmet Eken[2]
Mustafa Arga[1]

[1]*Department of Pediatric Allergy-Immunology, Istanbul Medeniyet University Faculty of Medicine, Istanbul, Turkey*
[2]*Department of Medical Biology, Genome and Stem Cell Center (GENKOK), Erciyes University Faculty of Medicine, Kayseri, Turkey*

Correspondence
Nurhan Kasap, Division of Pediatric Allergy/Immunology, Medeniyet University, Istanbul, Turkey.
Email: n_aruci@hotmail.com
Ahmet Eken, Department of Medical Biology, Erciyes University Faculty of Medicine, Kayseri 38030, Turkey.
Email: ahmet.eken@gmail.com

ORCID

Nurhan Kasap https://orcid.org/0000-0001-5432-4076
Kubra Aslan https://orcid.org/0000-0002-5952-906X
Leman Tuba Karakurt https://orcid.org/0000-0003-0818-8063
Hayrunnisa Bozkurt https://orcid.org/0000-0001-8642-4872
Halit Canatan https://orcid.org/0000-0002-0978-8311
Ozlem Cavkaytar https://orcid.org/0000-0002-5747-7032
Ahmet Eken https://orcid.org/0000-0002-5816-0686
Mustafa Arga https://orcid.org/0000-0002-0940-7398

REFERENCES

1. Hwa V. STAT5B deficiency: impacts on human growth and immunity. *Growth Horm IGF Res*. 2016;28:16-20. doi:10.1016/j.ghir.2015.12.006
2. Bandapalli OR, Schuessele S, Kunz JB, et al. The activating STAT5B N642H mutation is a common abnormality in pediatric T-cell acute lymphoblastic leukemia and confers a higher risk of relapse. *Haematologica*. 2014;99(10):e188-e192. doi:10.3324/haematol.2014.104992
3. Kucuk C, Jiang B, Hu X, et al. Activating mutations of STAT5B and STAT3 in lymphomas derived from gammadelta-T or NK cells. *Nat Commun*. 2015;6:6025. doi:10.1038/ncomms7025
4. Cross NCP, Hoade Y, Tapper WJ, et al. Recurrent activating STAT5B N642H mutation in myeloid neoplasms with eosinophilia. *Leukemia*. 2019;33(2):415-425. doi:10.1038/s41375-018-0342-3
5. Kawakami T, Ando T, Kawakami Y. Hypothetical atopic dermatitis-myeloproliferative neoplasm syndrome. *Front Immunol*. 2015;6:434. doi:10.3389/fimmu.2015.00434
6. Ando T, Xiao W, Gao P, et al. Critical role for mast cell Stat5 activity in skin inflammation. *Cell Rep*. 2014;6(2):366-376. doi:10.1016/j.celrep.2013.12.029
7. Ma CA, Xi L, Cauff B, et al. Somatic STAT5b gain-of-function mutations in early onset nonclonal eosinophilia, urticaria, dermatitis, and diarrhea. *Blood*. 2017;129(5):650-653. doi:10.1182/blood-2016-09-737817
8. Klammt J, Neumann D, Gevers EF, et al. Dominant-negative STAT5B mutations cause growth hormone insensitivity with short stature and mild immune dysregulation. *Nat Commun*. 2018;9(1):2105. doi:10.1038/s41467-018-04521-0
9. Brunner PM, Israel A, Zhang N, et al. Early-onset pediatric atopic dermatitis is characterized by TH2/TH17/TH22-centered inflammation and lipid alterations. *J Allergy Clin Immunol*. 2018;141(6):2094-2106. doi:10.1016/j.jaci.2018.02.040
10. Eisenberg R, Gans MD, Leahy TR, et al. JAK inhibition in early-onset somatic, nonclonal STAT5B gain-of-function disease. *J Allergy Clin Immunol Pract*. 2021;9(2):1008-1010.e2. doi:10.1016/j.jaip.2020.11.050

How to cite this article: Kasap N, Aslan K, Karakurt LT, et al. A novel gain-of-function mutation in *STAT5B* is associated with treatment-resistant severe atopic dermatitis. *Clin Exp Allergy*. 2022;52:907–910. doi:10.1111/cea.14148

13652222, 2022, 7, Downloaded from https://onlinelibrary.wiley.com/doi/10.1111/cea.14148 by University Of Liverpool, Wiley Online Library on [22/01/2023]. See the Terms and Conditions (https://onlinelibrary.wiley.com/terms-and-conditions) on Wiley Online Library for rules of use; OA articles are governed by the applicable Creative Commons License