Clinics in Dermatology (2013) **31**, 455–463

ELSEVIER

Clinics in Dermatology

Skin diseases associated with *Malassezia* yeasts: Facts and controversies

Georgios Gaitanis, MD[a,*], Aristea Velegraki, MD[b], Peter Mayser, MD[c], Ioannis D. Bassukas, MD[a]

[a]*Department of Skin and Venereal Diseases, University of Ioannina Medical School, Ioannina, Greece*
[b]*Mycology Laboratory, Microbiology Department, Medical School, National and Kapodistrian University of Athens, Athens Greece*
[c]*Department of Dermatology and Andrology, Justus Liebig University Giessen, Giessen, Germany*

Abstract The implication of the yeast genus *Malassezia* in skin diseases has been characterized by controversy, since the first description of the fungal nature of pityriasis versicolor in 1846 by Eichstedt. This is underscored by the existence of *Malassezia* yeasts as commensal but also by their implication in diseases with distinct absence of inflammation despite the heavy fungal load (pityriasis versicolor) or with characteristic inflammation (eg, seborrheic dermatitis, atopic dermatitis, folliculitis, or psoriasis).

The description of 14 *Malassezia* species and subsequent worldwide epidemiologic studies did not reveal pathogenic species but rather disease—associated subtypes within species. Emerging evidence demonstrates that the interaction of *Malassezia* yeasts with the skin is multifaceted and entails constituents of the fungal wall (melanin, lipid cover), enzymes (lipases, phospholipases), and metabolic products (indoles), as well as the cellular components of the epidermis (keratinocytes, dendritic cells, and melanocytes).

Understanding the complexity of their interactions will highlight the controversies on the clinical presentation of *Malassezia*-associated diseases and unravel the complexity of skin homeostatic mechanisms.
© 2013 Elsevier Inc. All rights reserved.

Historical perspectives

Controversy has been intrinsic to *Malassezia* yeasts and their association with certain skin diseases since the first recognition of the fungal nature of pityriasis versicolor (PV) by Karl Ferdinand Eichstedt (1816-1892) in 1846, when he noticed the budding yeast cells and hyphae in the lesions of this condition.[1] Some years later, (1873) Sebastiano Rivolta (1832-1893) noticed in "psoriatic" scales the double-contour budding yeast cells and gave them the name *Cryptococcus psoriasis*.[2] In 1874, Louis-Charles Malassez (1842-1909) attributed to the yeast, which later would take his name, scalp scaling (dandruff) and differentiated it from dermatophytes. For this reason, Henri Baillon (1827-1895) in 1889 suggested the name *Malassezia furfur*, adding "furfur" in order to describe the fine scaling of dandruff (furfur: Scurf; dandruff; http://www.websters-online-dictionary.org/definitions/furfur). In 1904, Raymond Sabouraud (1864-1938) noticed the association of the organism he named *Pityrosporum malassezii* with dandruff, and in 1913, Aldo Castellani (1875-1971) and Albert J. Chalmers (1870-1920)

* Corresponding author. Tel.: +302651007530; fax: +302651007031.
E-mail address: ggaitan@cc.uoi.gr (G. Gaitanis).

0738-081X/$ – see front matter © 2013 Elsevier Inc. All rights reserved.
http://dx.doi.org/10.1016/j.clindermatol.2013.01.012

introduced the name *Pityrosporum ovale* and in 1925 they managed to isolate the organism in culture.[3] In 1951, Morris A. Gordon isolated from PV lesions and healthy skin the double-contour, globose cells that he named *Pityrosporum orbiculare*.[4]

The cumbersome isolation procedures and the induction of the hyphal state *in vitro* maintained the controversies in the nomenclature of this species for many years. During this period, mycologists used the genus name *Malassezia* and recognized two species, *M furfur*, the human commensal and pathogen and *M pachydermatis*, the non-strictly lipophilic animal pathogen. Dermatologists used the genus name *Pityrosporum* for *P ovale* isolated from seborrheic dermatitis (SD) lesions and *P orbiculare* for the PV isolate.[3] For the animals *P pachydermatis* and *P canis* were used interchangeably.[5] The genus names *Malassezia* and *Pityrosporum* were considered to describe identical organisms by Wilhelmina Ch. Slooff in 1970[6] and this was confirmed few years later in the seminal work of Eveline Guého.[7,8] Since the time of first use, the genus name *Malassezia* was given priority over *Pityrosporum*.

In this contribution, we review available data that demonstrate controversies in the taxonomy, physiology, and biochemistry of this yeast in relation to skin diseases caused or aggravated by it.

Malassezia-associated skin diseases

Pityriasis versicolor

The association of *Malassezia* yeasts with PV (Figure 1A) is undisputed because it is associated with profuse growth of this fungus on the skin surface with transformation of the yeast to the hyphal form. This is evident in pathology slides (Figure 1B), whereas in direct microscopy it takes the characteristic "spaghetti and meatballs" feature (Figure 1C, 1D). Usually the disease presents with minimal to no inflammation, which also is evident in skin biopsies, despite the heavy fungal load (Figure 1B). The most common clinical forms of the disease are hypopigmented (PV alba) and hyperpigmented PV. Sometimes, it can present as PV rubra, characterized by dilations of dermal vasculature[9] or atrophying PV with atrophic lesions that may resolve after antifungal therapy.[10]

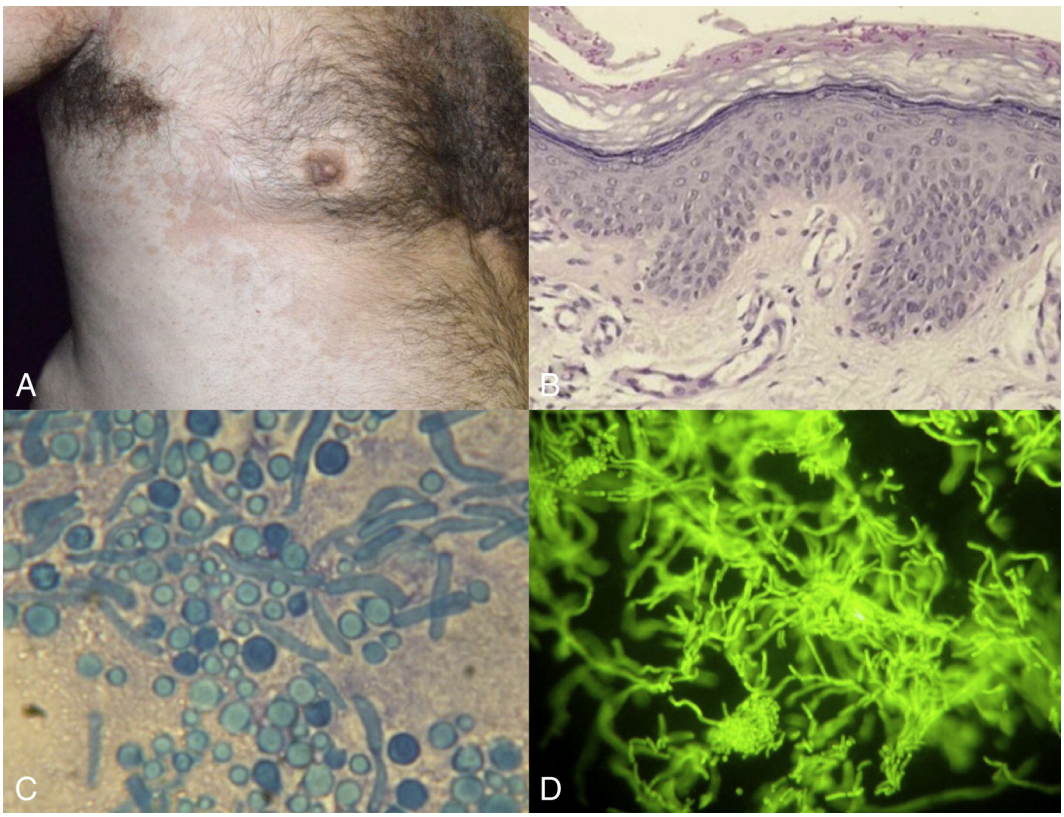

Fig. 1 Clinical, histologic, and direct microscopy findings in pityriasis versicolor. (A) Typical lesion of pityriasis versicolor on the trunk of 54-year-old man. (B) Histology of pityriasis versicolor, with evident absence of inflammatory infiltrate in the dermis and the abundant yeasts and hyphae in the entire stratum corneum (hematoxylin-eosin stain. original magnification X 200). (C) "Spaghetti and meatballs" appearance of the hyphae and yeast cells of *Malassezia* on the direct microscopy of pityriasis versicolor skin scales stained with Parker's ink (original magnification X 1,000). (D) Pityriasis versicolor skin scales after Calcofluor staining.

Seborrheic dermatitis and dandruff

SD is an inflammatory dermatosis confined to anatomical areas that are characterized by accumulation of active sebaceous glands (ie, the midface, chest, back, and scalp; Figure 2). The association of *Malassezia* yeasts with SD pathogenesis has been underscored by controversy through time. During the 1970s, the corresponding pathophysiological connection was disputed but resurfaced in the 1980s with a review that highlighted the common antifungal pharmacologic properties of the substances used for the treatment of SD.[11] There is emerging evidence that connects *Malassezia* synthesis of bioactive indoles[12] and lipase production,[13] as well as cytokine induction by keratinocytes[14] with SD.

Dandruff is used to describe flaking of the scalp with or without associated skin inflammation.[15] Sometimes, the condition is characterized as a mild form of SD, but there is no solid evidence to substantiate such an association. Alterations in skin barrier permeability aggravated by the local production of irritating oleic acid by *Malassezia* lipases are considered responsible for the development of this condition.[16]

Atopic dermatitis

There is increasing evidence in favor of the participation of *Malassezia* yeasts in atopic dermatitis (AD), especially in disease forms with mainly head and neck distribution, the skin area primary colonized by this yeast. AD can be differentiated into "intrinsic" and "extrinsic" forms and current concepts accept that the former can evolve into the latter one.[17] *Malassezia* yeasts seem to participate in both forms of this disease through the development of specific antibodies.

Malassezia folliculitis

Malassezia folliculitis is an acne-like eruption characteristically located on the "sebaceous" areas of the trunk (shoulders, back, chest). It is triggered by occlusion or immunosuppresion[18,19] and usually is accompanied by intense pruritus. Histologic sections demonstrate copious numbers of yeasts within the destroyed pilosebaceous units.

Fig. 2 Seborrheic dermatitis on the face of a 25-year-old woman. The lesions have been recurring over the past 8 years.

Individuals susceptible to the development of PV and SD are predisposed to *Malassezia* folliculitis[20] and the resident *Malassezia* skin flora is implicated in this condition.[21] It also has been reported in epidemic forms in the intensive care setting[22] and in heart transplant recipients.[23] The incidence of *Malassezia* folliculitis is expected to increase with the advent of the new biologic therapies as it has been observed in patients receiving anti-tumor necrosis factor (TNF)-α medication (infliximab) for inflammatory bowel disease,[24] erlotinib, for renal carcinoma,[25] and cetuximab for parotid gland adenocarcinoma.[26] Due to the many similarities with other forms of folliculitis and the fact that *Malassezia* yeasts are not routinely cultured, this condition might be underdiagnosed in the daily practice.

Psoriasis

The historical associations of *Malassezia* yeasts with psoriasis were presented in the introduction of this contribution. Currently, and as the psoriasis pathogenesis is dissected, only a secondary role, at most of an exacerbating factor, can be supported for *Malassezia* yeasts. The initial encouraging results in the treatment of scalp psoriasis with antifungal drugs[27,28] have not been established in subsequent studies.

In order to understand how *Malassezia* yeasts are implicated in diseases with diverse clinical presentations, an insight into relevant aspects of the pathobiology of this yeast in healthy and diseased skin follows. Current controversies that exist in the form of unanswered or emerging questions follow:

- Geographical variations in the isolation of *Malassezia* species
- Existence of pathogenic species or strains within species
- Healthy versus diseased skin isolates
- Effect of environmental factors on *Malassezia*-associated diseases

Pathobiology of *Malassezia*-associated diseases

Taxonomy and epidemiology

The advent of molecular techniques has resulted in the ongoing revision of the genus *Malassezia* with the identification of seven new species within the last decade (*M dermatis, M japonica, M nana, M yamatoensis, M equina, M caprae, M cuniculi*)[8,29-33] in addition to the seven described in 1996 (*M globosa, M restricta, M furfur, M sympodialis, M slooffiae, M obtusa, M pachydermatis*).[8] Species differentiation is performed employing catalase (ie, hydrolysis of H_2O_2) and β-glucosidase (splitting of esculin) production along with lipid (Tweens, Cremophor El) assimilation profile[14]; however, this has to be complemented by molecular analysis of genes encoding subunits of the

ribosomal RNA (rRNA)[14,34] as the metabolic traits that conventional identification methods employ do not have enough variables to differentiate this number of species. The recognition of these species has instigated the implementation of a significant number of epidemiologic studies throughout the globe in the effort to identify "pathogenic" *Malassezia* species (ie, species that cause disease).

Despite the initial evidence that supported the role of *M globosa* (the former *P orbiculare*) as the causative agent of PV,[35] subsequent studies showed that the distribution of *Malassezia* species from healthy and diseased skin was equivalent, thus failing to substantiate the existence of a pathogenic species not only in PV but also for the other *Malassezia*-associated diseases; however, intriguing observations surface when we compare epidemiologic data on *Malassezia* species isolation rates from different geographic locations, healthy or diseased skin. Definitely, *M globosa* and *M restricta* are the most commonly found species on healthy and diseased human skin.[14] Certain species, however, such as *M dermatis*, have been mainly isolated in the East, initially from AD skin in Japan[29] and subsequently from healthy and AD skin in Korea.[36,37] It also has been reported to be isolated from just 1 of 218 PV patients in Argentina.[38] More than 20 epidemiologic studies from the rest of the globe have failed to isolate this species,[14] demonstrating the existence of geographical variations in the distribution of *Malassezia* species. This finding, which also has been depicted in molecular comparisons of *M furfur* isolates,[39] needs to be confirmed in additional studies. The burden of *Malassezia* yeasts as found by their isolation rate in culture is higher in PV (1,352 positive cultures per 1,714 patients; 78.8%), followed by SD (218 positive cultures per 289 patients; 75.4%), psoriasis (88 positive cultures per 138 patients; 63.7%), and AD (122 positive cultures per 215 patients; 56.7%). The data were collectively analyzed[14] and they only can be considered indicative, as sampling, isolation, and culture conditions were not uniform. This is evident in the reported results for PV, which if properly sampled and cultured, has a *Malassezia* recovery rate well over 90%,[35,40] which is not the case in many of the studies previously recorded[14]; however, and keeping in mind that culture-based techniques detect live yeast cells, there is an impressive decline in *Malassezia* isolation rates in lesional skin of AD, despite the existence of a distinct subgroup of AD patients sensitized to this yeast.[41] This contradicts the results of studies that employ molecular techniques to identify and measure the quantity of *Malassezia* DNA on the skin, which demonstrate that *M globosa* and *M restricta* are detected in higher quantities in AD skin compared with SD and healthy skin.[42-44] This controversy can be explained by the fact that culture-based techniques isolate live cells, whereas molecular techniques measure DNA that could originate from dead or at least metabolically inert cells. Nevertheless, epidemiologic studies do point toward the existence of pathogenic subtypes within *Malassezia* species (ie, strains within species that are preferentially isolated from diseased compared with healthy skin).[34] Different strains of *M globosa* are isolated from extensive PV lesions compared with more confined disease.[40] Furthermore SD and AD skin lesions harbor different strains compared with healthy skin.[39,43,45] When trying to understand the pathogenic potential of *Malassezia* yeasts, we have to move away from the established concept of the Koch postulates, as we are all "carriers" of this fungus. In PV, there is a genetic background that favors the appearance of disease within blood relatives but not within married couples.[46] This would mean that either the postulated pathogenic *Malassezia* species or strains cannot be carried over, or if this happens, they do not express the relevant disease-associated traits in the new skin environment; however, with the exception of *Malassezia* folliculitis, in all skin diseases associated with this yeast, there is a dysfunction in the epidermal barrier function[17,47,48] and it is rational to assume that *Malassezia* subtypes on this skin would have to express additional physiologic and biochemical characteristics in order to adapt to the altered environment. Whether this, as in many skin diseases, initiates a vicious disease-exacerbating cycle is a matter open to research.

Physiology and biochemistry

Malassezia yeasts are a unique member of the human cutaneous flora, as they are the prevalent eukaryote of human skin (Figure 3). *Malassezia* yeasts are primarily found in the infundibulum of the sebaceous gland, where lipids, the main source of energy for *Malassezia*, are freely available. In humans, mostly lipid-dependent *Malassezia* species are found, probably after having adapted their particular nutrition needs to human sebum. *Malassezia* yeasts demonstrate a complex structure (Figure 3) and under steady-state conditions, manage to evade local immune responses and remain in equilibrium with human skin (commensal/symbiotic status). What disturbs this equilibrium and turns *Malassezia* yeasts to pathogens (PV, dandruff, SD, *Malassezia* folliculitis) or disease aggravators (AD, psoriasis) remains to be elucidated.

Currently, we can schematically discriminate the following states of *Malassezia* coexistence with the skin. One is the obvious symbiotic/commensal state, in which the yeast and the underlying skin are in equilibrium. The second is the pathogenic state, in which either the yeast amply proliferates without inflicting inflammation (PV) or is implicated in diseases with noticeable inflammation (SD, AD, and psoriasis). In the remaining of this contribution we synthesize available data that underlie this evident controversy.

Despite the absence of inflammation in PV, there is a distinct effect on the melanization process[49] and as recently shown, the integrity of the stratum corneum[47] as well as hair quantity[50] can be compromised. Initial research has shown that *Malassezia* metabolic byproducts such as azelaic acid could

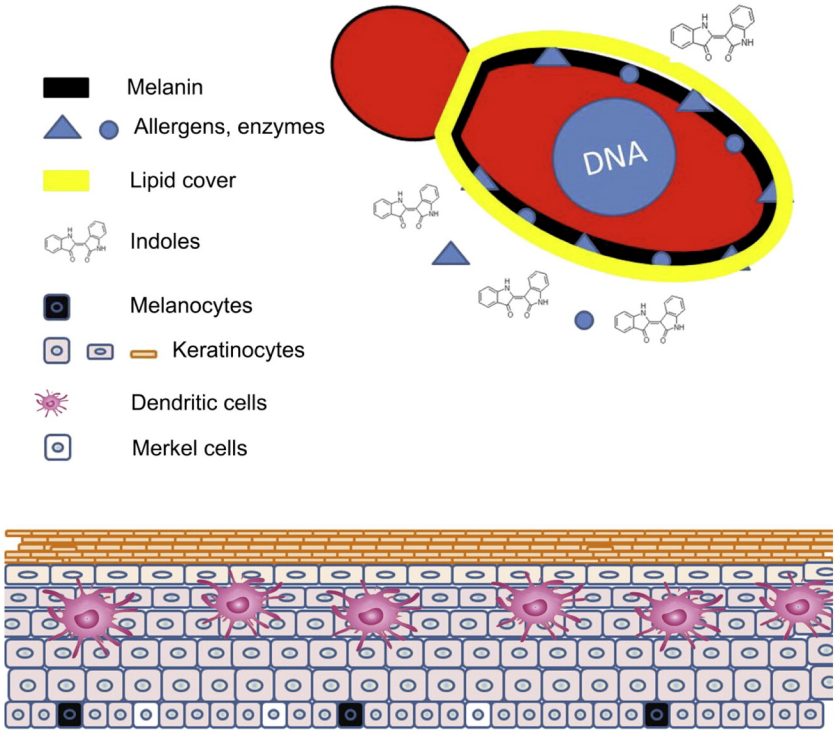

Fig. 3 Aspects of the interactions of *Malassezia* yeasts with the epidermis. Secreted enzymes and allergens can hurt the skin barrier function and sensitize susceptible individuals while metabolic products like indoles modify the function of melanocytes and dendritic cells.

inhibit tyrosinase activity in melanocytes, which might result in the depigmented lesions of PV; however, in subsequent studies it was shown that this metabolite could not be produced *in vivo* in quantities with clinical significance.[51]

Malassezia yeasts also produce an array of indoles from tryptophan that could be implicated in melanogenesis.[52] These are synthesized *in vitro* by many of the currently accepted *Malassezia* species, with the primary source being *M furfur*.[12,53,54] Among these compounds (Table 1), potent ligands of the aryl hydrocarbon receptor (AhR) are included (malassezin, indirubin, indolo[3,2-b]carbazole [ICZ], formylindolo[3,2-b]carbazole). This receptor recently has been implicated in the mediation of ultraviolet radiation (UVR) damage and melanogenesis.[55-57] Additionally, the clinically observed resistance of the depigmented PV lesions to UVR has been attributed to these substances[58]; furthermore, the absence of inflammation in the lesions of PV despite the heavy *Malassezia* load[59] has been attributed to the down-grading effect of the fungus on multiple aspects of the immune response, as is the down-regulation of the respiratory burst of human neutrophils by pityriarubins[60] and the down-regulation of the ability of dendritic cells to mature and present antigens in response to toll-like receptor (TLR) stimulation.[61] The latter effect was mediated through activation of AhR as it was inhibited by AhR antagonists.

In the "inflammatory" dermatoses (ie, SD, AD, and psoriasis) there are three main mechanisms through which *Malassezia* yeasts could increase the inflammatory response: (1) damage of the epidermal barrier function through the production of lipases and phospholipases; (2) increase in the local immune response through local production of an array of interleukins (ILs); and (3) sensitization to cross-reactive allergens produced by *Malassezia* yeasts.

As already mentioned, the damage to the epidermal barrier function in dandruff and AD underlies the initial pathophysiologic steps.[15,17] Increased secretion of lipases and phospholipases has been shown *in vivo* for patients with SD,[13] whereas *in vitro* phosholipase production increases after β-endorphin stimulation in *Malassezia* strains isolated from SD lesional skin.[62] Keratinocytes can produce pro-inflammatory (IL-1α, IL-6, IL-8, IL-12, TNF-α) and anti-inflammatory (IL-4, IL-10) cytokines after stimulation with *Malassezia* cells, which is species-specific[14]; however, the local production of metabolites by *Malassezia* yeasts also could modify the immune response, as has been shown for the effect of pityriarubins, indirubin, and ICZ.[60,61] Interestingly, flares of SD coincide with age and seasonal variations in sebum production pointing toward alterations in the *Malassezia* microenvironment that could result in the development of skin disease in predisposed individuals. Thus, up to this point the inflammatory trigger in the epidermis seems to be dependent on the exact mixture of *Malassezia* species on the skin, which can up- or down-regulate the immune response. With our current analytical methods we cannot assess the mixture in each individual as, for example, the production of the "anti-inflammatory" indirubin can be 10^3-fold more by *M furfur* strains compared with *M*

Table 1 Bioactive indole derivatives synthesized by *M furfur* when grown on agar containing L-tryptophan as the single nitrogen source

Pityriacitrin $C_{20}H_{13}N_3O$ MW311.34		**Malassezin** $C_{18}H_{14}N_2O$ MW274.32	
Pityrialactone $C_{20}H_{12}N_2O_3$ MW328.32		***Malassezia* Indole A** $C_{21}H_{17}N_3O_3$ MW358.38	
Pityriaanhydride		**Keto-Malassezin**	
Pityriarubin A $C_{32}H_{22}N_4O_4$ MW526.55		**Malasseziacitrin**	
Pityriarubin B $C_{32}H_{20}N_4O_4$ MW524.53		**Indolo[3,2-b]carbazole** MW282.296	
Pityriarubin $CC_{32}H_{19}N_3O_5$ MW525.51		**Indirubin** $C_{16}H_{10}N_2O_2$ MW262.263	
O52			
***Malassezia*-carbazole A-D**	**18**, R = H **19**, R = CHO	**20**	**21**, R = CO_2H

globosa (P. Magiatis, personal communication). Thus, the net indirubin production of 1 *M furfur* cell could equal that of 10^3 *M globosa* cells, suggesting that our macro-epidemiologic observations might be relatively irrelevant to the *Malassezia*-skin micro-environment; however, this is an area of future fascinating research.

The subsequent steps that might be followed until the development of clinically evident disease could well depend on individual susceptibility. In patients with SD, this might result in a nonspecific inflammatory response. One of the few studies performed on the inflammatory infiltrate in SD skin and adjacent skin showed the absence of a specific immune response in biopsies of SD skin compared with controls[63]; however, this also was evident in adjacent, clinically healthy skin of patients, pointing toward the existence of nonclinically evident inflammation. It is really puzzling the association of indole-producing strains of *M furfur* with SD.[12] The AhR activity of *Malassezia* indoles results in down-regulation of the inflammatory response,[61] the opposite of what we normally observe in SD lesions. Maybe the survival of indole-producing *M furfur* strains might not be the cause but actually the result of the local inflammation as strains that have the ability to down-regulate the inflammatory response in their microenvironment might have an advantage.

AD pathogenesis is underlined by a defective skin barrier[64] and aberrant skin immune response.[65] Thus, *Malassezia* yeasts could actively participate in the deregulation of the skin homeostatic mechanisms and trigger or sustain AD exacerbations. *M pachydermatis* proteinase and phospholipase production has been shown for the mainly animal isolate *M pachydermatis*.[66] and has been correlated with AD severity in dogs.[67] Phospholipase production as a response to β-endorphin stimulation, possibly through the expression of β-opioid receptors, also has been shown for *M pachydermatis*[68] and as already mentioned, has been confirmed in human lipophilic isolates.[62] Penetration of whole and fragmented *Malassezia* cells through the damaged epidermal barrier could activate the innate and sensitize adaptive immunity in these patients.[65] When healthy-looking atopic skin was patch-tested with *M sympodialis* extract, it demonstrated increased expression of inflammation and immune function–associated genes and down-regulation of genes associated with skin lipid production, a similar gene expression profile to diseased skin.[69] Also, the sensitization of atopic patients to *Malassezia* yeasts is specific for those with skin manifestations and is not present in atopic patients with mostly respiratory symptoms like rhinoconjuctivitis and/or asthma, or patients with other hypersensitivity skin syndromes as is urticaria.[70] The extent of this sensitization varies according to the recombinant allergen used for testing and is higher for antigens that could present higher degrees of cross-reactivity with human proteins. Furthermore, skin and peripheral blood lymphocyte stimulated by the *M sympodialis* allergen Mala s 13 (thioredoxin) can cross-react with human recombinant thioredoxin toward a T helper (Th)1, Th2, and Th17 inflammatory phenotype and express skin homing markers.[71]

The psoriasis pathogenesis model proposes the release of self-DNA by stressed keratinocytes and the formation of complexes with the cathelicidin LL-37, with subsequent stimulation of plasmacytoid dendritic cells to secrete interferon-α, initiating and sustaining psoriasis lesions.[48] *Malassezia* yeasts could invade epidermal cells[72] and stress predisposed keratinocytes to the increased production of cathelicidin LL-37.[73] *Malassezia* yeasts have been shown to induce the TLR-2 pathway,[74] which participates in the pathogenesis of psoriasis most probably through the cathelicidin pathway; however, only to demonstrate the controversial issues on the participation of *Malassezia* yeasts in psoriasis pathogenesis, the *Malassezia* produced indole indirubin, has been successfully employed in the treatment of this disease.[75]

Conclusions

The described controversies demonstrate the multifaceted interactions of *Malassezia* yeasts with the skin. The diversity of the clinical presentations of *Malassezia*-associated diseases does not allow the formation of solid pathogenetic pathways yet this can also be the soil of future, fascinating research that would highlight the role of this yeast on skin physiology.

Acknowledgment

Supported in part by the University of Ioannina, Special Research Committee Account No 22195.

References

1. Eichstedt E. Pilzbildung in der Pityriasis Versicolor. Froriep Neue Notiz Natur Heilk 1846;39:270.
2. Rivolta S. In: Speirani G, editor. Parasiti vegetali. Torino, Italy; 1873.
3. Hay R, Midgley G. Introduction: *Malassezia* yeasts from a historical perspective. In: Boekhout T, Guého E, Mayser P, Velegraki A, editors. *Malassezia* and the skin science and clinical practice. Berlin: Springer; 2010. p. 1-16.
4. Gordon MA. Lipophilic yeastlike organisms associated with tinea versicolor. J Invest Dermatol 1951;17:267-72.
5. Guého E, Boekhout T, Ashbee HR, Guillot J, Van Belkum A, Faergemann J. The role of *Malassezia* species in the ecology of human skin and as pathogens. Med Mycol 1998;36(Suppl 1):220-9.
6. Slooff W. Genus 6 *Pityrosporum* Sabouraud. In: Lodder J, editor. The yeasts, a taxonomic study. 2 ed. Amsterdam, The Netherlands: North-Holland; 1970. p. 1167-86.
7. Guillot J, Guého E. The diversity of *Malassezia* yeasts confirmed by rRNA sequence and nuclear DNA comparisons. Antonie Van Leeuwenhoek 1995;67:297-314.
8. Guého E, Midgley G, Guillot J. The genus *Malassezia* with description of four new species. Antonie Van Leeuwenhoek 1996;69:337-55.
9. Maeda M, Makimura KC, Yamaguchi H. Pityriasis versicolor rubra. Eur J Dermatol 2002;12:160-4.
10. Crowson AN, Magro CM. Atrophying tinea versicolor: a clinical and histological study of 12 patients. Int J Dermatol 2003;42:928-32.
11. Shuster S. The aetiology of dandruff and the mode of action of therapeutic agents. Br J Dermatol 1984;111:235-42.

12. Gaitanis G, Magiatis P, Stathopoulou K, et al. AhR ligands, malassezin, and indolo[3,2-b]carbazole are selectively produced by *Malassezia furfur* strains isolated from seborrheic dermatitis. J Invest Dermatol 2008;128:1620-5.
13. Patino-Uzcategui A, Amado Y, Cepero de Garcia M, et al. Virulence gene expression in *Malassezia* spp from individuals with seborrheic dermatitis. J Invest Dermatol 2011;131:2134-6.
14. Gaitanis G, Magiatis P, Hantschke M, Bassukas ID, Velegraki A. The *Malassezia* genus in skin and systemic diseases. Clin Microbiol Rev 2012;25:106-41.
15. Turner GA, Hoptroff M, Harding CR. Stratum corneum dysfunction in dandruff. Int J Cosmet Sci 2012;34:298-306.
16. DeAngelis YM, Gemmer CM, Kaczvinsky JR, Kenneally DC, Schwartz JR, Dawson Jr TL. Three etiologic facets of dandruff and seborrheic dermatitis: *Malassezia* fungi, sebaceous lipids, and individual sensitivity. J Investig Dermatol Symp Proc 2005;10:295-7.
17. Bieber T. Atopic dermatitis. N Engl J Med 2008;358:1483-94.
18. Back O, Faergemann J, Hornqvist R. *Pityrosporum* folliculitis: a common disease of the young and middle-aged. J Am Acad Dermatol 1985;12:56-61.
19. Morrison VA, Weisdorf DJ. The spectrum of *Malassezia* infections in the bone marrow transplant population. Bone Marrow Transplant 2000;26:645-8.
20. Faergemann J, Johansson S, Back O, Scheynius A. An immunologic and cultural study of *Pityrosporum* folliculitis. J Am Acad Dermatol 1986;14:429-33.
21. Akaza N, Akamatsu H, Sasaki Y, et al. *Malassezia* folliculitis is caused by cutaneous resident *Malassezia* species. Med Mycol 2009; 47:618-24.
22. Archer-Dubon C, Icaza-Chivez ME, Orozco-Topete R, Reyes E, Baez-Martinez R. Ponce de Leon S. An epidemic outbreak of *Malassezia* folliculitis in three adult patients in an intensive care unit: a previously unrecognized nosocomial infection. Int J Dermatol 1999;38:453-6.
23. Rhie S, Turcios R, Buckley H, Suh B. Clinical features and treatment of *Malassezia* folliculitis with fluconazole in orthotopic heart transplant recipients. J Heart Lung Transplant 2000;19:215-9.
24. Nasir A, El Bahesh E, Whitten C, Lawson A, Udall Jr JN. Pityrosporum folliculitis in a Crohn's disease patient receiving infliximab. Inflamm Bowel Dis 2010;16:7-8.
25. Cuetara MS, Aguilar A, Martin L, Aspiroz C, del Palacio A. Erlotinib associated with rosacea-like folliculitis and *Malassezia sympodialis*. Br J Dermatol 2006;155:477-9.
26. Cholongitas E, Pipili C, Ioannidou D. *Malassezia* folliculitis presented as acneiform eruption after cetuximab administration. J Drugs Dermatol 2009;8:274-5.
27. Farr PM, Krause LB, Marks JM, Shuster S. Response of scalp psoriasis to oral ketoconazole. Lancet 1985;2:921-2.
28. Rosenberg EW, Belew PW. Improvement of psoriasis of the scalp with ketoconazole. Arch Dermatol 1982;118:370-1.
29. Sugita T, Takashima M, Shinoda T, et al. New yeast species, *Malassezia dermatis*, isolated from patients with atopic dermatitis. J Clin Microbiol 2002;40:1363-7.
30. Sugita T, Takashima M, Kodama M, Tsuboi R, Nishikawa A. Description of a new yeast species, *Malassezia japonica*, and its detection in patients with atopic dermatitis and healthy subjects. J Clin Microbiol 2003;41:4695-9.
31. Cabanes FJ, Vega S, Castella G. *Malassezia cuniculi* sp. nov., a novel yeast species isolated from rabbit skin. Med Mycol 2011;49:40-8.
32. Hirai A, Kano R, Makimura K, et al. *Malassezia nana* sp. nov., a novel lipid-dependent yeast species isolated from animals. Int J Syst Evol Microbiol 2004;54:623-7.
33. Sugita T, Tajima M, Takashima M, et al. A new yeast, *Malassezia yamatoensis*, isolated from a patient with seborrheic dermatitis, and its distribution in patients and healthy subjects. Microbiol Immunol 2004;48:579-83.
34. Gaitanis G, Bassukas ID, Velegraki A. The range of molecular methods for typing *Malassezia*. Curr Opin Infect Dis 2009;22:119-25.
35. Crespo Erchiga V, Ojeda Martos A, Vera Casano A, Crespo Erchiga A, Sanchez Fajardo F. *Malassezia globosa* as the causative agent of pityriasis versicolor. Br J Dermatol 2000;143:799-803.
36. Jang SJ, Lim SH, Ko JH, et al. The Investigation on the Distribution of *Malassezia* Yeasts on the Normal Korean Skin by 26S rDNA PCR-RFLP. Ann Dermatol 2009;21:18-26.
37. Oh BH, Song YC, Lee YW, Choe YB, Ahn KJ. Comparison of nested PCR and RFLP for identification and classification of *Malassezia* yeasts from healthy human skin. Ann Dermatol 2009;21:352-7.
38. Giusiano G, Sosa Mde L, Rojas F, Vanacore ST, Mangiaterra M. Prevalence of *Malassezia* species in pityriasis versicolor lesions in northeast Argentina. Rev Iberoam Micol 2010;27:71-4.
39. Gaitanis G, Velegraki A, Alexopoulos EC, et al. *Malassezia furfur* fingerprints as possible markers for human phylogeography. ISME J 2009;3:498-502.
40. Gaitanis G, Velegraki A, Alexopoulos EC, Chasapi V, Tsigonia A, Katsambas A. Distribution of *Malassezia* species in pityriasis versicolor and seborrhoeic dermatitis in Greece. Typing of the major pityriasis versicolor isolate *M. globosa*. Br J Dermatol 2006;154: 854-9.
41. Kim TY, Jang IG, Park YM, Kim HO, Kim CW. Head and neck dermatitis: the role of *Malassezia furfur*, topical steroid use and environmental factors in its causation. Clin Exp Dermatol 1999;24: 226-31.
42. Sugita T, Suto H, Unno T, et al. Molecular analysis of *Malassezia* microflora on the skin of atopic dermatitis patients and healthy subjects. J Clin Microbiol 2001;39:3486-90.
43. Tajima M, Sugita T, Nishikawa A, Tsuboi R. Molecular analysis of *Malassezia* microflora in seborrheic dermatitis patients: comparison with other diseases and healthy subjects. J Invest Dermatol 2008;128: 345-51.
44. Sugita T, Tajima M, Tsubuku H, Tsuboi R, Nishikawa A. Quantitative analysis of cutaneous *Malassezia* in atopic dermatitis patients using real-time PCR. Microbiol Immunol 2006;50:549-52.
45. Sugita T, Kodama M, Saito M, et al. Sequence diversity of the intergenic spacer region of the rRNA gene of *Malassezia globosa* colonizing the skin of patients with atopic dermatitis and healthy individuals. J Clin Microbiol 2003;41:3022-7.
46. He SM, Du WD, Yang S, et al. The genetic epidemiology of tinea versicolor in China. Mycoses 2008;51:55-62.
47. Lee WJ, Kim JY, Song CH, et al. Disruption of barrier function in dermatophytosis and pityriasis versicolor. J Dermatol 2011;38: 1049-53.
48. Nestle FO, Di Meglio P, Qin JZ, Nickoloff BJ. Skin immune sentinels in health and disease. Nat Rev Immunol 2009;9:679-91.
49. Nazzaro-Porro M, Passi S. Identification of tyrosinase inhibitors in cultures of *Pityrosporum*. J Invest Dermatol 1978;71:205-8.
50. Mostafa WZ, Assaf MI, Ameen IA, El Safoury OS, Al Sulh SA. Hair loss in pityriasis versicolor lesions: a descriptive clinicopathological study. J Am Acad Dermatol. Epub 2012 May 8.
51. Leeming JP, Holland KT, Bojar RA. The *in vitro* antimicrobial effect of azelaic acid. Br J Dermatol 1986;115:551-6.
52. Kramer HJ, Podobinska M, Bartsch A, et al. Malassezin, a novel agonist of the aryl hydrocarbon receptor from the yeast *Malassezia furfur*, induces apoptosis in primary human melanocytes. Chembiochem 2005;6:860-5.
53. Magiatis P, Gaitanis G, Mexia N, et al. Chemistry and biology of *Malassezia* metabolites related to skin diseases. Planta Med 2010;76: 1293.
54. Mexia N, Magiatis P, Gaitanis G, Velegraki A, Skaltsounis AL. Synthesis, detection and quantification of the highly active AhR ligands tryptanthrin, indirubin and indolo[3,2-b]carbazol in *Malassezia* yeasts. Planta Med 2011;77:1237.
55. Fritsche E, Schafer C, Calles C, et al. Lightening up the UV response by identification of the arylhydrocarbon receptor as a cytoplasmatic target for ultraviolet B radiation. Proc Natl Acad Sci U S A 2007;104: 8851-6.

56. Jux B, Kadow S, Luecke S, Rannug A, Krutmann J, Esser C. The aryl hydrocarbon receptor mediates UVB radiation-induced skin tanning. J Invest Dermatol 2011;131:203-10.
57. Luecke S, Backlund M, Jux B, Esser C, Krutmann J, Rannug A. The aryl hydrocarbon receptor (AHR), a novel regulator of human melanogenesis. Pigment Cell Melanoma Res 2010;23:828-33.
58. Larangeira de Almeida Jr H, Mayser P. Absence of sunburn in lesions of pityriasis versicolor alba. Mycoses 2006;49:516.
59. Wroblewski N, Bar S, Mayser P. Missing granulocytic infiltrate in pityriasis versicolor—indication of specific anti-inflammatory activity of the pathogen? Mycoses 2005;48(Suppl 1):66-71.
60. Kramer HJ, Kessler D, Hipler UC, et al. Pityriarubins, novel highly selective inhibitors of respiratory burst from cultures of the yeast *Malassezia furfur*: comparison with the bisindolylmaleimide arcyriarubin A. Chembiochem 2005;6:2290-7.
61. Vlachos C, Schulte BM, Magiatis P, Adema GJ, Gaitanis G. *Malassezia*-derived indoles activate the aryl hydrocarbon receptor and inhibit Toll-like receptor-induced maturation in monocyte-derived dendritic cells. Br J Dermatol 2012;167:496-505.
62. Vlachos C, Gaitanis G, Alexopoulos EC, Papadopoulou Ch, Bassukas ID. Phospholipase activity after β-endorphin exposure discriminates *Malassezia* strains isolated from healthy and seborrheic dermatitis skin. J Eur Acad Dermatol Venereol. Epub 2012 Jul 4.
63. Faergemann J, Bergbrant IM, Dohse M, Scott A, Westgate G. Seborrhoeic dermatitis and *Pityrosporum* (*Malassezia*) folliculitis: characterization of inflammatory cells and mediators in the skin by immunohistochemistry. Br J Dermatol 2001;144:549-56.
64. Cork MJ, Danby SG, Vasilopoulos Y, et al. Epidermal barrier dysfunction in atopic dermatitis. J Invest Dermatol 2009;129:1892-908.
65. De Benedetto A, Agnihothri R, McGirt LY, Bankova LG, Beck LA. Atopic dermatitis: a disease caused by innate immune defects? J Invest Dermatol 2009;129:14-30.
66. Coutinho SD, Paula CR. Proteinase, phospholipase, hyaluronidase and chondroitin-sulphatase production by *Malassezia pachydermatis*. Med Mycol 2000;38:73-6.
67. Machado ML, Cafarchia C, Otranto D, et al. Genetic variability and phospholipase production of *Malassezia pachydermatis* isolated from dogs with diverse grades of skin lesions. Med Mycol 2010;48:889-92.
68. Cafarchia C, Dell'Aquila ME, Traversa D, et al. Expression of the micro-opioid receptor on Malassezia pachydermatis and its effect in modulating phospholipase production. Med Mycol 2010;48:73-8.
69. Saaf AM, Tengvall-Linder M, Chang HY, et al. Global expression profiling in atopic eczema reveals reciprocal expression of inflammatory and lipid genes. PLoS One 2008;3:e4017.
70. Casagrande BF, Fluckiger S, Linder MT, et al. Sensitization to the yeast *Malassezia sympodialis* is specific for extrinsic and intrinsic atopic eczema. J Invest Dermatol 2006;126:2414-21.
71. Balaji H, Heratizadeh A, Wichmann K, et al. *Malassezia sympodialis* thioredoxin-specific T cells are highly cross-reactive to human thioredoxin in atopic dermatitis. J Allergy Clin Immunol 2011;128:92-4.
72. Baroni A, Perfetto B, Paoletti I, et al. *Malassezia furfur* invasiveness in a keratinocyte cell line (HaCat): effects on cytoskeleton and on adhesion molecule and cytokine expression. Arch Dermatol Res 2001;293:414-9.
73. Agerberth B, Buentke E, Bergman P, et al. *Malassezia sympodialis* differently affects the expression of LL-37 in dendritic cells from atopic eczema patients and healthy individuals. Allergy 2006;61:422-30.
74. Baroni A, Orlando M, Donnarumma G, et al. Toll-like receptor 2 (TLR2) mediates intracellular signalling in human keratinocytes in response to *Malassezia furfur*. Arch Dermatol Res 2006;297:280-8.
75. Lin YK, Chang CJ, Chang YC, Wong WR, Chang SC, Pang JH. Clinical assessment of patients with recalcitrant psoriasis in a randomized, observer-blind, vehicle-controlled trial using indigo naturalis. Arch Dermatol 2008;144:1457-64.