[Downloaded free from http://www.ijccm.org on Tuesday, September 06, 2016, IP: 160.80.2.38]

Case Report

Tombs of *Aspergillus*: A missed cause of recurrent respiratory infections in allergic bronchopulmonary aspergillosis

Onkar Kumar Jha, Arjun Khanna[1], Charul Dabral, Deepak Talwar

Abstract

Broncholithiasis is an often overlooked condition and has been associated with symptoms such as cough, hemoptysis, and recurrent respiratory infections. The most common mechanism of a broncholith formation is the enlargement and subsequent erosion of a lymph node into an adjacent airway. Here, we describe this entity in a patient with advanced allergic bronchopulmonary aspergillosis, with chronic hypercapnic respiratory failure, and with frequent infective exacerbations. These frequent exacerbations were initially attributed to the poor lung function of the patient and the inability to cough out the secretions. The diagnosis of broncholithiasis was eventually established on bronchoscopy, when the patient was intubated and mechanically ventilated. In this patient, the mixed broncholiths were not associated with mediastinal lymphadenopathy and with biopsy showing *Aspergillus* with no lymph node tissue indicating its bronchial origin. A high index of suspicion should be kept in patients with recurrent infective exacerbations of pulmonary diseases, especially when computed tomography images show calcifications in the vicinity of airways even in the absence of lymphadenopathy, as most of these can be treated with routine bronchoscopic interventions.

Keywords: Allergic bronchopulmonary aspergillosis, broncholithiasis, broncholiths

Access this article online

Website: www.ijccm.org

DOI: 10.4103/0972-5229.186228

Quick Response Code:

Introduction

Broncholithiasis refers to the presence of calcified or ossified material within the lumen of the bronchus.[1] The most common mechanism of the formation of a broncholith is by erosion and extrusion of an adjacent, calcified lymph node into the bronchial lumen, usually secondary to the long-standing foci of necrotizing granulomatous lymphadenitis. Rarely, aspiration of bones and other foreign bodies or an eroded and extruded bronchial cartilage may give rise to these broncholiths. *In situ* formation of broncholith in bronchi and bronchial wall has not reported. Apart from this, cough and hemoptysis, which are the two most well-known symptoms of broncholiths and recurrent secondary infections owing to the pooling of secretions distally, have also been described.[2] The presence of broncholiths in patients with allergic bronchopulmonary aspergillosis (ABPA) has rarely been described in literature.[3] Here, we present a patient with advanced ABPA, who had frequent infective exacerbations secondary to multiple broncholiths, which had been missed earlier being considered as pulmonary calcifications secondary to previous infections being neither in the vicinity of airways or associated with lymphadenopathy. Retrospectively, after reviewing bronchoscopy findings, reconstruction of the computed

From:
Department of Metro Center for Respiratory Diseases, [1]Metro Center for Respiratory Diseases, Metro Multispeciality Hospital, Noida, Uttar Pradesh, India

Correspondence:
Dr. Arjun Khanna, Metro Center for Respiratory Diseases, Metro Multispeciality Hospital, Noida, Uttar Pradesh, India.
E-mail: doc.khanna@gmail.com

This is an open access article distributed under the terms of the Creative Commons Attribution-NonCommercial-ShareAlike 3.0 License, which allows others to remix, tweak, and build upon the work non-commercially, as long as the author is credited and the new creations are licensed under the identical terms.

For reprints contact: reprints@medknow.com

How to cite this article: Jha OK, Khanna A, Dabral C, Talwar D. Tombs of *Aspergillus*: A missed cause of recurrent respiratory infections in allergic bronchopulmonary aspergillosis. Indian J Crit Care Med 2016;20:421-4.

[Downloaded free from http://www.ijccm.org on Tuesday, September 06, 2016, IP: 160.80.2.38]

tomography (CT) scan images revealed multiple broncholiths in the airways.

Case Report

A 52-year-old male, reformed smoker, a known case of ABPA with chronic hypercapnic respiratory failure presented to our center with worsening dyspnea and high-grade fever with chills for the past 2 days. On reviewing his records, the patient had poorly controlled bronchial asthma for the past many years with highly elevated total IgE and specific IgE and IgG for *Aspergillus*. He had been on oral steroids for the past many years and had required treatment with multiple antibiotics and intravenous steroids almost on a monthly basis for the past 2 years on account of lower respiratory tract infections of the right middle and lower lobes. Multiple CT scans had been done over the past few years, which showed areas of bilateral bronchiectasis, with variable areas of consolidation and fibrosis [Figure 1]. The changes were mostly marked in the right middle and lower lobes. On examination, the patient had generalized wasting with marked respiratory distress and hypotension. In view of hypotension, respiratory distress, and acute respiratory acidosis (pH 7.23, $PaCO_2$ 98 mmHg, PO_2 52 mmHg, and HCO_3 42 mEq/L), the patient was endotracheally intubated and mechanically ventilated. Complete blood count revealed polymorphonuclear leukocytosis. Renal functions were deranged (serum creatinine, 2.1 mg/dL). Serum bilirubin was 1.8 mg/dL, with elevated AST (102 U/L) and ALT (154 U/L). Serum procalcitonin levels were elevated (5.2 ng/mL). Total serum IgE levels were 518 IU/ml. The patient was started on intravenous meropenem and colistin, based on the previous sputum culture and sensitivity reports (extended spectrum beta-lactamase-producing *Klebsiella* and *Pseudomonas* species had been identified in the sputum of the patient, on several prior occasions).

The patient showed signs of severe bronchospasm, which was not responsive to inhaled bronchodilators. Flexible bronchoscopy was carried out via the ET tube, which demonstrated viscid purulent secretions in the central airways. Multiple, hard, chalky white coral-like excrescences were noticed in the right main bronchus and in all distal airways on the right side [Figure 2]. These broncholiths were extremely hard and were embedded in the surrounding bronchial wall and could not be broken by the tip of the biopsy forceps. On attempted biopsy from the edge of one of these broncholiths, multiple bleeding points were appreciated. The broncholiths in the right intermediate bronchus were particularly large and were almost completely occluding the lumen of the airway. Thick purulent secretions were suctioned from the right-sided, distal bronchi. Extraction of the broncholith with biopsy of the surrounding bronchial mucosa was done from RIB. The histopathology of this broncholith and endobronchial mucosa revealed calcium deposition and *Aspergillus* colonies in submucosa, suggestive of invasive aspergillosis [Figure 3]. The patient was started on liposomal amphotericin B, in view of fungal invasion of the airway. The patient, however, developed worsening multiorgan failure and succumbed to his illness.

Discussion

ABPA is an pulmonary immune disorder caused by hypersensitivity to *Aspergillus fumigatus*, presenting with poorly controlled asthma, fleeting pulmonary infiltrates, and central bronchiectasis**.** The Rosenberg-Peterson criteria and the International Society for Human and

Figure 1: Computed tomography chest showing bilateral bronchiectasis with variable areas of consolidation and fibrosis

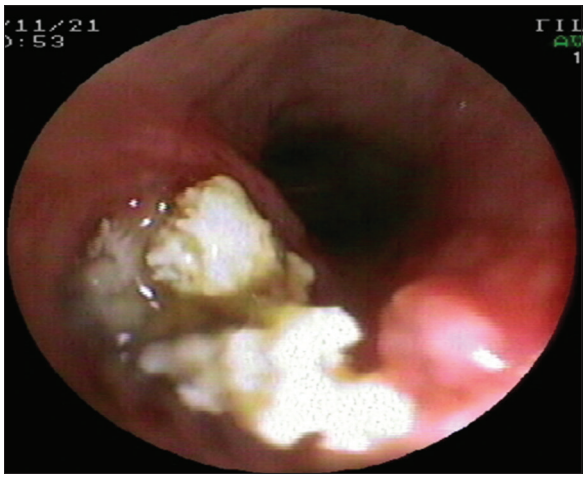

Figure 2: Chalky, white excrescences in the right main bronchus, suggestive of broncholiths

[Downloaded free from http://www.ijccm.org on Tuesday, September 06, 2016, IP: 160.80.2.38]

Animal Mycology criteria have been used to describe the disease.[4] As in our patient, invasive pulmonary aspergillosis has been reported to coexist in patients with ABPA. Nine cases of invasive aspergillosis have been reported in patients with ABPA.[5] A probable increase in serum steroid levels secondary to cytochrome enzyme inhibition consequent to itraconazole use has been postulated.

Broncholiths are formed in the airways secondary to a variety of chronic granulomatous infections such as tuberculosis, actinomycosis, histoplasmosis, and others.[6] The formation of these broncholiths as a consequence of chronic *Aspergillus* colonization of airways and ensuing chronic inflammation is a rare entity. Broncholiths may be missed out on routine chest CT scans, and may be picked up only after CT reconstruction[6] of airway images as was the case in our patient [Figures 4 and 5]. Patients with chronic respiratory diseases such as ABPA, especially with bronchiectasis, are prone to recurrent exacerbations, apart from the usual causes of exacerbations such as poorly controlled disease, ABPA exacerbations, or acute infective exacerbations on the underlying destructive parenchymal lung disease, and others. It may be prudent to search for unusual causes such as they may present as repeated infective exacerbations or worsening cough or as severe unresponsive airway obstruction. Our patient had multiple episodes of hospitalization and ER visits where he was treated with multiple courses of oral as well as injectable antibiotics and steroids. Most of these admissions were due to pneumonia on underlying bronchiectatic lungs, and hence, labeled as episodes of acute infective exacerbations or exacerbations of ABPA, despite IgE levels being in near normal range. An early diagnosis of broncholithiasis is imperative as it may cause massive hemoptysis. Bronchoscopic methods have been used in broncholith removal, even when these stones have an extraluminal penetrating component.[7] Results of fiberoptic extraction versus rigid bronchoscopic methods are identical in intraluminal broncholiths, but in penetrating mixed broncholiths, rigid bronchoscopy fares much better with success rates of 67% versus 30% with fiberoptic bronchoscopy. Large broncholiths with granulation tissue are preferably extracted under rigid bronchoscopy.[1,7] Surgical removal may be resorted to in patients presenting with massive hemoptysis and to deal with the complications of bronchoscopic removal, for example, rupture of the bronchial wall of the formation of airway fistulas. We could not extract all broncholiths in our patient, as he had a very poor general condition with septic shock and multiorgan dysfunction, though major airway-obstructing broncholiths were extracted without any complication. Retrospectively, we felt that timely diagnosis and treatment of these broncholiths in our patient may have led to a better outcome.

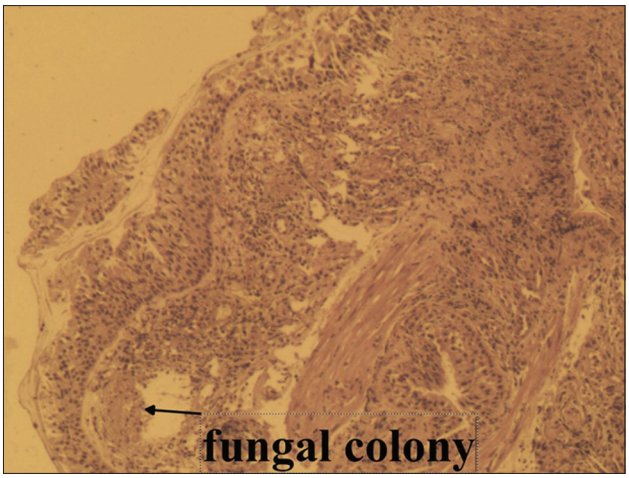

Figure 3: Calcium deposits and *Aspergillus* colonies in the bronchial submucosa, suggestive of invasive aspergillosis

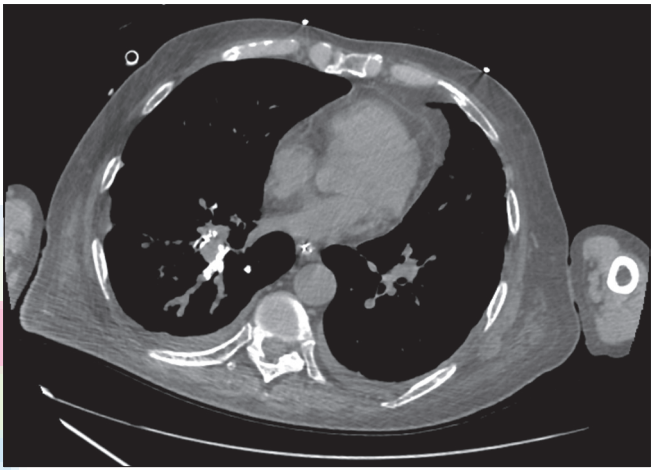

Figure 4: Computed tomography reconstruction showing the broncholiths

Figure 5: Computed tomography reconstruction images showing bilateral airways full of broncholiths

[Downloaded free from http://www.ijccm.org on Tuesday, September 06, 2016, IP: 160.80.2.38]

Financial support and sponsorship

Nil.

Conflicts of interest

There are no conflicts of interest.

References

1. De S, De S. Broncholithiasis. Lung India 2008;25:152-4.
2. Lim SY, Lee KJ, Jeon K, Koh WJ, Suh GY, Chung MP, *et al.* Classification of broncholiths and clinical outcomes. Respirology 2013;18:637-42.
3. Koh WJ, Han J, Kim TS, Lee KS, Jang HW, Kwon OJ. Allergic bronchopulmonary aspergillosis coupled with broncholithiasis in a non-asthmatic patient. J Korean Med Sci 2007;22:365-8.
4. Agarwal R, Chakrabarti A, Shah A, Gupta D, Meis JF, Guleria R, *et al.* Allergic bronchopulmonary aspergillosis: Review of literature and proposal of new diagnostic and classification criteria. Clin Exp Allergy 2013;43:850-73.
5. Maturu VN, Agarwal R. Acute invasive pulmonary aspergillosis complicating allergic bronchopulmonary aspergillosis: Case report and systematic review. Mycopathologia 2015;180:209-15.
6. Seo JB, Song KS, Lee JS, Goo JM, Kim HY, Song JW, *et al.* Broncholithiasis: Review of the causes with radiologic-pathologic correlation. Radiographics 2002;22:S199-213.
7. Menivale F, Deslee G, Vallerand H, Toubas O, Delepine G, Guillou PJ, *et al.* Therapeutic management of broncholithiasis. Ann Thorac Surg 2005;79:1774-6.