RMD Open
Rheumatic & Musculoskeletal Diseases

CLINICAL CASE

Bilateral swelling of the salivary glands and sicca symptoms: an unusual differential diagnosis—Kimura's disease, a rare allergic condition with a high IgE serum level—a case report and review of the literature

Jüergen Braun ,[1] Thomas Mairinger,[2] Oliver Kaschke,[3] Kai Behrendt,[4] Josef Ramsbacher,[5] Kirsten Karberg[6]

To cite: Braun J, Mairinger T, Kaschke O, *et al*. Bilateral swelling of the salivary glands and sicca symptoms: an unusual differential diagnosis—Kimura's disease, a rare allergic condition with a high IgE serum level—a case report and review of the literature. *RMD Open* 2023;**9**:e003135. doi:10.1136/rmdopen-2023-003135

Received 7 March 2023
Accepted 29 March 2023

Check for updates

© Author(s) (or their employer(s)) 2023. Re-use permitted under CC BY-NC. No commercial re-use. See rights and permissions. Published by BMJ.

For numbered affiliations see end of article.

Correspondence to
Prof.Dr. Jüergen Braun; juebraun@gmx.de

ABSTRACT

A 68-year-old woman presented with bilateral swelling of the salivary glands, sicca symptoms of eyes and mouth, itching, fatigue and weight gain of about 5 kg in the last 2–3 years. As part of a careful diagnostic work up including lab tests for antinuclear antibodies (ANA), antibodies to extractable nuclear antigens (ENA), anti-neutrophilic cytoplasmatic antiobodies (ANCA), immunoglobulin (Ig)G4, a whole body computed tomography (CT) and a parotid biopsy several rheumatic diseases such as Sjoegren's syndrome, IgG4-related disease and sarcoidosis were ruled out and, considering a very high titre of IgE, Kimura's disease was diagnosed. The case and a short review of the literature are presented.

WHAT IS ALREADY KNOWN ON THIS TOPIC

⇒ Kimura's disease has been largely ignored in the rheumatologic literature. Most publications have been released by other specialities.

WHAT THIS STUDY ADDS

⇒ This report shows that Kimura's disease is an important rheumatologic differential diagnosis because the symptoms may resemble Sjoegren's disease, IgG4 associated disease and sarcoidosis.

HOW THIS STUDY MIGHT AFFECT RESEARCH, PRACTICE OR POLICY

⇒ Rheumatologists will likely ask more intensively for allergic symptoms such as itching and order IgE lab tests - especially in cases which present with symptoms suggestive of Sjoegren's syndrome but lab results for ANA and IgG4 were normal.

INTRODUCTION

Inflammatory musculoskeletal rheumatic diseases (RMD) comprise many different symptoms and diseases, some more localised, other with clear systemic features. Features of autoimmunity such as in Sjoegren's syndrome and of autoinflammation such as in immunoglobulin G4-related disease (IgG4-RD), both systemic immune-mediated fibroinflammatory conditions, may display symptoms related to the salivary glands such as xerostomy. The pathogenesis of these diseases is incompletely understood, and this is similar for allergic diseases, which are generally different in terms of symptoms and pathomechanisms, but swelling of salivary glands does also, even though rarely, occur. One case is described here.

Since both, rheumatic and allergic diseases, show a pathophysiologically relevant involvement of the immune system, knowledge about allergic diseases matters also for rheumatologists. In addition, the frequency of atopic disorders in RMD has been of interest in this regard, and this was related to differences in cytokine patterns based on the TH1/TH2 paradigm.[1] Indeed, it is now well established that IgE-dependent allergies are TH2 driven. The TH2 branch of the adaptive immune system favours CD4+TH2 cells, eosinophils, basophils, mast cells, type 2 innate lymphoid cells as well as the production of cytokines such as IL-4, IL-5, IL-9 and IL-13 and humoral antibody responses of the immunoglobulin antibody IgE isotype.[2] Monomers of this antibody which is found only in mammals are synthesised by plasma cells and they consist of two heavy and two

light chains. IgE, discovered in 1967,[3] is thought to be important for the immune response against infections by certain parasitic worms. However, it is also essential for type I hypersensitivity reactions that manifest in various allergic diseases such as allergic asthma and rhinitis, food allergies, chronic urticaria and atopic dermatitis. IgE also plays a pivotal role in responses to allergens, such as: anaphylactic reactions to drugs, bee stings and antigen preparations used in desensitisation immunotherapy.[4] In allergic conditions, high titres of IgE are observed—and this was also the case in the patient we describe here.

Food allergy is an inadequate response of the immune system to an antigen, in the majority of cases of a protein nature, ingested in food, that is often accompanied by the synthesis of IgE antibodies directed at allergens. These bind to type I high-affinity IgE receptors (FcεRI) on mast cells and basophils, sensitising them to contact a cognate allergen. This promotes the release of a large variety of inflammatory mediators including histamine which are responsible for the symptoms of immediate hypersensitivity.[2] Histamine is a neuro-immuno-endocrine system mediator, which influences a whole spectrum of physiologic functions of various tissues and cells, including immunity. The half-life of histamine in plasma is relatively short, a few minutes. Histamine is metabolised in several pathways in the organism, the most important one is by diamine oxidase (DAO, 5). An elevated histamine and a low DAO level were also found in our patient.

CASE REPORT

A 68-year-old woman born in Bulgaria (figure 1) presented with bilateral swelling of the salivary glands, sicca symptoms of eyes and mouth, itching, weight gain of about 5 kg in the last 2–3 years, pain and dysaesthesia in the left upper arm and fatigue which had already been ongoing for almost 2 years. Degenerative changes in the cervical spine had been documented and a mild carpal tunnel syndrome had been diagnosed about 18 months ago. A current repetition of the test showed that it is still present and now a bit worse.

Without a clear diagnosis, she had been treated with glucocorticoids elsewhere with some transient success for a short period of time some weeks ago. The patient had obstructive sleep apnea (OSA) since several years which is currently treated with a continuous positive airway pressure device. Because of a history of atrial fibrillation (probably related to OSA) and a pacemaker implantation, she could not undergo magnetic resonance imaging (MRI). A computed tomography (CT) confirmed diffuse swelling of the salivary glands without signs of lymphoma (figure 2). The first diagnostic work up revealed a diffuse swelling of the salivary glands normal laboratory parameters including blood count, liver enzymes, creatinine, antinuclear antibodies (ANA), antibodies to extractable nuclear antigens (ENA), IgG4, thyroid stimulating hormone (TSH), creatine kinase (CK), C-reactive protein (CRP), erythrocyte sedimentation rate (ESR) and a urine analysis and a normal chest radiograph. The second work up included CTs of the chest and the abdomen, only showing knotty changes in the right thyroid gland and an incidentaloma in the left adrenal gland. In addition, a high IgE level (almost 3.000 units)—commissioned because of the strong itching complained by the patient - and a slight eosinophilia (7%) were detected, while CRP, ANCA and complement levels were in the

Figure 1 The patient.

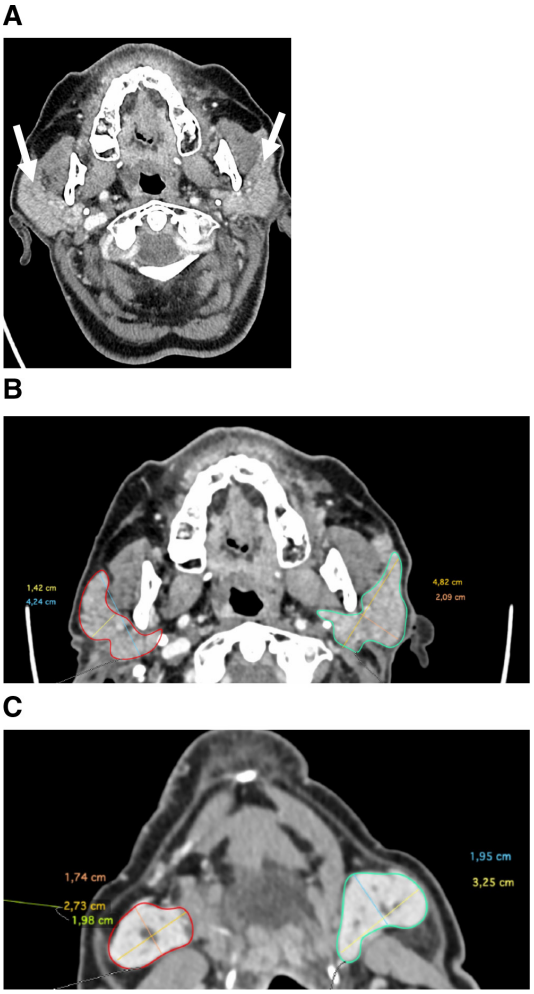

Figure 2 CT of the head showing bilaterally enlarged parotid glands (A) overview (arrows), (B) parotid glands, (C) submandibular glands. Red left, green right. The CT scan shows slightly enlarged parotid and submandibular glands (arrows) on both sides, with some differences in volume between sites.

Braun J, *et al*. *RMD Open* 2023;**9**:e003135. doi:10.1136/rmdopen-2023-003135

normal range. The patient was symptomatically treated with 10 mg of desloratadine to make itching more tolerable and 1000 mg of novaminsulfone for the pain in the left arm with some success. A parotid gland biopsy was performed, which showed lymphocytic and eosinophilic infiltrates with fibrotic changes, while there was no sign of Sjoegren's syndrome,[5–7] IgG4-related disease[8 9] or sarcoidosis,[10] but CD3, CD20 and plasma cell (Mum1) stainings demonstrated that the cellular infiltrates seen in the haematoxylin and eosin staining consisted mainly of T and B cells (figure 3A–D). These infiltrates were not close to the ducts of the salivary gland but rather diffuse tissue infiltrates. No ultrasound of the salivary glands was performed. After an intensive study of the literature, a diagnosis of Kimura's disease was made.[11–14]

A relatively large number of patients with Kimura's disease has been described earlier (see references), but we confess that we did not know the disease, and we have not seen a similar case in the last decades.

After the initial treatment with desloratadine had improved symptoms, especially itching, we prescribed a course of prednisolone starting with 1 mg/kg consequently tapered down within a few weeks. However, this was not really successful regarding general symptoms but there were typical side effects. Nevertheless, the eosinophil count went down and there was the impression that the enlargement of the glands had improved after 6 weeks. However, the patient insisted to discontinue prednisolone, and the IgE level was even a bit higher than initially.

A decision was made to first repeat the allergy tests which had been normal 4 years ago.

Serologic testing (Fluoreszenz-Enzym-Immunoassay, Fa. Thermo Fisher) revealed an allergic rection against mugwort, chicken and milk protein. The serum level of histamine was slightly elevated (1.2 ng/mL), while the level of diaminooxidase was low (5.9 U/mL).

At first, it was found that there is currently no bad need to treat with immunosuppressives or anti-IgE or anti-IL-4/13 antibodies, and the patient did not want to take those drugs.

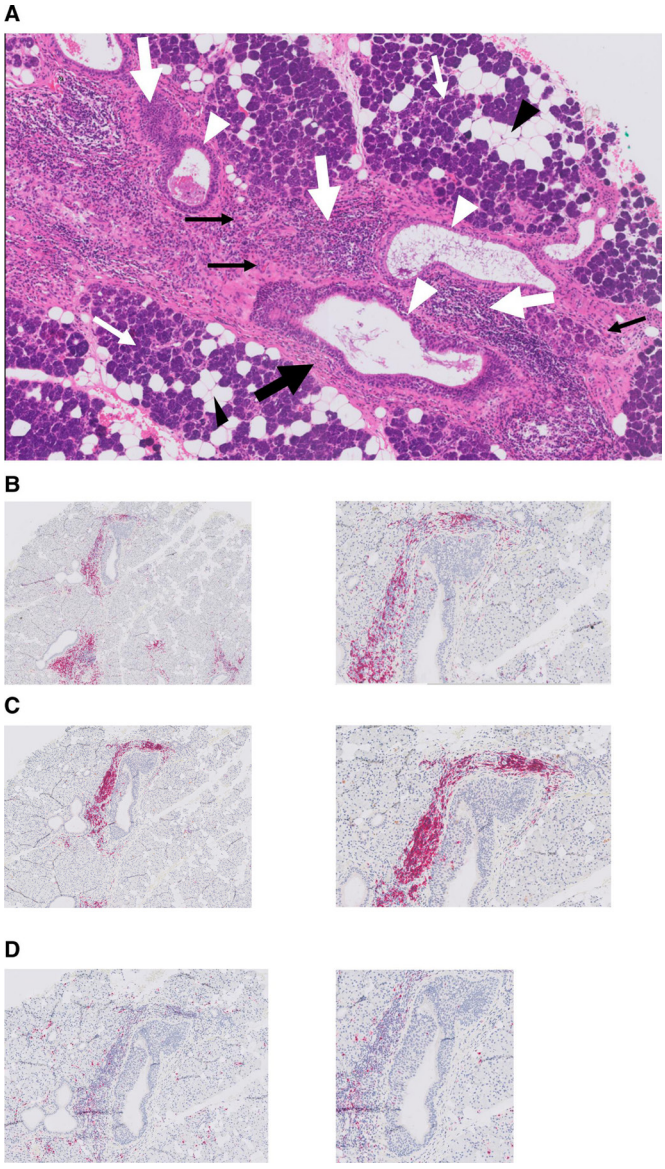

Figure 3 (A) Biopsy from the parotid gland: HE staining showing eosinophilic and lymphocytic infiltrates and fibrotic changes. The biopsy of the parotid gland of the patient described shows acini composed of serous cells with darkly staining granules (thin white arrows) and some admixed fat cells (black arrowheads), intercalated ducts lined by cuboidal epithelium (white arrowheads). Cellular infiltrates contain lymphocytes (thick white arrows) and eosinophilic granulocytes (black arrows). Bands of fibrous tissue (thick black arrow). Surrounds gland and separates lobules. (B) Biopsy from the parotid gland: staining for CD 3+T cells. The CD 3 staining demonstrates T cell infiltrates close to the ducts. (C) Biopsy from the parotid gland: staining for CD 20+B cells. The CD 20 staining demonstrates B cell infiltrates close to the ducts. (D) Staining for Mum 1 (plasma cells). The Mum1 staining shows that there are plasma cells in the tissue of the parotid gland at different sites.

DISCUSSION

A case of Kimura's disease is reported because it represents a rare differential diagnosis[11–15] to important inflammatory RMD,[16] namely primary Sjoegren's syndrome,[17 18] IgG4-related disease[19 20] and even eosinophilic granulomatosis with polyangiitis.[21] There was no evidence for a hyper IgE-syndrome either.[22]

Head and neck involvement has been described in many RMD patients.[16] The differential diagnosis of IG4-related sialadenitis and Kimura's disease has been recently studied and discussed in much detail based on 85 cases with IgG4-related disease and 52 with Kimura's disease.[15] In IgG4-related disease, the vast majority of cases had enlargement of multiple salivary and/or lacrimal glands and most patients had bilateral submandibular gland involvement. In Kimura's disease, unilateral parotid gland involvement and comorbid skin lesions were present in more than half of the patients. In IgG4-related disease, serum IgG4 levels were elevated in >90% of cases versus only in 19% in Kimura's disease.[15]

Elevated eosinophil counts and elevated IgE concentrations were found in most patients with Kimura's disease (86% and 96%, respectively) but also, even though less frequently, in IgG4-related disease (23% and 77%, respectively). In the latter, storiform fibrosis, irregular lymphoid follicles and increased IgG4-positive cells were common, while acellular fibrosis, regular lymphoid follicles, IgE-positive reticular networks, increased IgE-positive cells and tryptase-positive mast cells were more often detected in Kimura's disease.[15 23] In addition, in IgG4-related disease, lymphoplasmacytic infiltration and obliterative phlebitis have been described as being rather characteristic.[15] Involvement of specific T cells has been described in Kimura's disease,[24 25] and many differences in comparison to IgG4-related disease.[25] Taken together, there were several overlapping manifestations in that study, but histopathological examination revealed meaningful differences in the types of fibrosis, eosinophils and IgG4-positive cell counts.

In our patient, the leading symptoms were swelling of the face and itching. The main lab finding was a high IgE titre. Salivary glands were enlarged and the parotid biopsy revealed eosinophilic and lymphocytic infiltrates with some fibrosis. There was no expression of IgG4, there were no granulomas (sarcoidosis) and no foci according to Chisholm and Mason[6] suggestive of Sjoegren's syndrome.

A first publication of Kimura's disease occurred already in 1937 in a Chinese medical journal.[26] Accordingly, the disease has been described more often in Asians, but it does occur in non-Asians with a similar clinicopathologic presentation. It is a distinctive entity with no known aetiology that reportedly occurs more frequently in Asia where it affects more male patients, and lymph node involvement is common.[11–15]

The differential diagnosis of Kimura's disease also includes angiolymphoid hyperplasia with eosinophilia, angioimmunoblastic T-cell lymphoma, Hodgkin lymphoma, Langerhans cell histiocytosis, Castleman disease, florid follicular hyperplasia, dermatopathic lymph-adenopathy, drug reaction, tumour node metastases and parasitic lymphadenitis.[27]

At the centre of the pathogenesis of allergic diseases is the IgE antibody molecule.[2 3] The physiological function of IgE is to provide protective immunity against helminth parasites, but it can also mediate type I hypersensitivity reactions that contribute to the pathogenesis of allergic diseases such as asthma, allergic rhinitis and atopic dermatitis. However, despite IgE causing an abundance of human disease, it was not until 1967 that the molecule was discovered,[2] and this is in part due to its very low serum concentration relative to other antibody isotypes—over one hundred thousand-fold less than IgG in healthy individuals.[3] Despite the importance of IgE in immune biology and allergic pathogenesis, the cells and the pathways that produce and regulate IgE in detail are poorly understood. In sensitised individuals, re-exposure to the allergen results in IgE engagement, causing Fcε receptor cross-linking and activation of mast cells and basophils. The two primary vasoactive mediators histamine and cysteinyl-leukotrienes which are released by eosinophils, T cells, mast cells and basophils regulate the production of IgE on a local and systemic level.[3] This triggers the release of mediators into the local tissue, leading to a broad array of immediate symptoms associated with allergy. Chronic allergic inflammation is often associated with raised IgE titres which are normally <100 U/mL, but the frequency of IgE-producing memory B cells in peripheral blood is exceedingly low.[3] Studies of the human IgE molecule, and its targeted epitopes on allergens, have been rather limited to date.

The serologic examination revealed an allergic sensitisation to mugwort, chicken and milk protein and an increased serum level of histamine together with a low level of DAO—a finding frequently reported in food intolerance, a non-allergic food hypersensitivity, treated with low-histamine diet. A good response to such a diet confirms the diagnosis. Alongside the dietary measures, DAO supplementation supporting the degradation of ingested histamine can be tried.[28] In the case of our patient, allergen avoidance was recommended.

The anti-IgE monoclonal antibody omalizumab that binds to free IgE in the blood, and inhibits the activation of inflammatory mechanisms, has already been approved to treat severe asthmatic conditions many years ago. Since Kimura's disease is suspected to be an IgE-mediated allergic disorder, a pilot study with omalizumab has indeed been performed.[29] Three patients received a fixed schedule of 8 cycles of omalizumab 300 mg subcutaneous (s.c.) at intervals of 2 weeks. With that therapy, the size of the masses and peripheral blood eosinophil counts decreased. However, omalizumab may not work well in patients whose total serum IgE levels are >1500 U/mL.[30]

In another case, report on a patient with Kimura's disease oral glucocorticoids had been administered for 1 year, but the masses recurred as the dosage was tapered down.[31] Subsequently, anti-IgE therapy with omalizumab was administered at 450 mg s.c. at 4-week intervals. The size of the masses, the serum IgE level and the percentage of eosinophils did not decrease significantly after 19 cycles of continuous treatment. Thereafter, dupilumab, a monoclonal antibody blocking IL-4 and IL-13 that is approved for allergic diseases such as atopic dermatitis,[32] was administered in an initial dose of 600 mg, followed by 300 mg every 2 weeks for 4 months. This treatment demonstrated dramatic effects with reduced masses and fast dropdown of eosinophil counts, while the high level of serum IgE remained high.

Taken together, the clinical picture of Kimura's disease differs and therapy is not straight forward,[33] but there are developments, especially with anti-IgE and anti IL-4/IL-13 antibodies.[31 32] Surgical procedures and radiotherapy have also been successfully used, especially in patients with large masses.[34] However, several reports

also stress that the course of the disease may be rather benign—even with no specific therapy.[33]

The further course of the disease will be challenging, we are ready to try dupilumab in this patient who clearly has a reduced quality of life but is now considering to try a biologic drug.

Author affiliations
[1]Rheumapraxis Berlin, Ruhr University Bochum, Berlin, Germany
[2]Dept. of Pathology, Medizinisches Versorgungszentrum am Helios Klinikum Emil von Behring, Berlin, Germany
[3]Dept of Otorhinolaryngology, St.Gertrauden Krankenhaus, Humboldt-Universität zu Berlin, Berlin, Germany
[4]Roentgenpraxis Radiologie Eins, Humboldt-Universitat zu Berlin, Berlin, Germany
[5]Praxis für Neurochirurgie, Humboldt-Universitat zu Berlin, Berlin, Germany
[6]Rheumapraxis Berlin, Humboldt-Universitat zu Berlin, Berlin, Germany

Acknowledgements We acknowledge the contribution of Prof.B.Tebbe who made the allergy tests and Prof.M.Laniado who gave advice for imaging interpretation.

Contributors All authors have contributed. In detail, JB and KK have made the diagnosis, are responsible for patient management and have written the manuscript. TM has been responsible for the (immuno)histology, OK has made the parotid biopsy, KB has been responsible for imaging and JR has made the neurological examination and has referred the patient to rheumatology.

Funding We acknowledge support by the Open Access Publication Funds of the Ruhr-Universität Bochum and the Rheumazentrum Ruhrgebiet.

Competing interests None declared.

Patient consent for publication Consent obtained directly from patient(s).

Ethics approval Not applicable.

Provenance and peer review Not commissioned; externally peer reviewed.

Open access This is an open access article distributed in accordance with the Creative Commons Attribution Non Commercial (CC BY-NC 4.0) license, which permits others to distribute, remix, adapt, build upon this work non-commercially, and license their derivative works on different terms, provided the original work is properly cited, appropriate credit is given, any changes made indicated, and the use is non-commercial. See: http://creativecommons.org/licenses/by-nc/4.0/.

ORCID iD
Jüergen Braun http://orcid.org/0000-0002-9156-5095

REFERENCES

1 Rudwaleit M, Andermann B, Alten R, *et al*. Atopic disorders in ankylosing spondylitis and rheumatoid arthritis. *Ann Rheum Dis* 2002;61:968–74.
2 Vitte J, Vibhushan S, Bratti M, *et al*. Allergy, anaphylaxis, and nonallergic hypersensitivity: IgE, mast cells, and beyond. *Med Princ Pract* 2022;31:501–15.
3 Ishizaka K, Ishizaka T. Identification of γE-antibodies as a carrier of reaginic activity. *J Immunol* 1967;99:1187–98.
4 Smith SA, Chruszcz M, Chapman MD, *et al*. Human monoclonal IgE antibodies-a major milestone in allergy. *Curr Allergy Asthma Rep* 2023;23:53–65.
5 Sjögren H. On knowledge of keratoconjunctivitis sicca: keratitis filiformis due to lacrimal gland hypofunction. *Acta Ophthalmol* 1933;2:1–151.
6 Chisholm DM, Mason DK. Labial salivary gland biopsy in Sjögren's disease. *J Clin Pathol* 1968;21:656–60.
7 Shiboski CH, Shiboski SC, Seror R, *et al*. 2016 American College of rheumatology/european League against rheumatism classification criteria for primary Sjögren's syndrome: a consensus and data-driven methodology involving three international patient cohorts. *Ann Rheum Dis* 2017;76:9–16.
8 Wallace ZS, Zhang Y, Perugino CA, *et al*. Clinical phenotypes of IgG4-related disease: an analysis of two international cross-sectional cohorts. *Ann Rheum Dis* 2019;78:406–12.
9 Wallace ZS, Naden RP, Chari S, *et al*. The 2019 American College of Rheumatology/European League against rheumatism classification criteria for IgG4-related disease. *Arthritis Rheumatol* 2020;72:7–19.
10 James DG, Sharma OP. Parotid gland sarcoidosis. *Sarcoidosis Vasc Diffuse Lung Dis* 2000;17:27–32.
11 Kimura T, Yoshimura S, Ishikawa E. Unusual granulation combined with hyperplastic changes of lymphatic tissue. *Trans Soc Pathol Jpn* 1948;37:179–80.
12 Chen H, Thompson LDR, Aguilera NSI, *et al*. Kimura disease: a clinicopathologic study of 21 cases. *Am J Surg Pathol* 2004;28:505–13.
13 Kottler D, Barète S, Quéreux G, *et al*. Retrospective multicentric study of 25 Kimura disease patients: emphasis on therapeutics and shared features with cutaneous IgG4-related disease. *Dermatology* 2015;231:367–77.
14 Lee CC, Yu KH, Chan TM. Kimura's disease: a clinicopathological study of 23 cases. *Front Med (Lausanne)* 2022;9:1069102.
15 Zhu WX, Zhang YY, Sun ZP, *et al*. Differential diagnosis of immunoglobulin G4-related sialadenitis and Kimura's disease of the salivary gland: a comparative case series. *Int J Oral Maxillofac Surg* 2021;50:895–905.
16 Knopf A, Bas M, Chaker A, *et al*. Rheumatic disorders affecting the head and neck: underestimated diseases. *Rheumatology (Oxford)* 2011;50:2029–34.
17 Baldini C, Pepe P, Quartuccio L, *et al*. Primary Sjogren's syndrome as a multi-organ disease: impact of the serological profile on the clinical presentation of the disease in a large cohort of Italian patients. *Rheumatology (Oxford)* 2014;53:839–44.
18 Goules AV, Tzioufas AG. Primary Sjögren's syndrome: clinical phenotypes, outcome and the development of biomarkers. *Immunol Res* 2017;65:331–44.
19 Yamamoto M, Harada S, Ohara M, *et al*. Clinical and pathological differences between Mikulicz's disease and Sjögren's syndrome. *Rheumatology (Oxford)* 2005;44:227–34.
20 Kamisawa T, Zen Y, Pillai S, *et al*. Igg4-Related disease. *Lancet* 2015;385:1460–71.
21 Aravinthan M, Atukorala I, De Silva C. A diagnostic conundrum; Kimura's disease mimicking eosinophilic granulomatosis with polyangiitis. *SAGE Open Med Case Rep* 2022;10:2050313X211070522.
22 Rael EL, Marshall RT, McClain JJ. The hyper-IgE syndromes: lessons in nature, from bench to bedside. *World Allergy Organ J* 2012;5:79–87.
23 Kimura Y, Pawankar R, Aoki M, *et al*. Mast cells and T cells in Kimura's disease express increased levels of interleukin-4, interleukin-5, eotaxin and RANTES. *Clin Exp Allergy* 2002;32:1787–93.
24 Maehara T, Munemura R, Shimizu M, *et al*. Tissue-infiltrating immune cells contribute to understanding the pathogenesis of Kimura disease: a case report. *Medicine (Baltimore)* 2019;98:e18300.
25 Munemura R, Maehara T, Murakami Y, *et al*. Distinct disease-specific Tfh cell populations in 2 different fibrotic diseases: IgG4-related disease and Kimura disease. *J Allergy Clin Immunol* 2022;150:440–55.
26 Kim HT. Eosinophilic hyperplastic lymphogranuloma, comparison with Mikulicz's disease. *Chin Med J* 1937;23:699–670.
27 Kim WJ, Kim HK. Current concepts of Kimura disease: pathophysiology and evolution of treatment. *Arch Craniofac Surg* 2022;23:249–55.
28 Hrubisko M, Danis R, Huorka M, *et al*. Histamine intolerance-the more we know the less we know. A review. *Nutrients* 2021;13:2228.
29 Nonaka M, Sakitani E, Yoshihara T. Anti-Ige therapy to Kimura's disease: a pilot study. *Auris Nasus Larynx* 2014;41:384–8.
30 Ye P, Ma DQ, Yu GY, *et al*. Comparison of the efficacy of different treatment modalities for Kimura's disease. *Int J Oral Maxillofac Surg* 2017;46:350–4.
31 Yang B, Yu H, Jia M, *et al*. Successful treatment of dupilumab in Kimura disease independent of IgE: a case report with literature review. *Front Immunol* 2022;13:1084879.
32 Beck LA, Thaçi D, Hamilton JD, *et al*. Dupilumab treatment in adults with moderate-to-severe atopic dermatitis. *N Engl J Med* 2014;371:130–9.
33 Abuel-Haija M, Hurford MT. Kimura disease. *Arch Pathol Lab Med* 2007;131:650–1.
34 Lee CC, Feng IJ, Chen YT, *et al*. Treatment algorithm for Kimura's disease: a systematic review and meta-analysis of treatment modalities and prognostic predictors. *Int J Surg* 2022;100:106591.