Allergology International. 2009;58:✱✱✱-✱✱✱
DOI: 10.2332/allergolint.09-OA-0100

ORIGINAL ARTICLE

Evaluation of Novel Scoring System Named 5-5-5 Exacerbation Grading Scale for Allergic Conjunctivitis Disease

Jun Shoji[1], Noriko Inada[1] and Mitsuru Sawa[1]

ABSTRACT

Background: The objective of this study is to evaluate the practical usefulness of a scoring system using the 5-5-5 exacerbation grading scale for allergic conjunctivitis disease (ACD).

Methods: Subjects were 103 patients with ACD including 40 patients with vernal keratoconjunctivitis (VKC), 20 patients with atopic keratoconjunctivitis (AKC), and 43 patients with allergic conjunctivitis (AC).

The 5-5-5 exacerbation grading scale consists of the following 3 graded groups of clinical observations: the 100-point-grade group (100 points for each observation) includes active giant papillae, gelatinous infiltrates of the limbus, exfoliative epithelial keratopathy, shield ulcer and papillary proliferation at lower palpebral conjunctiva; the 10-point-grade group (10 points for each observation) includes blepharitis, papillary proliferation with velvety appearance, Horner-Trantas spots, edema of bulbal conjunctiva, and superficial punctate keratopathy; and the 1-point-grade group (1 point for each observation) includes papillae at upper palpebral conjunctiva, follicular lesion at lower palpebral conjunctiva, hyperemia of palpebral conjunctiva, hyperemia of bulbal conjunctiva, and lacrimal effusion. The total points in each grade group were determined as the severity score of the 5-5-5 exacerbation grading scale.

Results: The median severity scores of the 5-5-5 exacerbation grading scale in VKC, AKC and AC were 243 (range: 12-444), 32.5 (11-344), and 13 (2-33), respectively. The severity score of each ACD disease type was significantly different ($P < 0.001$, Kruskal-Wallis test). The severity of each type of ACD was classified as severe, moderate, or mild according to the severity score.

Conclusions: The 5-5-5 exacerbation grading scale is a useful clinical tool for grading the severity of each type of ACD.

KEY WORDS

allergic conjunctivitis, atopic keratoconjunctivitis, clinical severity score, vernal keratoconjunctivitis

INTRODUCTION

Allergic conjunctivitis disease (ACD) is a conjunctival inflammatory disorder caused by an immediate hypersensitivity response. ACD is divided into several clinical types such as allergic conjunctivitis (AC), atopic keratoconjunctivitis (AKC) and vernal keratoconjunctivitis (VKC).[1] However, each clinical type of ACD is different in severity and pathognomonic clinical manifestations. They are influenced by genetic elements and environmental factors such as season, climate, and home environment. Therefore, in clinical practice with ACD patients, an accurate diagnosis of the severity of the disease is essential in selecting the most effective therapy.

Converting clinical observations into clinical scores is useful when evaluating the clinical severity of ACD objectively. Results of epidemiological investigations and measurement of the effects of therapeutic drugs using clinical scores have been reported.[2-7] The effective severity score may make it possible to objectively determine the indication or cancellation stage for

[1]Department of Ophthalmology, Division of Visual Sciences, Nihon University School of Medicine, Tokyo, Japan.
Correspondence: Jun Shoji, Department of Ophthalmology, Division of Visual Sciences, Nihon University School of Medicine, 30–1 Oyaguchi-kamimachi, Itabashi-ku, Tokyo 173–8610, Japan.
Email: shojig@med.nihon–u.ac.jp
Received 6 March 2009. Accepted for publication 10 June 2009.
©2009 Japanese Society of Allergology

Table 1 Number and characteristics of the subjects

	No. of subjects	Age (Years) (Mean ± SD)	Sex (Male : Female)
AC	43	25.7 ± 17.0	21 : 22
AKC	20	24.5 ± 12.4	11 : 9
VKC	40	16.1 ± 8.3	34 : 6

AC, allergic conjunctivitis; AKC, atopic keratoconjunctivitis; VKC, vernal keratoconjunctivitis.

therapeutic drugs such as antiallergic drugs, immunosuppressive drugs, or corticosteroids. On the other hand, when we treat patients with ACD, the use of a clinical severity scoring system that reflects subtle variations in the severity of ACD is helpful for our practice. The scores for a clinical severity scoring system should be simple and quick to judge, and severity scores should not be determined based on the individual differences of the observers. In addition, by sharing the clinical severity score between the doctor, patient and patient's family, it can increase their involvement in the planning for treatment. It may also improve self-care of the patient.

We used the 5-5-5 exacerbation grading scale to evaluate the clinical severity of patients with ACD. The aim of our study was to evaluate the utility of this scale.

METHODS

SUBJECTS

Subjects were 103 patients (103 eyes) with ACD who visited the Department of Ophthalmology, Nihon University Itabashi Hospital, between January 2004 and December 2007. For every patients with ACD, informed consent for this study was obtained before enrollment. Patients with ACD were classified into 3 groups; 40 patients (40 eyes) with VKC, 20 patients (20 eyes) with AKC, and 43 patients (43 eyes) with AC. Demographic data are shown in Table 1. ACD was diagnosed based on the following 3 criteria: (1) having slit-lamp microscopic findings of ACD, (2) undergone examination for allergen-specific IgE antibodies in serum such as house-dust-mite or Japanese cedar pollen by the AlaSTAT® (Mitsubishi Kagaku Iatron, Tokyo, Japan) method, and identified to be positive for some allergens, (3) patients with non-allergic conjunctivitis, such as infectious conjunctivitis, phlyctenular keratoconjunctivitis, superior limbic keratoconjunctivitis, drug toxicity conjunctivitis, and cicatricial conjunctivitis, were excluded from the study.

Furthermore, ACD was classified into AC, VKC and AKC according to the characteristics of the following clinical observations.[8] AC is papillary conjunctivitis, which is characterized by itching, burning, redness, chemosis, and lid edema, but without proliferative conjunctival lesions such as giant papillae of the superior tarsal conjunctiva or gelatinous hypertrophy of the limbus. VKC is a recurrent and chronic conjunctivitis with mucous discharge, characterized by proliferative conjunctival lesion and keratopathy. AKC is a chronic ocular surface disorder related to atopic dermatitis and characteristics of AKC are reported by Hogan[9] and Foster.[10]

THE 5-5-5 EXACERBATION GRADING SCALE

The guidelines for evaluating the 5-5-5 exacerbation grading scale are demonstrated in Table 2. The critical clinical observations of ACD were classified into the 100-point-grade group, 10-point-grade group or 1-point-grade group, according to the clinical severity of ACD, and 5 critical findings were identified in each grade group. Each positive observation in the 100-point-grade group represented 100 points. Each positive observation in the 10-point-grade group represented 10 points, and each positive observation in the 1-point-grade group represented 1 point. When there were no findings it was scored as 0 points. Finally, the 5-5-5 exacerbation grading scale was determined by the number of total points scored from clinical observations.

The 100-point-grade group was determined based on the the presence of the following observations: active giant papillae (Fig.1 A-1), gelatinous infiltrates of the limbus (Fig.1 A-2), exfoliative corneal epitheliopathy (Fig.1 A-3), shield ulcer (Fig.1 A-4), and papillary proliferation at lower tarsal conjunctiva (Fig.1 A-5). The guidelines for evaluation are shown in Figure 1. The 10-point-grade group was determined based on the presence of the following observations: blepharitis (Fig.2 B-1), papillary proliferation with velvety appearance (Fig.2 B-2), Horner-Trantas spot (Fig.2 B-3), edema of bulbal conjunctiva (Fig.2 B-4), and superficial punctate keratopathy (Fig.2 B-5). The guidelines for evaluation are shown in Figure 2. The 1-point-grade group was determined based on the presence of the following observations: papillae at upper tarsal conjunctiva (Fig.3 C-1), follicular lesion at lower tarsal conjunctiva (Fig.3 C-2), hyperemia of tarsal conjunctiva (Fig.3 C-3), hyperemia of bulbal conjunctiva (Fig.3 C-4), and lacrimal effusion (Fig.3 C-5). The guidelines for evaluation are shown in Figure 3. Furthermore, the severity classes of each group were divided into mild, moderate or severe, according to the criteria shown in Table 3.

RESULTS

Results using the 5-5-5 exacerbation grading scale in patients with AC, AKC and VKC are shown in Figure 4. The median severity scores of the 5-5-5 exacerbation grading scale in each group showed 13 in the AC group, 32.5 in the AKC group, and 243 in the VKC group. A statistically significant difference was found among the groups ($P < 0.001$, Kruskal-Wallis test). In addition, the distribution of this scale for the AC,

Table 2 Judging guidelines for 5-5-5 exacerbation grading scale for allergic conjunctivitis disease

	Exacerbation grading scale		
Grade of clinical sign	100-point-grade	10-point-grade	1-point-grade
Clinical signs	Active giant papillae †	Blepharitis	Papillae at upper palpebral conjunctiva
	Gelatinous infiltrates of the limbus	Papillary proliferation with velvety appearance	Follicular lesion at lower palpebral conjunctiva
	Exfoliative epithelial keratopathy	Horner-Trantas spots	Hyperemia of palpebral conjunctiva
	Shield Ulcer	Edema of bulbal conjunctiva	Hyperemia of bulbal conjunctiva
	Papillary proliferation at lower palpebral conjunctiva	Superficial punctate keratopathy	Lacrimal effusion ‡
Score	100 points × number of positive signs	10 points × number of positive signs	1 point × number of positive signs
Range	0-500 points	0-50 points	0-5 points

† "Active giant papillae" means the giant papillary proliferation that spreads in hemispherical shape with mucous discharge, but mucous discharge is not essential. Giant papillae with flatness and poor inflammation findings are excluded.

‡ "Lacrimal effusion" refers to epiphora or tear meniscus increase caused by an eye irritation symptom.

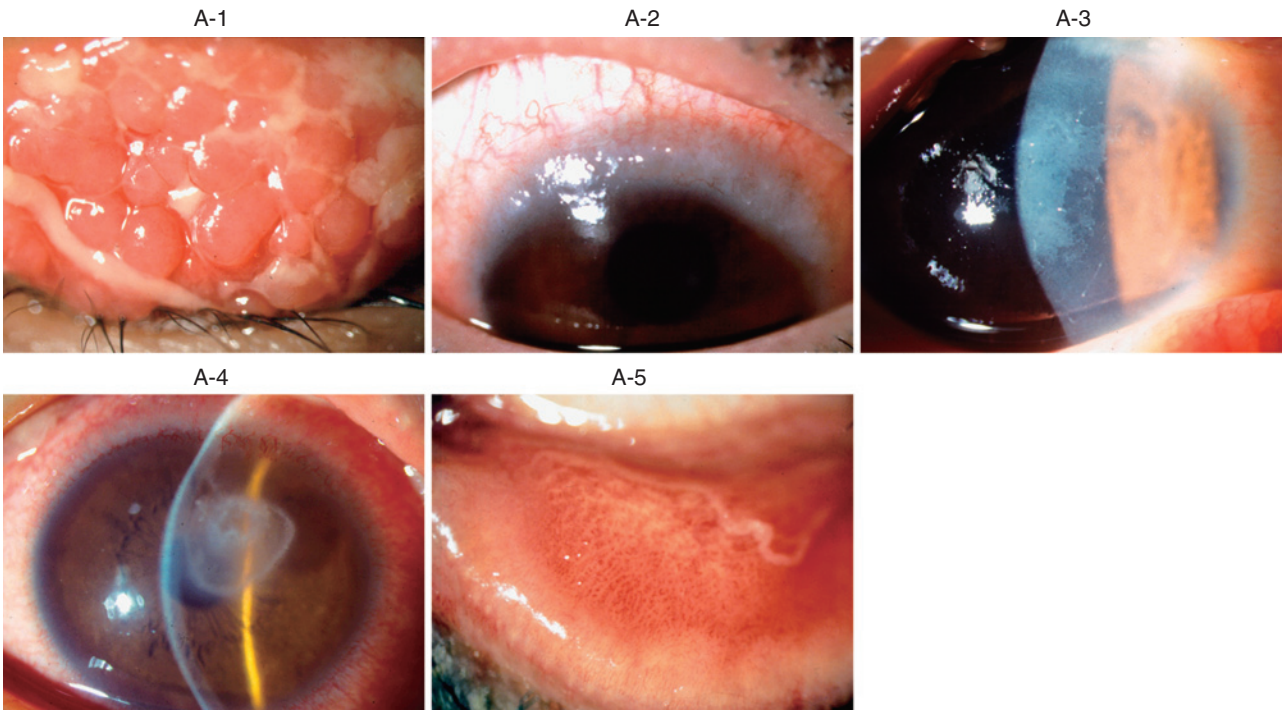

Fig. 1 **A-1**: Active giant papillae. "Active giant papillae" means a giant papillary proliferation (cobblestone appearance) that spreads in a hemispherical shape on the superior tarsal conjunctiva with mucous discharge. **A-2**: Gelatinous infiltrates of the limbus. Broad, thickened and gelatinous opacification is observed at the limbus. **A-3**: Exfoliative epithelial keratopathy. Exfoliative epithelial keratopathy is superficial punctate keratopathy with a mucous thread containing the fibrinous discharge, infiltrated inflammatory cells and deciduous epithelium. Clinical appearance is forming reticular and white opacification at the corneal surface. **A-4**: Shield ulcer. Shield ulcer is a horizontally oval, shallow and nonvascularized ulcer of the cornea. **A-5**: Papillary proliferation at lower palpebral conjunctiva. The papillary proliferation at the lower palpebral conjunctiva is a clinical observation to be distinguished from the papillary proliferation at the upper palpebral conjunctiva. The velvety appearance of the papillary proliferation is observed in patients with severe atopic keratoconjunctivitis.

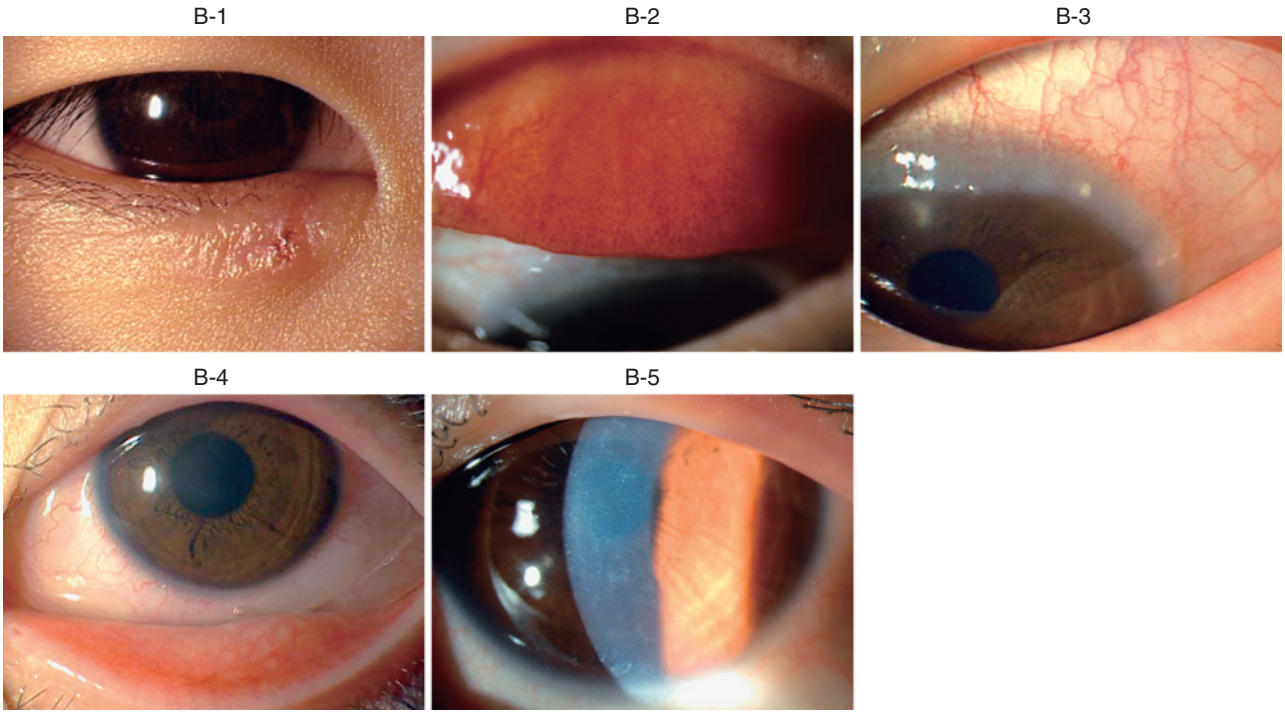

Fig. 2 **B-1**: blepharitis. **B-2**: papillary proliferation with velvety appearance. **B-3**: Horner-Trantas spots. **B-4**: edema of bulbal conjunctiva. **B-5**: superficial punctate keratopathy.

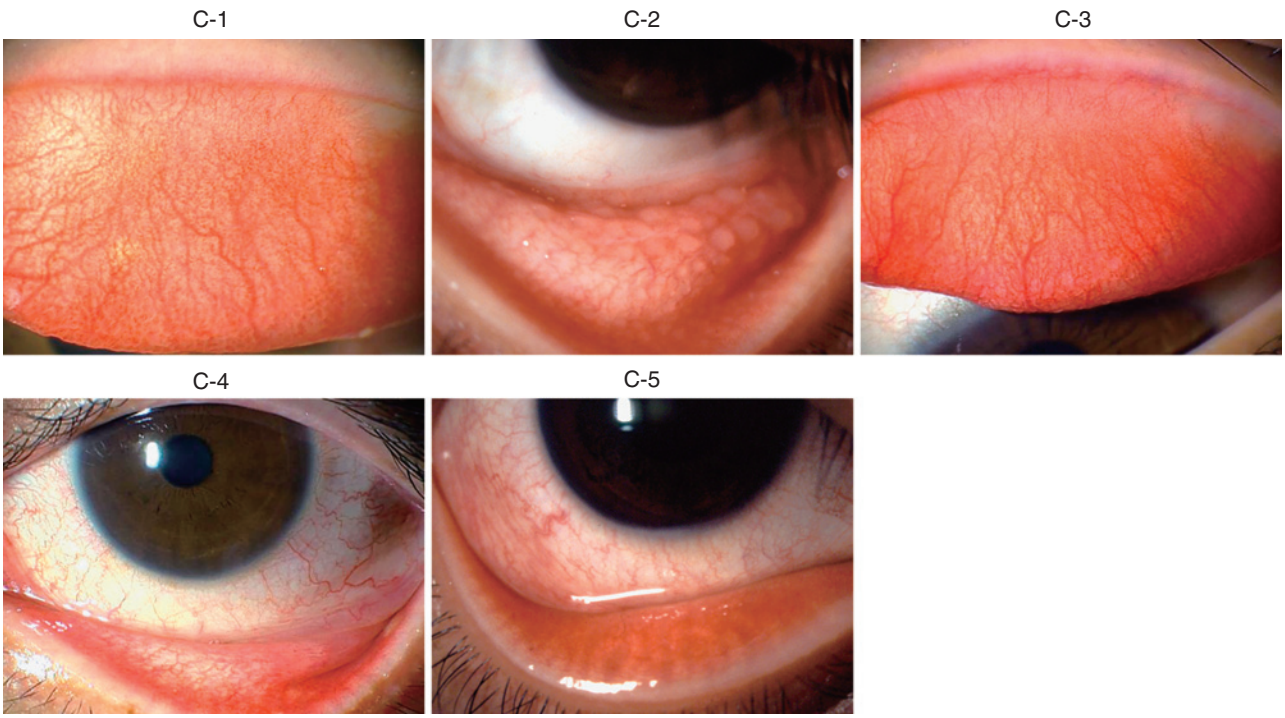

Fig. 3 **C-1**: papillae at upper palpebral conjunctiva. **C-2**: follicular lesion at lower palpebral conjunctiva. **C-3**: hyperemia of palpebral conjunctiva. **C-4**: hyperemia of bulbal conjunctiva. **C-5**: lacrimal effusion. "Lacrimal effusion" means epiphora or tear meniscus increase caused by an eye irritation symptom.

Table 3 Criteria of severity classification in allergic conjunctivitis disease

	AC	AKC	VKC
Severe	More than three clinical observations classified in 10-point-grade are observed, and those in 100-point-grade are absent.	At least one of the clinical observation classified in 100-point-grade is observed.	More than two clinical observations classified in 100-point-grade are observed.
Moderate	Less than two clinical observations classified in 10-point-grade are observed, and those in 100-point-grade are absent.	More than three clinical observations classified in 10-point-grade are observed, and those in 100-point-grade are absent.	Only one clinical observation classified in 100-point-grade is observed.
Mild	Clinical observation classified in 10- or 100-point-grade is absent.	Less than two clinical observations classified in 10-point-grade are observed, and those in 100-point-grade are absent.	Clinical observation classified in 100-point-grade is absent.

AC, allergic conjunctivitis; AKC, atopic keratoconjunctivitis; VKC, vernal keratoconjunctivitis.

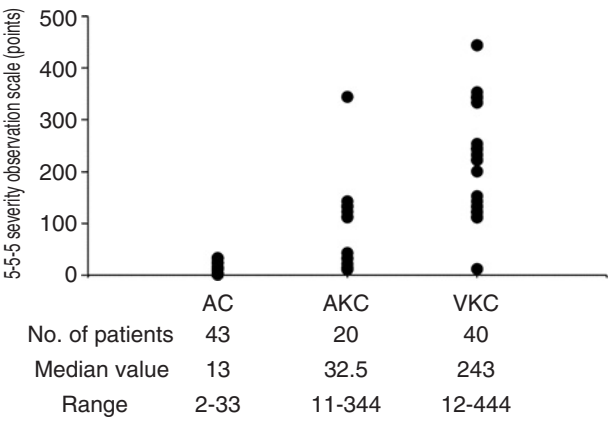

Fig. 4 Results of severity score determined by 5-5-5 exacerbation grading scale in VKC, AKC and AC patients. The severity scores of each type of allergic conjunctivitis disease were significantly different among VKC, AKC and AC patients. ($P < 0.001$, Kruskal-Wallis test). VKC, vernal keratoconjunctivitis; AKC, atopic keratoconjunctivitis; AC, allergic conjunctivitis.

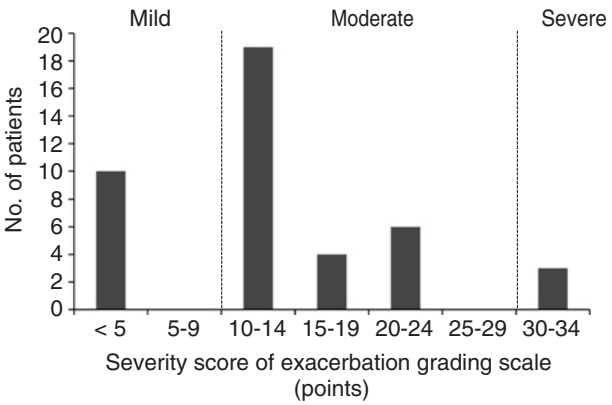

Fig. 5 Distribution of the severity score in allergic conjunctivitis patients. The border value to distinguish moderate severity from mild severity was determined as 10 points. The border value to distinguish severe severity from moderate severity was determined as 30 points.

AKC and VKC groups are shown as graphs in Figure 5, 6, and 7, respectively. The severity classes of each group were divided into mild, moderate or severe, according to the criteria shown in Table 3. The number of patients in each severity group is shown in Figure 5, 6, and 7.

DISCUSSION

We set out to determine the practical usefulness of a scoring system using the 5-5-5 exacerbation grading scale for allergic conjunctivitis disease (ACD). This study demonstrated that the use of the 5-5-5 exacerbation grading scale to assess clinical observations of ACD using the clinical severity score is simple and quick, and therefore suitable for follow-up examinations. The simplicity of the grading method, judging representative ACD findings as either present or absent, was reflected in the low inter-observer variability. There have been reports on clinical scores of patients with ACD[2,3,7] in which the severity of ACD and the effects of antiallergic drugs were evaluated using clinical scores. Clinical scores were used to determine a multi-point score for each representative observation of ACD. For each end point, 'severe' was equivalent to 3 points, 'moderate' to 2 points and 'mild' to 1 point. However, the problem with such clinical scores is that 1 point may represent a different of severity for each observation category. However, using our method, the 3-graded clinical observations provide the best measure for current severity of diseases in patients with ACD. An example of a 3-graded evaluation is the Japanese coma scale, which is used to evaluate comatose status using a 3-3-9 grading scale.[11] A characteristic of this evaluation method is that the score expresses clinical severity precisely by giving high points for severe observations and low points for mild observations. The 5-5-5 exacerbation grading scale used in our study follows the same con-

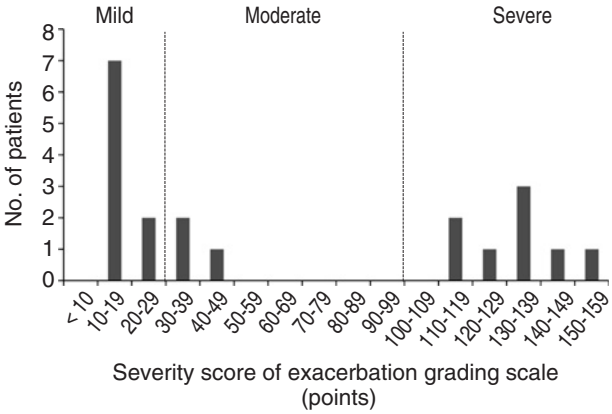

Fig. 6 Distribution of the severity scores in atopic keratoconjunctivitis patients. The border value to distinguish moderate severity from mild severity was determined as 30 points. The border value to distinguish severe severity from moderate severity was determined as 100 points.

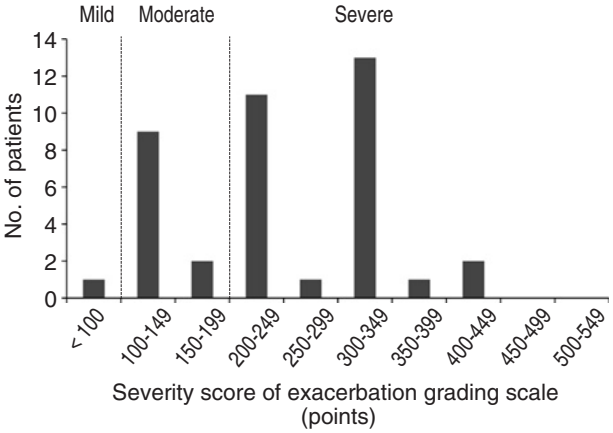

Fig. 7 Distribution of the severity score in vernal keratoconjunctivitis patients. The border value to distinguish moderate severity from mild severity was determined as 100 points. The border value to distinguish severe severity from moderate severity was determined as 200 points.

cept as this coma scale. According to our grading scale, the observations found in patients with severe VKC or AKC were classified as the "100-point-grade group" where 1 end point was equivalent to 100 points. Similarly, the observations found in patients with mild VKC or with severe AC were classified as the "10-point-grade group", where 1 end point was equivalent to10 points. The observations found in patients with mild AC were classified as the "1-point-grade group", where 1 end point was equivalent to 1 point. Therefore, using this exacerbation grading scale, the accumulation of severity scores could be found in severe cases. It is obvious that as the condition of the patient improves the severity score decreases, to the point where the patient no longer appears for treatment, with the consequent absence of further clinical findings.

In selecting the determinants for our grading scale, clinical observations with high frequency were adopted. General observations for VKC, giant papillae, gelatinous proliferative lesion at the limbus, and shield ulcer are noted.[6,12,13] In addition, it has been reported that the papillary proliferation often found in the lower palpebral conjunctiva is crucial in AKC observation.[14,15] Therefore, the determinants for the 100-point-grade group contain those observations which develop in patients with severe VKC and AKC. It has been reported that corneal plaque and fibrosis of the palpebral conjunctiva are pathognomonic observations developing in patients with VKC and AKC. It is rare that both were observed in the acute phase of allergic inflammation as they are often present in the healing stage, and therefore, cornea plaque and fibrosis of the palpebral conjunctiva were excluded in this scale for the purpose of determining alterations in severity. Trantas dots and papillary proliferation with velvety appearance that are found in severe AC, AKC and VKC, are included in the 10-points-grade group. Furthermore, observations that were common and nonspecific for ACD are included in the 1-point-grade group. The 5 determinants of each grade chosen in this manner are believed to be more useful observations in determining the severity of ACD in each patient.

In our study, we measured the scores in patients with VKC, AKC, and AC. As a result, the range of clinical severity scores in each clinical type of ACD was clarified and could be classified as severe, moderate or mild. These classifications will help in selecting the most suitable medical therapy for patients with ACD.

The 5-5-5 exacerbation grading scale is a useful clinical tool for grading the severity of each type of ACD, and may also be applied when evaluating the effects of medical treatment.

REFERENCES

1. Friedlaender MH. Conjunctivitis of allergic origin: clinical presentation and differential diagnosis. *Surv Ophthalmol* 1993;**38**:105-14.
2. Nivenius E, Montan PG, Chryssanthou E, Jung K, van Hage-Hamsten M, van der Ploeg I. No apparent association between periocular and ocular microcolonization and the degree of inflammation in patients with atopic keratoconjunctivitis. *Clin Exp Allergy* 2004;**34**:725-30.
3. Uchio E, Kimura R, Migita H, Kozawa M, Kadonosono K. Demographic aspects of allergic ocular diseases and evaluation of new criteria for clinical assessment of ocular allergy. *Graefes Arch Clin Exp Ophthalmol* 2008;**246**:291-6.
4. Montan PG, van Hage-Hamsten M. Eosinophil cationic protein in tears in allergic conjunctivitis. *Br J Ophthalmol* 1996;**80**:556-60.

5. Calonge M, Herreras JM. Clinical grading of atopic keratoconjunctivitis. *Curr Opin Allergy Clin Immunol* 2007;**7**: 442-5.
6. Bonini S, Sacchetti M, Mantelli F, Lambiase A. Clinical grading of vernal keratoconjunctivitis. *Curr Opin Allergy Clin Immunol* 2007;**7**:436-41.
7. Leonardi A, Borghesan F, Avarello A, Plebani M, Secchi AG. Effect of lodoxamide and disodium cromoglycate on tear eosinophil cationic protein in vernal keratoconjunctivitis. *Br J Ophthalmol* 1997;**81**:23-6.
8. Bielory L. Allergic and immunologic disorders of the eye. Part II: Ocular allergy. *J Allergy Clin Immunol* 2000;**106**: 1019-32.
9. Hogan MJ. Atopic keratoconjunctivitis. *Trans Am Ophthalmol Soc* 1952;**50**:265-81.
10. Foster CS, Calonge M. Atopic keratoconjunctivitis. *Ophthalmology* 1990;**97**:992-1000.
11. Ohta T. Phenomenological aspects of consciousness—its disturbance in acute and chronic stage. *Acta Neurochir Suppl* 2005;**93**:191-3.
12. Bonini S, Bonini S, Lambiase A *et al*. Vernal Keratoconjunctivitis revisited. A case series of 195 patients with long-term followup. *Ophthalmology* 2000;**107**:1157-63.
13. Leonardi A, Motterle L, Bortolotti M. Allergy and the eye. *Clin Exp Immunol* 2008;**153**(Suppl 1):17-21.
14. Hogan MJ. Atopic keratoconjunctivitis. *Trans Am Ophthalmol Soc* 1952;**50**:265-81.
15. Foster CS, Calonge M. Atopic keratoconjunctivitis. *Ophthalmology* 1990;**97**:992-1000.