Experimental and Molecular Pathology 105 (2018) 322–327

Contents lists available at ScienceDirect

Experimental and Molecular Pathology

journal homepage: www.elsevier.com/locate/yexmp

Basidiomycetes-X, an edible mushroom, alleviates the development of atopic dermatitis in NC/Nga mouse model

Kenichi Watanabe[a,b,**,1], Vengadeshprabhu Karuppagounder[b,c,1], Remya Sreedhar[b], Geetha Kandasamy[d], Meilei Harima[b,e], Ravichandiran Velayutham[f], Somasundaram Arumugam[b,f,*]

[a] Department of Laboratory Medicine and Clinical Epidemiology for Prevention of Noncommunicable Diseases, Niigata University Graduate School of Medical and Dental Sciences, 757, Ichibancho, Asahimachidori, Chuo ku, Niigata City 951-8510, Japan
[b] Department of Clinical Pharmacology, Faculty of Pharmaceutical Sciences, Niigata University of Pharmacy and Applied Life Sciences, 265-1, Higashijima, Akiha ku, Niigata 956-8603, Japan
[c] Department of Orthopedics and Rehabilitation, Penn State College of Medicine, 500 University Drive, Hershey, PA 17033, USA
[d] Department of Clinical Pharmacy, College of Pharmacy, King Khalid University, Abha, Saudi Arabia
[e] Faculty of Allied Health Sciences, Niigata University of Rehabilitation, 2-16, Kaminoyama, Murakami, Niigata 958-0053, Japan
[f] National Institute of Pharmaceutical Education and Research, Chuilal Bhawan, 168 Manicktala Main Road, Kolkata 700054, West Bengal, India

ARTICLE INFO

Keywords:
Basidiomycetes-X
Tumor necrosis factor
Cytokine
Atopic dermatitis
Inflammation
Interferon

ABSTRACT

Basidiomycetes-X (BDM-X) is a novel edible mushroom recently identified as a new fungi species and is effective against oxidative stress and anti-inflammation associated with immune response. However the effect of BDM-X on atopic dermatitis (AD) has not been elucidated. In this study, we have investigated the effect of BDM-X on AD skin lesions in NC/Nga mouse model. AD-like lesion was induced by the application of house dust mite extract (DfE) to the dorsal skin of NC/Nga mouse. After AD induction, BDM-X was administered once daily for 2 weeks. We have analyzed the effects of BDM-X on dermatitis severity, histopathological changes and changes in inflammatory and proinflammatory proteins expressions in DfE induced AD mice skin. Treatment with BDM-X attenuated the development of AD-like clinical symptoms and effectively inhibited hyperkeratosis, parakeratosis, acanthosis and mast cells in AD mice skin. Furthermore, BDM-X treatment inhibited DfE induced tumor necrosis factor (TNF)α, high mobility group protein (HMG)B1, nuclear factor kappa (NFκ)B and inflammatory cytokines. These results indicate that BDM-X inhibits AD through modulating Th1 and Th2 responses and diminishing the mast cells infiltration in the skin lesions in NC/Nga mice.

1. Introduction

Atopic dermatitis (AD) is a chronic, relapsing and inflammatory skin disease in humans, caused by a complex interrelationship among genetic, psychologic, pharmacologic, environmental, skin barrier dysfunction and immunological factors (Udompataikul and Limpa-O-Vart, 2012). Disease onset typically occurs by 6 months of age in 45%, by 1 year of age in 60% and 5 years of age in 85% of affected infants and children. Upto 70% of children have a spontaneous remission before their adolescence. The skin is an important interface between the host and its environment. Moreover, a leaky skin epithelial barrier combined with abnormal immune responsiveness likely contributes to the pathophysiology of AD (Kuo et al., 2013). The pathogenesis of AD is a complex mechanism. Environmental house dust mite allergen such as *Dermatophagoides farinae* (DfE) causes AD in human (Matsuoka et al., 2003).

Several animal models of AD have been developed; the NC/Nga mouse AD model is clinically and histologically very similar to human AD (Matsuoka et al., 2003). Along with the AD-like skin changes, NC/Nga mice exhibit Th cells differentiation toward Th2 cells, accumulation of inflammatory and mast cells in the skin lesion. Furthermore, NC/Nga mice are linked to the increased IgE production as well as

* Correspondence to: S. Arumugam, Department of Pharmacology and Toxicology, National Institute of Pharmaceutical Education and Research, Chuilal Bhawan, 168 Manicktala Main Road, Kolkata 700054, West Bengal, India.
** Correspondence to: K. Watanabe, Department of Laboratory Medicine and Clinical Epidemiology for Prevention of Noncommunicable Diseases, 757, Ichibancho, Asahimachidori, Chuo ku, Niigata City 951-8510, Japan.
E-mail addresses: wataken@med.niigata-u.ac.jp (K. Watanabe), somasundaram143@gmail.com, somasundaram@med.niigata-u.ac.jp (S. Arumugam).
[1] Authors contributed equally.

https://doi.org/10.1016/j.yexmp.2018.10.005
Received 13 July 2018; Received in revised form 4 October 2018; Accepted 8 October 2018
Available online 09 October 2018
0014-4800/ © 2018 Elsevier Inc. All rights reserved.

increased Th2 responses (Choi et al., 2013).

Topical or systemic corticosteroids are first line treatment for AD. However, long-term use of corticosteroids causes severe adverse effects. Recently, medicinal mushrooms have emerged as therapeutic alternative for the treatment of AD. Moreover, some medicinal mushrooms have been used in Japan as traditional Kampo medicines. Basidiomycetes-X (BDM-X) is an edible mushroom cultivated by Truffle Japan Co., Ltd. (Niigata, Japan). According to genomic analysis of 18S and 5.8S ribosomal RNA, this fungus was identified as a novel new species and was formally registered as BDM-X to the database in the international patent organism depositing of industrial technology institute of Japan (IPOD) (FERM BP-10011). Several in vitro anti-oxidant assay and experimental studies suggest that BDM-X has strong anti-oxidant activity. In spite of these reports, its effects on clinical sign and symptoms of AD were not explored. We hypothesized that BDM-X ameliorates skin inflammation and attenuates clinical signs and symptoms of AD in DfE induced NC/Nga mouse model.

2. Materials and methods

2.1. Materials

Biostir AD, a cream containing DfE extract (DfE cream), was purchased from Biostir, Inc. (Kobe Japan). Phosphatase arrest III was purchased from G-Biosciences, St.Louis, MO, USA. Trizma base, sodium choloride, sodium fluoride, sodium orthovanadate, 2-mercaptoethanol, bovine serum albumin (BSA) and tween 20 were purchased from Wako pure chemical Industries Ltd., Osaka, Japan. All the reagents and chemicals were of analytical grade and purchased from Sigma or Wako, Tokyo, Japan, until mentioned otherwise. BDM-X (hot water extract) was a gift from Mycology Techno Co., Ltd., Niigata, Japan.

2.2. Experimental design

Specific pathogen free female 6 weeks old NC/Nga mice were obtained from Charles River, Yokohama, Japan. The animals were maintained in controlled room (temperature 23 ± 2 °C, humidity 55 ± 15%, 12 h light cycle). After 1 week, the mice were randomly divided into 3 groups, untreated group- received vehicle (distilled water) (Normal, n = 5); DfE cream treated mice (100 mg/mouse) were divided into two groups and each received vehicle (distilled water) (AD, n = 5) or BDM-X (530 mg/kg/day, per oral) (AD + BDM-X, n = 5) and were allowed free access to drinking water and standard laboratory diet. The animal experiments were performed in accordance with the national guidelines and approved by the animal care committee of Niigata University of Pharmacy and Applied Life Sciences, Niigata, Japan.

2.3. Induction of AD

AD-like skin lesions were induced in NC/Nga mice using DfE cream, as we described previously (Karuppagounder et al., 2015a). Briefly, 150 μL of 4% sodium dodecyl sulfate (SDS) was applied to the shaved dorsal skin and ears. After 3 h, 100 mg of DfE cream was applied topically. This procedure was carried out twice weekly for 2 weeks. BDM-X treatment was started after AD induction (2 weeks from the start of the experiment) and continued for 2 weeks.

2.4. Evaluation of dermatitis severity

The dermatitis severity was measured every week according to the eczema area and severity index scoring using the following procedure: 0, no; 1, mild; 2, moderate; 3, severe symptoms were given based on following manifestation, erythema/hemorrhage, edema, excoriation/erosion, dryness/scaling (Hanifin et al., 2001; Karuppagounder et al., 2014).

2.5. Histopathological studies

By the end of the study period, mice were sacrificed, and their skin tissues were harvested for semi-quantitative immunoblotting studies. The half of the skin was immediately snap frozen in liquid nitrogen for subsequent protein extraction assays. The remaining excised skin were cut into about 2 mm thick transverse slices and fixed in 10% formalin. Sections of 3–5 μm thicknesses were stained with hematoxylin and eosin (H&E) or toluidine blue for detecting infiltrated mast cells, respectively. A histomorphological evaluation of all the skin sections was carried out in a blinded fashion (Karuppagounder et al., 2014; Watanabe et al., 2015). Purple colored mast cells were counted using 20× objective.

2.6. Protein analysis by Western blotting

Western blotting was performed as described previously (Arumugam et al., 2012). The total protein concentration in samples was measured by the bicinchoninic acid method. Briefly, the protein samples were subjected to SDS polyacrylamide gel electrophoresis and then transferred to nitrocellulose membranes. Membranes were blocked with 5% bovine serum albumin (BSA) in tris-buffered saline with 0.1% tween (TBST) and incubated using the following antibodies: Antibodies against high mobility group protein (HMG)B1, receptor for advanced glycation endproducts (RAGE), phospho extracellular signal regulated kinase (ERK), total ERK, phospho (p)-NFκB, total NFκB, interferon (IFN)γ, tumor necrosis factor (TNF)α, TNF receptor (TNFR)1, cyclooxygenase (COX)2 and galectin 3. All the antibodies were purchased from Santa Cruz Biotechnology, Inc. (Santa Cruz, CA, USA) or Cell Signaling Technology, Inc. (Danvers, MA, USA) and used at a dilution of 1:1000. After washing for three times with TBST, the membranes were incubated with appropriate horseradish-peroxidase (HRP) conjugated secondary antibodies for 1 h at room temperature. Further, the membranes were washed three times with TBST and then developed using a chemiluminescence detection system (Amersham Biosciences, Buckinghamshire, UK). The blots were scanned, and the signals were quantified with densitometric analysis using Image Studio Digits ver.4 (Superior Street, Lincoln, Nebraska, USA). Antibodies to glyceraldehyde-3-phosphate dehydrogenase (GAPDH) served as control protein.

2.7. Statistical analysis

Data are presented as mean ± standard error of mean (SEM) and were analyzed using one-way analysis of variance (ANOVA) followed by Tukey multiple comparison test or two-tailed *t*-test when appropriate. A value of $p^{<}0.05$ was considered statistically significant. For statistical analysis, GraphPad Prism 5 software (San Diego, CA) was used.

3. Results

3.1. BDM-X improves clinical symptoms of AD in NC/Nga mice

The AD-like skin lesions induced by cutaneous application of DfE cream resulted in immediate itching, erythema, and hemorrhage on the ear and back that was followed by edema, superficial erosion, deep excoriation, scaling and dryness of the skin. In AD and AD + BDM-X groups of NC/Nga mice, clinical signs and symptoms of dermatitis significantly developed during the 2 weeks of DfE cream application. During the course of treatment, the dermatitis score of the AD + BDM-X group decreased rapidly and became significantly different from that of the group AD mice. These results clearly suggest the ameliorative potential of BDM-X on the pathogenesis of AD (Fig. 1).

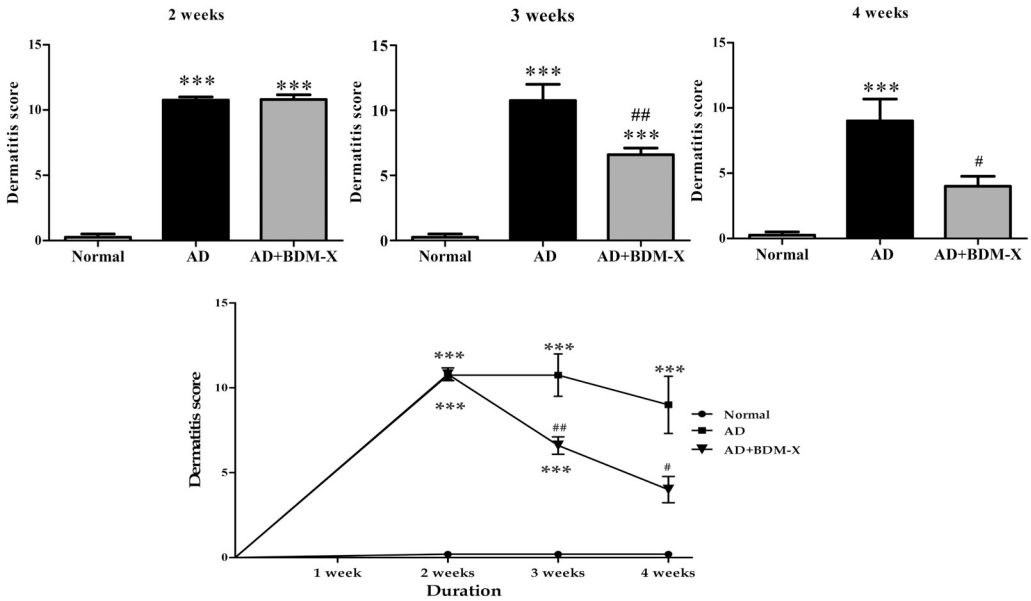

Fig. 1. Effect of *BDM-X* on time-dependent dermatitis score of NC/Nga mice with AD-like skin lesions. Each bar represents mean ± SEM. Normal, age-matched normal NC/Nga mice; AD, AD induced NC/Nga mice; AD + BDM-X, AD induced mice administered with *BDM-X* (530 mg/kg/day, per oral) (From 2 week to 4 week). $^{***}p < 0.001$ vs Normal; $^{\#}p < 0.05$ and $^{\#\#\#}p < 0.01$ vs AD.

3.2. BDM-X treatment improves histopathological changes

H&E and toluidine blue staining of the dorsal skin sections to reveal the effect of BDM-X on mast cell degranulation during AD. The results revealed hyperkeratosis, parakeratosis, acanthosis with varying degrees of spongiosis in the epidermis and infiltrated mast cells into the dermis of AD mice. In contrast, BDM-X treated mice showed the reductions in these dermal changes compared with AD mice (Fig. 2A, B and B1).

3.3. BDM-X downregulates HMGB1 and p-NFκB expression in AD mice

We examined the effect of BDM-X on HMGB1 expression. We have found that the protein expressions of HMGB1 and p-NFκB were significantly up-regulated in DfE induced AD mice skin when compared

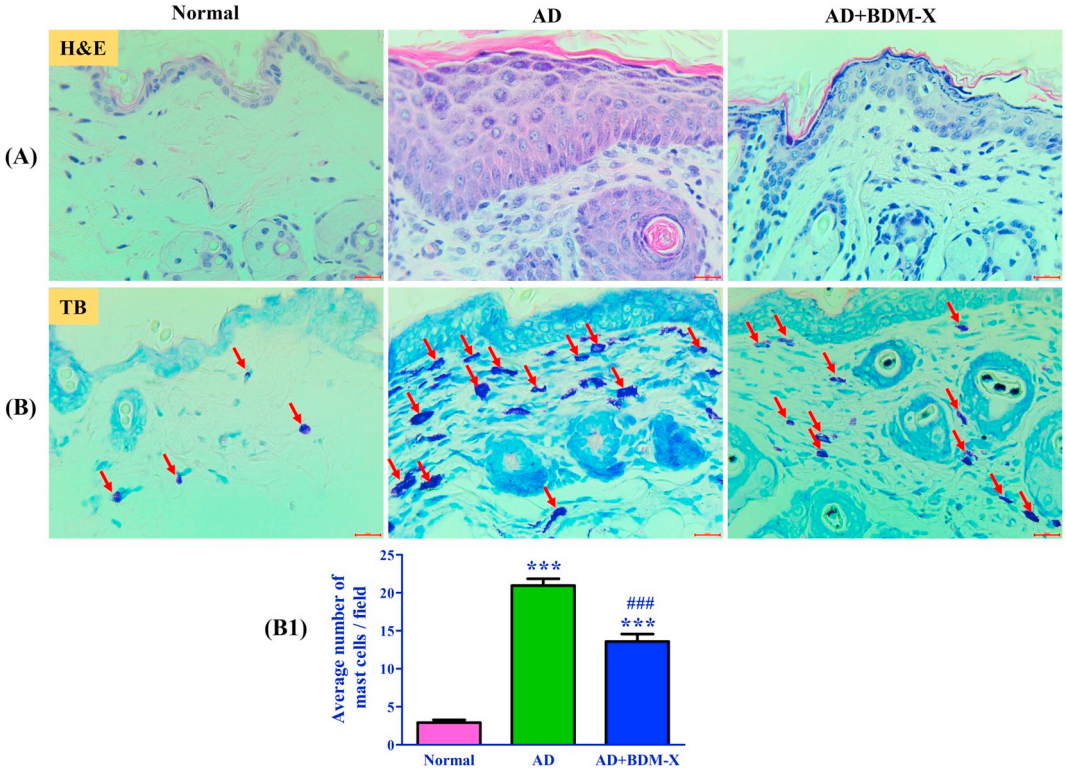

Fig. 2. (A) H&E staining of the cross-sectional tissue slices of skin showing hyperkeratosis, parakeratosis, acanthosis and spongiosis. (A1) Quantification of epidermal thickness. (B) Skin levels of mast cells (red arrow) by toluidine blue staining. (B1) Quantification of mast cells per field. Scale bar = 10 μm. Each bar represents mean ± SEM. Normal, age-matched normal NC/Nga mice; AD, AD induced NC/Nga mice; AD + BDM-X, AD induced mice administered with *BDM-X*. $^{***}p < 0.001$ vs Normal; $^{\#\#\#}p < 0.001$ vs AD. (For interpretation of the references to colour in this figure legend, the reader is referred to the web version of this article.)

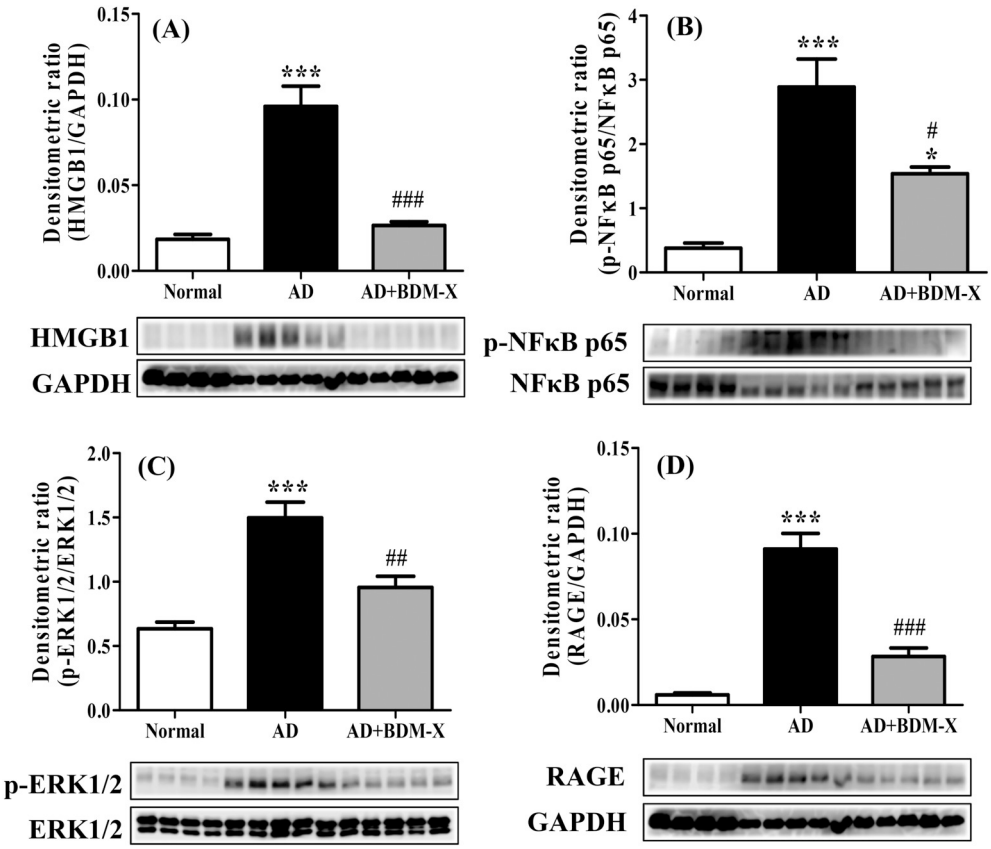

Fig. 3. Effects *BDM-X* on HMGB1, NFκB, ERK1/2 and RAGE protein expressions. Western blots show specific bands for (A) expression of HMGB1, expressed as a ratio relative to that of GAPDH, (B) expression of p-NFκB, expressed as a ratio relative to that of NFκB, (C) expression of p-ERK1/2, expressed as a ratio relative to that of ERK1/2 and (D) expression of RAGE, expressed as a ratio relative to that of GAPDH. Each bar represents mean ± SEM. Normal, age-matched normal NC/Nga mice; AD, AD induced NC/Nga mice; AD + BDM-X, AD induced mice administered with *BDM-X*. $^{*}p < 0.05$ and $^{***}p < 0.001$ vs Normal; $^{\#}p < 0.05$, $^{\#\#}p < 0.01$ and $^{\#\#\#}p < 0.001$ vs AD.

with that of normal group mice, whereas treatment with BDM-X significantly down-regulated their expression in AD induced mice vs AD group mice (Fig. 3A and B).

3.4. BDM-X treatment reduces p-ERK and RAGE expression in AD mice

The protein expression levels of p-ERK and RAGE were significantly increased in the AD mice skin vs normal mice skin, whereas treatment with BDM-X has significantly reduced their expression in AD + BDM-X group mice skin vs AD group mice skin (Fig. 3C and D).

3.5. Effects of BDM-X on inflammatory markers expression in DfE induced AD mice

Our Western blot analysis indicated that the IFNγ, TNFα, TNFR1, COX2 and galectin 3 protein expressions were significantly up-regulated in vehicle treated AD mice skin compared to that of normal group mice (Fig. 4A–D). BDX-M treatment has significantly suppressed all these inflammatory marker proteins expression except galectin 3, which showed reduced expression, but not significant when compared to that of AD group mice (Fig. 4E).

4. Discussion

BDM-X is an edible mushroom identified as a new fungi species and registered to the database of the NPO organization for International Patent Organism Depositing (IPOD) in the Industrial Technology Institute of Japan (Watanabe et al., 2008). It has showed potent antioxidant activity when compared with Agaricus, a commercially available medicinal mushroom. It has also been reported to strongly inhibit the lipopolysaccharide induced oxidative tissue damage (Watanabe et al., 2008). Mushrooms are identified as effective agents against AD and several studies have reported the beneficial effects of various mushrooms against skin diseases (Choi et al., 2016; Jesenak et al., 2016; Park et al., 2015; Suh et al., 2017). In addition, no adverse events or severe side effects of BDM-X has been reported (Mizuno and Nishitani, 2013). Based on these previous reports and upon the strong antioxidant activity of BDM-X, we have performed this study to evaluate the pharmacological effects of BDM-X on AD skin lesions in NC/Nga mouse model.

AD is an inflammatory skin disease, which has a complex pathogenesis, and it encompasses susceptibility genes, immunologic responses, environmental triggers, and compromised skin barrier function (Leung and Soter, 2001). AD-like skin lesions in NC/Nga mice are like those of human AD, showing various grades of signs and symptoms such as hemorrhage and erythema, followed by edema, superficial erosion, deep excoriation and skin dryness (Ngatu et al., 2012). In our study we showed that repeated topical application of DfE resulted in increased clinical symptoms of AD mice, whereas treatment with BDM-X significantly improved the DfE induced AD clinical symptoms in NC/Nga mice. Most patients with AD are pathologically characterized by hypertrophy and infiltrated inflammatory cells such as T lymphocytes, monocytes/macrophages, eosinophils, neutrophils and mast cells (Karki et al., 2012). In this study, hypertrophy and infiltrated inflammatory cells in the dermis were observed in the AD mice. These changes were associated with inflammation in skin tissues. Oral administration of BDM-X suppressed DfE-induced skin hypertrophy, morphological changes and infiltrated inflammatory cells, suggesting that treatment with BDM-X is effective in ameliorating the clinical symptoms and histological changes in AD mice.

Moreover, inflammatory responses such as hypersensitivity and allergic reactions are mediated by mast cells and the allergen cross-linking of surface IgE dependent mast cells activation stimulates the degranulation and release of histamine, prostaglandins and cytokines (Kim et al., 2012). Histological examinations revealed that BDM-X possesses a significant inhibitory effect on mast cell degranulation

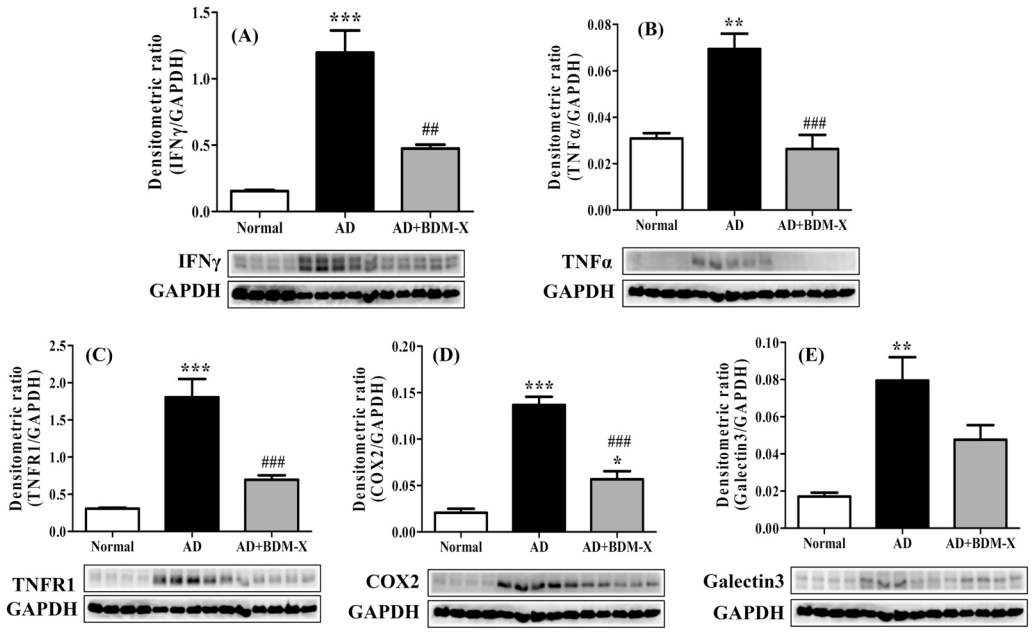

Fig. 4. Effects of *BDM-X* on inflammatory markers expression. (A-F) Densitometric data of protein analysis. The mean density values of IFNγ, TNFα, TNFR1, COX2 and galectin 3 (expressed as a ratio relative to that of GAPDH) with their representative Western blots showing specific bands. GAPDH was used as an internal control. Each bar represents mean ± SEM. Normal, age-matched normal NC/Nga mice; AD, AD induced NC/Nga mice; AD + BDM-X, AD induced mice administered with *BDM-X*. $^{*}p < 0.05$, $^{**}p < 0.01$ and $^{***}p < 0.001$ vs Normal; $^{\#\#}p < 0.01$ and $^{\#\#\#}p < 0.001$ vs AD.

possibly due to the inhibition of IgE hyperproduction. Interaction between IgE and allergen triggers the production of pro-inflammatory factors and cytokines such as TNFα and IFNγ. The Th2 cytokine IL-6 activates IgE production and released from B cells and binds to mast cells. On the other side, Th1 cytokines such as IL-2 and IFNγ play important roles in cell mediated immunity and skin inflammation (Kim et al., 2012). Similarly, galectin 3, a beta galactoside binding animal lectin expressed in epithelial as well as immune cells, is critical for the development of T-helper cells mediated inflammatory immune response (Larsen et al., 2011; Saegusa et al., 2009). Similarly, COX2 is reported to be a mediator, which is crucial for the development of AD (Ahn et al., 2016; Karuppagounder et al., 2015b; Karuppagounder et al., 2014).

In the present study, we have identified that the AD induced increased protein levels of TNFα, TNFR1, IFNγ, COX2 and galectin 3 were inhibited by treatment with BDM-X. Given the importance of these pro-inflammatory cytokines in AD, our present data suggests that *BDM-X* suppressed pro-inflammatory factors and cytokine responses in inflammatory skin diseases such as AD. In addition pro-inflammatory mediators such as HMGB1, RAGE and NFκB mainly associated with skin inflammation and elevated HMGB1, RAGE and NFκB levels indicates hallmark of skin diseases (Karuppagounder et al., 2015b). Activation of RAGE by HMGB1 can induce reactive oxygen species (ROS) as well as other downstream signaling pathways involving ERK and NFκB (Karuppagounder et al., 2014). Similarly, MAPK signaling is activated in inflammatory skin diseases and inhibitors of this pathway reduce skin inflammation in various rodent models of human skin diseases (Ipaktchi et al., 2006). Recently, we reported that HMGB1 and NFκB activate pro-inflammatory factors and cytokines in AD NC/Nga mouse model (Karuppagounder et al., 2015b). In the present study, we have found an effective suppression in their levels, after BDM-X treatment in AD mice.

In conclusion, we demonstrate that the oral administration of *BDM-X* attenuated the development of AD like skin lesions and ameliorates clinical sign and symptoms in NC/Nga mice induced by DfE. Furthermore, the BDM-X effectively suppressed infiltrated mast cells, IFNγ, as well as TNFα and pro-inflammatory factors. These results suggest that BDM-X could provide an effective alternative treatment for AD.

Conflict of interest

The authors declare that there are no conflicts of interest.

Acknowledgment

This research was supported by Ministry of Education, Culture, Sports, Science and Technology of Japan, and by a grant from the Promotion and Mutual Aid Corporation for Private Schools, Japan (23602012 and 26460239) respectively.

References

Ahn, S., et al., 2016. Ginsenoside Rg5:Rk1 attenuates TNF-alpha/IFN-gamma-induced production of thymus- and activation-regulated chemokine (TARC/CCL17) and LPS-induced NO production via downregulation of NF-kappaB/p38 MAPK/STAT1 signaling in human keratinocytes and macrophages. In Vitro Cell. Dev. Biol. Anim. 52, 287–295.

Arumugam, S., et al., 2012. Quercetin offers cardioprotection against progression of experimental autoimmune myocarditis by suppression of oxidative and endoplasmic reticulum stress via endothelin-1/MAPK signalling. Free Radic. Res. 46, 154–163.

Choi, J.H., et al., 2013. Topical application of Pleurotus eryngii extracts inhibits 2,4-dinitrochlorobenzene-induced atopic dermatitis in NC/Nga mice by the regulation of Th1/Th2 balance. Food Chem. Toxicol. 53, 38–45.

Choi, E.J., et al., 2016. Chemical composition and inhibitory effect of lentinula edodes ethanolic extract on experimentally induced atopic dermatitis in vitro and in vivo. Molecules 21.

Hanifin, J.M., et al., 2001. The eczema area and severity index (EASI): assessment of reliability in atopic dermatitis. EASI Evaluator Group. Exp. Dermatol. 10, 11–18.

Ipaktchi, K., et al., 2006. Topical p38MAPK inhibition reduces dermal inflammation and epithelial apoptosis in burn wounds. Shock 26, 201–209.

Jesenak, M., et al., 2016. Beta-Glucan-based cream (containing pleuran isolated from pleurotus ostreatus) in supportive treatment of mild-to-moderate atopic dermatitis. J. Dermatol. Treat. 27, 351–354.

Karki, R., et al., 2012. Inhibitory effect of nelumbo nucifera (Gaertn.) on the development of atopic dermatitis-like skin lesions in NC/Nga mice. Evid. Based Complement. Alternat. Med. 2012, 153568.

Karuppagounder, V., et al., 2014. Resveratrol attenuates HMGB1 signaling and inflammation in house dust mite-induced atopic dermatitis in mice. Int. Immunopharmacol. 23, 617–623.

Karuppagounder, V., et al., 2015a. Tannic acid modulates NFkappaB signaling pathway and skin inflammation in NC/Nga mice through PPARgamma expression. Cytokine 76, 206–213.

Karuppagounder, V., et al., 2015b. Modulation of HMGB1 translocation and RAGE/NFkappaB cascade by quercetin treatment mitigates atopic dermatitis in NC/Nga

transgenic mice. Exp. Dermatol. 24, 418–423.
Kim, S.R., et al., 2012. Topical application of herbal mixture extract inhibits ovalbumin- or 2,4-dinitrochlorobenzene-induced atopic dermatitis. Evid. Based Complement. Alternat. Med. 2012, 545497.
Kuo, I.H., et al., 2013. The cutaneous innate immune response in patients with atopic dermatitis. J. Allergy Clin. Immunol. 131, 266–278.
Larsen, L., et al., 2011. Galectin-3 and the skin. J. Dermatol. Sci. 64, 85–91.
Leung, D.Y., Soter, N.A., 2001. Cellular and immunologic mechanisms in atopic dermatitis. J. Am. Acad. Dermatol. 44, S1–S12.
Matsuoka, H., et al., 2003. A mouse model of the atopic eczema/dermatitis syndrome by repeated application of a crude extract of house-dust mite Dermatophagoides farinae. Allergy 58, 139–145.
Mizuno, M., Nishitani, Y., 2013. Immunomodulating compounds in Basidiomycetes. J. Clin. Biochem. Nutr. 52, 202–207.
Ngatu, N.R., et al., 2012. Anti-allergic effects of Vernonia amygdalina leaf extracts in hapten-induced atopic dermatitis-like disease in mice. Allergol. Int. 61, 597–607.
Park, H.S., et al., 2015. Functional polysaccharides from Grifola frondosa aqueous extract inhibit atopic dermatitis-like skin lesions in NC/Nga mice. Biosci. Biotechnol. Biochem. 79, 147–154.
Saegusa, J., et al., 2009. Galectin-3 is critical for the development of the allergic inflammatory response in a mouse model of atopic dermatitis. Am. J. Pathol. 174, 922–931.
Suh, W., et al., 2017. Chemical constituents identified from fruit body of Cordyceps bassiana and their anti-inflammatory activity. Biomol. Ther. (Seoul) 25, 165–170.
Udompataikul, M., Limpa-O-Vart, D., 2012. Comparative trial of 5% dexpanthenol in water-in-oil formulation with 1% hydrocortisone ointment in the treatment of childhood atopic dermatitis: a pilot study. J. Drugs Dermatol. 11, 366–374.
Watanabe, T., et al., 2008. In vitro and in vivo anti-oxidant activity of hot water extract of basidiomycetes-X, newly identified edible fungus. Biol. Pharm. Bull. 31, 111–117.
Watanabe, K., Karuppagounder, V., Arumugam, S., Thandavarayan, R.A., Pitchaimani, V., Sreedhar, R., Afrin, R., Harima, M., Suzuki, H., Suzuki, K., Nakamura, T., Nomoto, M., Miyashita, S., Fukumoto, K., Ueno, K., 2015 May. Pruni cortex ameliorates skin inflammation possibly through HMGB1-NFκB pathway in house dust mite induced atopic dermatitis NC/Nga transgenic mice. J. Clin. Biochem. Nutr. 56 (3), 186–194.