Dermatol Ther (Heidelb)
https://doi.org/10.1007/s13555-021-00586-w

ORIGINAL RESEARCH

Practical Management of Patients with Atopic Dermatitis on Dupilumab

Kim A. Papp · Chih-ho Hong · M. Perla Lansang · Irina Turchin · David N. Adam · Jennifer R. Beecker · Robert Bissonnette · Melinda J. Gooderham · Carolyn Jack · Marissa Joseph · Charles W. Lynde · Neil H. Shear

Received: June 2, 2021 / Accepted: July 25, 2021
© The Author(s) 2021

ABSTRACT

Introduction: Dupilumab is approved to treat moderate-to-severe atopic dermatitis (AD) in several countries in patients as young as 6 years of age. Since its approval, practical issues related to the use of dupilumab for AD have arisen, with particular interest in transitioning from current therapies and managing medication overlap, considerations for special populations of patients with AD, and management of potential adverse events.

Methods: This article aims to review the literature addressing several practical management issues related to dupilumab use for AD and to provide a framework for clinical decision-making in these circumstances and sub-populations. Each statement was reviewed, revised and voted on by authors to provide their level of agreement and degree of uncertainty for each statement.

Supplementary Information The online version contains supplementary material available at https://doi.org/10.1007/s13555-021-00586-w.

K. A. Papp · C. Hong · I. Turchin · D. N. Adam · J. R. Beecker · M. J. Gooderham · C. W. Lynde
Probity Medical Research, Waterloo, ON, Canada

K. A. Papp (✉)
K. Papp Clinical Research, 135 Union St E, Waterloo, ON N2J 1C4, Canada
e-mail: kapapp@probitymedical.com

C. Hong
Dr. Chih-ho Hong Medical, Inc, Surrey, BC, Canada

M. P. Lansang · N. H. Shear
Division of Dermatology, Sunnybrook Health Sciences Centre, Toronto, ON, Canada

M. P. Lansang · D. N. Adam · M. Joseph · C. W. Lynde
Division of Dermatology, Temerty Faculty of Medicine, University of Toronto, Toronto, ON, Canada

M. P. Lansang
Section of Dermatology, Division of Paediatric Medicine, The Hospital for Sick Children, Toronto, ON, Canada

I. Turchin
Brunswick Dermatology Centre, Fredericton, NB, Canada

D. N. Adam
CCA Medical Research, Ajax, ON, Canada

J. R. Beecker
Division of Dermatology, The Ottawa Hospital, Ottawa, ON, Canada

J. R. Beecker
Division of Dermatology, University of Ottawa, Ottawa, ON, Canada

R. Bissonnette
Innovaderm Research, Montreal, QC, Canada

Published online: 11 September 2021

Results: An agreement level > 80% was achieved for all of the statements.
Conclusion: The expert panel provides statements considering the practical management of patients with AD taking dupilumab to inform clinical decision-making in specific but frequently encountered clinical situations.

Keywords: Atopic dermatitis; Dupilumab; Practical management

Key summary points
Dupilumab has been approved in several countries for AD in patients as young as 6 years
Practical management issues around the use of dupilumab for AD remain, including considerations for treatment initiation and maintenance, special populations of interest, and management of potential adverse events
A panel of Canadian dermatologists reviews and provides practical recommendations for the use of dupilumab based on available literature and clinical expertise

M. J. Gooderham
SKiN Centre for Dermatology, Peterborough, ON, Canada

C. Jack
Division of Dermatology, McGill University, Montreal, QC, Canada

C. Jack
Research Institute of the McGill University Health Centre, Montreal, QC, Canada

M. Joseph
Division of Dermatology, Women's College Hospital, Toronto, ON, Canada

M. Joseph
Department of Pediatrics, Faculty of Medicine, University of Toronto, Toronto, ON, Canada

C. W. Lynde
Lynderm Research, Markham, ON, Canada

INTRODUCTION

Dupilumab is the first biologic approved to treat atopic dermatitis (AD) and is approved for use in patients as young as 6 years in some countries. Given the diverse populations being treated for AD with dupilumab in the real world compared to more restricted clinical trial populations, several practical issues remain of interest, including considerations for treatment initiation and maintenance, special populations of patients with AD not included in trials, and management of adverse events such as conjunctivitis and facial rash. The aim of this work is to provide a concise review of the available evidence and provide expert opinions from a panel of dermatologists specializing in AD relative to the practical use of dupilumab for this condition.

METHODS

The expert dermatology panel was comprised of 12 board-certified dermatologists with up to 40 years of clinical and research expertise in AD from across Canada. This panel discussed practical management issues and special populations relative to dupilumab use in AD, agreed upon topics for review and practical consideration, conducted an unstructured review of recent literature, identified points of uncertainty, and provided practical recommendations for dupilumab use based on both the available literature and clinical expertise. As no data were collected for the purpose of this work, institutional ethics approvals were not required.

To quantify panel concordance with each statement, support was quantified using an approach to solicit expert estimation of confidence and degree of uncertainty [1, 2]. Briefly, all authors reviewed each summary draft statements prior to voting. Responses were collated and revisions applied, followed by one round of anonymous voting indicating level of agreement for each statement (0–100%) and degree of uncertainty for each statement. Panelists evaluated each statement based on a combination of assessment of the available literature as

well as clinical opinion. Abstaining was not permitted.

Individual responses were represented as beta distributions in the supplementary appendix along with consolidated estimates and Bayesian distributions. Bayesian estimates of support and 95% credibility intervals were captured within the text and in Table 1.

Limitations of the current study include paucity of robust peer-reviewed data and/or controlled studies relative to several of the topics addressed here, subjective nature of polling and validation of level of agreement tools used in this study, and potential for selection bias by reviewers. Accordingly, statements were drafted and evaluated to reflect expert clinical opinion in consideration of the available published literature.

Section 1: Treatment Initiation and Maintenance

Dosing for adults and pediatric patients 60 kg consists of 600 mg loading dose (LD) followed by 300 mg every other week (q2w) for AD [3]. Pediatric dosing for patients 60 kg is weight-based, consisting of either 600 mg LD followed by 300 mg every 4 weeks (q4w) for patients 15 to < 30 kg, or 400 mg LD followed by 200 mg q2w for patients 30 to < 60 kg in Canada and the US.

Dupilumab has been studied in randomized controlled trials as monotherapy and with concomitant topical corticosteroids (TCS); however, no formal studies have assessed dupilumab in combination with traditional systemic agents currently used to manage AD, including methotrexate (MTX), cyclosporine (CsA), or systemic corticosteroids (SCS). Importantly, in AD clinical trials multiple dosing arms were studied including a weekly (qw) dosing arm in adult patients in both Phase 3 trials and open-label extension [4–6].

Since its approval for AD, practical issues related to dupilumab initiation and ongoing maintenance remain, including transition guidance from traditional systemic agents, how to address AD flares requiring additional therapies, and management of partial or non-durable response.

1.1 Transitioning from conventional systemic agents to dupilumab

Statement 1.1.1 Concurrent treatment with traditional systemic therapy and dupilumab does not alter either drug's intrinsic risk profile. *Bayesian estimate of support (95% credibility interval): 97.8% (97.1–98.2%).*

Statement 1.1.2 When initiating dupilumab, concurrent systemic therapies may be tapered according to clinical response following dupilumab introduction, except in cases of adverse event or intolerance to traditional systemic agent necessitating withdrawal as abruptly as permitted relative to the safety issue. *98.6% (98.3–99.3%).*

Given the widespread use of traditional systemic agents to treat moderate-to-severe AD, many patients are likely to be on such an agent upon dupilumab initiation. Clinicians may prefer to wean patients off these agents slowly to reduce the likelihood of rebound. However, there is little published literature on the concomitant use of dupilumab with traditional systemic agents to guide this process.

Three relevant publications provide practical guidance for transitioning to dupilumab [7, 8]. Ludwig et al. [7] suggest regular dose tapering of the traditional agent by half over 8 and 12 weeks in pediatric and adult patients, respectively, to match anticipated timing of dupilumab efficacy as extrapolated from phase 3 studies [4, 7, 9, 10]. This approach does not consider patient variability with respect to timing and degree of efficacy of both dupilumab and the overlapping systemic agent. De Wijs et al. [8] suggest an 8-week overlap at full dose of the traditional agent, followed by dose tapering every 2–4 weeks, with earliest discontinuation of the traditional agent at 12–14 weeks. It also includes specific guidance for CsA to prevent rebound and guidance for those not achieving disease control during taper. Notably, the authors published favorable data in a small patient sample comparing their approach to a more abrupt discontinuation approach, showing better overall improvements

Table 1 Final statements and voting results

	Topic area	Statement	Voting Results *(Bayesian estimate [95% credibility interval])*
Section 1. TreatmentInitiation andMaintenance	1.1 Transitioning from conventional systemic therapy to dupilumab	1.1.1. Concurrent treatment with traditional systemic therapy and dupilumab does not alter either drug's intrinsic risk profile	97.8% (97.1–98.2%)
		1.1.2. When initiating dupilumab, concurrent systemic therapies may be tapered according to clinical response following dupilumab introduction, except in cases of adverse event or intolerance to traditional systemic agent necessitating withdrawal as abruptly as permitted relative to the safety issue	98.6% (98.3–99.3%)
	1.2 Evaluation and maintenance of patients with AD on dupilumab	1.2.1. For patients with adequate clinical response to dupilumab, continued use at the approved dose regimen will provide optimal long-term benefit, unless PROs fail to improve	96.2% (95.4–96.9%)
		1.2.2. For patients who do not achieve clinical improvement in AD by week 16–24, re-evaluation of diagnosis and alternative treatment may improve outcome	98.4% (97.4–98.8%)
	1.3 Management of partial or non-durable responders and concomitant systemic therapies	1.3.1. Increasing to weekly dosing may be considered in patients with partial or non-durable response to dupilumab	92.7% (90.0–94.9%)
		1.3.2. For patients not achieving adequate response on dupilumab, the addition of a traditional systemic agent may provide benefit	98.3% (97.3–98.7%)
Section 2. Special Populations	2.1 Pregnancy and breastfeeding	2.1.1. Dupilumab exposure during pregnancy poses little risk to mother and fetus	89.9% (86.3–92.9%)
		2.1.2. There is negligible absorption of dupilumab by infants who are breast fed by women taking dupilumab	97.0% (96.1–97.9%)
	2.2 Malignancy	2.2.1. There is no known additional risk in treating patients with prior malignancy and most active malignancies with dupilumab. Exclusion of CTCL prior to dupilumab initiation is an important safety consideration	92.7% (90.1–94.9%)
	2.3 Patients with pre-existing immune disorders	2.3.1. Dupilumab is unlikely to increase risks associated with pre-existing immune disorders including patients with HIV, patients with HIES, and organ transplant recipients. Drug-drug interactions are an important consideration when using traditional systemic agents in patients with pre-existing immune disorders	95.6% (94.2–97.0%)
	2.4 AD in older adults	2.4.1. Dupilumab has no additive safety concerns in older patients with AD and should be considered preferential to traditional systemic agents where contraindications, polypharmacy, and co-existing conditions complicate their use	95.2% (94.0–96.8%)
		2.4.2. A confirmed diagnosis of AD in older adults with atypical presentation, especially to rule out CTCL, is crucial before initiating any systemic therapy, including dupilumab	95.8% (94.9–96.9%)
	2.5 Patients with suspected or confirmed COVID-19 infection	2.5.1. Dupilumab may be continued in patients with COVID-19	91.7% (88.8–94.1%)
		2.5.2 Dupilumab is unlikely to impact COVID-19 vaccine effectiveness and is not associated with additional safety risk	92.8% (89.2–95.5%)

Table 1 continued

	Topic area	Statement	Voting Results *(Bayesian estimate [95% credibility interval])*
Section 3. Management of Potential Adverse Events	3.1 Conjunctivitis	3.1.1. Prophylactic measures such as artificial tears may reduce the incidence of conjunctivitis in patients with AD taking dupilumab	92.8% (92.0–94.1%)
	3.2 Recalcitrant head and neck dermatitis	3.2.1. Dupilumab-associated recalcitrant head and neck dermatitis may respond to short courses of low- to mid-potency topical steroids, topical calcineurin inhibitors and/or topical ketoconazole without dupilumab interruption	98.4% (98.2–99.1%)
		3.2.2. A short course of itraconazole or adjunct systemic therapy has provided benefit in some patients not responding to topical therapy	81.8% (75.8–87.0%)
	3.3. Psoriasis	3.3.1. Psoriasiform eruption has been reported in patients receiving dupilumab for AD. Most cases are localized and can be managed with topical anti-psoriatic therapy without dupilumab discontinuation	85.7% (80.3–90.2%)
	3.4. Arthrosis	3.4.1. Arthrosis and arthralgia are rare in patients receiving dupilumab, and their association with dupilumab therapy is uncertain	86.7% (82.9–90.0%)

Please see S1 in the electronic supplementary material for details on the Individual and composite agreement plots of panelists including calculation of mean and Bayesian estimates

AD atopic dermatitis, *CTCL* cutaneous T-cell lymphoma, *HIV* human immunodeficiency virus, *HIES* hyper-IgE syndrome, *COVID-19* coronavirus disease of 2019

in Eczema Area and Severity Index (EASI) using the above taper protocol.

The overall goal of therapy is to optimize disease control with minimal safety or tolerability issues. As such, topical and non-prescription therapies should always be optimized to maximize therapy success both prior to and during management with a systemic or biologic agent. Patients optimally controlled on a traditional systemic agent with no significant adverse events, tolerability issues, or long-term safety risks should be left on their current medication. Patients achieving suboptimal response to their traditional systemic agent despite medication optimization and adherence should be transitioned to dupilumab, with the aim of using the lowest effective dose of the traditional agent to achieve control. Importantly, patients on CsA may be considered for transition to dupilumab even in cases of optimal clinical response due to potential long-term nephrotoxicity.

We are aligned with an approach that maintains overlap of dupilumab with the traditional systemic agent until optimal clinical response is achieved as assessed by the clinician. Extrapolating from published Phase 3 data, this may range from 2 to 16 weeks, but may vary from patient to patient depending on the speed or degree of response or based on patient factors [4, 9, 10]. One important exception is in cases of acute safety or tolerability concerns with the traditional systemic agent, which may require withdrawal as abruptly as permitted in a proportionate manner to the significance of the safety issue.

1.2 Evaluation and maintenance of patients with AD on dupilumab

Statement 1.2.1 For patients with adequate clinical response to dupilumab, continued use at the approved dose regimen will provide optimal long-term benefit, unless PROs fail to improve. *96.2% (95.4–96.9%).*

Statement 1.2.2 For patients who do not achieve clinical improvement in AD by week 16–24, re-evaluation of diagnosis and

alternative treatment may improve outcome. *98.4% (97.4–98.8%).*

Clinical response to therapy in AD should consider objective and subjective outcomes over and above those mandated in clinical studies. Importantly, the primary outcome of IGA 0/1 used in phase 3 studies in AD fails to consider important aspects of disease impact. Notably, Silverberg et al. [11] demonstrated in a pooled analysis of two phase 3 trials that most adult patients who do not achieve IGA 0/1 achieve clinically relevant treatment effects on dupilumab, including EASI improvement, body surface area involvement (BSA), pruritus, quality of life outcomes and patient satisfaction, underscoring the need to consider multiple outcomes in determining treatment success.

An international treat-to-target clinical approach for AD was recently published, which recommended patient evaluation at 3 and 6 months for initial and optimal disease control targets, respectively [12]. Briefly, treatment continuation should be considered for patients who achieve benchmarks in both patient self-reported global assessment (PtGA) and at least one disease domain (EASI, SCORAD, NRS, DLQI or POEM). Treatment optimization should be considered for patients achieving improvement in either PtGA or a disease domain, but not both. Finally, treatment modification should be considered for those failing to achieve either outcome. Overall, this is a reasonable and clinically meaningful approach to evaluating treatment effectiveness as it considers multiple clinician and patient-reported AD outcomes. For the purposes of the discussion below, we will categorize the groups above as adequate, partial, and non-responders, respectively, recognizing that clinicians may vary in their accordance with these definitions.

For patients achieving adequate response to dupilumab, dosing should be maintained for long-term clinical efficacy. Results from a long-term maintenance study of dupilumab in adult AD showed that reduced dose frequency may decrease overall efficacy without safety advantage [13]. Additionally, a nominally higher rate of anti-drug antibodies was reported in patients with reduced dose frequency; however, this signal is not associated with clinical adverse effect, and long-term data suggest that patients are able to effectively recapture treatment response after dupilumab interruption [14].

For those on an overlapping traditional systemic agent, this agent may be tapered in a stepwise fashion in consideration of the pharmacokinetics of the agent until it is eliminated, or until loss of clinical response is observed, in which case the lowest effective dose may be used as maintenance. High-level responders may be able to taper off their traditional systemic agent more rapidly.

Non-responders should be re-evaluated to confirm diagnosis and ensure therapy adherence, including non-prescription therapies. Clinicians may consider stopping dupilumab therapy in cases of lack of clinical response within 16–24 weeks.

1.3 Management of partial or non-durable responders and concomitant systemic therapy

Statement 1.3.1 Increasing to weekly dosing may be considered in patients with partial or non-durable response to dupilumab. *92.7% (90.0–94.9%).*

Statement 1.3.2 For patients not achieving adequate response on dupilumab, the addition of a traditional systemic agent may provide benefit. *98.3% (97.3–98.7%).*

Patients achieving partial response to dupilumab should be evaluated to ensure correct diagnosis, medication adherence, optimization of topical therapies and general measures, and the addition of NB-UVB phototherapy where available. Escalation to weekly dosing has been shown to be safe and effective based on long-term studies of dupilumab in adult AD and may be considered in partial responders [14]. Indeed, among adult patients not achieving primary trial endpoints on q2w dupilumab monotherapy who underwent dose escalation to qw in open-label extension, 91% of patients achieved EASI-75 by week 100 and 97% by week 148 [6].

Finally, the addition of a traditional systemic agent may provide additional clinical benefit and may be used at full dose to expedite disease control, followed by taper as previously described. Choice of agent may depend on several

factors, including the speed and degree of disease control required, severity of acute flare, and tolerability issues. CsA typically provides the most rapid response; however, it should be used under close surveillance due to nephrotoxicity and hypertension concerns. Importantly, abrupt discontinuation of traditional systemic therapies may cause rebound and should be avoided.

A retrospective analysis of 69 patients taking dupilumab for AD showed that in 11/12 patients deemed to have inadequate response to dupilumab, the addition of oral steroids, CsA, MTX, or NB-UVB therapy improved AD signs and symptoms by 8 weeks of combined therapy with no safety issues [15]. In cases of systemic steroid usage, the intramuscular route is a preferred option by this panel due to both safety and adherence issues.

Non-durable responders—those achieving adequate response followed by subsequent worsening of disease or failure to maintain benchmarks of adequate response—may be managed similarly to partial responders. In these patients, an alternative diagnosis should also be considered.

Section 2: Special Populations in AD

There are many considerations in treating AD in special populations who are typically excluded from clinical trials. Importantly, consideration of the pharmacologic and safety profile of these medications is important in clinical decision-making, particularly for specific patient groups such as pediatrics or patients with co-existing conditions. In addition, for patients in whom immunosuppression is already an issue, starting a medication that further suppresses immunity can be a cause for concern.

Many traditional systemic medications have known drug-drug interactions, which is a concern in patients where polypharmacy is already an issue. These include, but are not limited to, older adults, patients with organ transplants, and patients receiving antiretroviral medications for HIV.

Dupilumab selectively downregulates the IL-4 and IL-13 signaling pathways, which do not play a significant role in antimicrobial and antitumoral immunity. Furthermore, dupilumab is not associated with end organ damage or significant drug-drug interactions. In this light, dupilumab may present a more favorable long-term alternative to traditional systemic medications, particularly for patient groups for whom the above issues are of specific concern.

This section aims to review the available literature for special patient populations in AD, including patients who are pregnant or breast-feeding, those with active or prior malignancy, those with a co-existing immune condition, older adults with AD, and those with suspected or confirmed COVID-19 infection.

2.1 Dupilumab use during pregnancy and lactation

Statement 2.1.1 Dupilumab exposure during pregnancy poses little risk to mother and fetus. *89.9% (86.3–92.9%).*

Statement 2.1.2 There is negligible absorption of dupilumab by infants who are breast fed by women taking dupilumab. *97.0% (96.1–97.9%).*

During pregnancy, a shift in the Th1:Th2 balance of the maternal immune system favors Th2 immunity in order to prevent fetal rejection. This shift is accompanied by an increased risk of Th2/type 2-driven diseases presenting or flaring during pregnancy [16]. AD, a disease dominated by type 2 inflammation, is the most common pregnancy-related dermatosis [17, 18]. It may occur in patients with a history of AD but notably also presents de novo in some patients [19]. In addition to the pathophysiologic basis of AD exacerbation during pregnancy, the physical and psychologic stress of pregnancy may also lead to AD flares [20]. Evidence does not suggest an increase in adverse pregnancy outcomes in patients with AD [21, 22].

There is some published literature on the treatment of AD in pregnancy and lactation, but guidance regarding the specific use of dupilumab is scarce [19, 20]. Dupilumab is an IgG4 monoclonal antibody targeting IL-4Ra, the common receptor subunit of IL-4 and IL-13. IgG is actively transported through the placenta during pregnancy, with transfer beginning around 13 weeks gestational age and increasing

linearly over the course of pregnancy, and with the greatest transfer occurring during the third trimester [23]. This means that at term fetal IgG may exceed maternal levels by > 20–30% [23]. IgG4 is the second most transported IgG subclass following IgG1 [24].

There are no data to suggest teratogenicity due to dupilumab exposure [20]. Animal studies using a surrogate antibody against IL-4Ra did not show adverse outcomes on fertility and pregnancy [3]. Two recent case reports of dupilumab use during pregnancy/lactation have been published showing no adverse outcomes for the pregnancy [25, 26] as well as in the reported lactation period for one patient who breastfed [25]. However, one of the two patients experienced an AD flare while on dupilumab shortly after giving birth [26].

A position paper from the European Task Force on AD (ETFAD), based on expert opinion, recommended against the use of dupilumab in pregnancy/lactation based on insufficient evidence [20]. Similarly, Heilskov et al. [27] do not recommend dupilumab use during pregnancy planning, pregnancy, or breastfeeding; however, most recommendations in this review, with the exception of corticosteroids and MTX, are based on weak or inadequate evidence.

Biologics are large molecules that are passed through breastmilk in very small amounts, with IgA being the predominant immunoglobulin subtype diffusing into breastmilk. When ingested via breastmilk, IgG antibodies are also likely broken down in the infant gut. Consideration of biologic use during lactation should consider that transfer into breastmilk and infant absorption are minimal [28].

Due to lack of data, use of dupilumab during pregnancy and lactation should be based on shared decision-making between the patient and clinician and consider benefit/risk for both the mother and fetus/newborn. Pregnant patients are often hesitant to take any systemic medication during pregnancy, thinking that taking medication is unsafe. Clinicians should ensure patients understand that undertreated AD in pregnancy is not without risk [29]. One pregnancy registry for dupilumab is underway in the US, as is a retrospective analysis of pregnancy outcomes using healthcare databases, and future data will help to better inform decision-making [30, 31].

Finally, there is some evidence to suggest acceptable safety of other systemic treatment options for moderate-to-severe AD, including systemic corticosteroids, CsA, and AZA, if the need arises [20]. The ETFAD recommends that the use of systemic steroids be limited in general, but that they may be used at reduced dosage for short periods when required. CsA may be used in cases where there is a clear need for better long-term disease control.

2.2 Use of dupilumab in patients with malignancy

Statement 2.2.1 There is no known additional risk in treating patients with prior malignancy and most active malignancies with dupilumab. Exclusion of CTCL prior to dupilumab initiation is an important safety consideration. *92.7% (90.1–94.9%).*

The use of systemic therapies in patients with malignancy is an area of special interest based on the patient's current medication regimen, potential use of immunosuppressive or cytotoxic therapies, and overall health status. Furthermore, considerations may be different in patients with active vs. prior malignancy.

There are no clear reports of prior malignancy recurrence on dupilumab, but patients with a history of malignancy were generally excluded from dupilumab clinical trials [4, 5, 9, 10, 32–34]. There have been no safety signals for malignancy in clinical trials of dupilumab for AD or other indications [4, 5, 9, 10, 32–34]. Therefore, the use of dupilumab in patients with a prior malignancy is thought to be low risk.

Data for dupilumab in patients with active malignancy are scarce. There are published case reports of patients with active malignancy where dupilumab was safely used; these include bladder cancer, renal carcinoma, melanoma, squamous cell carcinoma, and immune-related cutaneous adverse events secondary to chemotherapy [35–38]. Indeed, ASCO guidelines include dupilumab in their treatment algorithm for patients with active malignancy experiencing pruritus as an adverse event of

chemotherapy [37]. Furthermore, published case reports suggest that dupilumab may be an effective therapy to treat eosinophilic dermatosis of hematologic malignancy in patients with active chronic lymphocytic leukemia [39–41].

One area of particular concern is patients with suspected or active cutaneous T-cell lymphoma (CTCL), as recently published case reports show progression of CTCL after initiation of dupilumab [42–44]. These patients had either an established CTCL diagnosis for which the medication was used off-label or a presumed diagnosis of AD when dupilumab was initiated followed by an eventual diagnosis of CTCL.

The relationship among AD, CTCL, and dupilumab is controversial. In older patients with an AD-like presentation, caution must be taken to ensure correct diagnosis prior to dupilumab initiation. Based on published reports, there is speculation that these cases may have been existing, early stage CTCL, misdiagnosed as AD [43, 44]. Additionally, Espinosa et al. [42] speculate that progression of CTCL may be due to resistance of IL-4/-13 blockade of some CTCL cells. Conversely, one case report described a patient with CTCL and concomitant AD responding to dupilumab in both diseases and an eventual weaning of some CTCL treatments [45]. Special caution should be exercised in patients who may have underlying CTCL, including older patients with atypical or new-onset AD-like presentation, erythrodermic presentation, patients presenting with new lesions at locations different from typical AD sites, patients with worsening pruritus, or those presenting with lymphadenopathy.

Special consideration of dupilumab use in patients with malignancy should involve many patient-specific factors, including immune status, polypharmacy, and patient preference. Based on the available data, dupilumab may be low risk in patients with a prior malignancy and may be considered in some cases of active malignancy, particularly to treat some cutaneous adverse events secondary to chemotherapy.

2.3 Dupilumab use in patients with pre-existing immune conditions

Statement 2.3.1 Dupilumab is unlikely to increase risks associated with pre-existing immune disorders including patients with HIV, patients with HIES, and organ transplant recipients. Drug-drug interactions are an important consideration when using traditional systemic agents in patients with pre-existing immune disorders. *95.6% (94.2–97.0%).*

Guidance regarding the use of dupilumab in patients with pre-existing immune conditions such as HIV, genetic immune disorders, and immune suppression related to organ transplantation is limited. These patients were generally excluded from clinical trials and, as such, reliance on case reports and pharmacologic principles must be used to guide clinical decision-making for these patients.

Patients with HIV Several case reports have described successful control of AD with dupilumab and no adverse outcomes with respect to viral load, CD4+counts, or infections for up to 23 months of therapy [36, 46–51]. Furthermore, some data suggest that IL-4 may contribute to HIV virulence and that antagonizing IL-4 may prevent HIV replication in polarized Th2 cells [52, 53]. Indeed, analyses of HIV resistance have demonstrated that reduced IL-4 activity was associated with HIV resistance [52, 54].

Thus, dupilumab may be considered a preferred systemic therapy option for patients with AD and concomitant HIV because of lack of immune suppressive effects and known relevant drug-drug interactions, unlike other oral immune suppressive medications.

Patients with hyper-IgE syndrome (HIES) HIES is an umbrella of immune disorders characterized by a triad of AD, recurrent skin and pulmonary infections, and elevated serum IgE [55]. Autosomal dominant HIES, or Job syndrome, is caused by heterozygous loss of function mutation of *STAT3* and is the disease prototype, with clinical features including neonatal onset AD, staphylococcal skin and respiratory infections, and non-immunologic features such as skeletal and tissue

abnormalities. Importantly, many patients with HIES will suffer from severe, uncontrollable AD.

There are three published case reports of patients with HIES successfully treated with dupilumab [56–58]. In these cases, improvement in AD signs, symptoms, and quality of life was observed for up to 17 months of treatment. In one case, pruritic eruption was observed at 17 months, which resolved quickly with steroid administration; however, this patient had transitioned to monthly injection at this point [58].

Likewise, we report here a 52-year-old male patient with autosomal dominant HIES and lifelong history of severe, extensive AD. This patient failed trials of MTX and CsA and was intolerant to intramuscular triamcinolone acetonide. Dupilumab was found to be effective and well tolerated and yielded improvement within 1 month of treatment (Fig. 1).

We also report a case of a 16-year-old female patient with severe AD, recurrent infection, multiple hospitalizations, and co-existing HIES. This patient failed TCS, TCI, and NB-UVB, and her parents refused traditional systemic agents. She has been successfully treated with dupilumab and has maintained mild disease for> 18 months of follow-up, along with improved sleep quality and overall quality of life.

Based on our clinical experience, and due to increased risk of infection in patients with HIES, dupilumab is a good choice of therapy where oral immunosuppressive medications may not be appropriate [55]. In addition, the demonstrated reduction of skin infections and eczema herpeticum noted with dupilumab treatment in AD may provide benefit [59].

Post-transplant allergy, autoimmunity, and immune-related disorders (PTAA) PTAA is an umbrella of allergic and autoimmune conditions that may present in patients post-transplant, likely as a consequence of continuous Th1 suppression with immunosuppressive agents used to prevent graft rejection [60]. This relative Th2 polarization can present as AD, asthma, allergic rhinitis, food allergy, or eosinophilia and appears to be most common in heart and liver transplant recipients [61].

There are several case reports of dupilumab use in patients experiencing AD following solid organ transplants including heart and liver [62–65]. All cases reported significant effectiveness and safety for as long as 2 years with no new safety issues or concerning infections reported [64]. Notably, conjunctivitis was observed in two patients following dupilumab initiation and required artificial tears, periocular tacrolimus, and/or steroid drops [64, 65].

Although renal transplant participants are less likely to develop PTAA compared to other transplants, they may suffer from pruritus related to compromised renal function [66]. Dupilumab has also been shown in two case reports to successfully treat uremic pruritus in renal transplant patients without safety concern [66, 67].

Dupilumab may be the preferred systemic agent of choice in patients with PTAA given lack of immunosuppression or drug-drug interactions. Collaboration with an interdisciplinary medical team is important in managing these complex patients.

2.4 Dupilumab use for AD in older adults

Statement 2.4.1 Dupilumab has no additive safety concerns in older patients with AD and should be considered preferential to traditional systemic agents where contraindications, polypharmacy, and co-existing conditions complicate their use. *95.2% (94.0–96.8%).*

Statement 2.4.2 A confirmed diagnosis of AD in older adults with atypical presentation, especially to rule out CTCL, is crucial before initiating any systemic therapy, including dupilumab. *95.8% (94.9–96.9%).*

AD in older adults is complicated by physiologic impairments associated with advancing age, multiple comorbidities, and risk of polypharmacy. AD in older adults may vary from the general AD population and include lower incidence of face, scalp, and flexural involvement along with higher incidence of lesions affecting the groin and buttocks [68]. AD in older patients may appear as late onset, recurrence in patients with a history of childhood AD, or continuation and/or recurrence in

patients with adolescent or adult history of AD [68].

Given the unique clinical presentation in this age group, it is important to consider differential diagnoses, which may include asteatotic, nummular, or contact dermatitis, prurigo, scabies, drug reactions, exanthematous variant of bullous pemphigoid, and chronic eczematous eruption of aging. Additionally, CTCL is of particular concern in this age group and may present with overlapping features of AD [42, 68]. Given the previously described concerns with dupilumab use in the context of CTCL, workup to rule out CTCL in suspected cases of AD in older patients is crucial before initiating dupilumab.

The management of AD in older adults presents unique challenges. Older patients tend to have decreased skin moisture content and difficulty maintaining self-care. Frequent visits associated with NB-UVB therapy may be too burdensome. Skin atrophy associated with TCS is a consideration in older adults, and TCI may be preferred for some patients [69]. Finally, traditional systemic agents have important contraindications in older patients, and prevalence of these contraindications increases with age [69].

The incidence of comorbid disorders in older patients with AD is high. In one study, reported comorbidities included hypertension (58.3%), cerebrovascular disease (26.3%), heart disease (23.7%), diabetes mellitus (17.4%), and renal disease (10.5%) [68]. The use of traditional systemic agents thus deserves special consideration in the setting of these comorbidities. Importantly, CsA has numerous potential drug interactions with calcium channel blockers, statins, NSAIDs, SSRIs, and diuretics, complicating its use in treating AD in the older population [69]. MTX is renally excreted, and special consideration should be given to patients with renal issues; Howell et al. [69] specifically recommend that in older patients with renal impairment, meticulous dose adjustment of MTX is required when prescribed.

There is a relative lack of data on systemic therapy for AD in older patients. Despite an estimated 7% prevalence of AD in patients > 65 years, a recent systematic review showed relatively lower representation of older patients in randomized controlled trials for AD, at 4% [70]. In addition, none reported outcomes explicitly for older patients.

Two recent retrospective analyses have evaluated dupilumab efficacy and safety in older adults. In a single-center study of 30 patients 65 years with AD, 72.7% of patients had a contraindication to CsA, many of which were due to potential drug interactions [71]. In these patients, dupilumab led to a statistically significant improvements in EASI, VAS-pruritus, and DLQI with a favorable safety profile. In a large, multi-center study of 253 patients 65 years with AD, dupilumab efficacy was found to be comparable to those aged 18–64 years treated with dupilumab over 16 weeks, with a favorable safety profile, including only one drug discontinuation due to adverse event [72].

Based on the available data, dupilumab appears to be a safe and effective treatment option for older patients with AD and does not present the same complications of potential drug interactions compared to some traditional systemic agents; however, more data are needed. Clinical data powered to differentiate efficacy and safety in older patients compared to the general AD population will be helpful in guiding treatment decisions for these complex patients and may provide insight into what, if any, dose adjustment considerations are needed.

2.5 Patients with suspected or confirmed COVID-19 infection

Statement 2.5.1 Dupilumab may be continued in patients with COVID-19. *91.7% (88.8–94.1%).*

Statement 2.5.2 Dupilumab is unlikely to impact COVID-19 vaccine effectiveness and is not associated with additional safety risk. *92.8% (89.2–95.5%).*

COVID-19 proposes distinctive challenges to clinicians, as the evidence of risk-benefit for continued treatment for patients with suspected or confirmed COVID-19 is still evolving. Type 2 immunity is important for host immunity against extracellular parasites and underlies many allergic disorders, but is of lesser

Fig. 1 Patient with HIES and severe AD. Panel i and ii: Before dupilumab, on MTX 25 mg weekly. Panel iii and iv: 1 month after dupilumab initiation plus MTX 25 mg weekly. Photos courtesy of Dr. M Gooderham. *HIES* hyper-IgE syndrome, *AD* atopic dermatitis, *MTX* methotrexate

importance to antiviral immunity, which tends to be dominated by IFN signaling and Th1 immunity [73–75].

Dupilumab does not appear to increase risk of infection or infection outcomes [59, 76]. However, these analyses are not specific to COVID-19 and are limited in their interpretation. Data from ongoing registries such as SECURE-AD and the AAD COVID-19 Dermatology Registry may provide useful data on COVID-19 infection risk and outcomes in patients with AD on any systemic therapy, which will better inform treatment decisions.

Current guidance from the International Eczema Council and the ETFAD suggests that dupilumab be continued as scheduled in cases of suspected or mild-to-moderate COVID-19 infection and that therapies targeting type 2 inflammation such as dupilumab may be preferred compared to traditional systemic agents during the pandemic, recognizing that this theoretical advantage is not supported by robust clinical data [77, 78].

Preliminary data from 145 patients in the SECURE-AD registry showed no significant difference in COVID-19 infection and recovery rates between patients taking dupilumab compared to traditional systemic agents [79]. However, the duration of COVID-19 symptoms was statistically lower in patients on dupilumab compared to traditional agents. Furthermore, a trend toward lower hospitalization risk for patients on dupilumab was found compared to those on traditional agents, although not statistically significant. This is a preliminary analysis, and more robust data from this registry and

others are needed to inform treatment decisions with respect to the COVID-19 pandemic.

In the context of active COVID-19 infection, dupilumab may be continued if the patient has severe underlying disease and if the risk of exacerbation of that disease is significant. Finally, if any systemic therapy for AD is withheld, appropriate management of the underlying condition with other agents should be considered.

Furthermore, data have shown safety and efficacy of non-live vaccines in the context of dupilumab use [80]. Given these data along with the known safety profile of currently authorized vaccines for COVID-19, vaccines for COVID-19 do not pose any known effects on vaccine efficacy or safety in patients taking dupilumab. Accordingly, the Canadian Dermatology Association recently published a position statement supporting the continued use of systemic therapy during vaccination against SARS-CoV-2, unless there is a specific concern of reduced vaccine effectiveness [81].

Discontinuation of dupilumab in the context of COVID-19 infection and/or vaccination should consider the impact of treatment withdrawal on primary disease, impact on comorbidities, and relative risk of viral infection with other systemic agents. In addition, the importance of COVID-19 vaccination during the pandemic outweighs current potential safety risks for patients taking dupilumab, despite the paucity of evidence available at this time.

Section 3: Management of Potential Adverse Events in Patients on Dupilumab for AD

While dupilumab has been associated with significant and sustained improvements in disease outcomes and quality of life in patients with AD [4], some adverse reactions such as conjunctivitis [4, 82], recalcitrant head and neck dermatitis [83–86], psoriasiform eruptions [87–92], and arthritic conditions have been reported in the literature [85, 93, 94]. Of those, only conjunctivitis was identified as a confirmed adverse event related to dupilumab based on clinical trial data [3].

Notably, conjunctivitis has not been reported in dupilumab clinical trials for indications other than AD [32, 34, 95], suggesting AD has a unique pathophysiology contributing to eye inflammation. Head and neck dermatitis has not been reported as an adverse event in any dupilumab trials [80] but has become a recognized phenomenon in real-world use. Psoriasiform eruptions and arthritic conditions are rare, and in some cases [85, 89] their association with dupilumab therapy is controversial.

3.1 Management of Conjunctivitis in AD

Statement 3.1.1 Prophylactic measures such as artificial tears may reduce the incidence of conjunctivitis in patients with AD taking dupilumab. *92.8% (92.0–94.1%).*

Conjunctivitis is an important adverse event associated with dupilumab in AD [82, 95]. Observational evidence suggests 30–50% of adult patients will eventually develop conjunctivitis on treatment [96, 97]. Importantly, epidemiologic studies have shown that conjunctivitis is a common comorbidity of AD regardless of therapy, with an estimated prevalence of 31.7% [98]. Interpretation of the literature about conjunctivitis and dupilumab is complex since, in many studies, patients were diagnosed by a dermatologist or allergist rather than an ophthalmologist. Furthermore, conjunctivitis refers to a cluster of terms captured in clinical trial data and the evolving literature recognizes “ocular surface disease” as a more accurate term for this observation relative to both dupilumab use and AD in general [99].

Conjunctivitis in dupilumab patients is characterized by bilateral hyperemia, pruritus, foreign body sensation, burning, stinging, and/or increase lacrimation. Risk factors for conjunctivitis include pre-dupilumab history of conjunctivitis, and more severe disease at baseline [82]. Of note, some patients with pre-existing conjunctivitis show improvement in eye symptoms after dupilumab treatment [100]. The mechanisms underlying the increase in conjunctivitis in patients with dupilumab are unknown, although several hypotheses are currently being investigated [99]. Presentation is most often mild to moderate and effectively

controlled with artificial tears/eyedrops, with some patients requiring topical medications to the eyelid skin and/or conjunctiva. It may also resolve spontaneously with continued dupilumab treatment. A small number of patients will have severe conjunctivitis that can lead to dupilumab discontinuation.

Other eye disorders reported in dupilumab-treated patients include dry eyes, blepharitis, and keratitis. Cases of subepithelial fibrosis, cicatricial conjunctivitis, cicatricial ectropion, and/or corneal ulcerations occurring as early as 3 weeks after dupilumab initiation have been reported in dupilumab-treated patients [101, 102]. Important differential diagnoses includes bacterial conjunctivitis, episcleritis, scleritis, keratitis, uveitis, and acute glaucoma, some of which are ophthalmic emergencies and are important to rule out.

Some evidence recommends prophylactic use of artificial tears, warm compresses, and antihistamine drops [103]. For mild conjunctivitis not responding to artificial tears or moderate-to-severe conjunctivitis, corticosteroid eye drops, antihistamine/mast cell stabilizer eye drops, cyclosporin eye drops, or periocular pimecrolimus/tacrolimus may be considered. Gooderham et al. [104] provide useful guidance for management of conjunctivitis for the dermatologist, and the reader is referred to this article for detailed information and guidance.

Ophthalmology referral should be considered in patients experiencing conjunctivitis uncontrolled with first line therapies or if significant eyelid edema, excoriation, or lichenification are observed, or if there is doubt about the diagnosis or treatment of the ocular disease. Urgent ophthalmology referral should be considered in cases of significant or predominant eye pain, loss of vision, or photophobia, especially with unilateral presentation.

Finally, there is little evidence to support changes to dose frequency to improve conjunctivitis in patients taking dupilumab for AD. An analysis of pooled Phase 3 data suggests, perhaps counterintuitively, that lower dupilumab exposure may be associated with increased incidence of conjunctivitis [82]. This may be related to the fact that patients with conjunctivitis have more severe AD [82].

3.2 Management of Recalcitrant Head and Neck Dermatitis

Statement 3.2.1 Dupilumab-associated recalcitrant head and neck dermatitis may respond to short courses of low- to mid-potency topical steroids, topical calcineurin inhibitors and/or topical ketoconazole without dupilumab interruption. *98.4% (98.2–99.1%).*

Statement 3.2.2 A short course of itraconazole or adjunct systemic therapy has provided benefit in some patients not responding to topical therapy. *81.8% (75.8–87.0%).*

Recalcitrant head and neck dermatitis (HND), commonly reported as facial erythema, is a common phenotype of AD and has also been observed in real-world patients treated with dupilumab [105]. While not identified as an adverse event in dupilumab clinical trials [80], retrospective analyses and registries suggest frequency ranging from 3 to 10% [84, 106, 107]. Simpson and Ahn [108] investigated the prevalence of facial erythema from 162 patients on dupilumab for AD and detected that most patients presented with facial erythema before dupilumab initiation, and signs resolved or improved on dupilumab. De novo cases of facial erythema in patients treated with dupilumab were uncommon, representing 4% of patients in this cohort.

Dupilumab-associated recalcitrant HND may present as erythema with or without fine scaling on the head and neck region, within weeks to months of dupilumab initiation [83]. Atopy and conjunctivitis history do not appear to be predisposing factors [84–86]. Lesional skin biopsies revealed relative lack of spongiosis, increased number of ectatic capillaries, and perivascular lymphohistiocytic infiltration in a small patient cohort [85]. Epidermal hyperplasia with elongation of the rete ridges was observed in some patients, resembling psoriasiform dermatitis [85]. A recent systematic review of the literature describes the clinical presentation, treatment approaches, and outcomes in patients taking dupilumab for AD [109].

The pathogenesis of this reaction is unclear, with several proposed theories including hypersensitivity, site-specific treatment failure, seborrheic dermatitis-like reaction to facial *Malassezia sp.*, paradoxical flaring of allergic contact dermatitis, and shift from Type 2/Th2 dominant toward Th1-, Th17-, and Th22-dominant responses [84, 85]. Based on heterogeneity of reported cases, it is likely that the reaction comprises several pathogenic mechanisms which may vary from patient to patient.

Jaros et al. [110] provide a useful framework for evaluating dupilumab-associated HND, including exclusion of allergic contact dermatitis, rosacea, periorificial dermatitis, demodex-associated dermatitis, TCS withdrawal, and *Malassezia*.

Patch testing in patients experiencing HND is controversial. Suresh et al. [111] suggest that all patients considered for dupilumab should be patch tested with a standard series prior to dupilumab initiation and that comprehensive patch testing be considered in patients who develop HND on dupilumab. However, these approaches may not be practical and are complicated by the potential of dupilumab to affect patch test results [87, 112]. Furthermore, published evidence suggests that even in patients with evidence of allergic contact dermatitis, allergen avoidance did not improve dermatitis [85, 86]. It may be more reasonable to consider patch testing only in patients whose presentation and thorough history suggest allergic contact dermatitis overlying their AD.

Many patients experiencing recalcitrant HND will show minimal discomfort and continue dupilumab therapy. Intermittent treatments with emollients, TCS/TCI, azole antifungals, fucidic acid, calcipotriene, ivermectin, or brimonidine, or systemic therapies including prednisone, fluconazole, doxycycline, or antihistamines have been reported in the literature and may be considered [84–86, 113]. A stepwise approach of low- to mid-potency TCS/TCI or topical ketoconazole for 2–4 weeks, followed by itraconazole 200 mg once daily (qd) for 2–4 weeks if no improvement, may be considered.

In patients who do not respond to the above, those with significant effect on QoL, or for those with severe recalcitrant face and neck involvement, addition of MTX or CsA or a temporary/permanent discontinuation of dupilumab has been reported and can be considered [110].

3.3 Management of paradoxical psoriasiform eruption in patients with AD on dupilumab

Statement 3.3.1 Psoriasiform eruption has been reported in patients receiving dupilumab for AD. Most cases are localized and can be managed with topical anti-psoriatic therapy without dupilumab discontinuation. *85.7% (80.3–90.2%).*

Paradoxical psoriasiform eruption has been described in a small number of cases of patients taking dupilumab for AD in adults [87–92, 114–118]. Localization was typically limited to extremities, although other locations were described. Napolitano et al. [117] report a 3% frequency of psoriasiform reaction in a cohort of 90 patients. In 80% of cases, the diagnosis was supported by histopathologic changes consistent with psoriasis (PsO) including regular acanthosis, hyperkeratosis, parakeratosis, and diminished granular layer.

Notably, dupilumab led to improvement in underlying AD lesions prior to or during the onset of paradoxical PsO presentation in nearly all cases; notably, in the only reported case for which dupilumab did not improve primary AD, the diagnosis was in question and PsO may have been present prior to dupilumab initiation [89]. Approximately half of patients were kept on therapy despite this reaction, with control achieved in most cases with TCS with or without vitamin D analogue. Among those who discontinued therapy, some reports noted resolution of PsO upon dupilumab discontinuation accompanied by eventual AD flare [92, 114].

Drug-induced PsO and psoriasiform eruption were not reported as adverse events in dupilumab clinical trials. With the limited number of reports available, the prevalence of this phenomenon remains in question. The case reports to date also have limited information on patient characteristics at baseline; only a few cases document patients meeting the Hanifin and

Rajka diagnostic criteria [87–92, 114–118]. Although most cases of AD and PsO are easily distinguished clinically, phenotypes can overlap or mimic each other, and both eczematoid psoriasis and psoriasiform dermatitis can be found on histology [119, 120]. Quaranta et al. [121] have previously reported a large case series of patients with simultaneous AD and PsO and found biomarkers of distinct T-cell subpopulations such as Th17 biomarkers found exclusively in PsO lesions and type 2 biomarkers found exclusively in AD lesions. Although supposedly antagonistic diseases, the heterogeneity of AD is well known, and the simultaneous presence of AD and PsO is known to occur even without treatment.

The mutual antagonism of T-cells causing PsO and AD has been reported, as Th1 signaling is known to inhibit Th2 signaling and vice versa. Indeed, targeted therapeutics for psoriasis, including anti-TNF and anti-IL-17A agents, can themselves induce paradoxical eczematous skin lesions, which have been postulated to be Th2-driven responses [122, 123]. Adult patients with AD may therefore develop psoriasis lesions on dupilumab when Th2 counterregulatory effects on Th17 responses are absent. However, recent evidence suggests that there is no long-term skewing of T cell subsets in patients taking dupilumab for AD, including Th1-skewing [124].

Dupilumab-associated psoriasiform lesions in patients may be managed with topical anti-psoriatic therapy without discontinuation of dupilumab treatment as noted in the published reports above. If this fails or in cases of severe psoriasiform eruption, a combination of topical anti-psoriatic treatments, phototherapy and/or systemic treatment (MTX, CsA), and/or discontinuation of dupilumab may be considered.

3.4 Management of Arthrosis in Patients on Dupilumab for AD

Statement 3.4.1 Arthrosis and arthralgia are rare in patients receiving dupilumab, and their association with dupilumab therapy is uncertain. *86.7% (82.9–90.0%).*

Arthrosis is a relatively new adverse event described in patients taking dupilumab and has been reported in only a few patients in the literature [85, 93, 94]. Of the reported cases, the clinical presentation varied and included generalized polyarthralgia, monoarthritis, and enthesitis, and onset occurred days to months following dupilumab initiation. Most patients were classified as having new-onset seronegative arthropathy. Notably, dupilumab treatment led to substantial improvement in AD in several cases, with three patients achieving EASI < 3 by week 8–12 of therapy. NSAIDs and oral steroids were used to treat the reaction in several cases, and three patients reported dupilumab discontinuation.

Arthralgia was not reported as an adverse event in clinical studies for dupilumab in AD or asthma. In a Phase 3 study of dupilumab in patients with chronic rhinosinusitis (CRSwNP), arthralgia was observed in 5% of patients receiving dupilumab vs. 1% placebo [34]. Importantly, patients with AD are often on a traditional systemic agent that may be discontinued at various times before or after dupilumab initiation. As was seen in one case, withdrawal from long-term anti-metabolites such as MTX may also be associated with new onset of spondyloarthritis.

Although the number of reported cases is sparse, there is a theoretical mechanism for psoriatic arthritis-like inflammation resulting from inhibition of type 2 inflammation. Without Th2-mediated cross-inhibition, there is a theoretical basis for IL-17- or IL-23-mediated peripheral spondyloarthritis/psoriatic arthritis pattern of inflammatory arthrosis in patients treated with dupilumab. Indeed, in one ex vivo study, stimulation of healthy entheses samples with LPS to induce IL-23 was downregulated by the addition of IL-4 and IL-13, lending weight to the mechanistic rationale of IL-23-mediated inflammation associated with downregulation of IL-4 and IL-13 [125].

To date, reports of arthralgia associated with dupilumab, possibly due to enthesitis, do not meet criteria for "probable" on the Naranjo ADR probability scale because of a lack of data [126], and larger studies are required to better understand the potential association.

Patients withdrawing from traditional systemic agents such as MTX may experience

rebound inflammation or inflammatory sequelae. As such, a tapered approach to withdrawing traditional systemic agents upon dupilumab initiation should be considered. Finally, when NSAIDs are ineffective, rheumatology referral may be considered. MTX may be an option to treat arthralgia for patients on dupilumab for AD.

ACKNOWLEDGEMENTS

Funding. Funding for the journal's rapid service fee was provided by Sanofi Genzyme.

Authorship. All named authors meet the International Committee of Medical Journal Editors (ICMJE) criteria for authorship for this article, take responsibility for the integrity of the work as whole, and have given their approval for this version to be published.

Author Contributions. All authors contributed to the study conception and design. Material preparation, data collection and analysis were performed by Kim A. Papp. The first draft of the manuscript was written by Kim A. Papp and all authors commented on previous versions of the manuscript. All authors read and approved the final manuscript.

Medical Writing, Editorial, and Other Assistance. Medical writing and editorial assistance provided by Tracy Chew, PhD of Sanofi Genzyme and Nikki-Marie Brown, PhD of Ogilvy Health, funded by Sanofi Genzyme Canada in accordance with Good Publication Practice (GPP3) guidelines *(Ann Intern Med. 2015; 163:461–464).*

Disclosures. The author(s) declared the following potential conflicts of interest with respect to the research, authorship, and/or publication of this article: David N. Adam is an investigator, consultant, advisory board member, speaker for and/or receives honoraria from Actelion, Amgen, Abbvie, Boehringer Ingelheim, Celgene, Coherus, Dermira, Eli Lilly, Galderma, Janssen, Leo, Merck, Novartis, Pfizer, Regeneron, Sanofi, Stiefel, and Valeant. Jennifer R. Beecker is an investigator, consultant, advisory board member, speaker for and/or receives honoraria from Abbvie, Amgen, Celgene, CeraVe, Lilly, Galderma, Janssen, Johnson and Johnson, La Roche Posay, Leo, Novartis, Pfizer, Sanofi Genzyme, and Vichy. Robert Bissonnette is an investigator, consultant, advisory board member, speaker for and/or receives honoraria from Aquinox Pharma, Antiobix, Asana, Astellas, Brickell Biotech, Dermavant, Dermira, Dignity Sciences, Eli Lilly, Galderma, Glenmark, GSK-Stiefel, Hoffman-LaRoche Ltd, Kiniksa, Leo Pharma, Neokera, Pfizer, Regeneron, Sienna, and Vitae. Robert Bissonnette is also shareholder of Innovaderm Research. Melinda J. Gooderham has been an investigator, speaker, advisor, and/or consultant for AbbVie, Actelion, Akros, Amgen, Arena, Arcutis, Asana, Bausch, Boehringer Ingelheim, BMS, Celgene, Coherus, Dermira, Eli Lilly, Galderma, Glenmark, GSK, Janssen, Kyowa Kirin, Leo Pharma, Medimmune, Merck, Novartis, Pfizer, Regeneron, Roche, Sanofi Genzyme, Sun Pharmaceuticals, Takeda, and UCB. Chih-ho Hong has been an investigator, speaker, advisor, and/or consultant for AbbVie, Amgen, Actelion, Akros, Boehringer Ingelheim, Bristol Meyers Squibb, Celgene, Eli Lilly, Galderma, GSK, Incyte, Janssen, Leo Pharma, Medimmune, Merck, Novartis, Pfizer, Roche, Roivant Sciences, Regeneron, Sanofi Genzyme, UCB, and Valeant. Carolyn Jack is an investigator, consultant, advisory board member, speaker for and/or receives honoraria from AbbVie, ActibioTx, Amgen, Asana, Bausch Medical, Boehringer Ingelheim, Celgene, Dermavant, Eli Lilly, Janssen, Kiniksa, Leo, Neokera, Novartis, Pfizer, Sanofi, UCB, and Valeant. Melinda J. Gooderham is an investigator, consultant, advisory board member, speaker for and/or receives honoraria from AbbVie, Amgen, Aralez, Celgene, Janssen, Johnson and Johnson, Leo, Valeant, Pfizer, Pierre Fabre, and Sanofi Genzyme. M. Perla Lansang has served as an advisor/consultant for, has received grants/honoraria from, and/or has served as a speaker for AbbVie, Amgen, Astellas, Boehringer Ingelheim, Celgene, Eli Lilly, Galderma, Janssen, Leo, Novartis, Pfizer, Sanofi Genzyme, and Valeant. Charles W. Lynde has served as an

advisor/consultant and speaker for AbbVie, Altius, Amgen, Aralez, Arcutis, Bausch Health, Bayer, Boehringer Ingelheim, Bristol Myers Squibb, Celgene, Cipher, Dermavant, Eli Lilly, Fresnius Kabi Galderma, Glaxosmithkline, Innovaderm, Intega Skin, Janssen, Kyowa, LaRoche Posay, Leo Pharma, L'Oreal, Medexus, Merck, Pfizer, Proctor & Gamble, Pediapharm, Regeneron, Roche, Sanofi Genzyme, Sentrex, Teva, Tribute, UCB, Valeant, and Viatris. Kim A. Papp has served as an advisor/consultant for, has received grants/honoraria from, and/or has served as a speaker for AbbVie, Akros, Allergan, Amgen, Anacor, Arcutis, Astellas, Avillon, Bausch Health/Valeant, Baxalta, Boehringer Ingelheim, Bristol-Myers Squibb, CanFite, Celgene, Coherus, Dermira, Dice Pharmaceuticals, Dow Pharma, Eli Lilly, Evelo, Galapagos, Galderma, Genentech, Gilead, GlaxoSmithKline, Incyte, Janssen, Kyowa Hakko Kirin, Leo Pharma, Medimmune, Meiji Seika Pharma, Merck, Mitsubishi Pharma, Moberg Pharma, Novartis, Pfizer, PRCL Research, Regeneron, Roche, Sanofi, Sun Pharma, Takeda, and UCB. Neil H. Shear is a consultant, advisory board member, speaker for and/or receives honoraria from AbbVie, Amgen, Bausch Medical, Eli Lilly, Galderma, Janssen, Leo, Novartis, Sanofi Genzyme, and Sun Pharma. Irina Turchin has served as an advisor/consultant for, has received grants/honoraria from, and/or has served as a speaker for Abbvie, Amgen, Cipher, Eli Lilly, Galderma, GlaxoSmithKline, Janssen, Leo Pharma, Merck, Novartis, Sanofi, and Valeant.

Compliance with Ethics Guidelines. As no patient data were collected for the purpose of this work, institutional ethics approvals were not required.

Data Availability. The datasets generated during and/or analyzed during the current study are available from the corresponding author on reasonable request.

Open Access. This article is licensed under a Creative Commons Attribution-Non-Commercial 4.0 International License, which permits any non-commercial use, sharing, adaptation, distribution and reproduction in any medium or format, as long as you give appropriate credit to the original author(s) and the source, provide a link to the Creative Commons licence, and indicate if changes were made. The images or other third party material in this article are included in the article's Creative Commons licence, unless indicated otherwise in a credit line to the material. If material is not included in the article's Creative Commons licence and your intended use is not permitted by statutory regulation or exceeds the permitted use, you will need to obtain permission directly from the copyright holder. To view a copy of this licence, visit http://creativecommons.org/licenses/by-nc/4.0/.

REFERENCES

1. Johnson FA, Smith BJ, Bonneau M, Martin J, Romagosa C, Mazzotti F, et al. Expert elicitation, uncertainty, and the value of information in controlling invasive species. Ecol Econ. 2017;137:83–90.

2. Butler AJ, Thomas MK, Pintar KDM. Systematic review of expert elicitation methods as a tool for source attribution of enteric illness. Foodborne Pathog Dis. 2015;12:367–82.

3. Sanofi-aventis Canada Inc. Dupixent product monograph. Laval: Sanofi-aventis Canada Inc; 2017.

4. Simpson EL, Bieber T, Guttman-Yassky E, Beck LA, Blauvelt A, Cork MJ, et al. Two phase 3 trials of dupilumab versus placebo in atopic dermatitis. N Engl J Med. 2016;375:2335–48.

5. Blauvelt A, de Bruin-Weller M, Gooderham M, Cather JC, Weisman J, Pariser D, et al. Long-term management of moderate-to-severe atopic dermatitis with dupilumab and concomitant topical corticosteroids (LIBERTY AD CHRONOS): a 1-year, randomised, double-blinded, placebo-controlled, phase 3 trial. The Lancet. 2017;389:2287–303.

6. Beck LA, Thaçi D, Deleuran M, Blauvelt A, Bissonnette R, de Bruin-Weller M, et al. Dupilumab provides favorable safety and sustained efficacy for up to 3 years in an open-label study of adults with moderate-to-severe atopic dermatitis. Am J Clin Dermatol. 2020;21:567–77.

7. Ludwig CM, Hsiao JL, Lio PA, Shi V. Transitioning from immunosuppressants to dupilumab in

pediatric atopic dermatitis. Dermatitis. 2020. https://doi.org/10.1097/DER.0000000000000690

8. Wijs LEM, Thyssen JP, Vestergaard C, Thio HB, Kunkeler ACM, Biedermann T, et al. An approach for the transition from systemic immunosuppressants to dupilumab. J Eur Acad Dermatol Venereol. 2020. https://doi.org/10.1111/jdv.16941.

9. Simpson EL, Paller AS, Siegfried EC, Boguniewicz M, Sher L, Gooderham MJ, et al. Efficacy and safety of dupilumab in adolescents with uncontrolled moderate to severe atopic dermatitis: a phase 3 randomized clinical trial. JAMA Dermatol. 2020;156:44.

10. Paller AS, Siegfried EC, Thaçi D, Wollenberg A, Cork MJ, Arkwright PD, et al. Efficacy and safety of dupilumab with concomitant topical corticosteroids in children 6 to 11 years old with severe atopic dermatitis: a randomized, double-blinded, placebo-controlled phase 3 trial. J Am Acad Dermatol. 2020;83:1282–93.

11. Silverberg JI, Simpson EL, Ardeleanu M, Thaçi D, Barbarot S, Bagel J, et al. Dupilumab provides important clinical benefits to patients with atopic dermatitis who do not achieve clear or almost clear skin according to the Investigator's Global Assessment: a pooled analysis of data from two phase III trials. Br J Dermatol. 2019;181:80–7.

12. Bruin-Weller MD, Biedermann T, Bissonnette R, Deleuran M, Foley P, Girolomoni G, et al. Treat-to-treat in atopic dermatitis: an International consensus on a Set og core decision points for systemic therapies. Acta Derm Venereol. 2021;101:adv00402.

13. Worm M, Simpson EL, Thaçi D, Bissonnette R, Lacour J-P, Beissert S, et al. Efficacy and safety of multiple dupilumab dose regimens after initial successful treatment in patients with atopic dermatitis: a randomized clinical trial. JAMA Dermatol. 2020;156:131.

14. Beck LA, Mette D, Zhang Q, Akinlade B, Staudinger H, Graham N, et al. 251 Treatment interruption did not impact efficacy or long-term safety of dupilumab: a phase 3 open-label trial. J Invest Dermatol. 2017;137:S43.

15. Gori N, Chiricozzi A, Malvaso D, D'Urso DF, Caldarola G, De Simone C, et al. Successful combination of systemic agents for the treatment of atopic dermatitis resistant to dupilumab therapy. Dermatology. 2021;237:535–41.

16. Tavakolpour S, Rahimzadeh G. New insights into the management of patients with autoimmune diseases or inflammatory disorders during pregnancy. Scand J Immunol. 2016;84:146–9.

17. Ambros-Rudolph CM, Müllegger RR, Vaughan-Jones SA, Kerl H, Black MM. The specific dermatoses of pregnancy revisited and reclassified: results of a retrospective two-center study on 505 pregnant patients. J Am Acad Dermatol. 2006;54:395–404.

18. Vaughan Jones H, Nelson-Piercy SB. A prospective study of 200 women with dermatoses of pregnancy correlating clinical findings with hormonal and immunopathological profiles. Br J Dermatol. 1999;141:71–81.

19. Yang CS, Teeple M, Muglia J, Robinson-Bostom L. Inflammatory and glandular skin disease in pregnancy. Clin Dermatol. 2016;34:335–43.

20. Vestergaard C, Wollenberg A, Barbarot S, Christen-Zaech S, Deleuran M, Spuls P, et al. European task force on atopic dermatitis position paper: treatment of parental atopic dermatitis during preconception, pregnancy and lactation period. J Eur Acad Dermatol Venereol. 2019;33:1644–59.

21. Trønnes H, Wilcox AJ, Markestad T, Tollånes MC, Lie RT, Moster D. Associations of maternal atopic diseases with adverse pregnancy outcomes: a national cohort study: maternal atopic diseases and pregnancy outcomes. Paediatr Perinat Epidemiol. 2014;28:489–97.

22. Hamann CR, Egeberg A, Wollenberg A, Gislason G, Skov L, Thyssen JP. Pregnancy complications, treatment characteristics and birth outcomes in women with atopic dermatitis in Denmark. J Eur Acad Dermatol Venereol. 2019;33:577–87.

23. Palmeira P, Quinello C, Silveira-Lessa AL, Zago CA, Carneiro-Sampaio M. IgG placental transfer in healthy and pathological pregnancies. Clin Dev Immunol. 2012;2012:1–13.

24. Koren G, Ornoy A. The role of the placenta in drug transport and fetal drug exposure. Expert Rev Clin Pharmacol. 2018;11:373–85.

25. Kage P, Simon JC, Treudler R. A case of atopic eczema treated safely with dupilumab during pregnancy and lactation. J Eur Acad Dermatol Venereol [Internet]. 2020. https://doi.org/10.1111/jdv.16235.

26. Mian M, Dunlap R, Simpson E. Dupilumab for the treatment of severe atopic dermatitis in a pregnant patient: a case report. JAAD Case Rep. 2020;6:1051–2.

27. Heilskov S, Deleuran MS, Vestergaard C. Immunosuppressive and immunomodulating therapy for atopic dermatitis in pregnancy: an appraisal of the literature. Dermatol Ther. 2020;10:1215–28.

28. Witzel SJ. Lactation and the use of biologic immunosuppressive medications. Breastfeed Med. 2014;9:543–6.

29. Wollenberg A, Degitz K. Eczema herpeticatum in graviditate. DMW - Dtsch Med Wochenschr. Georg Thieme Verlag KG Stuttgart, New York; 1995;120: 1395–8.

30. Regeneron Pharmaceuticals. Dupilumab and pregnancy outcomes: a retrospective cohort study using administrative healthcare databases (Dupi PODS) [Internet]. clinicaltrials.gov; 2020. Report No.: NCT03936335. https://clinicaltrials.gov/ct2/show/NCT03936335. Accessed 15 Mar 2021.

31. Regeneron Pharmaceuticals. Post-Authorization Safety Study to Monitor Pregnancy and Infant Outcomes Following Administration of Dupilumab During Planned or Unexpected Pregnancy in North America [Internet]. clinicaltrials.gov; 2020 May. Report No.: NCT04173442. Available from: https://clinicaltrials.gov/ct2/show/NCT04173442. Accessed 15 Mar 2021.

32. Castro M, Corren J, Pavord ID, Maspero J, Wenzel S, Rabe KF, et al. Dupilumab efficacy and safety in moderate-to-severe uncontrolled asthma. N Engl J Med. 2018;378:2486–96.

33. Rabe KF, Nair P, Brusselle G, Maspero JF, Castro M, Sher L, et al. Efficacy and safety of dupilumab in glucocorticoid-dependent severe asthma. N Engl J Med. 2018;378:2475–85.

34. Bachert C, Han JK, Desrosiers M, Hellings PW, Amin N, Lee SE, et al. Efficacy and safety of dupilumab in patients with severe chronic rhinosinusitis with nasal polyps (LIBERTY NP SINUS-24 and LIBERTY NP SINUS-52): results from two multicentre, randomised, double-blind, placebo-controlled, parallel-group phase 3 trials. Lancet. 2019;394:1638–50.

35. Bosma AL, de Wijs LEM, Hof MH, van Nieuwenhuizen BR, Gerbens LAA, Middelkamp-Hup MA, et al. Long-term effectiveness and safety of treatment with dupilumab in patients with atopic dermatitis: results of the TREAT NL (TREatment of ATopic eczema, the Netherlands) registry. J Am Acad Dermatol. 2020;83:1375–84.

36. Fowler E, Rosen J, Lev-Tov H, Yosipovitch G. Two cancer patients receiving dupilumab for treatment of atopic dermatitis. Acta Derm Venereol. 2019;99: 899–900.

37. Phillips GS, Wu J, Hellmann MD, Postow MA, Rizvi NA, Freites-Martinez A, et al. Treatment outcomes of immune-related cutaneous adverse events. J Clin Oncol. 2019;37:2746–58.

38. Siliquini N, Viola R, Giura MT, Fierro MT, Ribero S, Ortoncelli M. Case of bladder cancer during Dupilumab therapy: just an incidental event? Dermatol Ther [Internet]. 2020. https://doi.org/10.1111/dth.13854.

39. Cohen PR. What's in a name? a new nomenclature has been proposed For eosinophilic dermatosis of hematologic malignancy (EDHM): hematologic-related malignancy-induced eosinophilic dermatosis (He Remained). Dermatol Online J. 2020;26:6.

40. Goyal A, Lofgreen S, Mariash E, Bershow A, Gaddis KJ. Targeted inhibition of IL -4/13 with dupilumab is an effective treatment for eosinophilic dermatosis of hematologic malignancy. Dermatol Ther [Internet]. 2020. https://doi.org/10.1111/dth.13725.

41. Jin A, Pousti BT, Savage KT, Mollanazar NK, Lee JB, Hsu S. Eosinophilic dermatosis of hematologic malignancy responding to dupilumab in a patient with chronic lymphocytic leukemia. JAAD Case Rep. 2019;5:815–7.

42. Espinosa ML, Nguyen MT, Aguirre AS, Martinez-Escala ME, Kim J, Walker CJ, et al. Progression of cutaneous T-cell lymphoma after dupilumab: case review of 7 patients. J Am Acad Dermatol. 2020;83: 197–9.

43. Chiba T, Nagai T, Osada S, Manabe M. Diagnosis of mycosis fungoides following administration of dupilumab for misdiagnosed atopic dermatitis. Acta Derm Venereol. 2019;99:818–9.

44. Hollins LC, Wirth P, Fulchiero Jr GJ, Foulke GT. Long-standing dermatitis treated with dupilumab with subsequent progression to cutaneous T-cell lymphoma. Cutis [Internet]. 2020;106. https://www.mdedge.com/dermatology/article/227611/atopic-dermatitis/long-standing-dermatitis-treated-dupilumab-subsequent. Accessed 4 Feb 2021.

45. Mollanazar NK, Savage KT, Pousti BT, Jariwala N, Del Guzzo C, Haun P, et al. Cutaneous T-cell lymphoma and concomitant atopic dermatitis responding to dupilumab. Cutis [Internet]. 2020;106. https://www.mdedge.com/dermatology/article/228390/atopic-dermatitis/cutaneous-t-cell-lymphoma-and-concomitant-atopic. Accessed 4 Feb 2021.

46. Mollanazar NK, Qiu CC, Aldrich JL, Tedaldi E, Valdes- Rodriguez R, Savage KT, et al. Use of dupilumab in patients who are HIV-positive: report of four cases. Br J Dermatol. 2019;181:1311–2.

47. Marks DH, Piantadosi AL, Patil SU, Raff A, Yu J. Successful use of dupilumab for recalcitrant atopic dermatitis in an HIV patient. Dermatitis. 2019;30: 276–7.

48. Romagnuolo M, Angileri L, Tavecchio S, Marzano AV, Ferrucci S. Safety and efficacy of dupilumab in a patient with severe atopic dermatitis and HIV infection, with 15 months of follow-up. Clin Exp Dermatol. 2020;45:762–3.

49. Olbricht N, Kromer C, Forkel S, Schön MP, Buhl T. Effective treatment of atopic dermatitis with dupilumab in an HIV-positive patient. JDDG J Dtsch Dermatol Ges. 2020;18:1488–90.

50. Lor M, Villa N, Holland V. Safe and effective treatment of atopic dermatitis using dupilumab over 23 months in a patient with HIV. Dermatol Ther [Internet]. 2020. https://doi.org/10.1111/dth.14271.

51. Brodska P, Panzner P, Sedlacek D, Terl M, Cetkovska P. Use of dupilumab in a patient with atopic dermatitis, severe asthma, and HIV infection. Dermatol Ther [Internet]. 2020. https://doi.org/10.1111/dth.14159.

52. Becker Y. The molecular mechanism of human resistance to HIV-1 infectionin persistently infected individuals—a review, hypothesis and implications. Virus Genes. 2005;31:113–9.

53. Becker Y. The spreading of HIV-1 infection in the human organism is caused by fractalkine trafficking of the infected lymphocytes—a review, hypothesis and implications for treatment. Virus Genes. 2007;34:93–109.

54. Trivedi HN, Plummer FA, Anzala AO, Njagi E, Bwayo JJ, Ngugi EN, et al. Resistance to HIV-1 infection among African sex workers is associated with global hyporesponsiveness in interleukin4 production. FASEB J. 2001;15:1795–7.

55. Al-Shaikhly T, Ochs HD. Hyper IgE syndromes: clinical and molecular characteristics. Immunol Cell Biol. 2019;97:368–79.

56. Sogkas G, Hirsch S, Jablonka A, Witte T, Schmidt RE, Atschekzei F. Dupilumab to treat severe atopic dermatitis in autosomal dominant hyper-IgE syndrome. Clin Immunol. 2020;215:108452.

57. Lévy R, Béziat V, Barbieux C, Puel A, Bourrat E, Casanova J-L, et al. Efficacy of dupilumab for controlling severe atopic dermatitis in a patient with hyper-IgE syndrome. J Clin Immunol. 2020;40:418–20.

58. Su C-J, Tseng H-C. Treatment efficacy of dupliumab in a hyperimmunoglobulin E syndrome patient with severe atopic dermatitis. JAAD Case Rep. 2021;11:60–2.

59. Fleming P, Drucker AM. Risk of infection in patients with atopic dermatitis treated with dupilumab: a meta-analysis of randomized controlled trials. J Am Acad Dermatol. 2018;78:62-69.e1.

60. López-Abente J, Bernaldo-de-Quirós E, Camino M, Gil N, Panadero E, Campos-Domínguez M, et al. Immune dysregulation and Th2 polarization are associated with atopic dermatitis in heart-transplant children: a delicate balance between risk of rejection or atopic symptoms. Am J Transplant. 2019;19:1536–44.

61. Marcus N, Amir AZ, Grunebaum E, Dipchand A, Hebert D, Ng VL, et al. De novo allergy and immune-mediated disorders following solid-organ transplantation—prevalence, natural history, and risk factors. J Pediatr. 2018;196:154-160.e2.

62. Jamgochian M, Milgraum D, Milgraum S, Pappert A. Dupilumab as treatment for atopic dermatitis in a pediatric heart transplant patient: a case report. Dermatol Ther [Internet]. 2020. https://doi.org/10.1111/dth.14018.

63. Hamid RN, Bomar L, Strowd L. Dupilumab for treatment of severe atopic dermatitis in a heart transplant recipient. MDEDGE.com/dermatology. 2019;103:2.

64. Sklover L, Nielson C, De Benedetto A. The use of selective Th2 blocker dupilumab for the treatment of atopic dermatitis in a heart transplant patient: case report. Dermatol Ther [Internet]. 2019. https://doi.org/10.1111/dth.13144.

65. Ludriksone L, Elsner P, Malessa C, Settmacher U, Schliemann S. Effectiveness and safety of dupilumab for atopic dermatitis in a liver transplant recipient: a case report. JDDG J Dtsch Dermatol Ges. 2020;18:740–2.

66. Silverberg JI, Brieva J. A successful case of dupilumab treatment for severe uremic pruritus. JAAD Case Rep. 2019;5:339–41.

67. Kha C, Raji K, Chisolm S. Treatment of atopic dermatitis with dupilumab in a renal transplant patient. Dermatitis. 2020;31:e17–8.

68. Tanei R. Atopic dermatitis in older adults: a review of treatment options. Drugs Aging. 2020;37:149–60.

69. Howell AN, Ghamrawi RI, Strowd LC, Feldman SR. Pharmacological management of atopic dermatitis in the elderly. Expert Opin Pharmacother. 2020;21:761–71.

70. Lam M, Zhu JW, Maqbool T, Adam G, Tadrous M, Rochon P, et al. Inclusion of older adults in randomized clinical trials for systemic medications for atopic dermatitis: a systematic review. JAMA Dermatol. 2020;156:1240.

71. Napolitano M, Fabbrocini G, Scalvenzi M, Blasio C, Stingeni L, Patruno C. Efficacy and safety of dupilumab in atopic dermatitis in elderly patients: a retrospective study. Clin Exp Dermatol. 2020;45:888–90.

72. Patruno C, Napolitano M, Argenziano G, Peris K, Ortoncelli M, Girolomoni G, et al. Dupilumab therapy of atopic dermatitis of the elderly: a multicentre, real-life study. J Eur Acad Dermatol Venereol. 2021;35:958–64.

73. Paul WE, Zhu J. How are TH2-type immune responses initiated and amplified? Nat Rev Immunol. 2010;10:225–35.

74. Wong L-YR, Lui P-Y, Jin D-Y. A molecular arms race between host innate antiviral response and emerging human coronaviruses. Virol Sin. 2016;31:12–23.

75. Braun J, Loyal L, Frentsch M, Wendisch D, Georg P, Kurth F, et al. SARS-CoV-2-reactive T cells in healthy donors and patients with COVID-19. Nature. 2020;587:270–4.

76. Eichenfield LF, Bieber T, Beck LA, Simpson EL, Thaçi D, de Bruin-Weller M, et al. Infections in Dupilumab Clinical Trials in Atopic Dermatitis: A Comprehensive Pooled Analysis. Am J Clin Dermatol. 2019;20:443–56.

77. International Eczema Councill. IEC Statement on COVID 19 [Internet]. 2020. https://www.eczemacouncil.org/iec-statement-on-covid-19. Accessed 12 Feb 2021.

78. Wollenberg A, Flohr C, Simon D, Cork MJ, Thyssen JP, Bieber T, et al. European Task Force on Atopic Dermatitis statement on severe acute respiratory syndrome coronavirus 2 (SARS-Cov-2) infection and atopic dermatitis. J Eur Acad Dermatol Venereol [Internet]. 2020. https://doi.org/10.1111/jdv.16411.

79. ISAD Society. AD and COVID-19: lessons from the SECURE-AD registry and beyond [Internet]. 2020. https://www.youtube.com/watch?v=i0xNg95PKRg&feature=youtu.be. Accessed 12 Feb 2021.

80. Blauvelt A, Rosmarin D, Bieber T, Simpson EL, Bagel J, Worm M, et al. Improvement of atopic dermatitis with dupilumab occurs equally well across different anatomical regions: data from phase III clinical trials. Br J Dermatol. 2019;181:196–7.

81. Canadian Dermatology Association. Canadian Dermatology Association Position Statement SC2 / SARS-2 / SARS-Cov-2 (SC2) vaccination of patients on systemic therapies [Internet]. 2021. https://dermatology.ca/wp-content/uploads/2021/01/CDA-Position-Statement_-Vaccination-of-patients-on-systemic-therapies_20-Jan-2021.pdf. Accessed 12 Feb 2021.

82. Akinlade B, Guttman-Yassky E, de Bruin-Weller M, Simpson EL, Blauvelt A, Cork MJ, et al. Conjunctivitis in dupilumab clinical trials. Br J Dermatol. 2019;181:15.

83. Dalia Y, Johnson SM. First Reported Case of Facial Rash After Dupilumab Therapy. Pract Dermatol. 2018.

84. Waldman RA, DeWane ME, Sloan B, Grant-Kels JM. Characterizing dupilumab facial redness: a multi-institution retrospective medical record review. J Am Acad Dermatol. 2020;82:230–2.

85. Wijs LEM, Nguyen NT, Kunkeler ACM, Nijsten T, Damman J, Hijnen DJ. Clinical and histopathological characterization of paradoxical head and neck erythema in patients with atopic dermatitis treated with dupilumab: a case series. Br J Dermatol. 2019;183:745–9.

86. Seok SH, An JH, Shin JU, Lee HJ, Kim DH, Yoon MS, et al. Facial redness in atopic dermatitis patients treated with dupilumab: a case series. Allergy Asthma Immunol Res. 2020;12:1063.

87. Safa G, Paumier V. Psoriasis induced by dupilumab therapy. Clin Exp Dermatol. 2019;44:e49-50.

88. Stout M, Guitart J, Tan T, Silverberg JI. Psoriasis-like dermatitis developing in a patient with atopic dermatitis treated with dupilumab. Dermatitis. 2019;30:376–8.

89. Tracey EH, Elston C, Feasel P, Piliang M, Michael M, Vij A. Erythrodermic presentation of psoriasis in a patient treated with dupilumab. JAAD Case Rep. 2018;4:708–10.

90. Gori N, Caldarola G, Pirro F, De Simone C, Peris K. A case of guttate psoriasis during treatment with dupilumab. Dermatol Ther [Internet]. 2019. https://doi.org/10.1111/dth.12998.

91. Varma A, Levitt J. Dupilumab-induced phenotype switching from atopic dermatitis to psoriasis. JAAD Case Rep. 2020;6:217–8.

92. Fowler E, Silverberg JI, Fox JD, Yosipovitch G. Psoriasiform dermatitis after initiation of treatment with dupilumab for atopic dermatitis. Dermatitis. 2019;30:234–6.

93. Willsmore ZN, Woolf RT, Hughes C, Menon B, Kirkham B, Smith CH, et al. Development of inflammatory arthritis and enthesitis in patients on dupilumab: a case series. Br J Dermatol. 2019;181:1068–70.

94. Ishibashi M, Honda T, Tabuchi Y, Kabashima K. Polyenthesitis during treatment with dupilumab for atopic dermatitis. J Eur Acad Dermatol Venereol [Internet]. 2020. https://doi.org/10.1111/jdv.16239.

95. Bansal A, Simpson EL, Paller AS, Siegfried EC, Blauvelt A, de Bruin-Weller M, et al. Conjunctivitis in dupilumab clinical trials for adolescents with atopic dermatitis or asthma. Am J Clin Dermatol. 2021;22:101–15.

96. Halling A-S, Loft N, Silverberg JI, Guttman-Yassky E, Thyssen JP. Real-world evidence of dupilumab efficacy and risk of adverse events: a systematic review and meta-analysis. J Am Acad Dermatol. 2021;84:139–47.

97. Wollenberg A, Ariens L, Thurau S, van Luijk C, Seegräber M, de Bruin-Weller M. Conjunctivitis occurring in atopic dermatitis patients treated with dupilumab–clinical characteristics and treatment. J Allergy Clin Immunol Pract. 2018;6:1778-1780.e1.

98. Ravn NH, Ahmadzay ZF, Christensen TA, Larsen HHP, Loft N, Rævdal P, et al. Bidirectional association between atopic dermatitis, conjunctivitis and other ocular surface diseases: a systemic review and meta-analysis. J Am Acad Dermatol. 2021;85:453–61.

99. Utine CA, Li G, Asbell P, Pflugfelder S, Akpek E. Ocular surface disease associated with dupilumab treatment for atopic diseases. Ocul Surf. 2021;19:151–6.

100. Thyssen JP, Bruin-Weller MS, Paller AS, Leshem YA, Vestergaard C, Deleuran M, et al. Conjunctivitis in atopic dermatitis patients with and without dupilumab therapy—international eczema council survey and opinion. J Eur Acad Dermatol Venereol. 2019;33:1224–31.

101. Li G, Berkenstock M, Soiberman U. Corneal ulceration associated with dupilumab use in a patient with atopic dermatitis. Am J Ophthalmol Case Rep. 2020;19:100848.

102. Liberman P, Shifera AS, Berkenstock M. Dupilumab-associated conjunctivitis in patients with atopic dermatitis. Cornea. 2020;39:784–6.

103. Maudinet A, Law-Koune S, Duretz C, Lasek A, Modiano P, Tran THC. Ocular surface diseases induced by dupilumab in severe atopic dermatitis. Ophthalmol Ther. 2019;8:485–90.

104. Gooderham M, McDonald J, Papp K. Diagnosis and management of conjunctivitis for the dermatologist. J Cutan Med Surg. 2018;22:200–6.

105. Girolomoni G, de Bruin-Weller M, Aoki V, Kabashima K, Deleuran M, Puig L, et al. Nomenclature and clinical phenotypes of atopic dermatitis. Ther Adv Chronic Dis. 2021;12:204062232110029.

106. Igelman SJ, Na C, Simpson EL. Alcohol-induced facial flushing in a patient with atopic dermatitis treated with dupilumab. JAAD Case Rep. 2020;6:139–40.

107. Ariëns LFM, van der Schaft J, Spekhorst LS, Bakker DS, Romeijn GLE, Kouwenhoven TA, et al. Dupilumab shows long-term effectiveness in a large cohort of treatment-refractory atopic dermatitis patients in daily practice: 52-Week results from the Dutch BioDay registry. J Am Acad Dermatol. 2021;84:1000–9.

108. Ahn J, Lee DH, Na C, Shim DH, Jung HJ, Choi YS, et al. Facial Erythema in Moderate to Severe Atopic dermatitis patients treated with Dupilumab. Poster presented at: 11th Georg Rajka International Symposium on Atopic Dermatitis; April 19–20, 2021; Seoul, South Korea.

109. Jo CE, Finstad A, Georgakopoulos JR, Piguet V, Yeung J, Drucker AM. Facial and neck erythema associated with dupilumab treatment: A systematic review. J Am Acad Dermatol. 2021;84:1339–47.

110. Jaros J, Hendricks AJ, Shi VY, Lio PA. A practical approach to recalcitrant face and neck dermatitis in atopic dermatitis. Dermatitis. 2020;31:169–77.

111. Suresh R, Murase JE. The role of expanded series patch testing in identifying causality of residual facial dermatitis following initiation of dupilumab therapy. JAAD Case Rep. 2018;4:899–904.

112. de Wijs LEM, van der Waa JD, Nijsten T, Silverberg JI, Kunkeler ACM, Hijnen DJ. Effects of dupilumab treatment on patch test reactions: a retrospective evaluation. Clin Exp Allergy. 2021;51:959–67.

113. de Beer FSA, Bakker DS, Haeck I, Ariens L, van der Schaft J, van Dijk MR, et al. Dupilumab facial redness: positive effect of itraconazole. JAAD Case Rep. 2019;5:888–91.

114. Kim HS, Yeung J. Psoriasis appearing after dupilumab therapy in atopic dermatitis: a case report. SAGE Open Med Case Rep. 2020;8:2050313X2094045.

115. Ferrucci S, Tavecchio S, Berti E, Angileri L. Acute onset of psoriasis in a patient with atopic dermatitis treated with dupilumab. Clin Exp Dermatol. 2020;45:625–6.

116. Dimitrov D, Al Adawi M, Abdelhadi Z, Jafferany M. Exacerbation of psoriasis after initiation of dupilumab in atopic dermatitis patient. Dermatol Ther [Internet]. 2020. https://doi.org/10.1111/dth.13572.

117. Napolitano M, Scalvenzi M, Fabbrocini G, Cinelli E, Patruno C. Occurrence of psoriasiform eruption during dupilumab therapy for adult atopic dermatitis: a case series. Dermatol Ther [Internet]. 2019. https://doi.org/10.1111/dth.13142.

118. D'Ambra I, Babino G, Fulgione E, Calabrese G, Ronchi A, Alfano R, et al. Psoriasis onset under dupilumab treatment in two patients affected by atopic dermatitis and one patient affected by alopecia areata: clinical and dermoscopic patterns. Dermatol Ther [Internet]. 2020. https://doi.org/10.1111/dth.14169.

119. Garzorz-Stark N, Krause L, Lauffer F, Atenhan A, Thomas J, Stark SP, et al. A novel molecular disease classifier for psoriasis and eczema. Exp Dermatol. 2016;25:767–74.

120. Eyerich S, Onken AT, Weidinger S, Franke A, Nasorri F, Pennino D, et al. Mutual antagonism of T cells causing psoriasis and atopic eczema. N Engl J Med. 2011;365:231–8.

121. Quaranta M, Knapp B, Garzorz N, Mattii M, Pullabhatla V, Pennino D, et al. Intraindividual genome expression analysis reveals a specific molecular signature of psoriasis and eczema. Sci Transl Med. 2014;6:244ra90.

122. Nakamura M, Lee K, Singh R, Zhu TH, Farahnik B, Abrouk M, et al. Eczema as an adverse effect of anti-TNF therapy in psoriasis and other Th1-mediated diseases: a review. J Dermatol Treat. 2017;28:237–41.

123. Guttman-Yassky E, Krueger JG. Atopic dermatitis and psoriasis: two different immune diseases or one spectrum? Curr Opin Immunol. 2017;48:68–73.

124. Bakker DS, van der Wal MM, Heeb LEM, Giovannone B, Asamoah M, Delemarre EM, et al. Early and long-term effects of dupilumab treatment on circulating T-cell function on moderate-to-severe atopic dermatitis patient. J Invest Dermatol. 2021;141:1943-1953.e13.

125. Bridegwood C, Sharif K, Freeston J, Saleem B, Russell T, Watad A, et al. Regulation of entheseal IL-23 expression by IL-4 and IL-13 as an explanation for arthropathy development under dupilumab therapy. Rheumatology. 2020;60:keaa568.

126. Naranjo CA, Busto U, Sellers EM, Sandor P, Ruiz I, Roberts EA, et al. A method for estimating the probability of adverse drug reactions. Clin Pharmacol Ther. 1981;30:239–45.

Figure A1. Individual and composite agreement plots of panelists. *Left*, individual panelist responses. *Middle*, derived mean (green) and Bayesian distribution (pink) of composite responses. Mean and Bayesian estimates are denoted within the inset legend for each question. *Right*, where applicable, adjusted Bayesian estimates with outliers removed where appropriate.

Statement	Individual Responses	Derived Mean and Bayesian Estimates	Adjusted Mean and Bayesian Estimates
1.1.1. Concurrent treatment with traditional systemic therapy and dupilumab does not alter either drug's intrinsic risk profile.	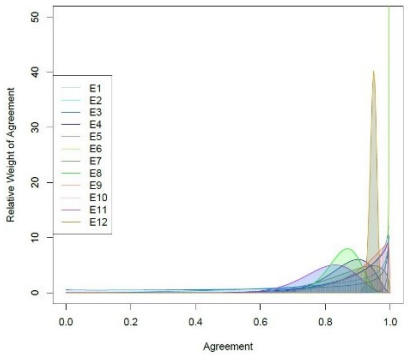	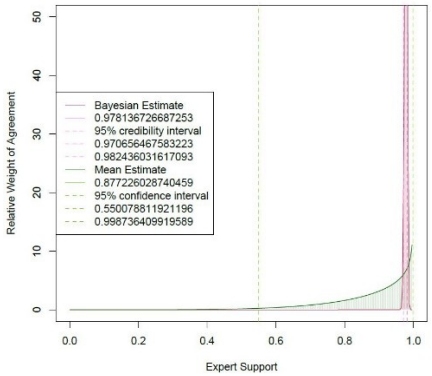	
1.1.2. When initiating dupilumab, concurrent systemic therapies may be tapered according to clinical response following dupilumab introduction, except in cases of adverse event or intolerance to traditional systemic agent necessitating withdrawal as abruptly as permitted relative to the safety issue.	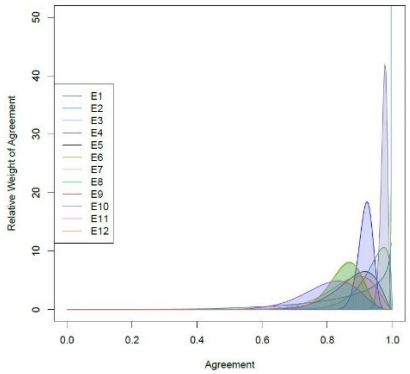	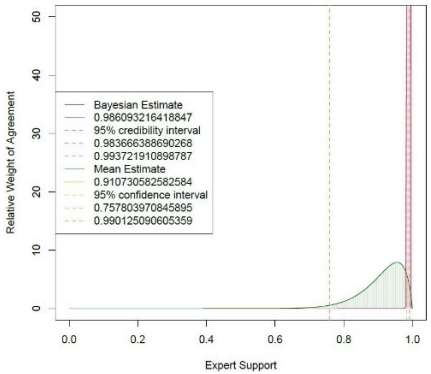	

1.2.1. For patients with adequate clinical response to dupilumab, continued use at the approved dose regimen will provide optimal long-term benefit, unless PROs fail to improve.	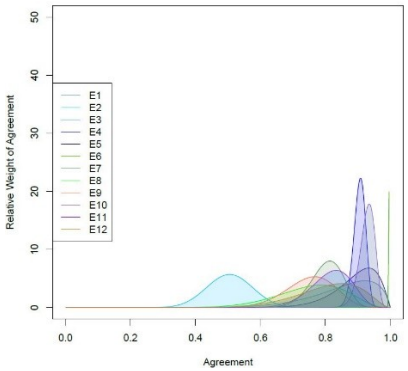	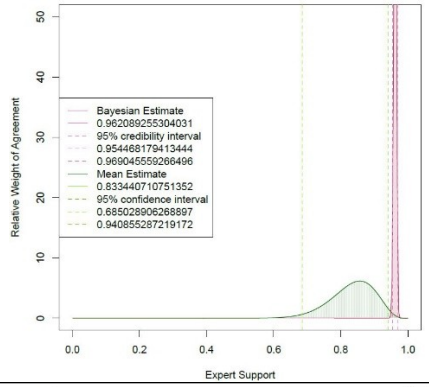	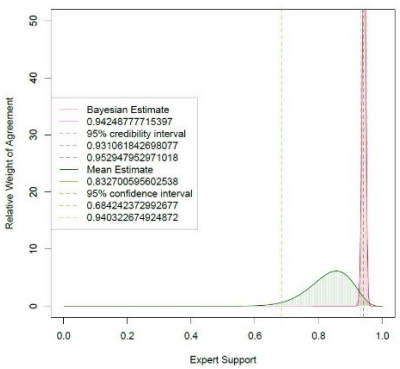
1.2.2. For patients who do not achieve clinical improvement in AD by week 16-24, re-evaluation of diagnosis and alternative treatment may improve outcome.	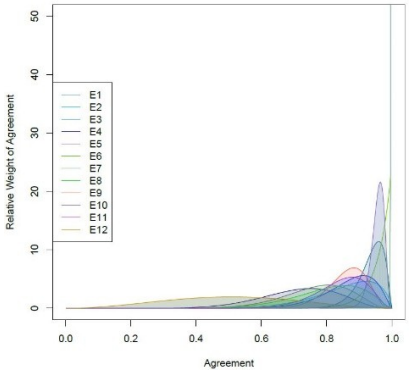	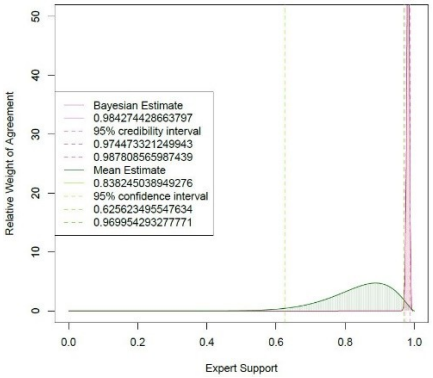	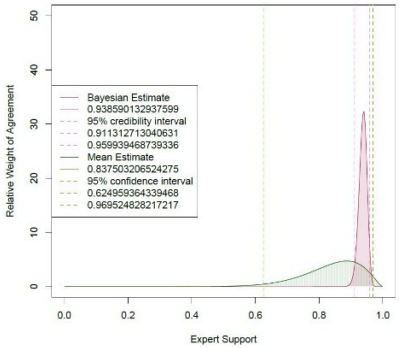
1.3.1. Increasing to weekly dosing may be considered in patients with partial or non-durable response to dupilumab.	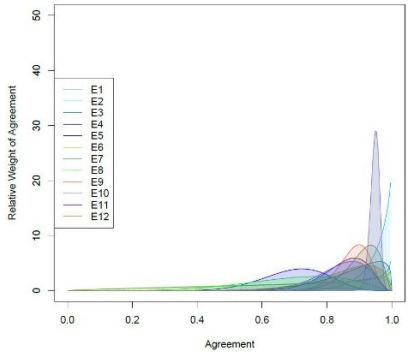	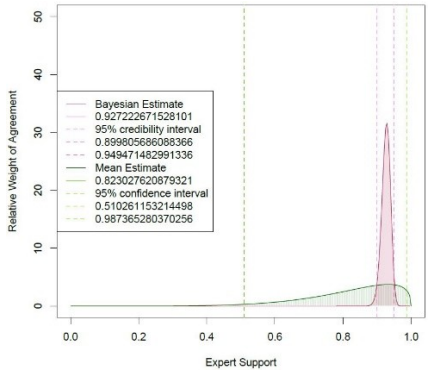	

1.3.2. For patients not achieving adequate response on dupilumab, the addition of a traditional systemic agent may provide benefit.	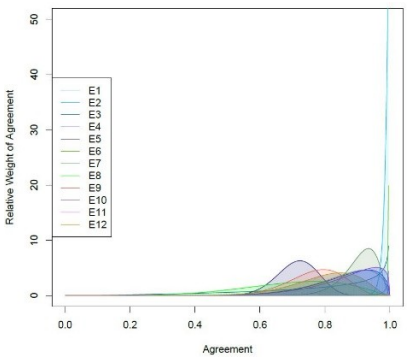	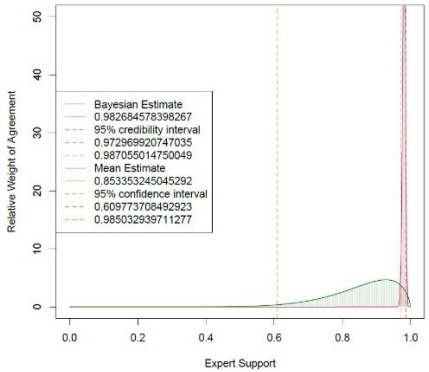	
2.1.1. Dupilumab exposure during pregnancy poses little risk to mother and fetus.	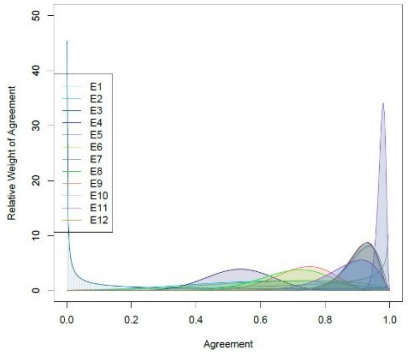	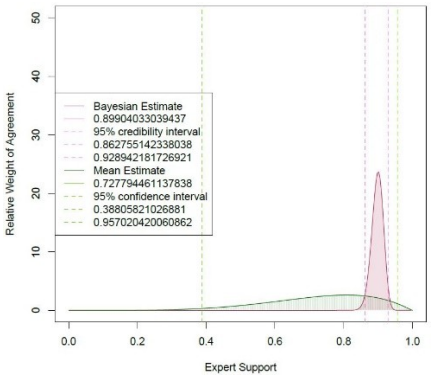	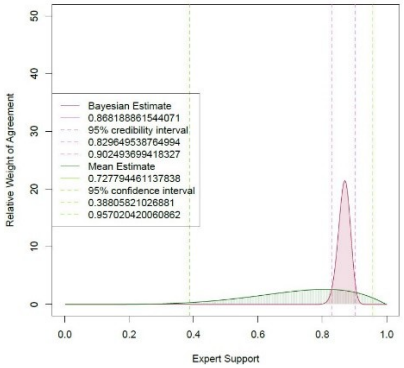
2.1.2. There is negligible absorption of dupilumab by infants who are breast fed by women taking dupilumab.	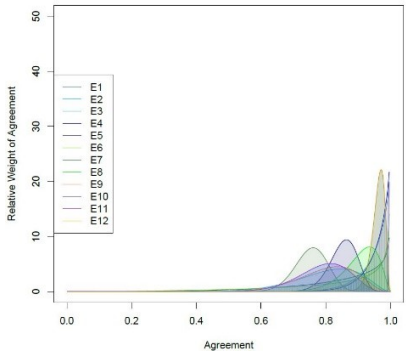	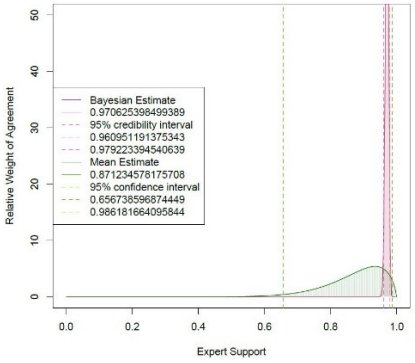	

2.2.1. There is no known additional risk in treating patients with prior malignancy and most active malignancies with dupilumab. Exclusion of CTCL prior to dupilumab initiation is an important safety consideration.	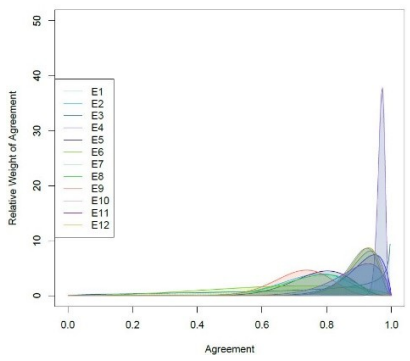	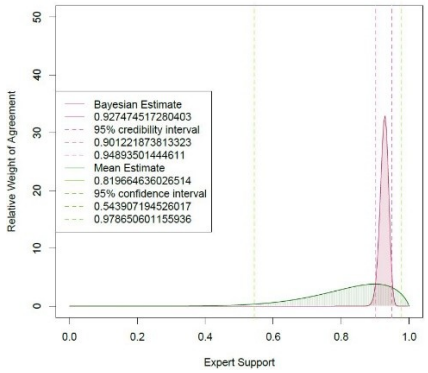	
2.3.1. Dupilumab is unlikely to increase risks associated with pre-existing immune disorders including patients with HIV, patients with HIES, and organ transplant recipients. Drug-drug interactions are an important consideration when using traditional systemic agents in patients with pre-existing immune disorders.	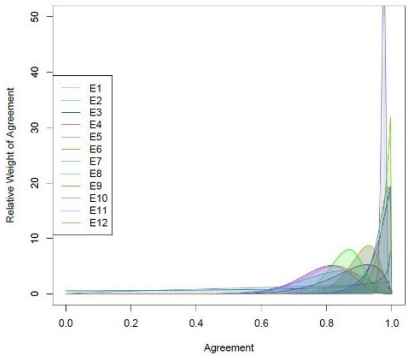	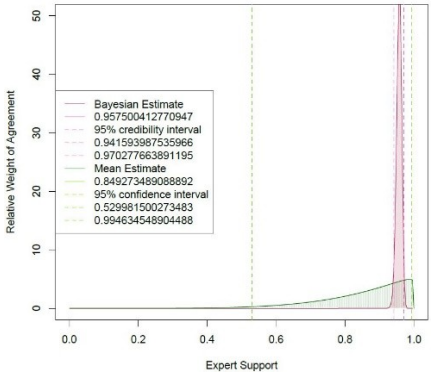	
2.4.1. Dupilumab has no additive safety concerns in older patients with AD, and should be considered preferential to traditional systemic agents where contraindications, polypharmacy, and co-existing conditions complicate their use.	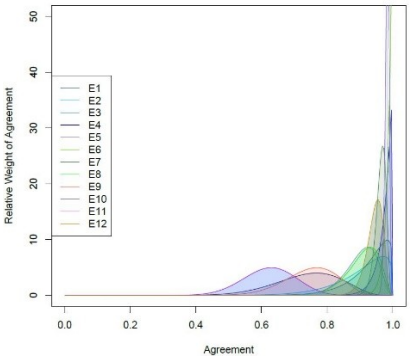	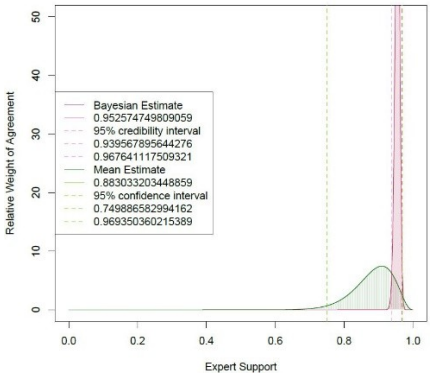	

2.4.2. A confirmed diagnosis of AD in older adults with atypical presentation, especially to rule out CTCL, is crucial before initiating any systemic therapy, including dupilumab.	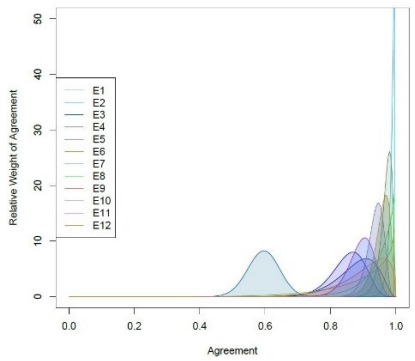	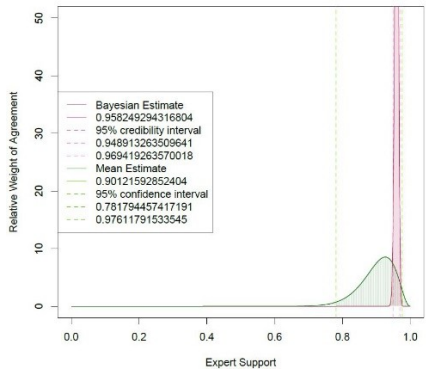	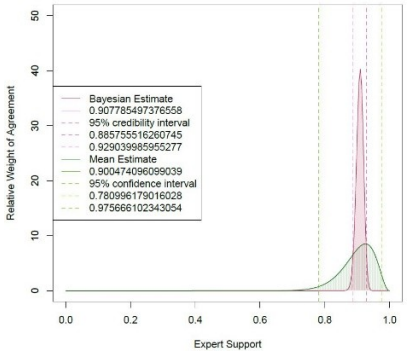
2.5.1. Dupilumab may be continued in patients with COVID-19.	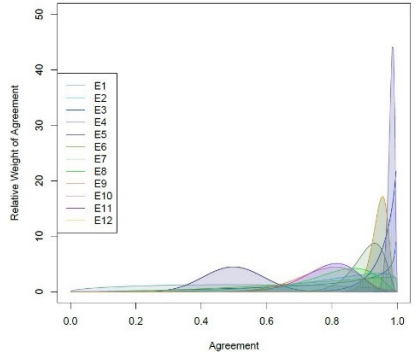	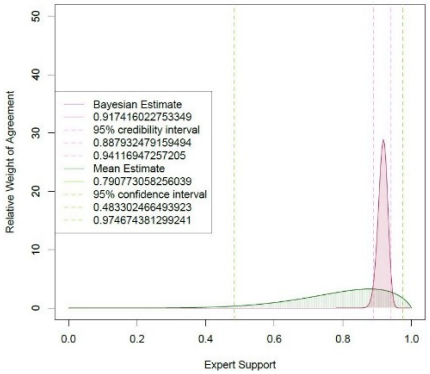	
2.5.2 Dupilumab is unlikely to impact COVID-19 vaccine effectiveness and is not associated with additional safety risk.	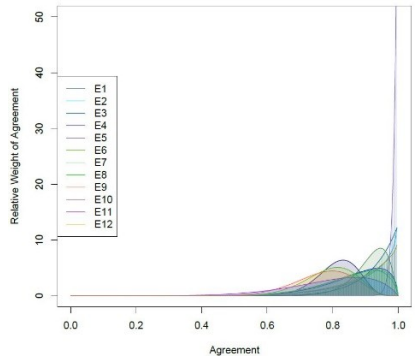	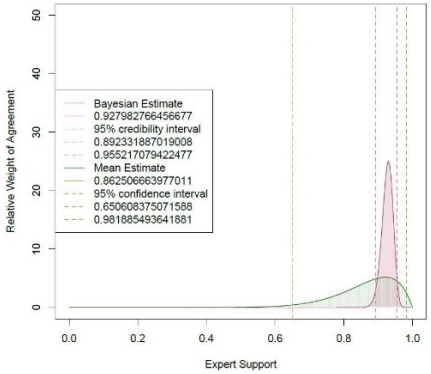	

3.1.1. Prophylactic measures such as artificial tears may reduce the incidence of conjunctivitis in patients with AD taking dupilumab.	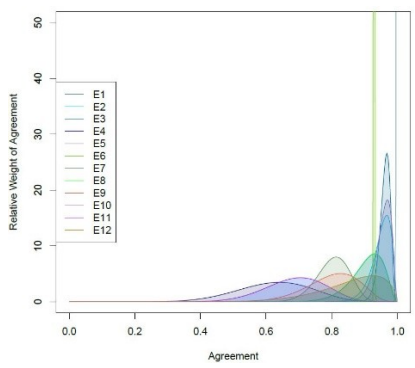	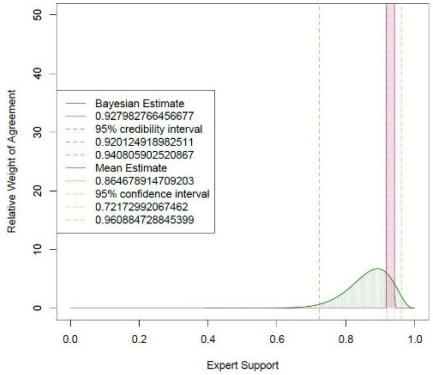	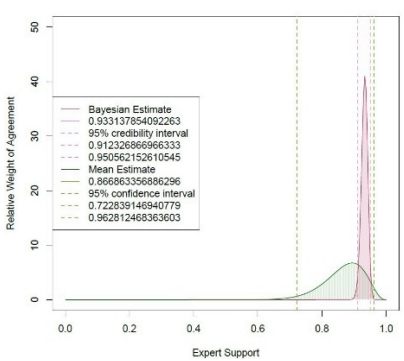
3.2.1. Dupilumab-associated recalcitrant head and neck dermatitis may respond to short courses of low- to mid-potency topical steroids, topical calcineurin inhibitors and/or topical ketoconazole without dupilumab interruption.	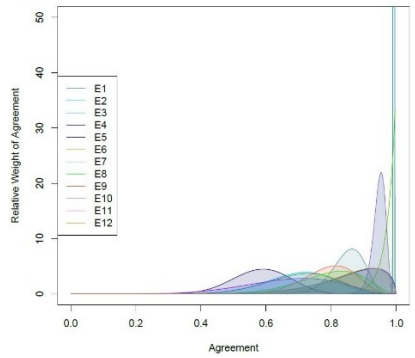	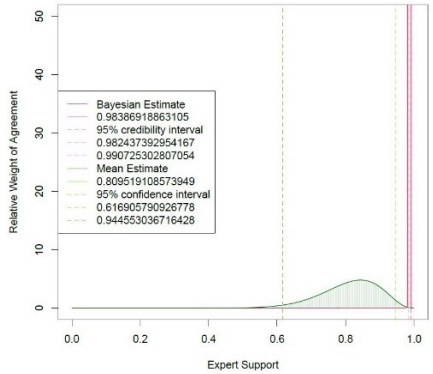	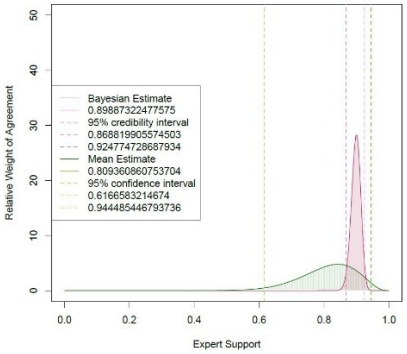
3.2.2. A short course of itraconazole or adjunct systemic therapy has provided benefit in some patients not responding to topical therapy.	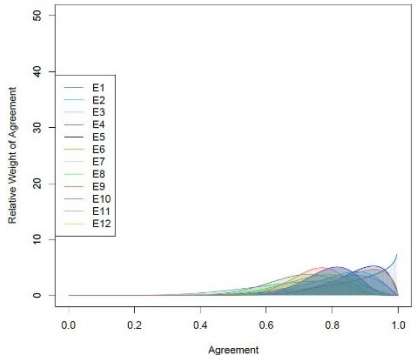	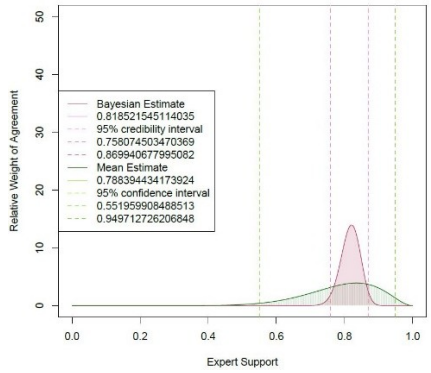	

3.3.1. Psoriasiform eruption has been reported in patients receiving dupilumab for AD. Most cases are localized and can be managed with topical anti-psoriatic therapy without dupilumab discontinuation.	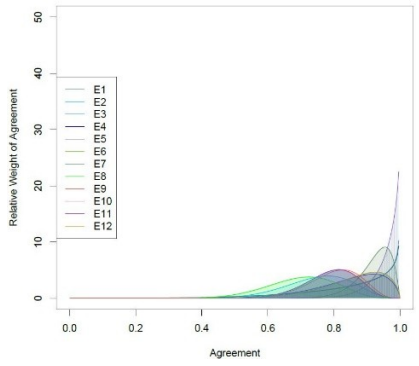	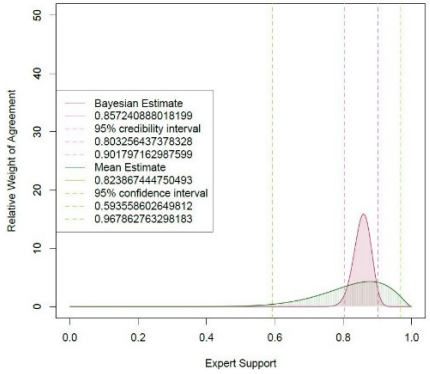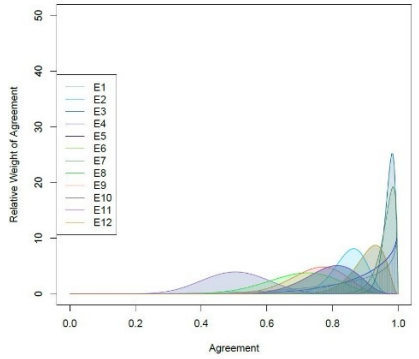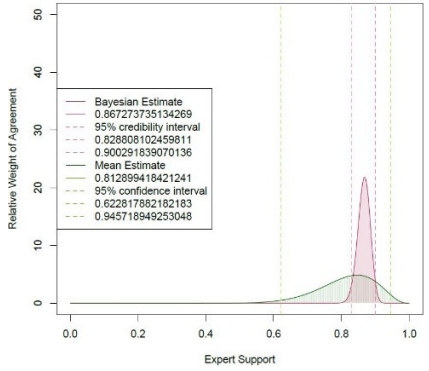	
3.4.1. Arthrosis and arthralgia are rare in patients receiving dupilumab, and their association with dupilumab therapy is uncertain.