Advances in Medical Sciences 64 (2019) 246–251

Contents lists available at ScienceDirect

Advances in Medical Sciences

journal homepage: www.elsevier.com/locate/advms

Original research article

Clinical characteristics of autoimmune pancreatitis with IgG4 related kidney disease

Sawako Kuruma, Terumi Kamisawa*, Masataka Kikuyama, Kazuro Chiba, Ryoko Shimizuguchi, Satomi Koizumi, Taku Tabata

Department of Internal Medicine, Tokyo Metropolitan Komagome Hospital, Tokyo, Japan

ARTICLE INFO

Keywords:
Autoimmune pancreatitis
IgG4-related kidney disease
IgG4

ABSTRACT

Purpose: To clarify the clinical characteristics of autoimmune pancreatitis (AIP) in immunoglobulin (Ig)G4-related kidney disease (IgG4-RKD).

Patients and methods: A total of 92 patients with AIP were divided into an IgG4-RKD-positive group (RKD-P group, n = 13) and an IgG4-RKD-negative group (RKD-N group, n = 79) on the basis of the diagnostic criteria for IgG4-RKD. Clinical characteristics, including: age; sex; the presence of extrapancreatic lesions other than renal lesions, proteinuria, and hematuria; serum concentrations of IgG, IgG4, IgE, and creatinine; and urinary concentrations of liver-type fatty acid binding protein, α1-microglobulin, β2-microglobulin, and N-acetyl-β-D-glucosaminidase were compared between the RKD-P and RKD-N groups. The clinical course of the RKD-P group was also characterized.

Results: The prevalence of extrapancreatic lesions other than renal lesions was significantly higher in the RKD-P group (84.6% vs 43.0%,$p < 0.01$). Serum creatinine (1.19 mg/dl versus 0.74 mg/dl, $p < 0.05$), urinary β2-microglobulin (6609.8 μg/l vs 265.8 μg/l, $p < 0.05$), and the prevalence of proteinuria (30.7% vs 7.6%, $p < 0.05$) were significantly higher in the RKD-P group. Nine out of thirteen patients in the RKD-P group had multiple low-density renal lesions on enhanced computed tomography, 3 patients had multiple high-intensity lesions on diffusion-weighted magnetic resonance images, and 1 patient had diffuse thickening of the renal wall, with a smooth intra-luminal surface.

Conclusions: Patients who had AIP with IgG4-RKD were more likely to have extrapancreatic lesions other than those in the kidney, and their serum creatinine and urinary β2-microglobulin concentrations were significantly higher than in those without IgG4-RKD.

1. Introduction

Autoimmune pancreatitis (AIP) is characterized radiologically by enlargement of the pancreas and narrowing of the main pancreatic duct, serologically by elevation of serum immunoglobulin (Ig)G4 levels, histologically by abundant infiltration of IgG4-positive plasma cells and lymphocytes with dense fibrosis of the pancreas, the frequent presence of sclerosis in other organs, and steroid responsiveness [1,2]. On the basis of its systemic manifestations, AIP is currently recognized as a pancreatic lesion of an IgG4-related disease [3–5]. Some authors have reported the presence of histological tubulointerstitial nephritis (TIN), with infiltration of IgG4-positive plasma cells, in patients with AIP [6–8], and renal lesions have been identified using computed tomography (CT) or magnetic resonance imaging (MRI) in 35%–38% of patients with AIP [9,10]. However, some patients have TIN with high serum IgG4 levels but no pancreatic lesions [11].

The reason why some patients with AIP also have renal lesions, while others do not, is unclear. Therefore, in the present study, we compared the clinical characteristics of patients with AIP with and without renal lesions.

2. Patients and methods

2.1. Patients

The subjects of this study were 92 patients with AIP (62 men and 30 women, with a mean age of 64 years). All of these patients had been diagnosed using the international consensus diagnostic criteria [2] and

* Corresponding author at: Department of Internal Medicine, Tokyo Metropolitan Komagome Hospital, 3-18-22 Honkomagome, Bunkyo-ku, Tokyo 113-8677, Japan.

E-mail address: kamisawa@cick.jp (T. Kamisawa).

https://doi.org/10.1016/j.advms.2018.12.005
Received 13 March 2018; Accepted 10 December 2018
1896-1126/ © 2018 Medical University of Bialystok. Published by Elsevier B.V. All rights reserved.

Table 1
Diagnostic criteria for IgG4-related kidney disease (IgG4-RKD) [12].
Adapted from: "Proposal for diagnostic criteria for IgG4-related kidney disease," by Kawano M, Saeki T, Nakashima H, Nishi S, Yamaguchi Y, Hisano S, et al, 2011, Clin Exp Nephrol, 15, p. 624. Copyright 2011 by the Japanese Society of Nephrology. Reprinted with permission.

Presence of some kidney damage, as manifested by abnormal urinalysis or urine marker (s) or decreased kidney function with either elevated serum IgG level, hypocomplementemia, or elevated serum IgE level	
Abnormal renal radiologic findings: a. Multiple low-density lesions on enhanced computed tomography b. Diffuse kidney enlargement c. Hypovascular solitary mass in the kidney d. Hypertrophic lesion of renal pelvic wall without irregularity of the renal pelvic surface	
Elevated serum IgG4 level (IgG4 ≥ 135 mg/dl)	
Histologic findings in the kidney a. Dense lymphoplasmacytic infiltration with infiltrating IgG4-positive plasma cells > 10/high power field (HPF) and/or IgG4/IgG-positive plasma cells > 40% b. Characteristic fibrosis surrounding nests of lymphocytes and/or plasma cells	
Histologic findings in extra-renal organ(s): Dense lymphoplasmacytic infiltration with infiltrating IgG4-positive plasma cells > 10/HPF and/or IgG4/IgG-positive plasma cells > 40% in extra-renal organ(s)	
Definite:	1) + 3) + 4) a, b
	2) + 3) + 4) a, b
	2) + 3) + 5)
	1) + 3) + 4) a + 5)
Probable:	1) + 4) a, b
	2) + 4) a, b
	2) + 5) 3) + 4) a, b
Possible:	1) + 3)
	2) + 3)
	1) + 4) a
	2) + 4) a

Appendix: (1) Clinically and histologically, the following diseases should be excluded: Wegener's granulomatosis, Churg-Strauss syndrome, extramedullary plasmacytoma. (2) Radiologically, the following diseases should be excluded: malignant lymphoma, urinary tract carcinomas, renal infarction and pyelonephritis (rarely, Wegener's granulomatosis, sarcoidosis and metastatic carcinoma). (3) Cases with suspected disease according to the diagnostic algorithm are classified into probable or possible IgG4-RKD according to these criteria.

all had type 1 AIP. These patients were initially investigated to determine whether the diagnostic criteria (Table 1) and algorithm (Fig. 1) for IgG4-related kidney disease (IgG4-RKD) published by the working group on IgG4-RKD, established by the Japanese Society of Nephrology [12], were satisfied. IgG4-RKD was diagnosed if a combination of kidney damage, appropriate renal radiologic findings, high serum IgG4 concentration, and consistent renal or extra-renal histologic findings were present.

Serum IgG, IgG4, and IgE concentrations were measured in 85, 90, and 74 patients, respectively. The presence or absence of proteinuria and hematuria was recorded in 65 patients and serum creatinine level was measured in 83 patients. Urinary α1-microglobulin (α1MG), β2-microglobulin (β2MG), N-acetyl-β-D-glucosaminidase (NAG), and L-type fatty acid binding protein (L-FABP) were measured in 20, 26, 27, and 17 patients, respectively. Sixty-nine patients underwent contrast-enhanced CT and MRI examinations, 14 underwent contrast-enhanced CT examination alone, and 9 underwent only MRI examination. Five out of the 9 patients who underwent only MRI examination could not undergo contrast-enhanced CT examination because of their renal dysfunction. IgG4-RKD was defined on enhanced CT by the presence of multiple low-density lesions, diffuse bilateral renal swelling, a hypovascular solitary nodule, and diffuse thickening of the wall of the renal pelvis, with a smooth intra-luminal surface [12]. It was defined on MRI by the presence of renal lesions that were relatively hypointense compared to normal parenchyma on T2-weighted images and hyperintense on diffusion-weighted images [13]. Serum IgG4 was measured in 90 out of 92 patients, and 3 patients underwent renal biopsy.

According to the diagnostic criteria and algorithm for IgG4-RKD, 2 patients were definitively diagnosed as having IgG4-RKD, none were diagnosed with probable IgG4-RKD, and 11 patients were diagnosed with possible IgG4-RKD. These 13 patients comprised an IgG4-RKD-positive group (RKD-P group) and the remaining patients comprised an IgG4-RKD-negative group (RKD-N group, n = 79). None of the patients in the RKD-P group had a past history of renal disease.

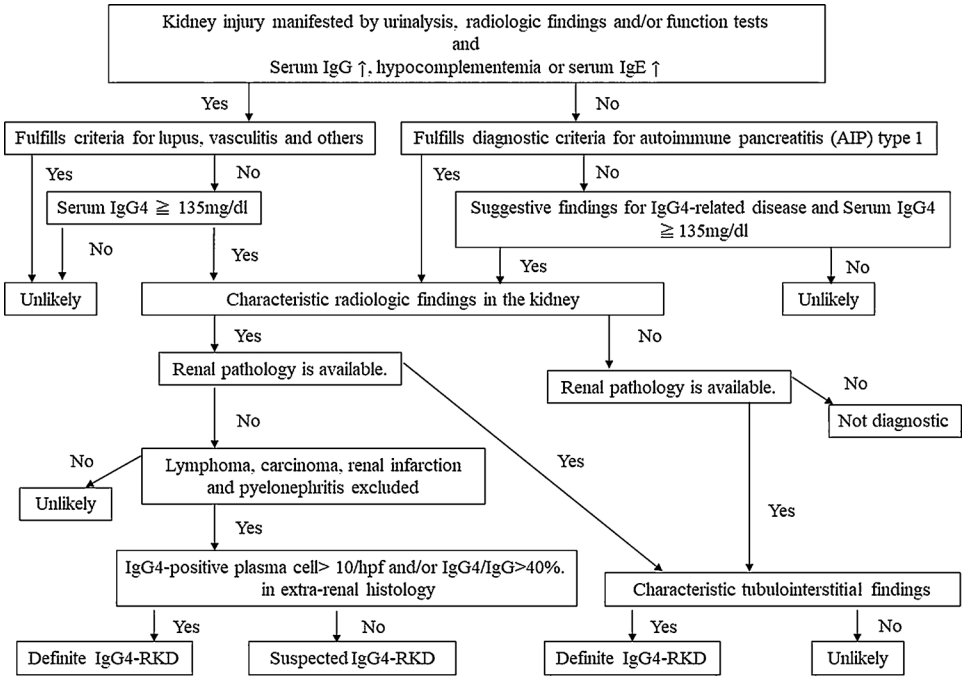

Fig. 1. Diagnostic algorithm for IgG4-related kidney disease (IgG4-RKD).
From "Proposal for diagnostic criteria for IgG4-related kidney disease," by Kawano M, Saeki T, Nakashima H, Nishi S, Yamaguchi Y, Hisano S, et al, 2011, *Clin Exp Nephrol*, 15, p. 621. Copyright 2011 by the Japanese Society of Nephrology.

2.2. Methods

We compared the clinical characteristics of patients in the two groups, including: age; sex; the presence of extrapancreatic lesions other than renal lesions, proteinuria, and hematuria; serum IgG, IgG4, IgE, and creatinine concentrations; and urinary α1MG, β2MG, NAG, and L-FABP concentrations.

The CT or MRI findings in the RKD-P group were characterized as follows: Type A - multiple low-density lesions on enhanced CT; Type B - diffuse kidney enlargement; Type C - hypovascular solitary mass in the kidney; and Type D - hypertrophic lesion of the renal pelvic wall, without irregularity of the pelvic surface. The clinical course of the RKD-P group was also monitored.

2.3. Ethical issues

The present study protocol was reviewed and approved by the Institutional Review Board of Tokyo Metropolitan Komagome Hospital (Reg. No. 1752). Informed consent was submitted by all subjects when they were enrolled.

3. Results

3.1. Clinical, serological, and urinary characteristics

The clinical characteristics of the RKD-P and RKD-N groups are shown in Table 2. There were no significant differences in the mean age or the ratio of men to women between the RKD-P and RKD-N groups. The prevalence of extrapancreatic lesions other than renal lesions was significantly higher in the RKD-P group (85%; sclerosing cholangitis - 2; sialadenitis - 3; dacryoadenitis - 1; retroperitoneal fibrosis - 3; lymphadenomegaly - 4; lung - 1; gall bladder - 3) than in the RKD-N group (43%; sclerosing cholangitis - 7; sialadenitis - 17; retroperitoneal fibrosis - 6; lymphadenomegaly - 6; dacryoadenitis - 9; hepatic pseudotumor - 2; dura mater - 1; sinusitis - 1) ($p < 0.01$).

The mean serum creatinine concentration was significantly higher in the RKD-P group than in the RKD-N group (1.19 ± 0.99 mg/dl [mean ± SD] vs 0.74 ± 0.21 mg/dl, $p < 0.05$). There were no significant differences in the serum IgG4, IgG, or IgE concentrations between the two groups.

The urinary concentration of β2MG was significantly higher in the RKD-P group (6,609.8 ± 1,5343.7 μg/l vs 265.8 ± 478.9 μg/l, $p < 0.05$), and the cutoff value that distinguished the RKD-P group from the RKD-N group was 178.0 μg/l (Fig. 2). The prevalence of proteinuria was significantly higher in the RKD-P group than in the RKD-N group (30.7% [4/13] vs 7.6% [4/52], $p < 0.05$).

Table 2
Clinical, serological, and urinary differences between IgG4-RKD positive group and negative group in patients with autoimmune pancreatitis.

	RKD-P	RKD-N	P value
mean age (years old)	65.9 (n = 13)	63.7 (n = 79)	0.64
male-female ratio	12:1 (n = 13)	50:29 (n = 79)	0.053
extrapancreatic lesions other than kidney	84.6% (n = 13)	43.0% (n = 79)	0.006
serum IgG level (mg/dl)	2254.3 (n = 13)	1917.3 (n = 72)	0.086
serum IgG4 level (mg/dl)	372.8 (n = 13)	450.4 (n = 77)	0.671
serum IgE level (IU/l)	434.2 (n = 12)	654.0 (n = 62)	0.586
serum creatinine level (mg/dl)	1.19 (n = 13)	0.74 (n = 74)	0.0208
rate of proteinuria (%)	30.7 (n = 13)	7.6 (n = 52)	0.044
rate of hematuria (%)	15.3 (n = 13)	7.6 (n = 52)	0.59
urinary L-FABP level (μg/g· Cre)	11.2 (n = 9)	6.27 (n = 8)	0.809
urinary α1MG level (mg/l)	17.5 (n = 9)	10.1 (n = 11)	0.21
urinary β2MG level (μg/l)	6609.8 (n = 9)	265.8 (n = 17)	0.025
urinary NAG level (IU/l)	12.7 (n = 10)	11.2 (n = 17)	0.505

L-FABP: L-type fatt acid binding protein, α1MG: α1-microglobulin, β2MG: β2-microglobulin, NAG: N-acetyl-β-D-glucosaminidase.

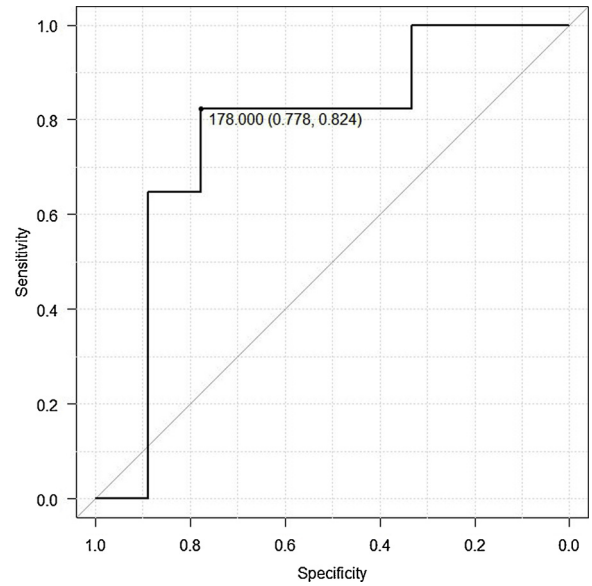

Fig. 2. The receiver operating characteristic (ROC) curve of urinary β2MG levels.
The area under the curve (AUC) was 0.77 (95% confidence interval: 0.544–0.999).

3.2. Radiological and pathological findings

Radiological and pathological findings and the clinical progression of the RKD-P group are shown in Table 3. Overall, 9 out of 13 patients in the RKD-P group had multiple low-density lesions on enhanced CT and 3 had multiple high-intensity lesions on diffusion-weighted MR images. These 12 patients were classified as type A (Fig. 3a). One patient had diffuse thickening of the renal wall with a smooth intra-luminal surface, and was classified as type D (Fig. 3b). Three out of 13 patients in the RKD-P group underwent renal biopsy - 1 patient was diagnosed with TIN and diabetes mellitus (DM) nephropathy, 1 had TIN alone (Fig. 4a, b), and 1 showed no abnormalities.

3.3. Changes during steroid therapy

Twelve patients in the RKD-P group underwent steroid therapy and one (No. 8) did not, because of an absence of symptoms and normal renal function. The initial dose of prednisolone was 0.6 mg/kg daily. After 2–4 weeks, the dose was tapered by 5 mg every 1–2 weeks, according to clinical response. All of the 12 patients then continued maintenance therapy of 2.5–5 mg daily. The pancreatic and renal lesions improved on CT or MRI in 8 (66.7%) of the patients, whereas the pancreatic lesion alone improved in 2 patients, and neither lesion improved in 1 patient. The renal lesion improved before steroid therapy and the pancreatic lesion improved during steroid therapy in 1 patient (Table 3). In 11 patients whose pancreatic lesions improved during steroid therapy, the mean time to improvement was 4.6 weeks (range 1–24 weeks). In 8 patients whose renal lesions improved after steroid therapy, the mean time for improvement was 12.5 weeks (range 1–68 weeks). There was no significant difference in the mean period of time required for radiological improvement between the pancreatic and renal lesions (4.6 ± 6.4 [mean ± SD] versus 12.5 ± 21.4, $p = 0.085$) (Fig. 5). The mean of follow up period was 37.6 months for the 12 patients who underwent steroid therapy. Seven patients had serum creatinine levels within the normal range before therapy, and all were still normal afterwards. Although the serum creatinine level of one patient (No. 11) was 4.3 mg/dl before steroid therapy, it improved to

Table 3
Radiological and pathological findings and clinical course of the RKD-P group.

No	Age	Sex	Renal biopsy	IgG4 (mg/dl)	Creatinine (mg/dl)	Radiological type	Radiological finding after PSL	Creatinine after PSL
1	63	M		320	0.9	D	improved (Panc 3 w. Kidney 3 w)	normal
2	59	F		313	0.5	A	improved (Panc 2 w after PSL. Kidney before PSL)	normal
3	61	M		351	1.2	A	improved (Panc 2 W. Kidney 68 w)	not improved
4	48	M		286	0.7	A	improved (Panc 2 W. Kidney 2 w)	normal
5	85	M		715	0.7	A	improved (Panc 2 W. Kidney 2 w)	normal
6	68	M		667	1.6	A[a]	improved (Only Panc 24 W)	not improved
7	55	M		136	0.8	A	improved (Only Panc 9 W)	normal
8	72	M	Normal	844	0.9	A	–	–
9	62	M		316	0.6	A	improved (Panc 1 W. Kidney 1 w)	normal
10	71	M		257	1	A	no change (Panc. Kidney)	not improved
11	72	M	TIN + DM nephropathy	244	4.3	A[a]	improved (Panc 2 W. Kidney 16 w)	improved
12	68	M	TIN	211	1.58	A[a]	improved (Panc 2 W. Kidney 2 w)	not improved
13	73	M		213	0.73	A	improved (Panc 2 W. Kidney 2 w)	normal

M: male, F: female, TIN: tubulointerstitial nephritis, DM: diabetes mellitus, Panc: pancreas, PSL: prednisolone.
[a] examined by MRI.

2.2 mg/dl 2 months later, after commencing steroid therapy. The serum creatinine concentrations of four patients (No. 3, 6, 10, 12) were 1.0–1.6 mg/dl, and these had also improved after steroid therapy (Table 3).

4. Discussion

In the present study, 14% of patients with AIP were shown to also have IgG4-RKD. Consistent with this, the prevalence of renal lesions in patients with AIP in previous studies ranged from 3.4% to 38% [8,9,11,14–16].

The prevalence of extrapancreatic lesions other than renal lesions was significantly higher in the RKD-P group than in the RKD-N group. Kanno et al. [16] reported that 57.9% of patients with AIP had extrapancreatic lesions. Although there was no significant difference in serum IgG4 concentration between the RKD-P and RKD-N groups, the severity of the disease might have been worse in the RKD-P group. Kawano et al. [12] reported that 95.1% of IgG4-RKD patients had accompanying extra-renal lesions, and 80.5% of IgG4-RKD patients already had IgG4-related disease of other organs. The fact that IgG4-RKD is rarely symptomatic explains why cases of IgG4-RKD are usually detected during screening for other IgG4-related diseases.

In the present study, several urinary markers were quantified, but only β2MG was significantly higher in the RKD-P than in the RKD-N group. Nishi et al. [17] reported that high urinary concentrations of NAG and α1MG were relatively frequently detected in patients with AIP, but no previous study has compared the concentrations of urinary markers in patients with AIP that was with and without IgG4 RKD.

β2MG is a component of the major histocompatibility class I molecule (MHC I) and is present in all nucleated cells [18]. It is reabsorbed almost completely by the proximal tubules and a high urinary concentration reflects a disorder of the proximal tubule [19]. The quantity of β2MG present on the surface of cells is greater when lymphocytes are activated in the presence of collagen disorders, autoimmune disease, and infection. When β2MG concentration rises in the serum, the urine β2MG concentration increases as well. Thus, the high concentrations of urinary β2MG in the RKD-P group might be the result of tubular inflammation.

In the present study, the serum creatinine concentration and the prevalence of proteinuria were found to be significantly higher in the RKD-P group. Nishi et al. [17] reported that there was renal involvement on contrast-enhanced CT imaging in 18.2% of patients with AIP, which was associated with proteinuria and lower estimated glomerular filtration rate (eGFR). Although the typical form of IgG4-RKD is TIN, a variety of glomerular diseases have also been reported in association with IgG4-RKD [12,20,21]. In previous studies, membranous glomerulonephritis was present in ~7% of patients with IgG4-RKD [21]. Although moderate-to-severe proteinuria was detected in 50.1% of IgG4-RKD patients [12], IgG4-RKD is rarely associated with nephrotic syndrome. In a previous study, IgG4-RKD patients with membranous glomerulonephritis had nephrotic syndrome [20]. However, in the present study, 3 patients underwent renal biopsy; of whom 1 had TIN and DM nephropathy, 1 had TIN alone, and 1 had no abnormal findings. Thus, none had membranous glomerulonephritis. The patient with TIN and DM nephropathy showed proteinuria and hematuria, and the patient who had TIN alone showed proteinuria.

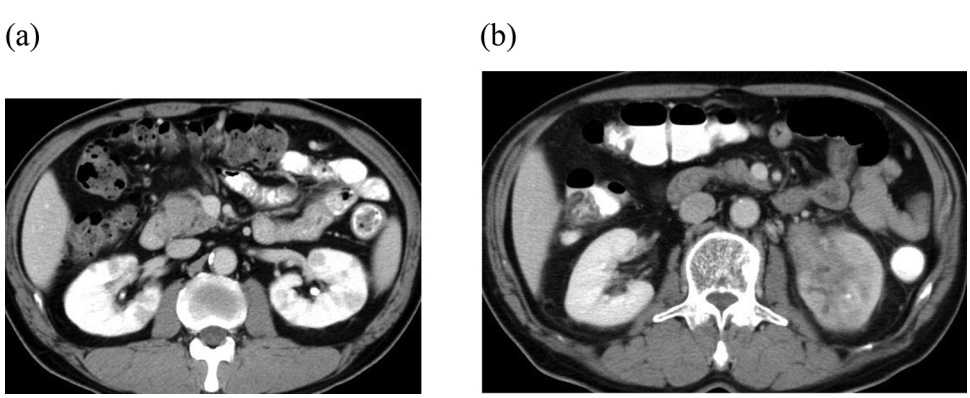

Fig. 3. Contrast-enhanced computed tomography of the kidneys in IgG4-RKD.
(a) Multiple low-density lesions and (b) Hypertrophic lesion of the renal pelvic wall, without irregularity of the renal pelvic surface.

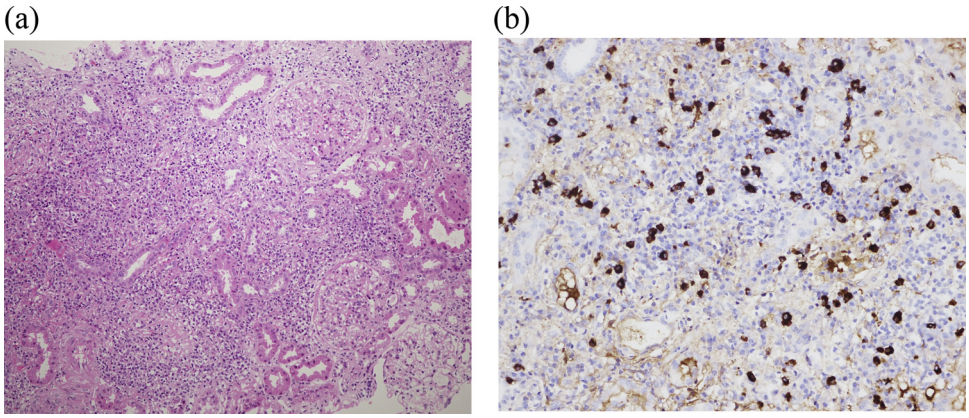

Fig. 4. Histopathological features of a renal biopsy from an IgG4-RKD patient.
(a) Tubulointerstitial nephritis (hematoxylin and eosin staining, ×100) and (b) Abundant infiltration with IgG4-positive plasma cells (IgG4-immunostaining, ×400).

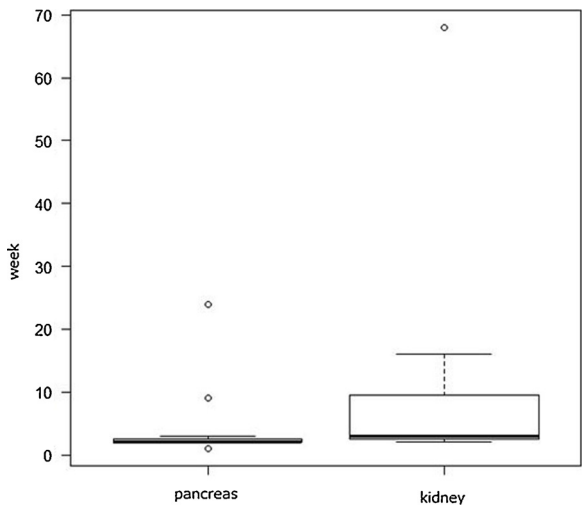

Fig. 5. Time to radiological improvement in pancreatic and renal lesions in IgG4-RKD patients after steroid therapy.

Following CT or MRI of the renal lesions in patients in the present study, 92% were categorized as Type A and one as Type D. In contrast, Kawano et al. [12] reported that, on performing a CT, 65.5% were found to be type A, 14.6% were Type D, 7.3% were Type B, and 3.4% were Type C. The radiological differential diagnosis of IgG4-RKD includes: pyelonephritis, renal infarction, and vasculitis for Type A; renal cancer, lymphoma, sarcoidosis, and granulomatosis with polyangiitis (formerly Wegener's granulomatosis) for Type C; and ureteropelvic cancer for Type D. The differential diagnosis among these diseases is made on the basis of clinical symptoms, urinary and other laboratory findings, and renal biopsy [22].

In the present study, pancreatic and renal lesions improved, as revealed on conducting a CT or MRI, in eight out of the twelve patients treated with steroids, the pancreatic lesions alone improved in 2 patients, and in 1 patient neither lesion improved. Consistent with this, Nishi et al. [17] reported that 80% of renal lesions in patients with AIP improved after steroid therapy and Takahashi et al. [10] reported that all of their 9 AIP patients showed improvement in their renal lesions, but 1 demonstrated a progressive renal lesion after cessation of the steroid therapy. Saeki et al. [23] reported that the renal radiologic features characteristic of IgG4-RKD had improved 1 month after the start of treatment in all of the 18 patients who were evaluated. In the present study, 6 out of 8 patients in the RKD-P group took 1–8 weeks to show improvement in their renal lesions, but one patient took 4 months and another one took 17 months. Concentration of serum creatinine was improved after steroid therapy in the patient whose radiological lesions took 4 months to show improvement, but it did not improve in the patient who took 17 months. Saeki et al. [23] reported that patients with IgG4-RKD showed improvements in their abnormal serological and radiological parameters 1 month after steroid therapy, and the renal function of the patients whose eGFR was under 60 ml/min before steroid therapy improved significantly afterwards. Thus, the response to steroid therapy in IgG4-RKD is good, as is for AIP, but one patient with IgG4-RKD has been reported to have required hemodialysis after steroid therapy [24]. In contrast to the observed duration of radiological improvement, improved renal function may persist for a relatively long period of time following steroid therapy.

4.1. Limitations of the study

The principal limitation of the present study is that it was retrospective. Urinary markers were measured only in some patients, and histology of the kidney was evaluated in only 3 patients. However, to our knowledge, this is the first report of the clinical differences in patients with AIP that is with and without renal lesions.

5. Conclusions

Patients with AIP and IgG4-RKD have been shown to have a significantly higher prevalence of extrapancreatic lesions other than those involving the kidneys, and their serum creatinine and urinary β2MG concentrations have been found to be significantly higher than in those without IgG4-RKD.

Conflict of interests

The authors declare no conflict of interests.

Financial disclosure

The authors have no funding to disclose.

The author contribution

Study Design: Sawako Kuruma, Terumi Kamisawa
Data Collection: Sawako Kuruma, Terumi Kamisawa, Kazuro Chiba, Masataka Kikuyama, Satomi Koizumi, Taku Tabata
Statistical Analysis: Sawako Kuruma, Terumi Kamisawa
Data interpretation: Sawako Kuruma, Terumi Kamisawa
Manuscript Preparation: Sawako Kuruma, Terumi Kamisawa
Literature Search: Sawako Kuruma, Terumi Kamisawa

References

[1] Kamisawa T, Takuma K, Egawa N, Tsuruta K, Sasaki T. Autoimmune pancreatitis and IgG4-related sclerosing disease. Nat Rev Gastroenterol Hepatol 2010;7:401–9.
[2] Shimosegawa T, Chari ST, Frulloni L, Kamisawa T, Kawa S, Mino-Kenudson M, et al. International consensus diagnostic criteria for autoimmune pancreatitis: guidelines of the International association of pancreatology. Pancreas 2011;40:352–8.
[3] Kamisawa T, Funata N, Hayashi Y, Eishi Y, Koike M, Tsuruta K, et al. A new clinicopathological entity of IgG4-related autoimmune disease. J Gastroenterol 2003;38:982–4.
[4] Stone JH, Khosroshahi A, Deshpande V, Chan JK, Heathcote JG, Aalberse R, et al. Recommendations for the nomenclature of IgG4-related disease and its individual organ system manifestations. Arthritis Rheum 2012;64:3061–7.
[5] Kamisawa T, Zen Y, Pillai S, Stone JH. IgG4-related disease. Lancet 2015;385(9976):1460–71. https://doi.org/10.1016/S0140-6736(14)60720-0.
[6] Murashima M, Tomaszewski J, Glickman JD. Chronic tubulointerstitial nephritis presenting as multiple renal nodules and pancreatic insufficiency. Am J Kidney Dis 2007;49:7–10.
[7] Nishi H, Tojo A, Onozato M, Jimbo R, Nangaku M, Uozaki H, et al. Anti-carbonic anhydrase II antibody in autoimmune pancreatitis and tubulointerstitial nephritis. Nephrol Dial Transplant 2007;22:1273–5.
[8] Uchiyama-Tanaka Y, Mori Y, Kimura T, Sonomura K, Umemura S, Kishimoto N, et al. Acute tubulointerstitial nephritis associated with autoimmune-related pancreatitis. Am J Kidney Dis 2004;43:18–25.
[9] Triantopoulou C, Malachias G, Maniatis P, Anastopoulos J, Siafas I, Papailiou J. Renal lesions associated with autoimmune pancreatitis: CT findings. Acta Radiologica 2010;6:702–7.
[10] Takahashi N, Kawashima A, Fletcher JG, Chari ST. Renal involvement in patients with autoimmune pancreatitis: CT and MR imaging findings. Radiology 2007;42(791):801.
[11] Saeki T, Nishi S, Ito T, Yamazaki H, Miyamura S, Emura I, et al. Renal lesions in IgG4-related systemic disease. Intern Med 2007;46(17):1365–71.
[12] Kawano M, Saeki T, Nakashima H, Nishi S, Yamaguchi Y, Hisano S, et al. Proposal for diagnostic criteria for IgG4-related kidney disease. Clin Exp Nephrol 2011;15:615–26.
[13] Kim B, Kim JH, Byun JH, Kim HJ, Lee SS, Kim SY, et al. IgG4-retaled kidney disease: MRI findings with emphasis on the usefulness of diffusion-weighted imaging. Eur J Radiol 2014;83:1057–62.
[14] Sahani DV, Kalva SP, Farrell J, Maher MM, Saini S, Mueller PR, et al. Autoimmune pancreatitis: imaging feature. Radiology 2004;233:345–52.
[15] Khalili K, Doyle DJ, Chawla TP, Hanbidge AE. Renal cortical lesions in patients with autoimmune pancreatitis: a clue to differentiation from pancreatic malignancy. Eur J Radiol 2008;67:329–35.
[16] Kanno A, Masamune A, Okazaki K, Kamisawa T, Kawa S, Nishimori I, et al. Nationwide epidemiological survey of autoimmune pancreatitis in Japan in 2011. Pancreas 2015;44(4):535–9.
[17] Nishi H, Shibagaki Y, Hirano K, Akahane M, Kido R, Nangaku M, et al. Laboratory and imaging features of kidney involvement in autoimmune pancreatitis: incidence, correlation, and steroid therapy response. Clin Nephrol 2010;73(4):253–9.
[18] Creswell P, Springer T, Strominger JL, Turner MJ, Grey HM, Kubo RT. Immunological identity of the small subunit of HL-a antigens and beta2-microglobulin and its turnover on the cell membrane. Proc Natl Acad Sci U S A 1974;71(5):2123–7.
[19] Wibell LB. Studies on beta2-microglobulin in patients and normal subjects. Acta Clin Belg 1976;31:14–26.
[20] Saeki T, Nishi S, Imai N, Ito T, Yamazaki H, Kawano M, et al. Clinicopathological characteristics of patients with IgG4-related tubulointerstitial nephritis. Kidney Int 2010;78:1016–23.
[21] Cornell L. IgG4-related disease. Curr Opin Nephrol Hypertens 2012;21:279–88.
[22] Inoue D, Kawano M, Yamada K, Matsui O, Gabata T. Kidney and urinary tract lesions. In: Umehara H, Okazaki K, Stone JH, Kawa S, Kawano M, editors. IgG4-related disease Japan: Springer; 2014. p. 99–105. https://doi.org/10.1007/978-4-431-54228-5_15.
[23] Saeki T, Kawano M, Mizushima I, Yamamoto M, Wada Y, Nakashima H, et al. The clinical course of patients with IgG4-related kidney disease. Kidney Int 2013;84:826–33.
[24] Saida Y, Homma N, Hama H, Ueno M, Imai N, Nishi S, et al. Case of IgG4-related tubulointerstitisal nephritis showing the progression of renal dysfunction after a cure for autoimmune pancreatitis. Nihon Jinzo Gakkai Shi 2010;52(1):73–9. (in Japanese).