Key words: acetylsalicylic acid; diclofenac; cross-reactivity; urticaria.

G. Gala*, R. Blanco, S. Quirce, I. Pérez-Camo, J. A. Alvarez-Fernández, M. L. Díez-Gómez
*Allergy Department
Hospital Ramón y Cajal
Ctra. Colmenar km 9.1
28034 Madrid
Spain

Accepted for publication 2 December 1997
Copyright © Munksgaard 1998
ALLERGY *1998:53:623–624*

REFERENCES
1. Szczeklik A. Adverse reactions to aspirin and nonsteroidal antiinflammatory drugs. Ann Allergy 1987;59:113-18.
2. Alkhawajah AM, Eifawal M, Mahmoud SF. Fatal anaphylactic reaction to diclofenac. Forensic Sci Int 1993;60:107-10.
3. Mescheder A, Nokhodian A, Kirch W. Anaphylactic shock as complication of MI application of diclofenac. Arzneimittel-therapie 1993;11:237-9.
4. Romano A, Pietrantonio F, Di Fonso M, et al. Positivity of patch tests in cutaneous reaction to diclofenac. Allergy 1994;49:57-9.
5. Gebhardt M, Reuter A, Knopf B. Allergic contact dermatitis from topical diclofenac. Contact Dermatitis 1994;30:183-4.
6. Faich G. Special report: adverse drug reaction monitoring. N Engl J Med 1986;314:1589-92.
7. Stevenson D. Diagnosis, prevention and treatment of adverse reactions to aspirin and nonsteroidal anti-inflammatory drugs. J Allergy Clin Immunol 1984;74:617-22.

Aztreonam and ceftazidime: evidence of *in vivo* cross-allergenicity

Aztreonam is a monocyclic β-lactam antibiotic which appears to lack cross-reactivity with other classes of β-lactams. Nevertheless, *in vitro* studies have shown cross-allergenicity between aztreonam and ceftazidime (1), a third-generation cephalosporin which is the only drug with the same side-chain (Fig. 1). These facts suggest that reactions to aztreonam are caused by its side-chain.

We present a case of sensitization to aztreonam with cross-reactivity to ceftazidime, proved by skin tests and tolerance of other β-lactams. No cases of *in vivo* cross-allergenicity between aztreonam and ceftazidime have been previously reported.

■ Our patient was a 57-year-old man who had had a cutaneous reaction to clindamycin 6 years before. He had a personal history of ischemic heart disease and left pneumonectomy because of cryptogenetic lung hypoplasia with recurrent respiratory infections, and this was treated with large courses of many antibiotic agents. At the moment, pleural empyema was diagnosed, and the patient was started on amoxicillin/clavulanate (1 g IV) and aztreonam (1 g IV). Two hours after receiving the first dose of both drugs, he developed a widespread pruriginous maculopapular eruption. Amoxicillin/clavulanate was stopped and aztreonam was continued, but the latter was withdrawn 2 days later because of the increase of the skin reaction. Corticosteroids and antihistamines were needed to control the reaction, which had completely disappeared after 8 days.

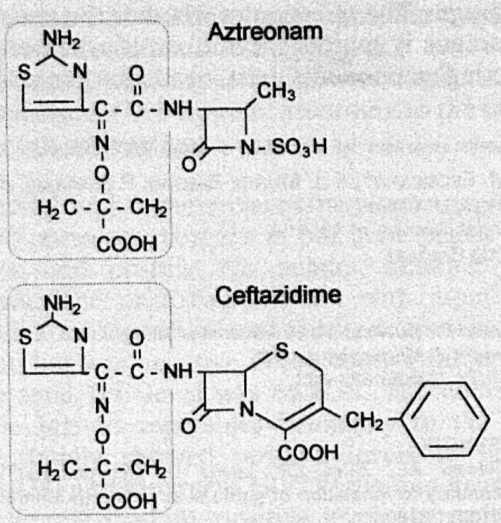

FIGURE 1 Structural formulas of aztreonam and ceftazidime.

Patients with allergic reactions to aztreonam should not be given ceftazidime.

Specific IgE was determined for penicillin and amoxicillin (Pharmacia© CAP System), and proved to be negative. Skin prick and intradermal tests were performed with penicilloyl polylysine and a minor determinant mixture (Allergopen© Merck), benzylpenicillin (10 000 UI/ml), amoxicillin (20 mg/ml), amoxicillin/clavulanate (20/5 mg/ml), cephradine (20 mg/ml), ceftazidime (20 mg/ml), and aztreonam (2 mg/ml). The results were positive with aztreonam and ceftazidime in intradermal tests, with persistence of the reaction after 24 h. We performed patch tests with amoxicillin, amoxicillin/clavulanate, ceftazidime, and aztreonam, at concentrations of 20% in vaseline, obtaining positive results with ceftazidime and aztreonam. Negative results were obtained in 10 control subjects. We performed challenge tests with amoxicillin, amoxicillin/clavulanate, and

three cephalosporins (cephradine, cefuroxime, and ceftriaxone) at therapeutic doses. These drugs were well tolerated.

From the results, a diagnosis of sensitization to aztreonam was established, and the patient was forbidden to use ceftazidime.

■ Aztreonam, the main representative of the monocyclic β-lactam antibiotics (monobactams), is known to cause IgE-mediated reactions (urticaria/angioedema, anaphylaxis) (2, 3), even on the first exposure (4). Other adverse reactions are rash, eosinophilia, gastrointestinal disorders, elevation of liver enzymes, and erythema multiforme.

Aztreonam has been found to be well tolerated by subjects allergic to other β-lactam antibiotics (5), and to be only weakly immunogenic (1). A few cases of sensitization to aztreonam and good tolerance of other β-lactam antibiotics (including ceftazidime) have been reported (2, 3). In *in vitro* studies, cross-reactivity between aztreonam and ceftazidime has been described (1), although we have not found previous cases of cross-allergenicity proved by *in vivo* testing (intradermal and patch test) in the scientific literature.

The patient's tolerance of amoxicillin, cephradine, cefuroxime, and ceftriaxone supports the hypothesis of the side-chain implication.

We recommend that ceftazidime be prohibited in cases of allergic reaction to aztreonam, at least before performing skin tests, because of the evidence of cross-reactivity.

Key words: aztreonam; ceftazidime; cross-reactivity.

A. Pérez Pimiento*, M. Gómez Martínez, A. Mínguez Mena, A. Trampal González, S. de Paz Arranz, M. Rodríguez Mosquera
*Servicio de Alergia
Clínica Puerta de Hierro
C/ San Martín de Porres, 4
28035 Madrid
Spain

Accepted for publication 2 December 1997
Copyright © Munksgaard 1998
ALLERGY *1998:53:624–625*

REFERENCES

1. Adkinson NF Jr. Immunogenicity and cross-allergenicity of aztreonam. Am J Med 1990;88 Suppl 3C:12S-15S.
2. de la Fuente Prieto R, Armentia Medina A, Sánchez Palla P, Díez Pérez JM, Sanchís Merino ME, Fernández Garcia A. Urticaria caused by sensitization to aztreonam. Allergy 1993;48:634-6.
3. Iglesias Cadarso A, Sáez Jiménez SA, Vidal Pan C, Rodríguez Mosquera M. Aztreonam-induced anaphylaxis. Lancet 1990;336:746-7.
4. Soto Álvarez J, Sacristán Del Castillo JA, Sampedro García Y, Alsar Ortiz MJ. Immediate hypersensitivity to aztreonam. Lancet 1990;335:1094.
5. Vega JM, Blanca M, García JJ, et al. Tolerance to aztreonam in patients allergic to betalactam antibiotics. Allergy 1991;46:196-202.

Eczema-like plaques to enoxaparin

Rarely, immunologically mediated hypersensitivity reactions to heparins can occur. We present a patient who developed infiltrated, eczematous plaques at the sites of subcutaneous injections of enoxaparin.

A 50-year-old nonsmoker woman, with no personal or family history of allergy, underwent total vaginal hysterectomy because of uterine prolapse. Some years before, the patient had had two operations, one for kidney stones and the other for venous insufficiency. During admission for hysterectomy, the patient was treated with prophylactic sodium enoxaparin (Clexane 20), once a day, injected subcutaneously in the abdominal wall. Three days after beginning this therapy, the patient complained of itching and tightness at the sites where heparin was injected. Clinical examination revealed four 3–5-cm erythematous and infiltrated plaques (Fig. 1). No systemic reaction was observed. Skin biopsy of one of these lesions showed spongiotic dermatitis. Treatment with topical corticosteroids was established. Recovery was complete in 7 days. One month later, an allergologic study was performed. Patch tests with the standard contact antigen panel of the Spanish Contact Dermatitis Research Group, vehicle and drug series, were positive for nickel sulfate and miconazole. Patch tests using enoxaparin, as is, in the Finn-chamber, and Leukotest showed eczematous changes at 48 and 96 h. Prick and intradermal tests with sodium enoxaparin 5000 and 500 UI/ml, calcium nadroparin 10 000 and 1000 UI/ml, and sodium heparin 5000 and 500 UI/ml were carried out on the volar surface of the forearm. For intradermal tests, 0.02 ml of each substance was injected with 1 ml insulin syringes and 25-gauge needles, giving a bleb approximately 3 mm in diameter. Readings were done at 15 min, and 1, 24, and 72 h in order to rule out immediate or late responses. Immediate (15 min) and 1-h readings were negative for all substances. At 24 h, intradermal tests with sodium enoxaparin 5000 and 500 UI/ml and calcium nadroparin 10 000 UI/ml showed positive erythe-

A case of delayed hypersensitivity with cross-reactions to nadroparin and sodium heparin.

This document is a scanned copy of a printed document. No warranty is given about the accuracy of the copy. Users should refer to the original published version of the material.