CLINICAL REPORT

Toxic Epidermal Necrolysis Following Allergic Contact Dermatitis Caused by Occupational Exposure to Ultraviolet-cured Inks

Toshiko IDO[1], Takahiro KIYOHARA[1], Hidenori TAKAHASHI[1], Yuka YAMAGUCHI[1], Daisuke TANI[2] and Masanobu KUMAKIRI[1]
[1]*Department of Dermatology, Faculty of Medical Sciences, University of Fukui, Fukui and* [2]*Department of Pharmacy, Osaka Red Cross Hospital, Osaka, Japan*

Erythema multiforme is a relatively common skin disorder; the most common cause is herpes simplex infection, but topical sensitivities reportedly also provoke this reaction. We report here a case that progressed to toxic epidermal necrolysis due to contact with ultraviolet (UV)-cured inks. The diagnosis was confirmed by patch tests to acrylates in the UV-cured inks, histopathological studies of the lesions, and positive patch test to 1,6-hexanediol diacrylate. ***Key words: toxic epidermal necrolysis; allergic contact dermatitis; erythema multiforme; 1,6-hexanediol diacrylate; ultraviolet-cured ink.***

(Accepted August 22, 2011.)

Acta Derm Venereol 2011; 91: XX–XX.

Takahiro Kiyohara, Department of Dermatology, Faculty of Medical Sciences, University of Fukui, 23-3 Shimoaizuki, Matsuoka, Eiheiji-Cho, Yoshida-Gun, Fukui 910-1193, Japan. E-mail: kiyo@u-fukui.ac.jp

Erythema multiforme (EM), Stevens-Johnson syndrome (SJS) and toxic epidermal necrolysis (TEN) evolving from contact dermatitis are rare, but may be caused by occupational exposure to chemicals (1–5), or by various allergens, such as nickel, rubber, *Primula obconica*, poison ivy, hair dye, and topical medications. We report here a case of occupational allergic contact dermatitis due to ultraviolet (UV)-cured inks that led to TEN.

CASE REPORT

A 33-year-old woman presented with severe diffuse erythema and blisters with a target-like aspect on her face, extremities and trunk. She had no history of drug intake, atopic dermatitis, herpes simplex or other infectious disease during the previous months. For the preceding 16 days she had worked in the printing industry. Although she had worn goggles, gloves, and protective clothing, her face and arms had come into contact with UV-cured inks, and her clothing had become soaked in the inks. After one week of work, she had developed erythema with itching on her arms and face. She was treated with topical glucocorticoid ointment by a dermatologist, but the erythematous papulo-vesicles worsened over the area contacted by the inks. Subsequently, she developed multiple dull-red macules with target-like configurations on the unexposed areas, and diffuse erythema and blisters on the extremities, face and abdomen. She was treated by oral administration of 30 mg/day prednisolone for 3 days, but the lesions progressed until bulla and erosion involved more than 30% of the body surface, although there was no sign of mucosal involvement (Fig. 1). On blood examination, there was moderate leukocytosis (12,100/µl) with an increase in eosinophilia (1,742/µl). Renal and liver function tests were normal. C-reactive protein was mildly elevated at 0.47 mg/dl (normal <0.32 mg/dl). Total serum immunoglobulin E was 481 U/ml, and antinuclear antibodies were normal.

Fig. 1. Confluent erythema with bullae and satellite target lesions on the upper extremities.

The patient was admitted to our hospital, and received oral administration of 70 mg/day prednisolone. Her skin lesions gradually improved, and prednisolone was tapered and then withdrawn completely after 2 weeks.

A provisional diagnosis of TEN-like contact dermatitis due to UV-cured inks was made. To confirm this

© 2012 The Authors. doi: 10.2340/00015555-1255
Journal Compilation © 2012 Acta Dermato-Venereologica. ISSN 0001-5555

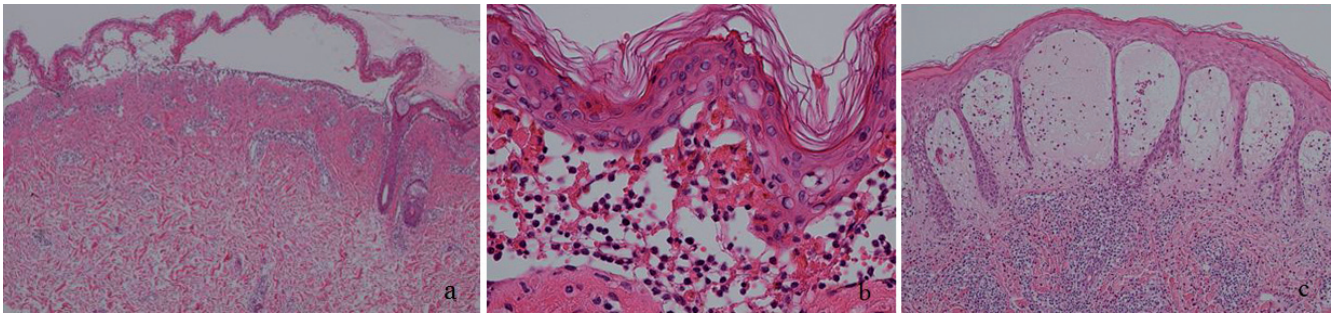

Fig. 2. Skin specimen from a blister on the upper arm stained with haematoxylin and eosin showed subepidermal blister and interface and perivascular lymphocytes (a, original magnification ×40) and vacuolar changes in the basal keratinocytes, necrotic keratinocytes in the basal and upper epidermis (b, original magnification ×400). Histopathological evaluation of the positive patch test to 1,6-hexanediol diacrylate (HDDA) (1% in petrolatum) demonstrated pronounced oedema of the papillary dermis resulting in subepidermal blisters (c, original magnification ×200).

diagnosis, skin biopsies and patch tests were performed. Histopathological evaluation of a biopsy taken from a blister on her upper arm demonstrated subepidermal blister, vacuolar changes in the basal keratinocytes, necrotic keratinocytes in the basal and upper epidermis, and interface and perivascular lymphocytes (Fig. 2a, b). She was patch-tested with a Japanese standard allergen series and photopatch-tested with 8 ingredients of the UV-cured inks provided by the manufacturers.

The patch testing and reading were carried out according to the International Contact Dermatitis Research Group (ICDRG) recommendations using Finn Chambers® (Epitest Ltd Oy, Tuusula, Finland) and Scanpor® (Norgesplaster A/S, Oslo, Norway) tape. Duplicate allergens for photopatch tests were applied to the back, and one set was irradiated on day one with 5 J/cm^2 fluorescent UV-A using Dermaray® (Terumo Clinical Supply, Gifu, Japan). Reading was performed after removal of the control set on days 2, 3 and 7. The patch tests with 1,6-hexanediol diacrylate (HDDA) (0.1% and 1% in petrolatum), urethane acrylate and HDDA blend (1% in petrolatum) and propoxylated neopentyl glycol diacrylate (0.1% and 1% in petrolatum) showed positive reactions, but there were no positive reactions to any of the other 5 ingredients of the inks (Table I). None of the ingredients of the inks showed a photoaugmentation. A positive reaction to nickel sulphate (2.5% in petrolatum) was also obtained. There was no positive reaction on patch-testing to any of the other allergens in the Japanese standard series, including epoxy resin. Eight days after patch testing, an extreme positive reaction to HDDA persisted. There were bullae on the patch test site, but no target lesions were identified. A biopsy of the site of this positive patch test to HDDA (1% in petrolatum) showed pronounced oedema of the papillary dermis, resulting in subepidermal blisters, spongiosis, and perivascular infiltrate composed of lymphocytes containing eosinophils (Fig. 2c). Two healthy volunteers were patch-tested with all ingredients of the inks (0.1% and 1% in petrolatum) with negative results.

Based on her clinical history, histopathological findings, and positive patch tests to the UV-cured inks, we concluded that the occupational allergic contact dermatitis due to the inks led to TEN. Thereafter, the patient stopped working in the printing industry. There has not been any recurrence for 6 months.

DISCUSSION

EM induced by contact dermatitis is rare and has been reported to be caused by contact with plant allergens, metals, topical medications, cosmetics and occupational exposure to chemicals (5). In those cases, EM ranged from mild localized exanthema to generalized EM or even TEN (1–4). The present case illustrates the occurrence of EM following contact dermatitis in a woman sensitized to UV-cured inks. Notably, the lesions in this case progressed to TEN. Histopathological findings of bullous lesions support the diagnosis of TEN. There were vacuolar changes in the basal keratinocytes, satellite cell necrosis, necrotic keratinocytes in the upper epidermis, and subepidermal blister formation.

The pathogenesis of EM in relation to allergic contact dermatitis remains unclear. In several reported cases, the histopathological findings of EM following contact der-

Table I. *Results of patch tests (PT) and photo patch tests (PTT)*

Materials	Conc./ vehicle (% pet)	48 h		72 h		1 week	
		PT	PPT	PT	PPT	PT	PPT
Japanese allergen set							
Nickel sulphate	2.5	+	NT	+	NT	–	NT
Other 24 allergen		–	NT	–	NT	–	NT
Ingredients of UV-cured inks							
1,6-hexanediol diacrylate	1	+	+	++	++	+++	+++
(HDDA)	0.1	–	–	+	+	+	+
	0.01	–	–	–	–	–	–
HDDA and urethane	1	+	+	+	+	+	+
acrylate blend	0.1	–	–	–	–	–	–
	0.01	–	–	–	–	–	–
Propoxylated neopentyl	1	+	+	++	++	++	++
glycol diacrylate	0.1	–	–	+	–	+	–
	0.01	–	–	–	–	–	–
Other five ingredients		–	–	–	–	–	–
Petrolatum (control)	As is	–	–	–	–	–	–

matitis were indistinguishable from typical EM following herpes simplex virus infection (6). Although these were EM-like lesions induced by contact dermatitis, presenting clinically as "targeted" lesions typical of EM, there were histopathological signs of spongiotic dermatitis (7). Interestingly, in several reported cases of contact EM, biopsy specimens from positive patch test sites demonstrated various changes, spongiotic dermatitis, vacuolar changes in the basal keratinocytes, and oedema of the papillary dermis, with dilated vessels surrounded by perivascular infiltrate (8–10). Histopathological examination of the site of the positive (3+) patch test to HDDA showed pronounced oedema of the papillary dermis, resulting in subepidermal blisters in our case. These histopathological changes were compatible with EM, dermal type. A review of many cases of typical EM with multiple biopsies has shown that some biopsy specimens demonstrated predominantly dermal changes, and biopsies of target lesions occasionally showed epidermal necrosis in the centre and dermal changes at the periphery (11).

Histopathological studies of the lesions and histopathological studies of the site of the positive patch test to HDDA both support the diagnosis of EM and TEN. To the best of our knowledge, this is the first reported case of TEN that was associated with UV-cured inks containing HDDA, urethane acrylate, and propoxylated neopentyl glycol diacrylate.

The use of UV-cured inks and coatings has increased in the printing industry (12). Occupational allergic contact dermatitis in printers due to UV-cured inks has been reported previously (12–14). HDDA has also been shown to be a strong sensitizer in the guinea pig maximization test (15). Botella-Estrada et al. (13) reported that 0.1% pet of HDDA was not an irritant after patch testing in 20 controls. Two volunteers were patch-tested with 1% pet and 0.1% pet of HDDA, the blend, and propoxylated neopentyl glycoldiacrylate, with negative results in our case. We excluded the possibility of irritation as the cause of the positive reaction in the patient based on these results. Our case was also sensitive to propoxylated neopentyl glycol diacrylate. Allergy developing from propoxylated neopentyl glycol diacrylate has not been reported previously. Nethercott et al. (14) reported five cases of allergic contact dermatitis due to urethane acrylate in UV-cured inks. Our case showed positive patch test results to HDDA and urethane acrylate blend, but we could not confirm contact allergy to pure urethane acrylate.

Printers are at high risk of developing occupational dermatitis, as they are exposed to a variety of irritants and sensitizers, including multifunctional acrylates in UV-cured inks. The present case showed that there is a strong allergen in UV-cured inks that can induce allergic contact dermatitis and typical findings of EM, which progresses to TEN. We recommend that all workers in the printing industry should avoid repeated exposure to acrylates.

The authors declare no conflict of interest

REFERENCES

1. Thompson JA Jr, Wansker BA. A case of contact dermatitis, erythema multiforme, and toxic epidermal necrolysis. J Am Acad Dermatol 1981; 5: 666–669.
2. Inamadar AC, Palit A. Cutaneous reactions simulating erythema multiforme and Stevens Johnson syndrome due to occupational exposure to a plant-growth regulator. Indian J Dermatol Venereol Leprol 2007; 73: 330–332.
3. Toyama T, Matsuda H, Ishida I, Tani M, Kitaba S, Sano S, et al. A case of toxic epidermal necrolysis-like dermatitis evolving from contact dermatitis of the hands associated with exposure to dendrimers. Contact Dermatitis 2008; 59: 122–123.
4. Aoyama Y, Kouchi K, Hiramitsu Y, Hiramitsu Y, Iwata H, Kitajima Y. Generalized eruption with histopathological toxic epidermal necrolysis caused by occupational exposure to thiourea dioxide. Eur J Dermatol 2009; 19: 509–511.
5. Wiedemeyer K, Enk A, Jappe U. Erythema multiforme following contact dermatitis: case report and literature review. Acta Derm Venereol 2007; 87: 559–561.
6. Puig L, Fernandez-Figueras MT, Montero MA, Ferrandiz C, Alomar A. Erythema-multiforme-like eruption due to topical contactants: expression of adhesion molecules and their ligands and characterization of the infiltrate. Contact Dermatitis 1995; 33: 329–332.
7. Lachapelle JM. The spectrum of disease for which patch testing is recommended. In: Lachapelle JM, Maibach HI editors. Patch testing and prick testing. A practical guide official publication of the ICDRG, 2nd edn. Berlin: Springer-Verlag, 2009: p. 7–32.
8. Athanasiadis GI, Pfab F, Klein A, Braun-Falco M, Ring J, Ollert M. Erythema multiforme due to contact with laurel oil. Contact Dermatitis 2007; 57: 116–118.
9. Khanna M, Qasem K, Sasswville D. Allergic contact dermatitis to tea tree oil with erythema multiforme-like id reaction. Am J Contact Dermat 2000; 11: 238–242.
10. Koch P, Bahmer FA. Erythema multiforme-like, urticarial papular and plaque eruptions from bufexamac: report of 4 cases. Contact Dermatitis 1994; 31: 97–101.
11. Howland WW, Golitz LE, Weston WL. Erythema multiforme: clinical, histopathologic, and immunologic study. J Am Acad Dermatol 1984; 10: 438–446.
12. Morgan VA, Fewings JM. 1,6-Hexanediol diacrylate: a rapid and potent sensitizer in the printing industry. Australas J Dermatol 2000: 41: 190–192.
13. Botella-Estrada R, Mora E, de la Cuadra J. Hexandiol diacrylate sensitization after accidental occupational exposure. Contact Dermatitis 1992; 26: 50–51.
14. Nethercott JR, Jakubovic HR, Pilger C, Smith JW. Allergic contact dermatitis due to urethane acrylate in ultraviolet cured inks. Br J Indust Med 1983; 40: 241–250.
15. Bjorker B. The sensitization capacity of multifunctional acrylates in the guinea pig. Contact Dermatitis 1984; 11: 236–246.