Pathology International

Pathology International 2010; **60**: 247–258 doi:10.1111/j.1440-1827.2010.02524.x

Review Article

IgG4-related disease: Historical overview and pathology of hematological disorders

Yasuharu Sato,[1,*] Kenji Notohara,[2,*] Masaru Kojima,[3,*] Katsuyoshi Takata,[1] Yasufumi Masaki[4] and Tadashi Yoshino[1]

[1]*Department of Pathology, Okayama University Graduate School of Medicine, Dentistry and Pharmaceutical Sciences, Okayama,* [2]*Department of Pathology, Kurashiki Central Hospital, Kurashiki,* [3]*Department of Anatomic and Diagnostic Pathology, Dokkyo University School of Medicine, Mibu and* [4]*Department of Hematology and Immunology, Kanazawa Medical University, Kahoku, Japan*

IgG4-related diseases comprise a recently recognized systemic syndrome characterized by mass-forming lesions in mainly exocrine tissue that consist of lymphoplasmacytic infiltrates and sclerosis. There are numerous IgG4-positive plasma cells in the affected tissues, and the serum IgG4 level is increased in these patients. The present study describes the history, autoimmune pancreatitis (AIP), IgG4-related lymphadenopathy and lymphomagenesis based upon ocular adnexal IgG4-related disease. Lymphoplasmacytic sclerosing pancreatitis, a prototypal histological type of AIP, is now recognized as a systemic IgG4-related disease. Lymph node lesions can be subdivided into at least five histological subtypes, and systemic IgG4-related lymphadenopathy should be distinguished from multicentric Castleman's disease. Interleukin-6 and CRP levels are abnormally high in multicentric Castleman's disease, but are normal in the majority of systemic IgG4-related lymphadenopathy. Ocular adnexal IgG4-related disease frequently involves bilateral lacrimal glands swelling, and obliterative phlebitis is rare. Moreover, some malignant lymphomas, especially mucosa-associated lymphoid tissue lymphoma, arise from ocular adnexal IgG4-related disease. In addition, IgG4-producing lymphoma also exists.

Key words: autoimmune pancreatitis, IgG4, lymph node, mucosa-associated lymphoid tissue lymphoma, ocular adnexa

IgG4 is a minor component of the four subclasses of IgG in serum. Sporadic examples, such as IgG4 autoantibodies present in patients with autoimmune bullous skin diseases[1–3] and deposition of IgG4 seen in membranous nephropathy,[4] had indicated that IgG4 might be pathogenetically related to some diseases. But little attention has been paid to this minor component of IgG since Hamano *et al.* found elevated serum IgG4 level in patients with autoimmune pancreatitis (AIP).[5] This was the beginning of the use of IgG4 as a serological marker for a specific disease, and nowadays serum IgG4 is acknowledged as an important serological test for making a diagnosis of AIP and other related diseases. The same group also reported that numerous IgG4-positive plasma cells were characteristically observed in pancreatic tissues with AIP.[6] This perception facilitated the identification of numerous extrapancreatic diseases that were potentially related to AIP pathogenetically, and more importantly triggered a reclassification of pre-existing entities. These diseases are now grouped together and called IgG4-related diseases, and the number of constituents in this category is still increasing.

This review article first focuses on how the concept of IgG4-related diseases emerged by reviewing the history, and debates the pathology of AIP, with special references to the lymph nodal lesion and lymphomagenesis of the ocular adnexal region.

HISTORICAL PERSPECTIVES OF AUTOIMMUNE PANCREATITIS AND IgG4-RELATED DISEASES

Pathology of AIP and its relationship to IgG4

The concept of AIP was proposed by Yoshida *et al.* in 1995.[7] According to their description and other reports mainly from Japan, AIP is common in elderly men. The chief complaint is usually mild abdominal symptoms or obstructive jaundice. Diabetes mellitus is commonly associated with this. Some patients are asymptomatic. Severe abdominal pain is exceptional. Radiologically, the affected pancreas has diffuse or focal swelling and irregular narrowing of the main pancreatic

Correspondence: Tadashi Yoshino, MD, PhD, Department of Pathology, Okayama University Graduate School of Medicine, Dentistry and Pharmaceutical Sciences, 2-5-1 Shikata-cho, Kita-ku, Okayama 700-8558, Japan. Email: yoshino@md.okayama-u.ac.jp

*These authors contributed equally to this work.

Received 28 October 2009. Accepted for publication 20 December 2009.

© 2010 The Authors
Journal compilation © 2010 Japanese Society of Pathology

duct. Thus from the clinical standpoint, it is difficult to distinguish AIP from pancreatic carcinoma, and many resections had been performed for suspected carcinoma before this entity was recognized. Serology often indicated hypergammaglobulinemia, elevated IgG level and the presence of various autoantibodies, such as antinuclear antibody and rheumatoid factor. Characteristically, serum IgG4 level is often elevated. Notably, corticosteroid treatment is effective, and its effect is usually evident in a few weeks. From these observations, autoimmune mechanism has been considered to play a role in this condition, which led to the term AIP.

The histological feature of AIP is diffuse lymphoplasmacytic infiltration and fibrosis. It is pathologically so peculiar among inflammatory conditions of the pancreas that, indeed, there had been some sporadic reports on pathology dealing with this topic even before the concept of AIP was proposed, such as chronic inflammatory sclerosis of the pancreas,[8] lymphoplasmacytic sclerosing pancreatitis (LPSP),[9] non-alcoholic duct destructive chronic pancreatitis[10] and inflammatory pseudotumor.[11] As the concept of AIP had been gradually accepted among clinicians, and it has become recognized that lymphoplasmacytic infiltration with fibrosis was a histological characteristic of AIP, these pathological concepts were regarded as equivalent to AIP. It should be noted, however, that there are some differences among these reports. For example, patients with chronic inflammatory sclerosis complained of severe abdominal pain and died of cachexia, which is unusual for the current concept of AIP.[8] According to studies of non-alcoholic duct destructive chronic pancreatitis, neutrophilic infiltration in interlobular ducts was common, although this is not a feature of LPSP.[5,10]

After 2000, some groups argued that what was clinically diagnosed as AIP was not pathologically a single entity, but consisted of at least two different groups. A group from Mayo Clinic conducted a retrospective study with resected pancreata with a diagnosis of pancreatitis, and concluded that, in addition to a group that corresponded to LPSP, there was a group designated as idiopathic duct-centric chronic pancreatitis (IDCP).[12] A similar observation was also reported from Europe and Massachusetts General Hospital.[13–15]

LPSP is a histologically unique lesion that was proposed by Kawaguchi *et al.* in 1991.[9] It consists of diffuse lymphoplasmacytic infiltration and fibrosis that focally gives rise to a swirling pattern (storiform fibrosis; Fig. 1a). Eosinophils can be observed, but neutrophils are absent. Pancreatic lobules are relatively well preserved compared to alcoholic chronic pancreatitis, but focal destruction of pancreatic acini and replacement with fibrosis are commonly seen. The same inflammatory process is characteristically observed around the main and interlobular ducts, leaving the duct epithelium and lumen intact (Fig. 1b). It appears as if the duct wall is thickened with inflammation. Veins are almost always obliterated by the same inflammatory process (obliterative phlebitis; Fig. 1c). Splenic vein and even portal vein may be involved, which makes surgeons suspect that they are dealing with an inoperative carcinoma. The common bile duct is also often inflamed. This is the main cause of jaundice seen in patients with AIP. Numerous IgG4-positive plasma cells are identified in LPSP (Fig. 1d).[16,17]

Another group, designated as IDCP, is characterized by inflammation centered on the duct epithelium.[12,13,15] Neutrophilic infiltration in the main and/or interlobular ducts is characteristic, and is seen within the epithelium and lumen (Fig. 2). This finding is called 'granulocytic epithelial lesion' by the European group.[13] Duct epithelium shows destructive and regenerative changes, and, due to the inflammation, the lumen looks stenotic or tortuous. A band of lymphocytes and plasma cells surrounds the lumen but, in contrast to LPSP, the ductal lesion lacks the appearance of a thickened wall. Sometimes the entire duct appears to be entrapped within an aggregate of inflammatory cells (Fig. 2a). When the inflammation is severe, pancreatic lobules are also inflamed with neutrophils, lymphocytes and plasma cells. Microabscesses may be encountered. Although there is fibrosis around pancreatic lobules, inflammatory cells are scarce within fibrosis itself, in contrast to LPSP, in which inflammatory cells are numerous within fibrosis. Obliterative phlebitis is rare, and inflammation of the common bile duct is less common compared to LPSP. IgG4-positive plasma cells are usually few in IDCP.[17]

The clinical features of LPSP are concordant with those of AIP reported from Japan, described previously.[12] Serum IgG4 is elevated in 80% of AIP patients in Japan, which correlates well with numerous IgG4-positive plasma cells seen in LPSP. In contrast, patients with IDCP are younger than LPSP patients, and many of them are younger than 40 years.[12] There is no gender preponderance. Obstructive jaundice is less common in IDCP than in LPSP. The association of inflammatory bowel disease (IBD) is found in IDCP, but extrapancreatic manifestations seen in LPSP, which are described in the following section, are rare. Notably, IDCP is rare in Japan.[18]

Both LPSP and IDCP share some clinicopathological features. There has been a debate therefore on whether these two pathological groups are different manifestations of a single entity of AIP, or whether they are different clinicopathological entities. The controversy is due to the variety of AIP diagnostic criteria proposed by different groups. The diagnostic criteria from Japan,[19] Korea,[20] Asia[21] and Mayo Clinic[22] define LPSP as the pathological entity of AIP, but other groups include both LPSP and IDCP in AIP.[13,15,23] Considering the demographic and clinical differences as well as different immunoreactivity for IgG4, however, the idea that LPSP and IDCP are different is gradually gaining acceptance. Recently, new terms, type 1 and type 2 AIP, which correspond to LPSP and IDCP, respectively, have been proposed from the West.[24] It is important to note that, among these two groups, only

© 2010 The Authors
Journal compilation © 2010 Japanese Society of Pathology

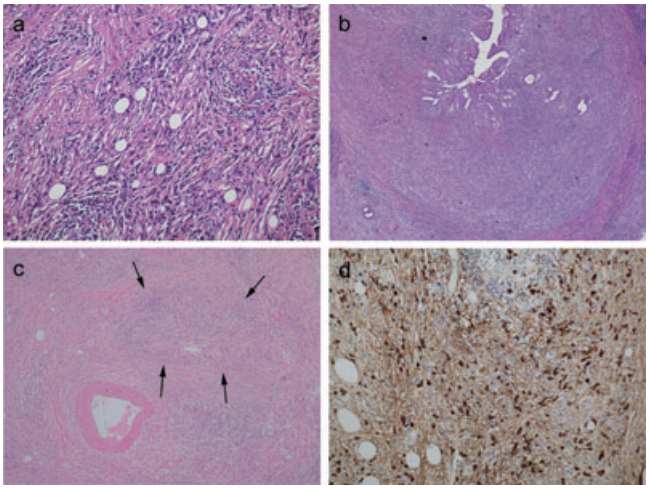

Figure 1 Lymphoplasmacytic sclerosing pancreatitis. (**a**) Lymphoplasmacytic infiltration and fibrosis giving rise to storiform fibrosis. (**b**) Ductal inflammation around the intact epithelium. The duct wall appears to be thickened with the inflammation. (**c**) Obliterative phlebitis (arrow). (**d**) Numerous IgG4-positive plasma cells are identified on immunostaining.

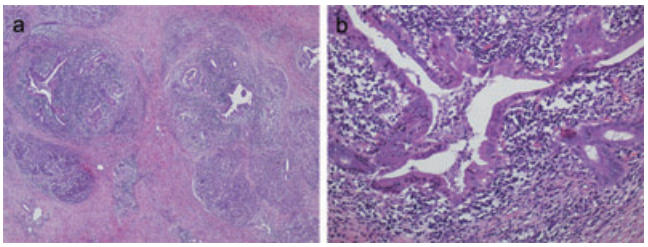

Figure 2 Idiopathic duct-centric chronic pancreatitis. (**a**) Duct-centric inflammation. Two ducts shown here are entrapped within an aggregate of inflammatory cells. (**b**) Neutrophilic infiltration in the duct lumen.

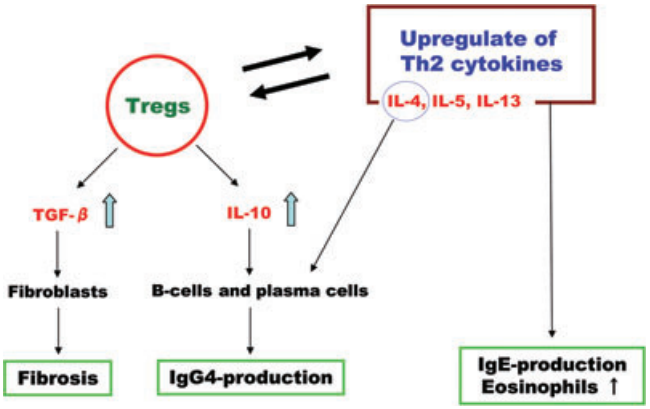

Figure 3 IgG4-related disease: hypothesis of the pathogenesis. The expression of T-helper cell 2 (Th2) cytokines (interleukin (IL)-4, IL-5, and IL-13) and regulatory cytokines (IL-10 and transforming growth factor (TGF)-β) was upregulated in the affected tissues of patients with IgG4-related diseases, suggesting that this disease might reflect an allergic mechanism in its pathogenesis. Tregs, regulatory T cell.

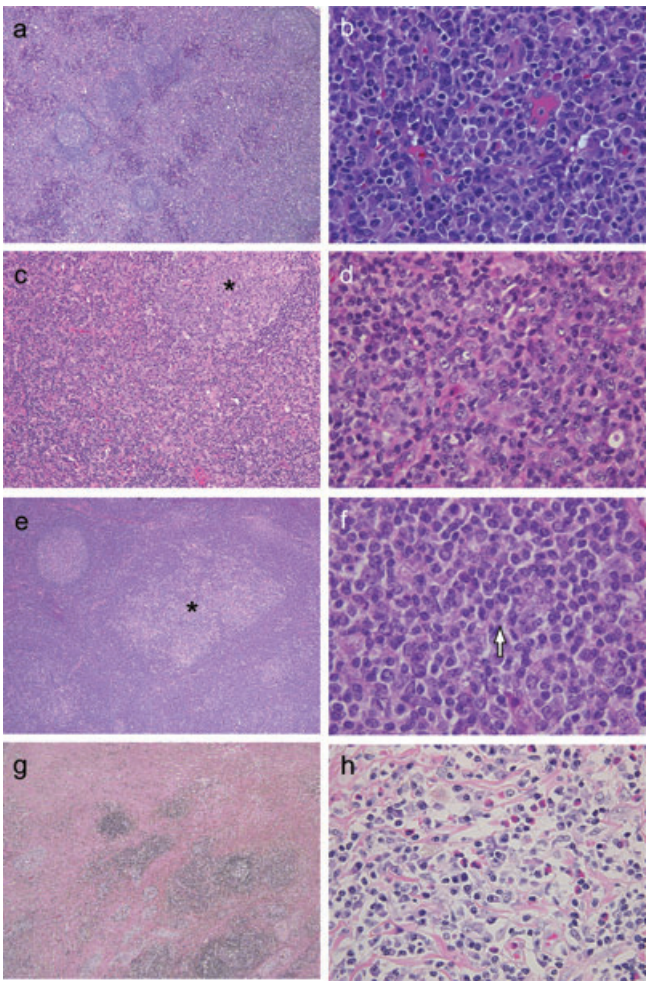

Figure 4 (**a**) Type I lesion. On low-power field, the lymph node demonstrated numerous lymphoid follicles with active germinal centers and distinct mantle zone and expansion of the interfollicular area. The interfollicular area contained a moderate number of capillaries. (**b**) Type I lesion. On high-power field, the interfollicular area was heavily infiltrated by mature plasma cells, plasmacytoid cells and small lymphocytes. Scattered medium-sized lymphocytes, transformed lymphocytes including immunoblasts and eosinophils were also present. (**c**) Type III lesion. On medium-power field, the lymph node demonstrated an active germinal center (*) with a distinct mantle zone, and expansion of the interfollicular area containing moderate vascularization. (**d**) Type III lesion. On high-power field, the paracortical area contained numerous mature plasma cells, plasmacytoid cells, immunoblasts, small and medium-sized lymphocytes and histiocytes. Note an eosinophil. (**e**) Type IV lesion. On low-power field a large early stage progressive transformation of germinal center (*) is surrounded by secondary lymphoid follicles. (**f**) Type IV lesion. On high-power field, a relatively large number of residual centrocytes, centroblasts and immunoblasts are present, in addition to the small mantle zone lymphocytes. Note a few mature plasma cells (arrow). (**g**) Type V lesion. On low-power field, the majority of the lymph nodes were occupied by the hyalinized tissue, and a few residual lymphoid follicles and a focally dense lymphoid infiltrate were observed. (**h**) Type V lesion. On high-power field, mature plasma cells, small lymphocytes and eosinophils focally infiltrated in the sclerosing tissue.

© 2010 The Authors
Journal compilation © 2010 Japanese Society of Pathology

LPSP should be regarded as the pancreatic manifestation of IgG4-related diseases.

Concept of IgG4-related disease

Kawaguchi *et al.* suggested that LPSP was a systemic disease.[9] In addition to the pancreas, their patients had involvements in the extrahepatic bile duct, gallbladder and labial gland, and all lesions showed histological similarity to LPSP. They further noted that LPSP histologically resembled multifocal fibrosclerosis. Multifocal fibrosclerosis is an entity that includes systemic diseases, such as 'primary sclerosing cholangitis' (PSC), retroperitoneal fibrosis, Riedel thyroiditis and orbital pseudotumor. Association of 'pancreatic pseudotumors' has also been reported.[25] Notably, obliterative phlebitis, one of the unique features of LPSP, has been reported to occur in multifocal fibrosclerosis.[26–29] Ever since AIP was recognized as an entity, it has become well realized among clinicians that extrapancreatic lesions are common in AIP patients. According to a recent report, pulmonary hilar lymphadenopathy, bile duct lesions, lacrymal and salivary gland lesions, hypothyroidism and retroperitoneal fibrosis are commonly seen in Japanese patients with AIP,[30] suggesting the analogy of LPSP and multifocal fibrosclerosis. Curiously, an association with Riedel thyroiditis has been rarely reported in AIP, but the reason is not known.

On immunohistochemistry, Hamano *et al.* identified numerous IgG4-positive plasma cells in the retroperitoneal fibrosis seen in AIP patients.[6] Kamisawa *et al.* extended the observation, and reported that IgG4-positive plasma cells are increased systemically in patients with AIP.[31] They concluded that AIP patients have a systemic disease, and proposed the entity 'IgG4-related sclerosing disease'.[32] More recent entities, such as IgG4-related plasmacytic exorinopathy[33] and IgG4-positive multiorgan lymphoproliferative syndrome,[34] are synonymous.

The histological features and numerous IgG4-positive cells are unique to LPSP. Using these morphological and immunohistochemical features as a hallmark, Zen *et al.* proposed new concepts of IgG4-related diseases in various organs.[35–40] This is not merely a proposal of new concepts, but a reclassification of pre-existing entities. In addition, the recognition of these new entities is important from the clinical standpoint as well, because many of these lesions involve a mass that is clinically suspicious for malignant diseases, and nevertheless they are responsive to corticosteroid therapy. For example, IgG4-related sclerosing cholangitis had been diagnosed as PSC before this entity was recognized,[35] but the histological finding is different from classic PSC.[35] IgG4-related sclerosing cholangitis produces changes that are histologically similar to LPSP including numerous IgG4-positive plasma cells, while in classic PSC, the inflammation is centered on the bile duct epithelium, and IgG4-positive plasma cells are usually few. Importantly, IgG4-related sclerosing cholangitis is common in elderly men, in a similar fashion to LPSP. Classic PSC is well known to be associated with IBD, but such an association is rare in IgG4-related sclerosing cholangitis. The radiological features of the two are also different.[41] Corticosteroid treatment is effective for patients with IgG4-related sclerosing cholangitis, while there is no such indication for classic PSC, for which the only treatment option is liver transplantation.

Table 1 Previous reports of IgG4-related diseases

• Pachymeningitis	• Autoimmune pancreatitis
• Hypophysitis	• Hepatitis
• Lacrimal gland lesion (Mikulicz's disease)	• Sclerosing cholangitis
• Sclerosing sialadenitis (Küttner tumor)	• Retroperitoneal fibrosis
• Thyroid gland	• Prostatitis
• Pulmonary lesions	• Inflammatory aortic aneurysm
• Mastitis	• Tubulointerstitial nephritis
	• Lymphadenopathy
	• Skin Lesion

Since then, many entities that are related to IgG4 have been described from all over the world (Table 1), especially in Western countries, as well as in Japan.[36–57] They include sclerosing sialadenitis,[36] pulmonary plasma cell granuloma and other pulmonary lesions,[38,47,48] mastitis,[37,49] hepatitis,[39] tubulointerstitial nephritis,[50] prostatitis,[51]inflammatory aortic aneurysm,[40,43,44,52] lymphadenopathy,[53,54] pachymeningitis[55] and skin lesion.[54,56] Each of these diseases could occur separately, or in various combinations. It should be stressed, however, that the occurrence of numerous IgG4-positive plasma cells is not entirely specific for IgG4-related diseases. Suppurative granulation tissue, for example, may contain numerous IgG4-positive cells.[57] It is also well known that LPSP-like histology and numerous IgG4-positive plasma cells can be seen in association with pancreatic carcinomas, and some patients with pancreatic carcinoma have elevated serum IgG4.[58–60] A cautious approach is thus mandatory for pathologists to determine if each condition or each case is truly related to IgG4-related diseases.

The etiology of IgG4-related diseases is not well understood. The overall immune response seems to be mediated by T-helper cell 2 (Th2) reaction, and involvement of regulatory T cells is suggested (Fig. 3)[61]

Kawa *et al.* reported that the human leukocyte antigen DRB1*0405-DQB1*0401 haplotype is common among Japanese patients with AIP,[62] suggesting that a certain genetic preponderance is involved in the disease. IgG4 autoantibodies to various tissues have been found in the patients' sera,[63] and dense deposits have been identified ultrastructurally.[15] But IgG4 cannot activate the classic complement pathway, and it is unclear how IgG4 deposition can lead to tissue damage. Another unique feature of IgG4 is its ability to bind

© 2010 The Authors
Journal compilation © 2010 Japanese Society of Pathology

other immunoglobulins through its Fc (Fragment, crystallizable),[64] but its relationship to IgG4-related diseases is still unknown.

IgG4-RELATED LYMPHADENOPATHY

Pathology and clinical findings of IgG4-related lymphadenopathy.

Concomitant lymphadenopathy is common in IgG4-related diseases.[39,53] Recently, several reports dealing with the morphological and immunohistological findings of the lymph nodal lesion have been published.[53,54,65,66] It appears that histomorphological findings of IgG4-related lymphadenopathy showed histological diversity.[53,54,65,66] Moreover, clinically, IgG4-related lymphadenopathy occasionally showed systemic lymphadenopathy, polyclonal hyperimmunoglobulinemia, especially elevation of IgG and IgE, and positivity of various autoantibodies.[53,54,65] Although some cases of lymphadenopathy were previously designated as atypical lymphoproliferative disorders,[67] mimicking malignant lymphomas, these cases lack immunoglobulin gene monoclonality, and are thought to be non-neoplastic.

We considered that there are five histological subtypes in IgG4-related lymphadenopathy (Table 2).

Type I: Castleman's disease- like morphology

The lymph node architecture is preserved. The lesion contains numerous lymphoid follicles (Fig. 4a). Cheuk *et al.* noted that the lymphoid follicles had a variable degree of regressive changes in the germinal centers, with decreased centroblasts, tingible body macrophages, and mitotic figures in some cases.[53] Hyalinized blood vessels frequently penetrate into the germinal centers. In some lymphoid follicles concentric files of small lymphocytes produced an onion skin pattern in the mantle zone. Other authors, however, reported that the lymphoid follicles had normal germinal centers with distinct mantle zone (Fig. 4a).[54,65,66] The interfollicular area contained mild–moderate increased vascular proliferation and moderate–large numbers of mature plasma cells with a few plasmacytoid cells and large transformed cells (immunoblasts) (Fig. 4b).[54,65,66] Occasionally, eosinophilic infiltration is observed in the interfollicular area (Fig. 4b). Immunohistology showed polytypic immunoglobulin in the plasma cells, and there was no human herpes virus type-8 (HHV-8) positive cells in 11 cases examined.[53,54,66]

Table 2 Histological subtypes and distribution pattern of IgG4-positive cells in IgG4-related lymphadenopathy

	Histological subtype	Distribution pattern of IgG4-positive cells
Pattern I	Castleman's disease-like morphology	Interfollicular
Pattern II	Reactive follicular hyperplasia	Interfollicular
Pattern III	Interfollicular plasmacytosis and immunoblastosis	Interfollicular
Pattern IV	Progressive transformation of germinal center-like	Intra-germinal center
Pattern V	Inflammatory pseudotumor-like morphology	Interfollicular

Type II: Reactive follicular hyperplasia

The lymph node shows reactive follicular hyperplasia, and small–moderate numbers of mature plasma cells in the interfollicular area.[53]

Type III: Interfollicular plasmacytosis and immunoblastosis

On low-power field, the lesion has paracortical hyperplasia with small vessel proliferation, and various numbers of lymphoid follicles with minimal sinuses (Fig. 4c).[53,54] The germinal centers were usually hyperplastic, although a few were atrophic. On high-power field, the paracortical area was diffusely infiltrated by a polymorphous population consisting of numerous mature plasma cells, plasmacytoid cells, large basophilic transformed lymphocytes (immunoblasts), eosinophils, small to medium-sized lymphocytes and histiocytes (Fig. 4d).[53,54] Immunostain demonstrates the mixed T- and B-cell nature of immunoblasts. The T cells in the interfollicular area were negative for CD10 and there was no extrafollicular proliferation of follicular dendritic cells using the anti-follicular dendritic cell antibodies, which are usually observed in angioimmunoblastic T-cell lymphomas (AITL). On immunohistochemistry, light chain immunoglobulin of the interfollicular plasma cells, plasmacytoid cells and B-immunoblasts is bi-modal and non-neoplastic.

Type IV: Progressive transformation of germinal center like

Progressive transformation of germinal center (PTGC) is characterized by the presence of large nodules of lymphocytes, often threefold to fourfold the size of other normal reactive germinal centers (Fig. 4e).[68] In PTGC, small lymphocytes migrate into the germinal center in a multifocal fashion, progressively accumulate and expand there, and then disrupt germinal centers.[68] In the early stage, germinal centers develop an unusual shape or break up without clear demarcation of the germinal center and mantle zone (Fig. 4e). These germinal center cell clusters contain centroblasts and centrocytes. Mitotic figures and tingible body macrophages are usually evident in the germinal center. In the late stage, PTGC are composed of large nodules with numerous small lymphocytes and centroblasts and centrocytes. In IgG4-related lymphadenopathy, early PTGC and normal

© 2010 The Authors
Journal compilation © 2010 Japanese Society of Pathology

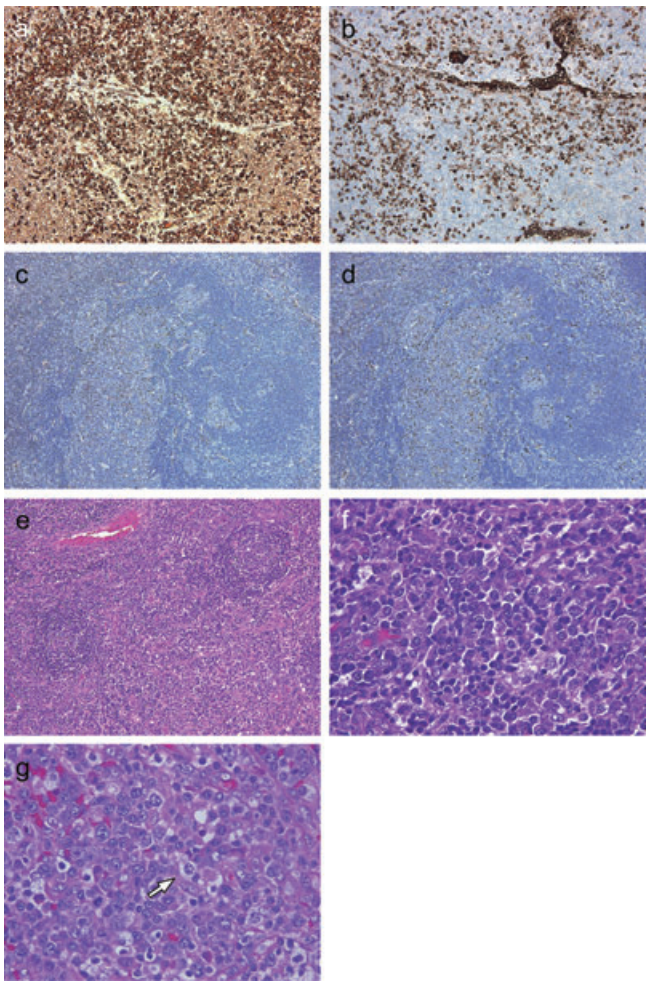

Figure 5 (**a**) Immunostaining for IgG and (**b**) IgG4. A large number of IgG4-positive cells infiltrated the type III lesion. (**c**) Immunostaining for IgG and (**d**) IgG4. IgG4-positive cells mainly infiltrated the type IV lesion of PTGC. (**e**) ALPIB. On low-power field, the lesion contained diffuse paracortical hyperplasia with small vessel proliferation and two small germinal centers. (**f**) ALPIB. On high-power field, the paracortical area contained numerous mature plasma cells, plasmacytoid cells, immunoblasts, small and medium-sized lymphocytes and histiocytes. (**g**) Angioimmunoblastic T-cell lymphoma. On high-power field, the lesion contained numerous plasma cells. Note scattered clear cells (arrow).

reactive germinal centers had scattered mature plasma cells (Fig. 4f) in the germinal centers.[54]

Type V: Inflammatory pseudotumor like

Inflammatory pseudotumor (IPT) of the lymph node develops in stages:[68,69] stage I, small nodules with partial involvement of the lymph node; stage II, inflammatory infiltrate and fibroblastic proliferation cause marked distortion of the connective tissue framework of the lymph node including hilum, trabeculae and capsule with secondary spread into the lymph node parenchyma and extranodal adipose tissue; and stage

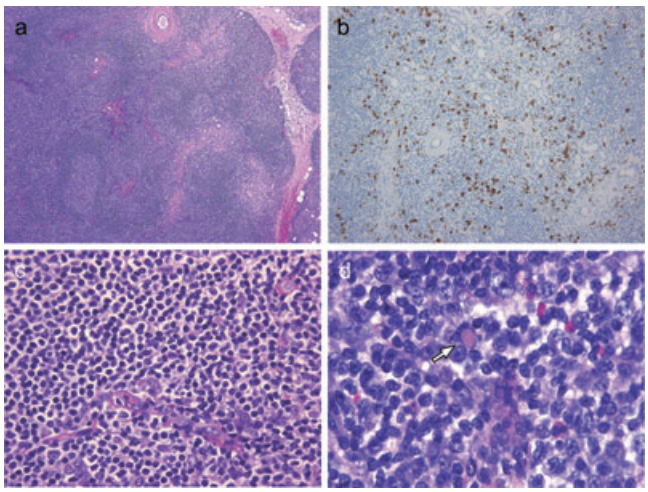

Figure 6 Ocular adnexal IgG4-related mucosa-associated lymphoid tissue lymphoma. (**a**) Diffuse dense infiltrate of lymphoid cells with lymphoid follicles and fibrosis band in lacrimal gland. (**b**) Numerous IgG4-positive plasma cells are identified (IgG4/IgG-positive cell ratio ≥ 50%). (**c**) The infiltrate consists of monocytoid B-cell-like cells, centrocytic cells and eosinophils. (**d**) Eosinophil infiltration and a few lymphoid cells exhibit Dutcher body (arrow).

III, areas of dense sclerosis of the lymph node with minimal inflammation. IgG4-related lymphadenopathy has similar histological findings to those of stage III of IPT (YS and MK, pers. comm., 2009). Histologically, the majority of the lymph nodes were occupied by the hyalinized tissue, and a few residual lymphoid follicles and focally dense lymphoid infiltrate were observed in the lymph node (Fig. 4g). Mature plasma cells, small lymphocytes and eosinophils focally infiltrate the sclerosing tissue (Fig. 4h).

The proportion of IgG4/IgG-positive plasma cells ranged from 40% to 99% in the literature.[53,54,66] We recognized two types of distribution pattern of IgG4-positive plasma cells, namely interfollicular and intra-germinal center type (Table 2).[54] In the interfollicular pattern, the majority of IgG4-positive plasma cells are located in the interfollicular area (Fig. 5a,b), whereas IgG4-positive plasma cells were observed more frequently in the lymphoid follicles in the intragerminal center type (Fig. 5c,d). Patterns I, II, III and V usually involved an interfollicular distribution, but pattern IV involved an intragerminal center distribution.

Clinically, three types of lymphadenopathy are recognized.[53] Group A involves enlarged regional and group B involves non-regional lymph node of organs affected by IgG4-related disease. Cases of unexplained lymphadenopathy were designated as group C. The characteristic clinical presentation of group B and C patients can be summarized as follows (Table 3):[53,54] (i) the patients are middle-aged to elderly with marked male predominance; (ii) usually systemic lymphadenopathy; (iii) the lymph nodes are not very large (usually up to 2 cm); (iv) the exocrine or extranodal lesions

© 2010 The Authors
Journal compilation © 2010 Japanese Society of Pathology

Table 3 Clinical characters of systemic IgG4-related lymphadenopathy

Clinical presentation	(i) Patients are middle-aged–elderly with marked male predominance
	(ii) Systemic lymphadenopathy
	(iii) Lymph node are not very large (usually up to 2 cm)
	(iv) Exocrine or extranodal lesions may precede, follow, or present together with the lymph node swelling
	(iv) Absence of fever
Abnormal laboratory findings	(i) Polyclonal hyperimmunoglobulinemia
	(ii) Raised serum IgG and IgE levels
	(iii) Elevation of serum soluble interleukin-2 receptor
	(iv) Presence of autoantibodies
Normal laboratory findings	(i) Interleukin-6 level
	(ii) Negativity of C-reactive protein
	(iii) Lactate dehydrogenase level

may precede, follow, or present together with the lymph node swelling; and (v) despite the systemic nature of the disease, there is no fever or other B symptoms. The diagnostic laboratory clues to diagnosis are polyclonal hyperimmunoglobulinemia, raised serum IgG and IgE levels, elevation of serum soluble interleukin-2 (IL-2) receptor and presence of autoantibodies, whereas the IL-6, CRP and lactate dehydrogenase level were within normal limits in the majority of cases.

Differential diagnostic problems of IgG4-related lymphadenopathy

The present review demonstrates the histological variety of IgG4-related lymphadenopathy. Clinically, this disease frequently affected middle-aged and elderly patients, producing systemic lymphadenopathy associated with various immunological abnormalities.[53,54]

IgG4-related lymphadenopathy should be differentiated from various atypical and malignant LPD containing numerous and plasma cells.

Type I lesions had similar clinicopathological findings to multicentric Castleman's disease (MCD), including idiopathic plasmacytic lymphadenopathy with polyclonal hyperimmunoglobulinemia (IPL).[67,70] In Japan, HHV-8 appears to be unrelated to the etiology of MCD except for HIV type-1 infection as well as IgG4-related lymphadenopathy.[70,71] We (YS and MK) have seen numerous IgG4-positive plasma cells in the lymph nodal lesion of IPL, although the serum IL-6 level was within normal limits in the majority of type I lesions.[54,66] The abnormal clinical findings, such as general fatigue, anemia and polyclonal hypergammaglobulinemia, elevated CRP and thrombocytosis may be related to a high level of IL-6 in the MCD,[72–74] but there were no clinical characteristics of MCD in any of the IgG4-related lymphadenopathies.

Type I lesions also should be differentiated from lymph node lesions of autoimmune disease-associated lymphadenopathy, in particular rheumatoid arthritis (RA) and systemic lupus erythematosus (SLE).[75,76] The characteristic histological finding of lymph nodal lesion of RA is both reactive follicular hyperplasia and interfollicular plasmacytosis.[75] The lymph nodal lesion of SLE occasionally has similar histological findings to Castleman's disease,[76] but there is no evidence of definite autoimmune disease in any of the IgG4-related lymphadenopathies.

One of the most important differential diagnostic problems is atypical lymphoplasmacytic and immunoblastic proliferation (autoimmune-disease-associated lymphadenopathy).[77] Koo *et al*. reported an unusual lymph node lesion, namely 'ALPIB',[77] which is associated with various autoimmune disease including RA and SLE.[77,78] Histologically, the lesion is characterized by prominent polyclonal lymphoplasmacytic infiltration with various numbers of immunoblasts.[77] There is no evidence, however, of definite autoimmune disease in any of the IgG4-related lymphadenopathies.

When AITL contains a few tumor cells (clear cells) with numerous plasma cells and B-immunoblasts, it can be confused with type III lesions. In contrast to AITL, there are no cytologically atypical CD10+ T-cells and there is no extrafollicular follicular dendritic proliferation in type III lesions.[79] Moreover, AITL usually involves systemic symptoms such as fever.[79]

Type IV lesion has histological findings of early stage PTGC.[68] A portion of PTGC containing numerous plasma cells in the germinal center may be an IgG4-related lymphadenopathy.

Type V lesions have similar histological findings to those of the IPT of the lymph node. IPT of the lymph node, however, mainly affects the lymph node framework such as hilum, trabeculae and capsule,[68,69] whereas lesions of IgG4-related disease are usually located in the lymph node parenchyma.

The importance of recognition of this entity lies in the remarkable response to steroid therapy. The diagnosis requires awareness and a high index of suspicion for this entity, which could present as unexplained lymphadenopathy with numerous plasma cells and scattered eosinophils, or lymphadenopathy in patients with known pancreatitis, lacrimal gland lesion or salivary gland lesion.

OCULAR ADNEXAL IgG4-RELATED DISEASE

Clinical and pathological findings of ocular adnexal IgG4-related disease

IgG4-related diseases frequently involve the ocular adnexal region.[80,81] Ocular adnexal IgG4-related disease is also

© 2010 The Authors
Journal compilation © 2010 Japanese Society of Pathology

called Mikulicz's disease or chronic sclerosing dacryoadenitis.[82–86] Clinically, the lacrimal glands are involved, and bilateral lacrimal gland swelling is frequently observed.[80] Though some patients do not show obvious lacrimal gland involvement clinically, lacrimal gland component was frequently detected histologically. This suggests that accessory lacrimal glands may be involved.

Mikulicz's disease is a unique condition that refers to bilateral, painless and symmetrical swelling of the lacrimal, parotid and submandibular glands. Although Mikulicz's disease has been considered a subtype of Sjögren syndrome, there are several differences between the two diseases. Patients with Mikulicz's disease lack anti-SS-A and anti-SS-B antibodies, but frequently have elevated serum IgG4 levels.[34,82–84] Infiltration of many IgG4-positive plasma cells into the lacrimal and salivary glands has been detected in Mikulicz's disease. Additionally, Mikulicz's disease has good responsiveness to steroids, and reversible of lacrimal and salivary gland function. Thus, it is important to distinguish Mikulicz's disease from Sjögren syndrome.[34,82–84]

The ocular adnexal IgG4-related disease is histologically uniform: marked lymphoplasmacytic infiltration and lymphoid follicles, admixed with dense fibrosis, and infiltration of many IgG4-positive plasma cells.[80] These findings are similar to those of previous reports of IgG4-related disease of other organs. The ocular adnexal IgG4-related diseases often are associated with ones of the salivary glands.[80]

As referred to here, obliterative phlebitis has been identified as a histological feature of IgG4-related diseases since Kawaguchi *et al*. reported on the histopathology of sclerosing pancreatitis in 1991,[9] and it has been easily and characteristically found in sclerosing pancreatitis and sclerosing sialadenitis. But obliterative phlebitis is usually not detected in ocular adnexal IgG4-related disease.[80] Therefore, we suggest that obliterative phlebitis may be organ specific, but not a common feature of IgG4-related diseases.

Interestingly, although serum IgG4 levels are often evaluated after treatment, it remains elevated even in remission.[80] This may be due to residual IgG4-secreting plasma cells located subclinically elsewhere.

Ocular adnexal IgG4-related disease and mucosa-associated lymphoid tissue lymphoma

Little is known about lymphomagenesis in the context of IgG4-related disease.[80,85,87] We recently first reported ocular adnexal mucosa-associated lymphoid tissue (MALT) lymphomas arising from IgG4-related disease, occurring in the same organ.[80]

MALT lymphoma is an extranodal lymphoma consisting of morphologically heterogeneous small B-cells including marginal zone cells.[88,89] The infiltrate is in the marginal zone of reactive B-cell follicles and extends into the interfollicular region. In epithelial tissues, the neoplastic cells typically infiltrate the epithelium, forming lymphoepithelial lesion. The presence of lymphoepithelial lesion is important when making a diagnosis of MALT lymphoma.[88,89]

In many cases of MALT lymphoma, there is a history of chronic inflammatory, often autoimmune disorders that result in accumulation of extranodal lymphoid tissue. These include *Helicobacter pylori*-associated chronic gastritis, Sjögren syndrome or Hashimoto thyroiditis.[88,89] Thus, we considered that patients with ocular adnexal IgG4-related disease may be at an increased risk of developing ocular adnexal MALT lymphoma. Another study has also described ocular adnexal lymphomas arising from IgG4-related disease.[85] Takahashi *et al*. reported that three patients with IgG4-related disease with or without autoimmune pancreatitis later developed B-cell non-Hodgkin lymphoma (two of whom developed diffuse large B-cell lymphoma).[87] In addition, Ochoa *et al*. reported on marginal zone B-cell lymphoma of the salivary gland arising in Küttner tumor.[90] It has previously been noted that autoimmune pancreatitis and Küttner tumor were considered to be IgG4-related disease. Therefore, these reports suggest that IgG4-related disease may be a risk factor for malignant lymphoma.

We experienced seven patients with the ocular adnexal MALT lymphomas arising from IgG4-related disease (IgG4-related ocular adnexal MALT lymphoma), occurring in the same organ. Six patients had localized disease (clinical stage IE or IIE; unpubl. data, 2009). Histologically, in this series of patients there was dense fibrosis subdividing the lacrimal gland, and marked lymphoid cell infiltration with lymphoid follicles. These histological findings were consistent with previous reports of IgG4-related disease. However, some infiltrated lymphoid cells showed centrocyte-like features, and Dutcher bodies were found in some of the cases (Fig. 6) in addition to histological finding of IgG4-related disease. All cases had immunoglobulin light chain restriction, and immunoglobulin heavy chain gene rearrangement on polymerase chain reaction and/or Southern blot hybridization. Interestingly, lymphoepithelial lesion was not found in any cases. Lymphoepithelial lesions usually are not found in ocular adnexal MALT lymphomas (especially in the lacrimal gland region).[90] Another report also noted that lymphoepithelial lesion was not found in ocular adnexal IgG4-related MALT lymphoma. It remains unclear whether the absence of lymphoepithelial lesion indicates biological differences in the lacrimal gland, or whether the epithelium may have been destroyed due to IgG4-related chronic inflammation.

© 2010 The Authors
Journal compilation © 2010 Japanese Society of Pathology

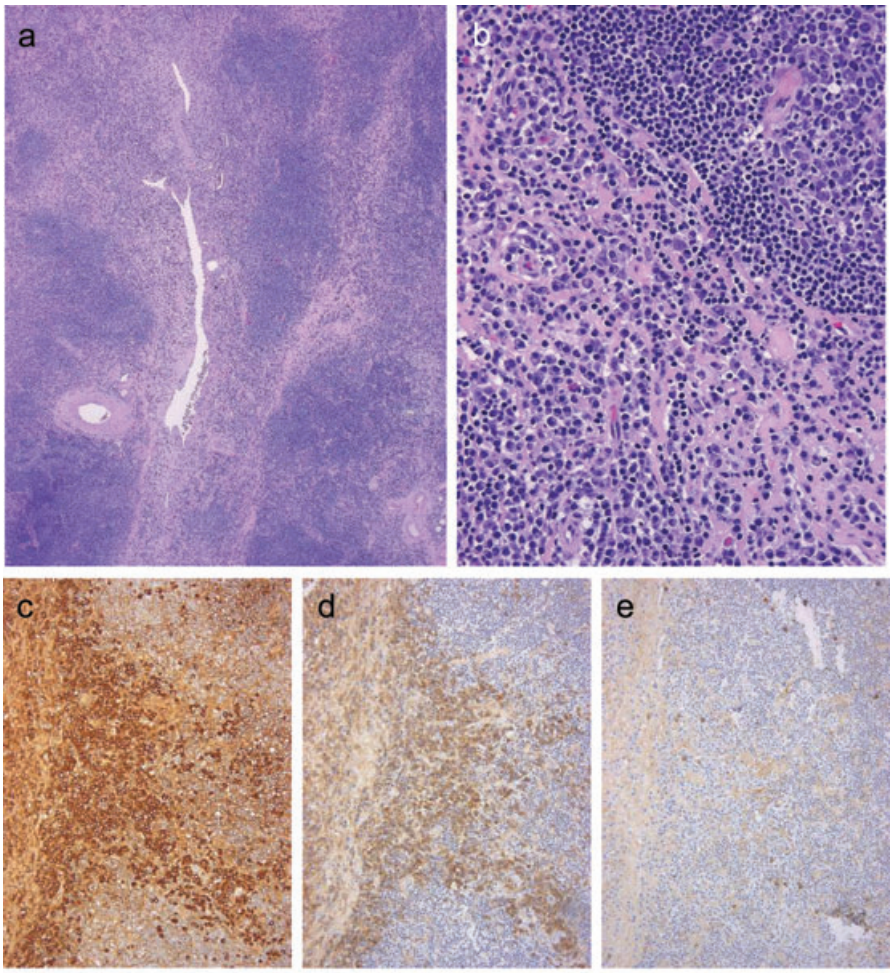

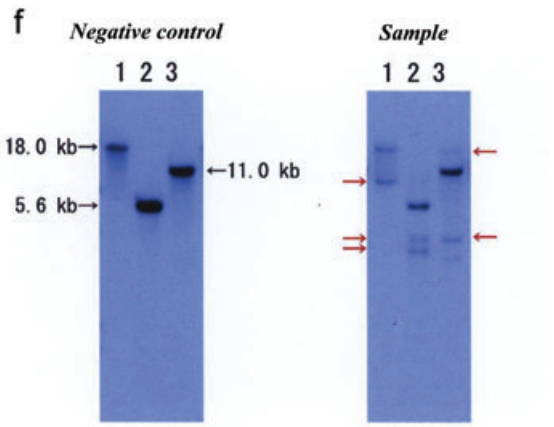

Figure 7 Ocular adnexal IgG4-producing mucosa-associated lymphoid tissue lymphoma. (**a**,**b**) Dense fibrosis and marked lymphoplasmacytic infiltration in the lacrimal gland. Histologically, this is compatible with previous reports of IgG4-related sclerosing disease. Immunostain for (**c**) IgG4, (**d**) kappa-light chain and (**e**) lambda-light chain. Most of the IgG4-positive cells exhibit kappa-light chain restriction. (**f**) Immunoglobulin heavy chain gene rearrangement was detected on Southern blot hybridization.

There have been many reports on ocular adnexal IgG4-related lymphomas at the annual meetings of the Japanese Society, but in IgG4-related disease of other sites, there is rare or absent IgG4-related MALT lymphoma. In the orbital region, the most common tumor is malignant lymphoma, especially MALT lymphoma.[91] In contrast, submandibular gland and pancreas have a low incidence of MALT lymphoma. Therefore IgG4-related MALT lymphoma may occur more easily in the ocular adnexa.

IgG4-PRODUCING LYMPHOMA

Little is known about IgG4-producing lymphoma.[85,92] We recently reported the first case of IgG4-producing marginal zone B-cell lymphoma of the lymph node.[92] The IgG4-positive tumor cells were lambda light-chain-restricted and CD138 partially positive, although the expression was fainter than that of the non-neoplastic cells. Additionally, the tumor cells were partially positive for CD20, which is normally

© 2010 The Authors
Journal compilation © 2010 Japanese Society of Pathology

negative in non-neoplastic plasma cells, and had elevation of serum IgG4 level.[92] Therefore that case indicates that not only can malignant lymphomas occur in the setting of IgG4-related diseases, but that IgG4-producing cells can also be neoplastic.

Moreover, we encountered a case of ocular adnexal IgG4-producing MALT lymphoma (Fig. 7). The histology was compatible with ocular adnexal IgG4-related disease (Fig. 7a,b), and there was elevation of serum IgG4 level, serum IgG4/IgG ratio, and IgG4/IgG-positive cell ratio (≥50%). The lesion exhibited immunoglobulin light chain restriction of IgG4-positive cells (Fig. 7c–e) and immunoglobulin heavy chain gene rearrangement (Fig. 7f). Previously, Cheuk *et al.* also reported on ocular adnexal IgG4-producing lymphoma.[85] They concluded that it remains unclear whether ocular adnexal IgG4-producing MALT lymphoma arises from pre-existing IgG4-related disease, or de novo IgG4-postive MALT lymphoma. We suggest that it may clonal expansion of IgG4-positive cells occurring against a background of IgG4-related chronic inflammation. This is because the case showed marked lymphoplasmacytic infiltration and lymphoid follicles, admixed with dense fibrosis, and also detected elevation of serum IgG4 level. These findings are compatible with IgG4-related disease.

Clinicopathological features of IgG4-producing lymphoma should be clarified in the future by accumulation and evaluation of such cases.

CONCLUSION

IgG4-related diseases are a new clinicopathological systemic entity, but the pathogenesis and etiology remain unclear. IgG4-related diseases have a good response to steroids. Accordingly, accurate pathological diagnosis is very important.

ACKNOWLEDGMENTS

This work was supported in part by grants from Intractable Diseases, the Health and Labour Sciences Research Grants from Ministry of Health, Labor and Welfare (H21-112).

REFERENCES

1 Bird P, Friedmann PS, Ling N *et al.* Subclass distribution of IgG autoantibodies in bullous pemphigoid. *J Invest Dermatol* 1986; **86**: 21–5.
2 Flotte TJ, Baird LG. Immunoglobulin light and heavy chain isotypes in skin diseases: Restricted distribution in bullous pemphigoid and linear IgA bullous dermatosis. *J Immunol* 1986; **136**: 491–6.
3 Jones CC, Hamilton RG, Jordon RE. Subclass distribution of human IgG autoantibodies in pemphigus. *J Clin Immunol* 1988; **8**: 43–9.
4 Doi T, Mayumi M, Kanatsu K *et al.* Distribution of IgG subclasses in membranous nephropathy. *Clin Exp Immunol* 1984; **58**: 57–62.
5 Hamano H, Kawa S, Horiuchi A *et al.* High serum IgG4 concentrations in patients with sclerosing pancreatitis. *N Engl J Med* 2001; **344**: 732–8.
6 Hamano H, Kawa S, Ochi Y *et al.* Hydronephrosis associated with retroperitoneal fibrosis and sclerosing pancreatitis. *Lancet* 2002; **359**: 1403–4.
7 Yoshida K, Toki F, Takeuchi T *et al.* Chronic pancreatitis caused by an autoimmune abnormality. Proposal of the concept of autoimmune pancreatitis. *Dig Dis Sci* 1995; **40**: 1561–8.
8 Sarles H, Sarles JC, Muratore R *et al.* Chronic inflammatory sclerosis of the pancreas: An autonomous pancreatic disease? *Am J Dig Dis* 1961; **6**: 688–98.
9 Kawaguchi K, Koike M, Tsuruta K *et al.* Lymphoplasmacytic sclerosing pancreatitis with cholangitis: A variant of primary sclerosing cholangitis extensively involving pancreas. *Hum Pathol* 1991; **22**: 387–95.
10 Ectors N, Maillet B, Aerts R *et al.* Non-alcoholic duct destructive chronic pancreatitis. *Gut* 1997; **41**: 263–8.
11 Wreesmann V, van Eijck CHJ, Naus DCWH *et al.* Inflammatory pseudotumour (inflammatory myofibroblastic tumour) of the pancreas: A report of six cases associated with obliterative phlebitis. *Histopathology* 2001; **38**: 105–10.
12 Notohara K, Burgart LJ, Yadav D *et al.* Idiopathic chronic pancreatitis with periductal lymphoplasmacytic infiltration. Clinicopathologic features of 35 cases. *Am J Surg Pathol* 2003; **27**: 1119–27.
13 Zamboni G, Lüttges J, Capelli P *et al.* Histopathological features of diagnostic and clinical relevance in autoimmune pancreatitis: A study on 53 resection specimens and 9 biopsy specimens. *Virchows Arch* 2004; **445**: 552–63.
14 Kojima M, Sipos B, Klapper W *et al.* Autoimmune pancreatitis: Frequency, IgG4 expression, and clonality of T and B cells. *Am J Surg Pathol* 2007; **31**: 521–8.
15 Deshpande V, Chiocca S, Finkelberg D *et al.* Autoimmune pancreatitis: A systemic immune complex mediated disease. *Am J Surg Pathol* 2006; **30**: 1537–45.
16 Kamisawa T, Funata N, Hayashi Y. Lymphoplasmacytic sclerosing pancreatitis is a pancreatic lesion of IgG4-related systemic disease. *Am J Surg Pathol* 2004; **28**: 1114.
17 Zhang L, Notohara K, Levy MJ *et al.* IgG4-positive plasma cell infiltration in the diagnosis of autoimmune pancreatitis. *Mod Pathol* 2007; **20**: 23–8.
18 Mino-Kenudson M, Smyrk TC, Deshpande V *et al.* Autoimmune pancreatitis: West vs. East. *Mod Pathol* 2008; **21**(Suppl. 1): 312A (abstract).
19 Okazaki K, Kawa S, Kamisawa T *et al.* Clinical diagnostic criteria of autoimmune pancreatitis: Revised proposal. *J Gastroenterol* 2006; **41**: 626–31.
20 Kim KP, Kim MH, Kim JC, Lee SS, Seo DW, Lee SK. Diagnostic criteria for autoimmune chronic pancreatitis revisited. *World J Gastroenterol* 2006; **12**: 2487–96.
21 Otsuki M, Chung JB, Okazaki K *et al.* Asian diagnostic criteria for autoimmune pancreatitis: Consensus of the Japan-Korea symposium on autoimmune pancreatitis. *J Gastroenterol* 2008; **43**: 403–8.
22 Chari ST, Smyrk TC, Levy MJ *et al.* Diagnosis of autoimmune pancreatitis: The Mayo Clinic experience. *Clin Gastroenterol Hepatol* 2006; **4**: 1010–16.

© 2010 The Authors
Journal compilation © 2010 Japanese Society of Pathology

23 Frulloni L, Scattolini C, Falconi M *et al.* Autoimmune pancreatitis: Differences between the focal and diffuse forms in 87 patients. *Am J Gastroenterol* 2009; **104**: 2288–94.
24 Sugumar A, Klöppel G, Chari ST. Autoimmune pancreatitis: Pathologic subtypes and their implications for its diagnosis. *Am J Gastroenterol* 2009; **104**: 2308–10.
25 Clark A, Zeman RK, Choyke PL *et al.* Pancreatic pseudotumors associated with multifocal idiopathic fibrosclerosis. *Gastrointest Radiol* 1988; **13**: 30–32.
26 Mitchinson MJ. The pathology of idiopathic retroperitoneal fibrosis. *J Clin Pathol* 1970; **23**: 681–9.
27 Meyer S, Hausman R. Occlusive phlebitis in multifocal fibrosclerosis. *Am J Clin Pathol* 1976; **65**: 274–83.
28 Mombaerts I, Goldschmeding R, Schlingemann RO *et al.* What is orbital pseudotumor? *Surv Ophthalmol* 1996; **41**: 66–78.
29 Meijer S, Hausman R. Occlusive phlebitis, a diagnostic feature in Riedel's thyroiditis. *Virchows Arch* 1978; **377**: 339–49.
30 Hamano H, Arakura N, Muraki T *et al.* Prevalence and distribution of extrapancreatic lesions complicating autoimmune pancreatitis. *J Gastroenterol* 2006; **41**: 1197–205.
31 Kamisawa T, Funata N, Hayashi Y *et al.* Close relationship between autoimmune pancreatitis and multifocal fibrosclerosis. *Gut* 2003; **52**: 683–7.
32 Kamisawa T, Funata N, Hayashi Y *et al.* A new clinicopathological entity of IgG4-related autoimmune disease. *J Gastroenterol* 2003; **38**: 982–4.
33 Yamamoto M, Takahashi H, Sugai S *et al.* Clinical and pathological characteristics of Mikulicz's disease (IgG4-related plasmacytic exocrinopathy). *Autoimmun Rev* 2005; **4**: 195–200.
34 Masaki Y, Dong L, Kurose N *et al.* Proposal for a new clinical entity, IgG4-positive multiorgan lymphoproliferative syndrome: Analysis of 64 cases of IgG4-related disorders. *Ann Rheum Dis* 2009; **68**: 1310–15.
35 Zen Y, Harada K, Sasaki M *et al.* IgG4-related sclerosing cholangitis with and without hepatic inflammatory pseudotumor, and sclerosing pancreatitis-associated sclerosing cholangitis. Do they belong to a spectrum of sclerosing pancreatitis? *Am J Surg Pathol* 2004; **28**: 1193–203.
36 Kitagawa S, Zen Y, Harada K *et al.* Abundant IgG4-positive plasma cell infiltration characterizes chronic sclerosing sialadenitis (Küttner's tumor). *Am J Surg Pathol* 2005; **29**: 783–91.
37 Zen Y, Kasahara Y, Horita K *et al.* Inflammatory pseudotumor of the breast in a patient with a high serum IgG4 level. Histologic similarity to sclerosing pancreatitis. *Am J Surg Pathol* 2005; **29**: 275–8.
38 Zen Y, Kitagawa S, Minato H *et al.* IgG4-positive plasma cells in inflammatory pseudotumor (plasma cell granuloma) of the lung. *Hum Pathol* 2005; **36**: 710–17.
39 Umemura T, Zen Y, Hamano H *et al.* Immunoglobulin G4-hepatopathy: Association of immunoglobulin G4-bearing plasma cells in liver with autoimmune pancreatitis. *Hepatology* 2007; **46**: 463–71.
40 Kasashima S, Zen Y, Kawashima A *et al.* Inflammatory abdominal aortic aneurysm: Close relationship to IgG4-related periaortitis. *Am J Surg Pathol* 2008; **32**: 197–204.
41 Nakazawa T, Ohara H, Sano H *et al.* Cholangiography can discriminate sclerosing cholangitis with autoimmune pancreatitis from primary sclerosing cholangitis. *Gastrointest Endosc* 2004; **60**: 937–44.
42 Kamisawa T, Okamoto A. IgG4-related sclerosing disease. *World J Gastroenterol* 2008; **14**: 3948–55.
43 Ishida M, Hotta M, Kushima R *et al.* IgG4-related inflammatory aneurysm of the aortic arch. *Pathol Int* 2009; **59**: 269–73.
44 Ito H, Kaizaki Y, Noda Y *et al.* IgG4-related inflammatory abdominal aortic aneurysm associated with autoimmune pancreatitis. *Pathol Int* 2008; **58**: 421–6.
45 Li Y, Bai Y, Liu Z *et al.* Immunohistochemistry of IgG4 can help subclassify Hashimoto's autoimmune thyroiditis. *Pathol Int* 2009; **59**: 636–41.
46 Ishida M, Hotta M, Kushima R *et al.* Multiple IgG4-related sclerosing lesions in the maxillary sinus, parotid gland and nasal septum. *Pathol Int* 2009; **59**: 670–75.
47 Yamashita K, Haga H, Kobashi Y, Miyagawa-Hayashino A, Yoshizawa A, Manabe T. Lung involvement in IgG4-related lymphoplasmacytic vasculitis and interstitial fibrosis. Report of 3 cases and review of the literature. *Am J Surg Pathol* 2008; **32**: 1620–26.
48 Shrestha B, Sekiguchi H, Colby TV *et al.* Distinctive pulmonary histopathology with increased IgG4-positive plasma cells in patients with autoimmune pancreatitis. Report of 6 and 12 cases with similar histopathology. *Am J Surg Pathol* 2009 Jul 20. [Epub ahead of print].
49 Cheuk W, Chan ACL, Lam WL *et al.* IgG4-related sclerosing mastitis: Description of a new member of the IgG4-related sclerosing diseases. *Am J Surg Pathol* 2009; **33**: 1058–64.
50 Cornell LD, Chicano SL, Deshpande V *et al.* Pseudotumors due to IgG4 immune-complex tubulointerstitial nephritis associated with autoimmune pancreatocentric disease. *Am J Surg Pathol* 2007; **31**: 1586–97.
51 Uehara T, Hamano H, Kawakami M *et al.* Autoimmune pancreatitis-associated prostatitis: Distinct clinicopathological entity. *Pathol Int* 2008; **58**: 118–25.
52 Sakata N, Tashiro T, Uesugi N *et al.* IgG4-positive plasma cells in inflammatory abdominal aortic aneurysm: The possibility of an aortic manifestation of IgG4-related sclerosing disease. *Am J Surg Pathol* 2008; **32**: 553–9.
53 Cheuk W, Yuen HKL, Chu SYY *et al.* Lymphadenopathy of IgG4-related sclerosing disease. *Am J Surg Pathol* 2008; **32**: 671–81.
54 Sato Y, Kojima M, Takata K *et al.* Systemic IgG4-related lymphadenopathy: A clinical and pathologic comparison to multicentric Castleman's disease. *Mod Pathol* 2009; **22**: 589–99.
55 Chan SK, Cheuk W, Chan KT *et al.* IgG4-related sclerosing pachymeningitis. A previously unrecognized form of central nervous system involvement in IgG4-related sclerosing disease. *Am J Surg Pathol* 2009; **33**: 1249–52.
56 Cheuk W, Lee KC, Chong LY *et al.* IgG4-related sclerosing disease. A potential new etiology of cutaneous pseudolymphoma. *Am J Surg Pathol* 2009; **33**: 1713–19.
57 Suda K, Takase M, Fukumura Y *et al.* Pathology of autoimmune pancreatitis and tumor-forming pancreatitis. *J Gastroenterol* 2007; **42** (Suppl. 18): 22–7.
58 Kamisawa T, Chen PY, Tu Y *et al.* Pancreatic cancer with a high serum IgG4 concentration. *World J Gastroenterol* 2006; **12**: 6225–8.
59 Ghazale A, Chari ST, Smyrk TC *et al.* Value of serum IgG4 in the diagnosis of autoimmune pancreatitis and in distinguishing it from pancreatic cancer. *Am J Gastroenterol* 2007; **102**: 1646–53.
60 Witkiewicz AK, Kennedy EP, Kennyon L *et al.* Synchronous autoimmune pancreatitis and infiltrating pancreatic ductal adenocarcinoma: Case report and review of the literature. *Hum Pathol* 2008; **39**: 1548–51.
61 Zen Y, Fujii T, Harada K *et al.* Th2 and regulatory immune reactions are increased in immunoglobulin G4-related sclerosing pancreatitis and cholangitis. *Hepatology* 2007; **45**: 1538–46.
62 Kawa S, Ota M, Yoshizawa K *et al.* HLA-DRB1*0405-DQB1*0401 haplotype is associated with autoimmune pancreatitis in the Japanese population. *Gastroenterology* 2002; **122**: 1264–9.

© 2010 The Authors
Journal compilation © 2010 Japanese Society of Pathology

63 Aoki S, Nakazawa T, Ohara H *et al.* Immunohistochemical study of autoimmune pancreatitis using anti-IgG4 antibody and patients' sera. *Histopathology* 2005; **47**: 147–58.
64 Kawa S, Kitahara K, Hamano H *et al.* A novel immunoglobulin-immunoglobulin interaction in autoimmunity. *PloS One* 2008; **3**: e1637.
65 Boulanger E, Fuentes V, Meignin V *et al.* Polyclonal IgG4 hypergammaglobulinemia associated with plasmacytic lymphadenopathy, anemia and nephropathy. *Ann Hematol* 2006; **86**: 833–40.
66 Kojima M, Miyawaki S, Takada S *et al.* Lymphoplasmacytic infiltrate of regional lymph node in Küttner's tumor (chronic sclerosing sialoadenitis). A report of three cases. *Int J Surg Pathol* 2008; **16**: 263–8.
67 Frizzera G. Atypical lymphoproliferative disorders. In: Knowles DM, ed. *Neoplastic Hematopathology*, 2nd edn. Baltimore: Lippincott Williams & Wilkins, 2001; 569–622.
68 Ioachim HL, Medeiros LJ. *Ioachim's Lymph Node Pathology*, 4th edn. Philadelphia, PA: Lippincott, Williams & Wilkins, 2009.
69 Moran CA, Suster S, Abbondanzo SL. Inflammatory pseudotumor of lymph nodes: A study of 25 cases with emphasis on morphological heterogeneity. *Hum Pathol* 1997; **28**: 332–8.
70 Kojima M, Nakamura N, Tsukamoto N *et al.* Clinical implications of idiopathic multicentric Castleman's disease among Japanese. A report of 28 cases. *Int J Surg Pathol* 2008; **16**: 391–8.
71 Suda T, Kanato H, Delsol G *et al.* HHV-8 infection status of AIDS-unrelated and AIDS-associated multicentric Castleman's disease. *Pathol Int* 2001; **51**: 671–9.
72 Leary AG, Ikebuch Ki, Hirai Y *et al.* Synergism between interleukin-6 and interleukin-3 in supporting proliferation of human hematopoietic stem cells: Comparison with interleukin-1 alpha. *Blood* 1988; **71**: 1759–63.
73 Yoshizaki K, Matsuda T, Nishimoto N *et al.* Pathogenic significance of interleukin-6 (IL-6/BSF-2) in Castleman's disease. *Blood* 1989; **74**: 1360–67.
74 Nishimoto N, Kanakura Y, Aozasa K *et al.* Humanized anti-interleukin-6 receptor antibody treatment of multicentric Castleman's disease. *Blood* 2005; **106**: 2627–32.
75 Kojima M, Hosomura Y, Itoh H *et al.* Reactive proliferative lesions in lymph node from rheumatoid arthritis patients. A clinicopathological study and immunohistochemical study. *Acta Pathol Jpn* 1990; **40**: 249–54.
76 Kojima M, Nakamura S, Morishita Y *et al.* Reactive follicular hyperplasia in the lymph node lesions from systemic lupus erythematosus patients. A clinicopathological study of 21 cases. *Pathol Int* 2000; **50**: 304–12.
77 Koo CH, Nathwani BN, Winberg CD, Hill LR, Rappaport H. Atypical lymphoplasmacytic and immunoblastic proliferation in lymph nodes of patients with autoimmune disease (autoimmune-disease-associated lymphadenopathy). *Medicine (Baltimore)* 1984; **63**: 274–90.
78 Kojima M, Motoori T, Hosomura Y *et al.* Atypical lymphoplasmacytic and immunoblastic proliferation from rheumatoid arthritis. A case report. *Pathol Res Pract* 2006; **202**: 51–4.
79 Attygale AD, Kyriakou C, Dupuis J *et al.* Histologic evolution of angioimmunoblastic T-cell lymphoma in consecutive biopsies: Clinical correlation and insights into natural history and disease progression. *Am J Surg Pathol* 2007; **31**: 1077–88.
80 Sato Y, Ohshima K, Ichimura K *et al.* Ocular adnexal IgG4-related disease has uniform clinicopathology. *Pathol Int* 2008; **58**: 465–70.
81 Mehta M, Jakobiec F, Fay A. Idiopathic fibroinflammatory disease of the face, eyelids, and periorbital membrane with immunoglobulin G4-positive plasma cells. *Arch Pathol Lab Med* 2009; **133**: 1251–5.
82 Yamamoto M, Harada S, Ohara M *et al.* Clinical and pathological differences between Mikulicz's disease and Sjogren's syndrome. *Rheumatology (Oxford)* 2005; **44**: 227–34.
83 Yamamoto M, Takahashi H, Ohara M *et al.* A new conceptualization for Mikulicz's disease as an IgG4-related plasmacytic disease. *Mod Rheumatol* 2006; **16**: 335–40.
84 Yamamoto M, Takahashi H, Naishiro Y *et al.* Mikulicz's disease and systemic IgG4-related plasmacytic syndrome (SIPS). *Nihon Rinsho Meneki Gakkai Kaishi* 2008; **31**: 1–8.
85 Cheuk W, Yuen HKL, Chan ACL *et al.* Ocular adnexal lymphoma associated with IgG4+ chronic sclerosing dacryoadenitis: A previously undescribed complication of IgG4-related sclerosing disease. *Am J Surg Pathol* 2008; **32**: 1159–67.
86 Shiomi T, Yoshida Y, Horie Y *et al.* Acquired reactive perforating collagenosis with the histological features of IgG4-related sclerosing disease in a patient with Mikulicz's disease. *Pathol Int* 2009; **59**: 326–31.
87 Takahashi N, Ghazale AH, Smyrk TC *et al.* Possible association between IgG4-associated systemic disease with or without autoimmune pancreatitis and non-Hodgkin lymphoma. *Pancreas* 2009; **38**: 523–6.
88 Yoshino T, Akagi T. Gastric low-grade mucosa-associated lymphoid tissue lymphomas: Their histogenesis and high-grade transformation. *Pathol Int* 1998; **48**: 323–31.
89 Inagaki H. Mucosa-associated lymphoid tissue lymphoma: Molecular pathogenesis and clinicopathological significance. *Pathol Int* 2007; **57**: 474–84.
90 Ochoa ER, Harris NL, Pilch BZ. Marginal zone B-cell lymphoma of the salivary gland arising in chronic sclerosing sialadenitis (Küttner tumor). *Am J Surg Pathol* 2001; **25**: 1546–50.
91 Ohtsuka K, Hashimoto M, Suzuki Y. A review of 244 orbital tumors in Japanese patients during a 21-year period: Origins and locations. *Jpn J Ophthalmol* 2005; **49**: 49–55.
92 Sato Y, Takata K, Ichimura K *et al.* IgG4-producing marginal zone B-cell lymphoma. *Int J Hematol* 2008; **88**: 428–33.

© 2010 The Authors
Journal compilation © 2010 Japanese Society of Pathology