Case Report

Knee Surg Relat Res
https://doi.org/10.5792/ksrr.18.072
pISSN 2234-0726 · eISSN 2234-2451
Published Online: 18 March 2019

KSRR
Knee Surgery & Related Research

The Migratory Cortical Button: A Rare Case of Hypersensitivity to Titanium after an Anterior Cruciate Ligament Reconstruction

Nicolas Bouguennec, MD, Philippe Colombet, MD, Nicolas Graveleau, MD, and Stephane Jambou, MD
Sports Clinic of Bordeaux-Merignac, Merignac, France

Allergy to metal, especially to titanium, is a poorly known subject in orthopedic surgery and is mostly found after arthroplasty. Here, we describe an original case of titanium allergy that developed after an anterior cruciate ligament (ACL) reconstruction of the left knee in a patient with a history of severe atopic dermatitis. Three years after the surgery, he returned to the clinic with the femoral cortical button in his hand; he removed the device from the wound when the skin spontaneously opened at the lateral part of the thigh. The wound healed with dressings without use of any antibiotics. Clinical and functional results were favorable and magnetic resonance imaging signal of the graft was normal. We ruled out the possibility of infection and the final diagnosis was allergy to titanium. This case demonstrates the need to investigate the presence of allergy to metal, including titanium, before an ACL reconstruction.

Keywords: **Knee, Anterior cruciate ligament reconstruction, Titanium, Hypersensitivity**

Immunologic reactions to metal orthopedic devices are still a controversial subject and even the terms are not well defined. "Allergy", "hypersensitivity", and "metal-related pathology" have all been proposed to refer to residual postoperative pain. In knee surgery, this concept of reaction to metal has been especially used in association with residual pain after a total knee arthroplasty but its application can be extended to cover more cases.

We describe a case of a 37-year-old man who underwent anterior cruciate ligament (ACL) reconstruction using a hamstring tendon autograft with a femoral cortical suspension device on the femoral side and a bioabsorbable screw on the tibial side. He presented with a cyst over the tibial screw, which is quite common. However, three years after the surgery, the patient himself removed the femoral titanium cortical button from a spontaneous wound on the lateral part of the thigh. The clinical and functional treatment results were favorable. To the best of our knowledge, this is the first description of such a case; no similar case could be found in the literature.

Received December 2, 2018; Revised January 3, 2019;
Accepted January 20, 2019
Correspondence to: Nicolas Bouguennec, MD
Sports Clinic of Bordeaux-Merignac, 4, rue Negrevergne, 33700 Merignac, France
Tel: +33-5-56-18-17-11, Fax: +33-5-56-18-17-11
E-mail: docteur.bouguennec@gmail.com

This is an Open Access article distributed under the terms of the Creative Commons Attribution Non-Commercial License (http://creativecommons.org/licenses/by-nc/4.0/) which permits unrestricted non-commercial use, distribution, and reproduction in any medium, provided the original work is properly cited.

Case Report

Three and a half years ago, a 34-year-old man came to our clinic for chronic instability of the left knee. He had sustained a knee injury while practicing judo two months before presentation. He had a positive Lachman test and a positive pivot shift test. He complained of frequent instability of the knee in daily activities. The X-ray findings were normal. Magnetic resonance imaging (MRI) showed a rupture of the ACL (Fig. 1) without any meniscal lesion. The patient had severe atopic dermatitis with severe general eczema. Allergy tests did not reveal any allergy to metal and he only took asthma medicines.

Given his age, his symptoms and MRI findings, ACL reconstruction was determined. ACL reconstruction was performed using a hamstring tendon autograft 3 months after the trauma

Copyright © 2019 KOREAN KNEE SOCIETY

Fig. 1. Preoperative T2 sagittal magnetic resonance imaging of the left knee showing the rupture of the anterior cruciate ligament.

by a senior surgeon (S.J.) using a RIGIDLOOP™ 30-mm Fixed Loop Implant (DePuy Synthes Mitek, Raynham, MA, USA) cortical button on the femoral side (inside-out technique through the anteromedial portal) and a bioabsorbable LIGAFIX® screw 9/30 (S.B.M., Lourdes, France) on the tibial side (Fig. 2). The surgery was uneventful and initial postoperative outcomes were satisfactory. Rehabilitation was started the day after surgery for ambulation recovery under full weight bearing with a brace and crutches used for one month.

Nine months after the surgery, the patient came to the clinic because of pain at the aperture of the tibial tunnel. A cyst around the tibial screw was observed (Fig. 3). As he complained of pain in the course of daily activities, the screw was removed with

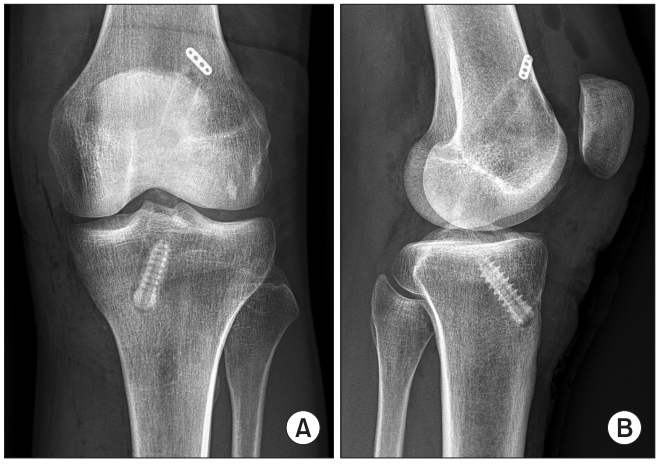

Fig. 2. Postoperative anteroposterior (A) and lateral (B) X-rays.

Fig. 4. Postoperative 9-month frontal T2 magnetic resonance imaging. The femoral cortical button (circle) is no longer located on the lateral femoral cortex but migrated in the soft tissues of the thigh.

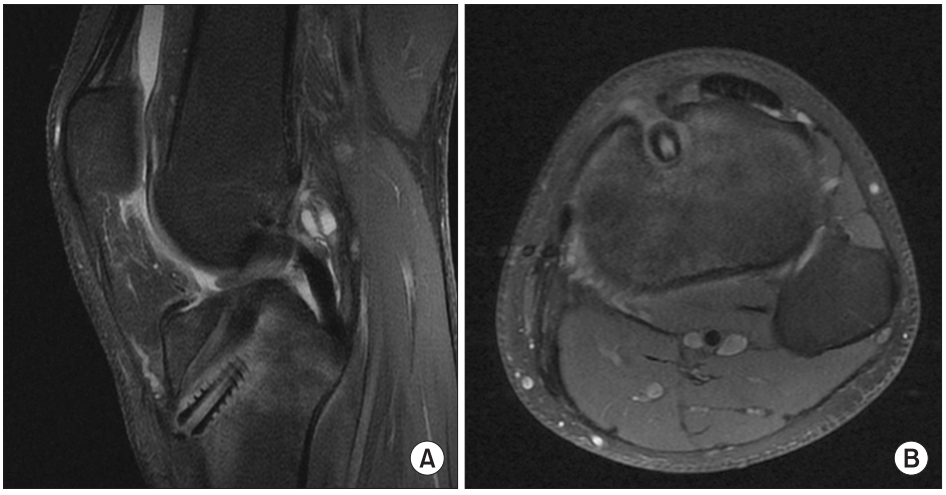

Fig. 3. Postoperative 9-month T2 sagittal (A) and axial (B) magnetic resonance imaging showing an increased signal intensity around the bioabsorbable screw beyond the tibial cortex indicating a tibial cyst.

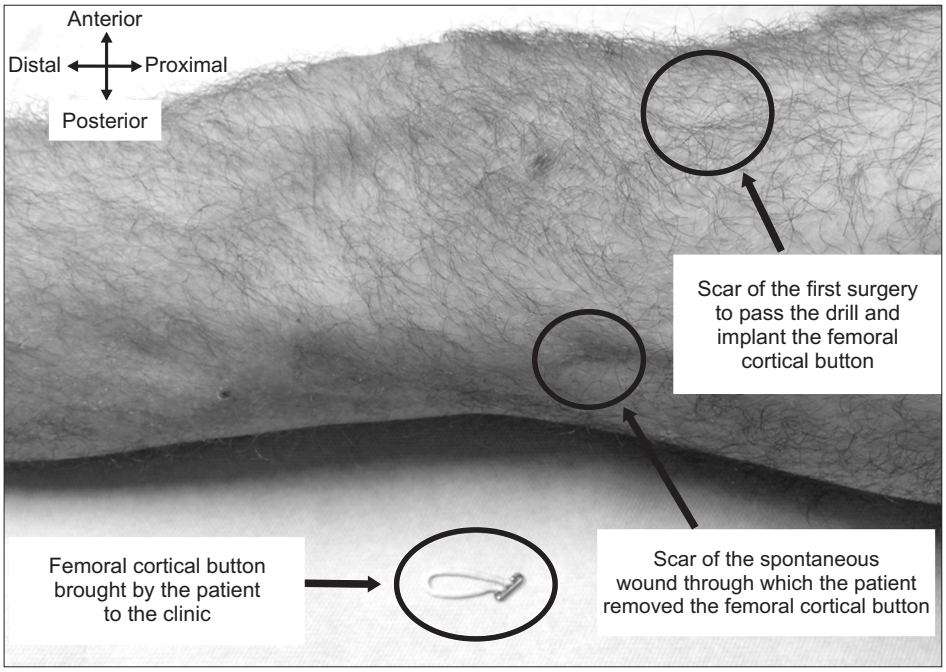

Fig. 5. Photograph of the lateral side of the left knee. The patient removed the cortical button by himself though the spontaneous wound located posterior to the scar made for drill passage in anterior cruciate ligament reconstruction.

curettage of the tibial tunnel. Intraoperative samples showed no sign of infection. On the 9-month postoperative MRI, the femoral cortical button was observed to be no longer fixed against the femoral cortex (Fig. 4); however, since no symptom was reported on the femoral side by the patient, no additional procedure was done. Clinical results were satisfactory, and the patient returned to his daily and sports activities without symptoms 3 months after the screw removal with curettage.

Three years after the surgery, the patient called the clinic because the cortical button had protruded from the skin: the skin had spontaneously opened 3 days before his call and he just pulled out the device which was deep in the wound. He was seen at the clinic the following day with the femoral cortical button in his hand; he had removed it from his thigh. The wound was located posterior to the scar left by the drill used to implant the cortical button device during the initial ACL surgery (Fig. 5). No antibiotics were prescribed to not hide an infection. The scar healed in one week with dressings and the clinical condition was good without any sign of infection. The patient was seen 6 months after the removal of the cortical button. Clinically, the Lachman test result was negative and the pivot shift test results was negative with a full range of motion. After the wound healed, the patient resumed the practice of judo without any instability. The MRI done three and a half years after the ACL reconstruction showed normal signal and orientation of the ACL graft (Fig. 6). No abnormality was found at the distal femur and soft tissues of the thigh (Fig. 6). As all allergy tests had already been done for the patient before the removal of the cortical button, based on consultation with an allergist, the established diagnosis was hypersensitivity to titanium and additional surgery on the femoral side was considered unnecessary.

Fig. 6. T2 sagittal magnetic resonance imaging at more than 3 years of follow-up after removal of the femoral cortical button. The signal of the anterior cruciate ligament is normal.

Discussion

We reported an original case of hypersensitivity to a titanium

femoral cortical button which led to the spontaneous expulsion of this cortical button with negative patch tests.

Hypersensitivity corresponds to an abnormal and excessive response to an antigen: hypersensitivity reactions can thus be allergic (immunologic) or non-allergic. The mechanism leading to surgical device rejection is not well understood, and descriptions remain confusing as several terms are used. With the development of immunology, the mechanisms of allergy have been analyzed. According to the Gell and Coombs classification[1], two types of mechanisms can describe immunologic responses related to hypersensitivity. A type I reaction occurs after exposure to an allergen through immunoglobulin E mediation causing mast cell degranulation and liberation of vasoactive mediators. This type of mechanism causes reactions from contact urticaria to anaphylactic shock hours or days after exposure but cannot explain postoperative metal allergies. A type IV reaction can also explain allergic reactions to an allergen and is also referred to as a CD4+ T-lymphocyte mediated reaction. An antigen-presenting cell presents the antigenic complex to T-helper cells activating T-lymphocytes and releasing pro-inflammatory cytokines. This cell-mediated delayed reaction leads to development of inflammatory lesions of tissues. Examples of type IV reactions include atopic dermatitis, psoriasis and eczema. This type of reaction could explain hypersensitivity to metal implants used in orthopedic surgery. We suspected this type of reaction was involved in the case we described, even though no inflammation was observed on the MRI taken 9 months after the surgery and the patient never experienced pain in the thigh before the spontaneous wound opening on the femoral side of the knee joint.

The prevalence of allergy and asthma has doubled in 30 years and is ranked 4th in the list of chronic diseases published by the World Health Organization. In particular, atopic dermatitis concerns 15% to 20% of adults in Northern Europe. The prevalence of cutaneous metal hypersensitivity in the population is between 10% and 15% in descending order: nickel, cobalt, and chromium[2,3]. This prevalence could increase to 25% for patients with a metal implant with a good functional result and to 60% for those with a poor functional result[2,4]. The concept of hypersensitivity to metallic orthopedic implants was introduced in the late 90s[3] and can cause pain, aseptic loosening and synovial reactions even though the link between symptoms and allergy remains uncertain. As reported by Merritt and Rodrigo[3], it is difficult to determine whether an allergy should be considered as a cause or an effect. Also, Bravo et al.[5] did not find any significant relation between total knee arthroplasty failure and a positive skin patch for metal allergy and did not confirm the etiology.

Allergy to titanium is, however, rarer and in a review of the literature, Wang et al.[6] found only 16 patients with allergy to titanium. As far as orthopedic surgery is concerned, they found only one case report of a patient who presented with fever more than seven months after surgical treatment of a hallux valgus. The patient had a positive patch test to titanium alloys. In 2006, Thomas et al.[7] reported a case report of a patient with eczema and malunion after an osteosynthesis of a metacarpal fracture with a titanium plate with the patch test showing no reaction to titanium, nickel, cobalt and chromium.

Allergy to titanium is a very rare pathology and is difficult to diagnose. If an implant is suspected to have caused hypersensitivity symptoms, other etiologies of pain must be explored before considering a reaction to metal, such as infection, chronic regional pain syndrome, implant malposition, prosthesis instability, and referred back/hip pain. Imaging, blood test and joint aspiration may be necessary. In this case report, C-reactive protein blood test was normal and symptoms resolved without any antibiotics eliminating the possibility of infection and the patient did not suffer from pain on the femoral side of the knee joint before removal of the cortical button. Once the diagnosis of hypersensitivity to metal is confirmed, patch tests should be performed although a positive patch test does not necessarily signify a joint hypersensitivity to metal[8]. Moreover, Wang et al.[6] found that of the 16 patients with an allergy to titanium, only 11 had a history of metal allergy and 13 had a positive patch test. This indicates that a negative titanium patch test does not exclude the possibility of a titanium allergy. In our case, patch tests did not detect any reaction to metal including titanium.

In the case of hypersensitivity to an implant, no treatment recommendations exist. In orthopedic surgery, most studies on hypersensitivity concern prostheses. For cutaneous reactions such as eczema and dermatitis after implantation, which are quite rare, a local dermatologic treatment (local or systemic use of steroids) can be tried and medical treatment should first be considered, but once again no recommendation exists. If symptoms do not improve or become severe, surgery may be needed. Titanium is the best option for implants in case of revision, and the concept of "hypersensitivity-friendly" implants (made of titanium alloy or zirconium)[2] has recently been developed. If the patient has an allergy to titanium or titanium alloys, another option must obviously be chosen. Sun et al.[9] recently reported cases of implant failure after cranioplasty with titanium plates and suggested that allergy screening should be performed before a cranioplasty and Polyetheretherketone (PEEK) implants should be used if allergy to more than three metals is detected preoperatively. Ceramic is

also considered as an option in orthopedic surgery in case of an allergy to titanium[6]. In our case, the tibial screw was removed one year after the surgery but it was not a metal device and cyst formation is a known complication of bioabsorbable screws[10]. No additional surgery was performed on the femoral side and the wound spontaneously appeared on the lateral part of the thigh, distant from the scar of the primary surgery. Because of the favorable status for the 2 weeks of dressing, no additional surgery was done. Patch tests had already been done so no complementary exploration was carried out but the patient was advised to report it in case of subsequent surgery.

This case report suggests that a metal allergy, even to titanium, should be investigated before using an orthopedic metal device, even for arthroscopic surgery and ACL reconstruction as several devices are now manufactured with titanium. In the case of a metal allergy, a patch test analysis should be done and a non-metal device such as ceramic or PEEK should be used if needed. In our case, titanium was initially implanted as the patient had no history of positive patch tests to metal and a revision surgery was not required as the graft healed normally despite the removal of the femoral cortical button.

In conclusion, hypersensitivity to metal is a subject of debate. It is rarer for titanium and could explain symptoms like pain, healing problems or swelling after surgery. It occurs through a type IV reaction and could require the use of a ceramic implant when detected prior to surgery or the removal of an implant when hypersensitivity is confirmed by postoperative tests. We reported an original case of a patient who had severe dermatitis but no metal allergy. He pulled out the titanium femoral cortical button after an ACL reconstruction. As no evidence of infection was found and functional and clinical outcomes were favorable after removal of the device, hypersensitivity was concluded. This case suggests that questions about allergy to metal, including titanium, should be asked before ACL reconstruction if the patient has a history of allergic diseases.

Conflict of Interest

No potential conflict of interest relevant to this article was reported.

References

1. Gell PGH, Coombs RRA. The classification of allergic reactions underlying disease. In: Gell PGH, Coombs RRA, eds. Clinical aspects of immunology. Oxford: Blackwell Science; 1963.
2. Bao W, He Y, Fan Y, Liao Y. Metal allergy in total-joint arthroplasty: case report and literature review. Medicine (Baltimore). 2018;97:e12475.
3. Merritt K, Rodrigo JJ. Immune response to synthetic materials. Sensitization of patients receiving orthopaedic implants. Clin Orthop Relat Res. 1996;(326):71-9.
4. Akil S, Newman JM, Shah NV, Ahmed N, Deshmukh AJ, Maheshwari AV. Metal hypersensitivity in total hip and knee arthroplasty: current concepts. J Clin Orthop Trauma. 2018; 9:3-6.
5. Bravo D, Wagner ER, Larson DR, Davis MP, Pagnano MW, Sierra RJ. No increased risk of knee arthroplasty failure in patients with positive skin patch testing for metal hypersensitivity: a matched cohort study. J Arthroplasty. 2016;31: 1717-21.
6. Wang LF, Wu J, Zheng C, Li SL, Huang RR, Zhang JK. Long-term fever after hallux valgus surgery secondary to titanium allergy: a case report and review of the literature. J Foot Ankle Surg 2016;55:1282-6.
7. Thomas P, Bandl WD, Maier S, Summer B, Przybilla B. Hypersensitivity to titanium osteosynthesis with impaired fracture healing, eczema, and T-cell hyperresponsiveness in vitro: case report and review of the literature. Contact Dermatitis. 2006;55:199-202.
8. Hallab N, Merritt K, Jacobs JJ. Metal sensitivity in patients with orthopaedic implants. J Bone Joint Surg Am. 2001;83-A:428-36.
9. Sun Y, Hu Y, Yuan Q, Yu J, Wu X, Du Z, Wu X, Hu J. Association between metal hypersensitivity and implant failure in patients who underwent titanium cranioplasty. J Neurosurg. 2018. doi: 10.3171/2018.1.JNS171804 [Epub ahead of print]
10. Chevallier R, Klouche S, Gerometta A, Bohu Y, Herman S, Lefevre N. Bioabsorbable screws, whatever the composition, can result in symptomatic intra-osseous tibial tunnel cysts after ACL reconstruction. Knee Surg Sports Traumatol Arthrosc. 2018. doi: 10.1007/s00167-018-5037-9 [Epub ahead of print]