A Rare Case of Plastic Bronchitis Following Bronchial Thermoplasty

Barbarroja-Escudero J[1], Sánchez-González MJ[1], Ruíz-Peña A[2], Pérez-Labour RA[2], Rodríguez-Rodríguez M[1], Alvarez-Mon M[1]
[1]*Servicio de Enfermedades del Sistema Inmune-Alergia, Hospital Universitario Príncipe de Asturias, Departamento de Medicina y Especialidades Médicas, Universidad de Alcalá, Alcalá de Henares, Madrid, Spain*
[2]*Servicio de Neumología, Hospital Universitario Príncipe de Asturias, Departamento de Medicina y Especialidades Médicas, Universidad de Alcalá, Alcalá de Henares, Madrid, Spain*

J Investig Allergol Clin Immunol 2019; Vol. 29(4): 331-332
doi: 10.18176/jiaci.0400

Key words: Bronchial thermoplasty. Casts or plugs. Omalizumab. Plastic bronchitis. Uncontrolled severe asthma.

Palabras clave: Termoplastia bronquial. Moldes o tapones. Omalizumab. Bronquitis plástica. Asma severo no controlado.

Bronchial thermoplasty (BT) is a safe nonpharmacological procedure for treatment of uncontrolled severe asthma that was approved by the United States Food and Drug Administration in 2010 [1]. However, adverse events and complications have been reported and include bronchiectasis, inflammatory polyps, pulmonary cysts with pneumothorax, artery pseudoaneurysms with hemorrhage, or recurrent atelectasis from fibrin plugs [2-6]. We report a new case of bronchial plugs following BT with an unexpected outcome.

In May 2013, a 27-year-old atopic woman (never smoker) diagnosed with uncontrolled severe asthma was referred to our outpatient clinic. She had experienced progressive asthma symptoms for the previous 15 years. Moreover, she was allergic to house dust mites, pollens, fruits, nuts, and *Anisakis simplex*. She experienced severe systemic reactions to omalizumab requiring a premedication protocol for each dose to complete 16 weeks of treatment. She fulfilled the criteria for New York Heart Association (NYHA) class III-IV despite following the treatment shown in the Supplementary Table.

Skin prick testing (SPT) was performed with a common battery of aeroallergens (mites, pollens, danders), food allergens (*Anisakis simplex*, fish, shellfish, milk, egg, cereals, fruits, nuts, vegetables, legumes, profilin, and lipid transfer protein), and latex (ALK-Abelló). Both a negative control (50% glycerinated saline) and a positive control (histamine, 10 mg/mL) were used. Moreover, a specific study on mold allergens was performed using SPT (ALK-Abelló) and serum specific IgE levels (Thermo Fisher) for *Aspergillus fumigatus*, recombinant *Aspergillus* allergens (rAsp f 1, rAsp f 4, rAsp f 6), *Alternaria alternata*, recombinant *Alternaria* allergen (rAlt a 1), *Penicillium notatum*, *Candida albicans*, and *Cladosporium herbarum*. Serum total IgE, baseline tryptase, and specific IgE levels against the same aeroallergens, food allergens, and latex were analyzed (Thermo Fisher). General and specific laboratory tests were performed. Additional tests included antinuclear antibody testing, protein profiling, α-1 antitrypsin test, sweat test, and determination of immunoglobulins, angiotensin-converting enzyme, rheumatoid factor, and antineutrophil cytoplasmic antibodies. Pulmonary function was also assessed (diffusion capacity, exercise testing, sleep studies, and echocardiography).

SPT was positive (wheal ≥3 mm greater than negative control), as was serum specific IgE, to mites, pollens, *Anisakis simplex*, fruits, and nuts. The results for the other aeroallergens and foods tested were negative. The remaining laboratory tests yielded normal results. Pulmonary function and laboratory values are shown in the Supplementary Table. Chest x-ray and computed tomography revealed laminar atelectasis located in the right middle lobe, thus ruling out bronchiectasis and pulmonary nodules or infiltrates (Supplementary Figure). There were no data on hypoventilation syndrome, sleep apnea syndrome, diastolic dysfunction, or pulmonary hypertension. We also ruled out cystic fibrosis, allergic bronchopulmonary mycosis, and sarcoidosis.

Given the lack of improvement after the abovementioned treatments, 3-session BT (Alair Bronchial Thermoplasty System) was performed under conscious sedation in April-May 2015, as previously described [1]. Two hours after the last session, more than 20 white rigid bronchial casts were expelled after several cough attacks (Figure). Unfortunately, histopathology was impossible because the casts were obtained and photographed at home after the last session of BT (this procedure is normally performed in an outpatient setting). Therefore, given the patient's atopic asthma background, she was diagnosed with plastic bronchitis.

We report an unusual case of plastic bronchitis associated with uncontrolled severe asthma in which BT was decisive. Several weeks after performing BT, prednisone was tapered and discontinued over 6 weeks, and the patient maintained NYHA class I-II for over 3 years. Between the last hospital admission and BT, the patient had gained more than 20 kg

Figure. Cast measuring 10 cm in length showing the typical branching pattern of plastic bronchitis, expelled after the third bronchial thermoplasty session.

© 2019 Esmon Publicidad

of weight because of long-term treatment with prednisone at doses of 30 mg/d and the inactivity resulting from asthma. For this reason, she needed nocturnal oxygen for 8 hours. This was discontinued within a few weeks of BT (Supplementary Table).

From December 2017, the patient required new cycles of prednisone (40-50 mg/d for 2-4 weeks every 3 months), which was combined with roflumilast (500 µg/d). Although her weight increased further, thus complicating her unstable clinical situation, she did not require nocturnal oxygen or new aerosol cycles. Furthermore, the low blood eosinophil levels during follow-up, both before and after the prednisone cycles, ruled out an eosinophilic pattern. However, given the aggressiveness of BT, we would have tried monoclonal antibody therapy (anti–IL-5 agents) if it had been available at the time (Supplementary Table).

Plastic bronchitis is an extremely rare complication of unclear etiology. The few cases reported in adults [6-9] involve bronchial mucofibrinous plugs or casts in the tracheobronchial tree that may have caused severe airway obstruction [10]. Two types of casts (inflammatory [type 1] and noninflammatory [acellular or type 2]) have been associated with various clinical conditions [7,8]. Type 1 casts are associated with diffuse bronchial hypersecretory disorders (asthma, cystic fibrosis, allergic bronchopulmonary aspergillosis, and infection) and are composed of an eosinophilic infiltrate [7,8]. Type 2 casts are associated with cyanotic congenital heart diseases, sickle cell acute chest syndrome, and lymphatic diseases and are composed of mucinous, fibrinous, or chylous infiltrates [7,8]. Although these plugs could be considered eosinophilic in the present case, we think that they were caused by the inflammation resulting from the bronchial thermoplastic process itself. Remarkably, the patient did not have fever, new expectoration, or discomfort during the weeks following BT. The follow-up analysis revealed no apparent infection, and the bronchial exudate culture was negative for bacteria and fungi. She only had to use rescue salbutamol during the following 24 hours.

Interestingly, we observed a very significant clinical improvement after a strong cough causing expulsion of hard, rigid, and large casts, thus making bronchoscopic extraction unlikely. While bronchoscopic extraction may not have been viable in the present case, it could prove effective in cases with more flexible plugs. We think that each patient should be assessed individually.

In conclusion, we report an exceptional case of an adult woman diagnosed with uncontrolled severe asthma where BT provoked plastic bronchitis. However, the spontaneous expulsion of casts was key to a considerable clinical improvement. The case we report may shed light on the utility of this therapeutic modality in some cases of severe asthma, although the possibility of producing rigid plugs in the bronchial tree must always be considered.

Funding

This study was partially supported by the Programa de Actividades de I+D in research groups from Comunidad de Madrid en Biomedicina, reference B2017/BMD-3804 “Medicina individualizada traslacional en inflamación y cáncer”.

Conflicts of Interest

The authors declare that they have no conflicts of interest.

Previous Presentations

This study was presented in part, in poster form, at the Congress of the Sociedad Española de Alergología e Inmunología Clínica, October 2016, San Sebastián, Spain.

References

1. Nasim F, Iyer VN. Bronchial thermoplasty-an update. Ann Thorac Med. 2018 Oct-Dec;13(4):205-11.
2. Qiu M, Lai Z, Wei S, Jiang Q, Xie J, Qiu R, et al. Bronchiectasis after bronchial thermoplasty. J Thorac Dis. 2018 Oct;10(10):E721-E726.
3. Takeuchi A, Kanemitsu Y, Takakuwa O, Ito K, Kitamura Y, Inoue Y, et al. A suspected case of inflammatory bronchial polyp induced by bronchial thermoplasty but resolved spontaneously. J Thorac Dis. 2018 Sep;10(9):E678-E681.
4. Funatsu A, Kobayashi K, Iikura M, Ishii S, Izumi S, Sugiyama H. A case of pulmonary cyst and pneumothorax after bronchial thermoplasty. Respirol Case Rep. 2017 Dec 22;6(2):e00286.
5. Nguyen DV, Murin S. Bronchial artery pseudoaneurysm with major hemorrhage after bronchial thermoplasty. Chest. 2016 Apr;149(4):e95-7.
6. Facciolongo N, Menzella F, Lusuardi M, Piro R, Galeone C, Castagnetti C, et al. Recurrent lung atelectasis from fibrin plugs as a very early complication of bronchial thermoplasty: a case report. Multidiscip Respir Med. 2015 Mar 8;10(1):9.
7. Eberlein MH, Drummond MB, Haponik EF. Plastic bronchitis: a management challenge. Am J Med Sci. 2008;335:163-9.
8. Turgut T, In E, Özercan IH, Kaplan M. A case of plastic bronchitis. Arch Iran Med. 2014;17:589-90.
9. Kim EJ, Park JE, Kim DH, Lee J. Plastic bronchitis in an adult with asthma. Tuberc Respir Dis (Seoul). 2012;73:122-6.
10. Singhi AK, Vinoth B, Kuruvilla S, Sivakumar K. Plastic bronchitis. Ann Pediatr Cardiol. 2015;8:246-8.

Manuscript received February 18, 2019; accepted for publication April 12, 2019.

José Barbarroja-Escudero
Servicio de Enfermedades del Sistema Inmune-Alergia
Hospital Universitario Príncipe de Asturias
Departamento de Medicina y Especialidades Médicas
Universidad de Alcalá
Carretera Madrid-Barcelona Km 33.600
28805 Alcalá de Henares (Madrid), Spain
E-mail: jose.barbarroja@gmail.com; jose.barbarroja@uah.es

 © 2019 Esmon Publicidad

Supplementary Material - Table

Table. Evolution of the quality of life, treatment, pulmonary function, and laboratory tests. Bronchial thermoplasty was performed between April 2015 and May 2015.

	May 2013	June 2015	December 2017	March 2019
Quality of Life				
• Emergency room visits by year	12-15	-	-	-
• Hospital admissions by year	7-8	-	-	-
• NYHA functional class	III-IV	I	II	II
• ACT	8	20	18	17
Treatment				
• Budesonide/formoterol 160/4.5 µg	2 inhalations twice daily	2 inhalation twice daily	-	-
• Tiotropium bromide 2.5 µg	2 inhalations once daily	2 inhalations once daily	2 inhalations once daily	2 inhalations once daily
• Montelukast 10 mg	1	1	1	1
• Aerosol therapy with budesonide/ipratropium/ salbutamol/hypertonic saline	Frequent	-	-	-
• Chest physiotherapy	Frequent	-	-	-
• Long-term domiciliary oxygen therapy	At 2 liters/night	-	-	-
• Prednisone, mg/d	30	-	20	40-50
• Roflumilast, µg/d	-	-	-	500
• Fluticasone/formoterol 250/10 µg	-	-	2 inhalations twice daily	2 inhalations twice daily
Pulmonary Function				
• FVC, mL (%)	2 360 (70)	3 830 (112)	1 490 (44)	2 050 (60)
• FEV1, mL (%)	1 100 (37)	2 800 (94)	940 (32)	1 210 (41)
• FEV1/FVC, %	46	73	63	58
• FeNO, ppb	58	47	53	64
• BMI, kg/m^2	42	23	27	33
Laboratory Tests				
• Serum tryptase, µg/L	4.8	5.1	4.2	3.9
• Blood eosinophils, cells/µL (%)	210 (2.9)	130 (1.5)	240 (2.6)	100 (2.8)
• Serum total IgE, IU/mL	644	825	387	280

Abbreviations: NYHA, New York Heart Association; ACT, Asthma Control Test (ACT < 20, uncontrolled asthma; and ACT 20-25, controlled asthma); FVC, Forced vital capacity; FEV1, Forced expiratory volumen in 1 second; FeNO, Fractional exhaled nitric oxide (normal to 50); BMI, Body mass index (BMI >30, obese; BMI 26-30, overweight; BMI 20-25, healthy weight).

© 2019 Esmon Publicidad
doi: 10.18176/jiaci.0400

Supplementary Material - Figure

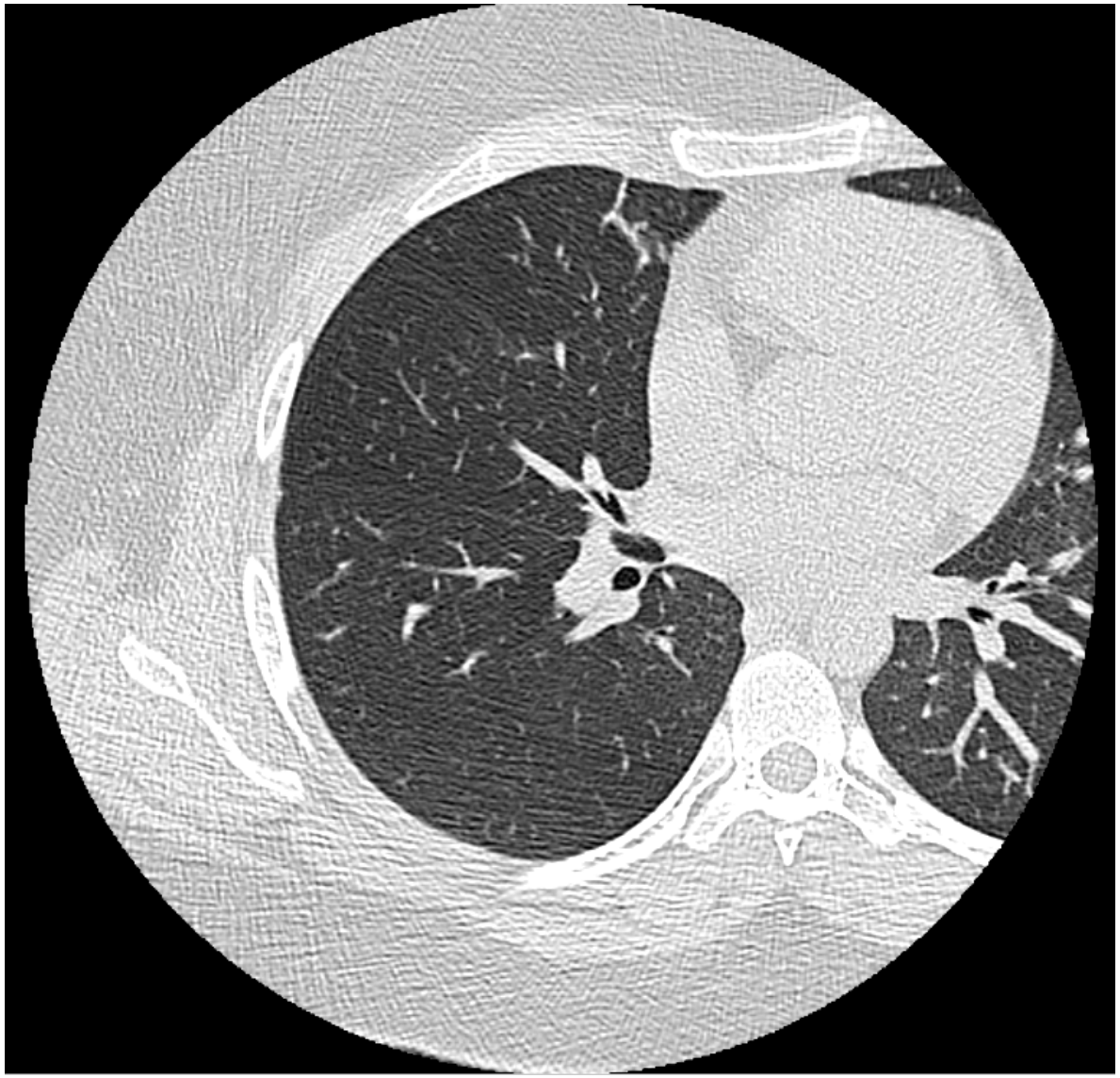

J Investig Allergol Clin Immunol 2019; Vol. 29(4) : 331-332
doi: 10.18176/jiaci.0400

© 2019 Esmon Publicidad