Letter to the Editor

Natural killer cell hyporesponsiveness and impaired development in a CD247-deficient patient

To the Editor:

The analysis of single gene defects in patients with primary immunodeficiency has provided important insights into the normal physiology of the immune system and is particularly valuable in those instances where the human and murine immune systems are different.[1] CD247 (T-cell receptor [TCR] ζ/CD3ζ) is one of the invariant chains that, along with CD3γ, CD3δ, CD3ε, and a clonotypic TCR heterodimer (αβ or γδ), forms the TCR antigen receptor complex expressed at the surfaces of T lymphocytes. However, CD247 is also expressed in natural killer (NK) cells, and although the biology of CD247 in the TCR complex is similar in mice and human subjects, there are marked differences between human and murine NK cells in the expression and association of activating NK receptors (CD16/FcγRIII, natural cytotoxicity receptor (NCR)3/NKp30, and NCR1/NKp46) with CD247.[2,3] Thus analysis of the rare patients deficient in CD247 provides unique insights into the biology of this signaling molecule in NK cells that cannot be obtained from the study of murine models.

Two CD247-deficient patients have been described previously.[4,5] Those studies focused on the effects of this deficiency on T cells, and although a somewhat reduced NK cell activity was noted, this population was not studied in detail. Here we report in-depth analyses of NK cells in a new case of inherited CD247 deficiency (see the Case report in this article's Online Repository at www.jacionline.org) because of loss of the translation initiation codon (see Fig E1, *A*, in this article's Online Repository at www.jacionline.org). NK cells from other family members, who were either heterozygous for the mutation in CD247 or homozygous for wild-type CD247 (see Fig E1, *B*), were also analyzed.

Loss of the initiation codon led to the complete absence of CD247 protein expression in the proband (see Fig E1, *C*), and correlation between levels of CD247 expression in $CD3^{-}CD56^{dim}$

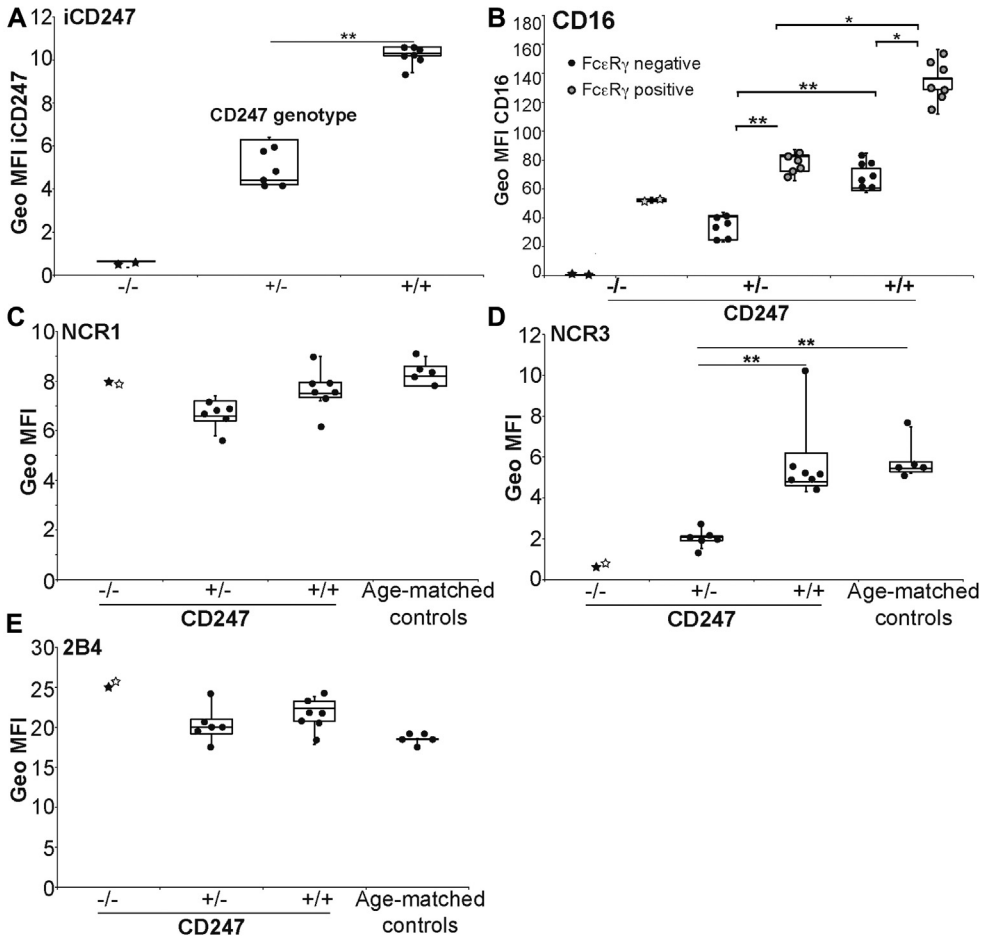

FIG 1. CD247 genotype correlates with expression of CD247 and CD16 and NCR3 expression on NK cells. NK receptor expression levels in $CD3^{-}CD56^{dim}$ NK cells from the $CD247^{-/-}$ patient were compared with those of $CD247^{+/-}$ and $CD247^{+/+}$ relatives or age-matched control subjects for intracellular CD247 **(A)**, CD16 on $FcεRγ^{+}$ or $FcεRγ^{-}$ cells **(B)**, NCR1 **(C)**, NCR3 **(D)**, and 2B4 **(E)**. Data are shown as geometric mean fluorescence intensity *(Geo MFI)*. ★/☆, First/second sample taken 3 months apart $*P < .05$ and $**P < .01$.

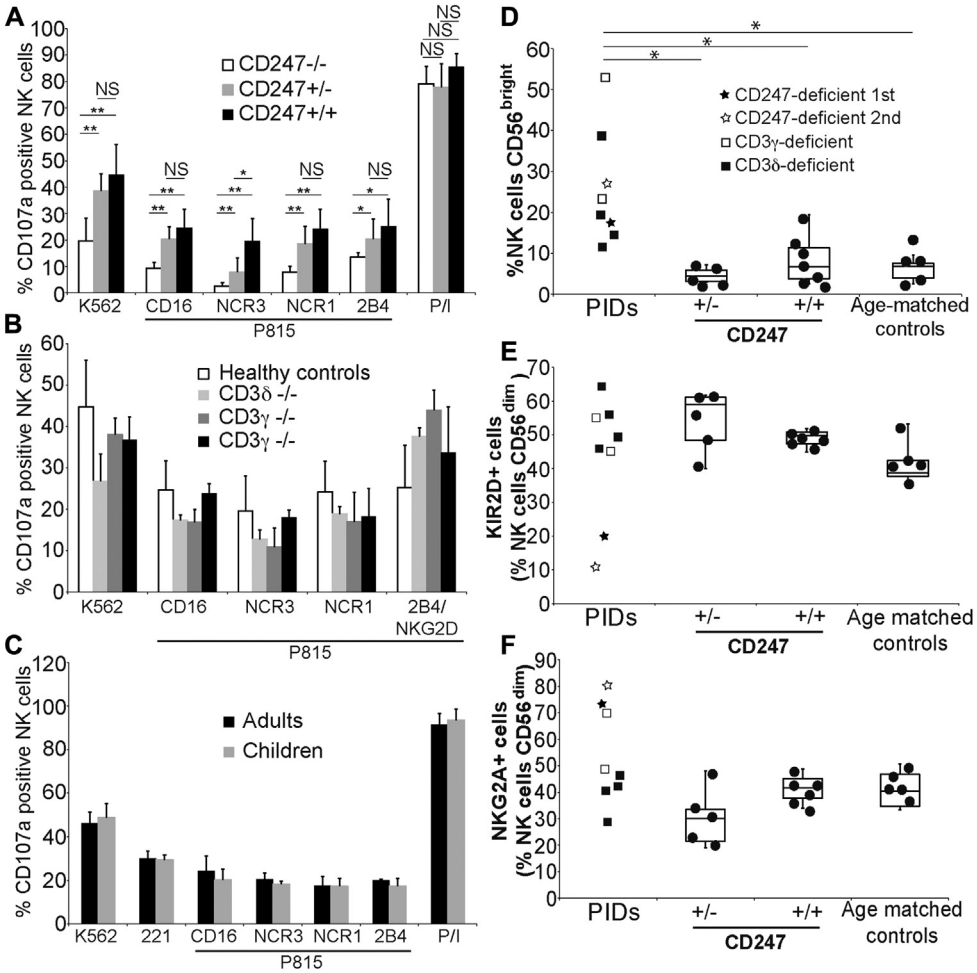

FIG 2. Hyporesponsiveness **(A-C)** and impaired maturation **(D-F)** of CD247-deficient NK cells. Comparative degranulation in response to the indicated stimuli for the 3 CD247 genotypes (Fig 2, *A*), CD3δ- and CD3γ-deficient patients versus healthy control subjects (Fig 2, *B*), and healthy adults versus children (Fig 2, *C*). CD3-deficient *(squares)* and CD247-deficient primary immunodeficiencies were compared among them and with $CD247^{+/-}$ and $CD247^{+/+}$ relatives or age-matched control subjects for peripheral blood $CD56^{bright}$ NK cells (Fig 2, *D*), KIR2D+$CD56^{dim}$ NK cells (Fig 2, E), and CD94/NKG2A+$CD56^{dim}$ NK cells (Fig 2, *F*). ★/☆, First/second sample. $*P < .05$ and $**P < .01$.

NK cells and genotype was observed in family members (Fig 1, *A*). In human NK cells the CD16, NCR1/NKp46, and NCR3/NKp30 receptors associate with CD247 or FcεRγ.[3] The level of surface CD16 on NK cells, both $Fc\varepsilon R\gamma^{-}$ and $Fc\varepsilon R\gamma^{+}$, segregated with the CD247 genotype of the donor (Fig 1, *B*, and see Fig E2, *A*, in this article's Online Repository at www.jacionline.org), strongly suggesting that the defective expression of CD247 underlies these phenotypic changes.

In contrast, NCR1, but not NCR3, expression in NK cells was comparable in all genotypes (Fig 1, *C* and *D*, and see Fig E2, *B*), suggesting that association with FcεRγ is sufficient for surface expression of NCR1, even in the absence of CD247, whereas NCR3 expression depends principally on CD247. Finally, as expected, surface expression of the 2B4 receptor, which is not known to associate with CD247, was normal in all subjects, irrespective of the CD247 genotype (Fig 1, *E*).

To gain insight into the functional effect of CD247 deficiency on NK cell function, we analyzed degranulation of IL-2–cultured NK cells from the patient and her relatives in response to receptor-mediated signals (shown in Fig 1) by using either specific mAb and P815 cells or K562 cells as targets (Fig 2, *A*). IL-2–cultured NK cells were used for these experiments because NK cell cytotoxicity is greatly reduced compared with that seen in adults in early life; however, exposure to IL-2 can reconstitute NK cell cytotoxic capacity to adult levels,[6] thus permitting a fair comparison of NK cell cytotoxic function from the infant patient and adult family members. The patient's NK cells responded poorly to all receptor-mediated signals, irrespective of their surface expression levels (Fig 2, *A*). However, the patient's NK cells did not have a general defect in cytotoxic machinery because their receptor-independent degranulation induced by phorbol 12-myristate 13-acetate plus ionomycin was normal. Although NK cell degranulation from $CD247^{+/-}$ subjects was always somewhat less than that observed for $CD247^{+/+}$ control subjects, these differences only reached statistical significance for stimulation through NCR3 (Fig 2, *A*), again suggesting that CD247 is particularly important for NCR3 expression and signaling.

The observed receptor-mediated NK cell hyporesponsiveness was specific for CD247 deficiency because it was not seen for NK cells from patients with CD3γ or CD3δ deficiencies (Fig 2, *B*) and was unrelated to age (Fig 2, *C*).

Given the hyporesponsiveness of NK cells from the CD247-deficient patient, her NK cell differentiation was compared with that of other family members and age-matched control subjects. Peripheral blood NK cells can be divided into 2 subsets: $CD56^{bright}$ and $CD56^{dim}$ cells. $CD56^{bright}$ NK cells produce cytokines after monokine stimulation and are considered progenitors of the $CD56^{dim}$ NK cells, which are more specialized for cytotoxicity.[7] Although the total number of $CD3^{-}CD56^{+}$ NK cells was comparable in the CD247-deficient patient and other family members and control subjects (data not shown), the proportion of $CD56^{bright}$ NK cells was considerably higher (Fig 2, *D*), suggesting defective NK cell differentiation. Consistent with this hypothesis, flow cytometric analysis of expression of additional surface markers in the $CD56^{dim}$ NK cell subset also revealed impaired NK cell maturation in the patient. In particular, late stages of the differentiation of $CD56^{dim}$ NK cells are characterized by a switch from CD94/NKG2A expression to killer immunoglobulin-like receptor (KIR) expression.[7] As expected, the majority of $CD56^{dim}$ NK cells from control subjects expressed KIR2D receptors, as did NK cells from patients with CD3γ or CD3δ deficiencies. However, only approximately 20% of $CD56^{dim}$ NK cells from the CD247-deficient patient expressed KIR2D (Fig 2, *E*), whereas greater than 80% of these cells expressed the CD94/NKG2A heterodimer (Fig 2, *F*), demonstrating a specific block in the late differentiation stages of $CD56^{dim}$ NK cells in this patient.

Our data suggest that CD247 deficiency affects NK cell development and function both directly and indirectly. In particular, an increased proportion of peripheral blood $CD56^{bright}$ NK cells was noted in all CD3/CD247-deficient patients examined, suggesting that the absence of functional T cells, rather than specifically CD247, affects NK differentiation. This observation is consistent with data from patients undergoing stem cell transplantation (SCT) in whom the first NK cells to repopulate the periphery have an immature phenotype and are less able to mediate cytotoxicity before T-cell recovery.[8] Interestingly, the ability of peripheral blood NK cells from the CD247-deficient patient to proliferate in mixed lymphocyte cultures *in vitro* was severely limited (see Fig E3 in this article's Online Repository at www.jacionline.org), but this phenotype could be reversed by IL-2 addition.

During differentiation, the ability of NK cells to respond to stimulation is finely tuned in function of the repertoire of inhibitory and activating receptors expressed by each NK cell.[9] Because CD247 deficiency causes decreased expression and function of a range of activating NK receptors, impaired signaling might underlie the partial block of NK cell differentiation and NK cell hyporesponsiveness, which were observed in the CD247-deficient patient. Importantly, similar changes in NK cell phenotype and function have not been seen in children with symptomatic congenital human cytomegalovirus (CMV) infection,[10] arguing against the hypothesis that the changes observed in the CD247-deficient patient are a consequence of CMV infection.

Our observations have direct implications for the clinical management of immunodeficient patients. Even when not directly fatal, episodes of infectious disease delay transplantation and negatively affect the outcome. Thus, because NK cells play a critical role in antiviral immunity, the potentiation of NK cell function, for example by means of low-dose therapy with IL-2, could be a useful strategy to minimize infections and aid in the management of these patients until SCT.

We thank all of the subjects who have contributed blood samples for these studies and Drs M. Lopez-Botet, J. Gil-Herrera, and M. L. Toribio for helpful discussion and advice.

Mar Valés-Gómez, PhD[a]*
Gloria Esteso, PhD[a]*
Cigdem Aydogmus, MD[b]
Alfonso Blázquez-Moreno, BSc[a]
Ana V. Marín, BSc[c]
Alejandro C. Briones, BSc[c]
Beatriz Garcillán, PhD[c]
Eva-María García-Cuesta, BSc[a]
Sheila López Cobo, BSc[a]
Sule Haskologlu, MD[d]
Manuela Moraru, MD[e]
Funda Cipe, MD[b]
Kerry Dobbs, BS[f]
Figen Dogu, MD[d]
Silvia Parolini, PhD[g]
Luigi D. Notarangelo, MD[f]
Carlos Vilches, MD, PhD[e]
Maria J. Recio, PhD[c]
José R. Regueiro, PhD[c]
Aydan Ikinciogullari, MD[d]
Hugh T. Reyburn, PhD[a]

From [a]the Department of Immunology and Oncology, National Centre for Biotechnology, CSIC, Madrid, Spain; [b]the Department of Pediatric Immunology, Istanbul Kanuni Sultan Süleyman Hospital, Istanbul, Turkey; [c]the Department of Immunology, Complutense University School of Medicine and Hospital 12 de Octubre Health Research Institute, Madrid, Spain; [d]the Department of Pediatric Immunology-Allergy, Ankara University School of Medicine, Ankara, Turkey; [e]Immunogenetics-HLA, Instituto de Investigación Sanitaria Puerta de Hierro, Madrid, Spain; [f]the Division of Immunology, Boston Children's Hospital, Boston, Mass; and [g]the Department of Molecular and Translational Medicine, University of Brescia, Brescia, Italy. E-mail: mvales@cnb.csic.es. Or: htreyburn@cnb.csic.es.

*These authors contributed equally to this work.

Supported by grants from the Fondo de Investigación Sanitaria (PI11/00298, PS09/00181, FIS2011-00127 and PI08/1701), MINECO (SAF2011-24235, SAF2012-32293, SAF2010-22153-C03-03, SAF2014-54708-R and SAF2014-58752-R), the Comunidad de Madrid (grant S2010/BMD-2326 to M.V.-G. and S2010/BMD-2316 to J.R.R.), and the National Institutes of Health (grant 5R01AI100887-03 to L.D.N.).

Disclosure of potential conflict of interest: M. Vales-Gomez has received research support from the Regional Government of Madrid, MINECO, and Instituto Carlos III. A. C. Briones, B. Garcillan, E. -M. Garcia-Cuesta, S. Lopez-Cobo, M. J. Recio, and J. R. Regueiro have received research support and travel support from the Spanish Ministerio de economía y competitividad (MINECO). G. Esteso, A. Blazquez-Moreno, and H. T. Reyburn have received research support from Instituto Carlos III and MINECO. A. V. Marin, M. Moraru, and C. Vilches have received research support from MINECO. L. D. Notarangelo has received research support from the National Institutes of Health (NIH) and the March of Dimes; is a board member for the *Journal of Allergy and Clinical Immunology*, the *Journal of Clinical Immunology*, and Novimmune; is employed by Boston Children's Hospital Pediatric Associates; and has received royalties from UpToDate. The rest of the authors declare that they have no relevant conflicts of interest.

REFERENCES

1. Casanova JL, Conley ME, Seligman SJ, Abel L, Notarangelo LD. Guidelines for genetic studies in single patients: lessons from primary immunodeficiencies. J Exp Med 2014;211:2137-49.
2. Hollyoake M, Campbell RD, Aguado B. NKp30 (NCR3) is a pseudogene in 12 inbred and wild mouse strains, but an expressed gene in *Mus caroli*. Mol Biol Evol 2005;22:1661-72.
3. Lanier LL. Up on the tightrope: natural killer cell activation and inhibition. Nat Immunol 2008;9:495-502.

4. Rieux-Laucat F, Hivroz C, Lim A, Mateo V, Pellier I, Selz F, et al. Inherited and somatic CD3zeta mutations in a patient with T-cell deficiency. N Engl J Med 2006; 354:1913-21.
5. Roberts JL, Lauritsen JP, Cooney M, Parrott RE, Sajaroff EO, Win CM, et al. T-B+NK+ severe combined immunodeficiency caused by complete deficiency of the CD3zeta subunit of the T-cell antigen receptor complex. Blood 2007;109: 3198-206.
6. Guilmot A, Hermann E, Braud VM, Carlier Y, Truyens C. Natural killer cell responses to infections in early life. J Innate Immun 2011;3:280-8.
7. Luetke-Eversloh M, Killig M, Romagnani C. Signatures of human NK cell development and terminal differentiation. Front Immunol 2013;4:499.
8. Nguyen S, Dhedin N, Vernant JP, Kuentz M, Al Jijakli A, Rouas-Freiss N, et al. NK-cell reconstitution after haploidentical hematopoietic stem-cell transplantations: immaturity of NK cells and inhibitory effect of NKG2A override GvL effect. Blood 2005;105:4135-42.
9. Shifrin N, Raulet DH, Ardolino M. NK cell self tolerance, responsiveness and missing self recognition. Semin Immunol 2014;26:138-44.
10. Noyola DE, Fortuny C, Muntasell A, Noguera-Julian A, Munoz-Almagro C, Alarcon A, et al. Influence of congenital human cytomegalovirus infection and the NKG2C genotype on NK-cell subset distribution in children. Eur J Immunol 2012;42:3256-66.

http://dx.doi.org/10.1016/j.jaci.2015.07.051

CASE REPORT

A Turkish girl born in 2012, the first child of first-degree cousins (Fig E1), was healthy until 2 months of age, when she was admitted for sepsis because of a 10-day fever after routine vaccination (DaPT-polio/Hib and BCG). Immunoglobulin levels were normal (IgG, 1.260 mg/dL; IgA, 41 mg/dL; and IgM, 138 mg/dL). Paleness, bone marrow aspiration performed because of pancytopenia, and high transaminase and ferritin levels were compatible with hemophagocytic lymphohistiocytosis, and therefore she was started on steroids. On determination of CMV antigenemia (3000 copies/mL), she received intravenous ganciclovir and intravenous immunoglobulin. An underlying primary immunodeficiency was suspected because of consanguinity and hemophagocytic lymphohistiocytosis.

Lymphocyte subsets determined after cessation of steroid treatment were as follows: 0.5% $CD3^+CD16^-CD56^-$, 0.3% $CD3^+CD4^+$, 0.1% $CD3^+CD8^+$, 23% $CD19^+$, 23% $CD20^+$, 31% HLA-DR^+, and 36% $CD3^-CD16^+CD56^+$ cells and 2% recent thymic emigrants (RTE) cells evaluated as $CD4^+CD45RA^+CD31^+$ cells. T-lymphocyte activation in response to PHA was extremely low (5.5% $CD3^+CD25^+$ and 5.9% $CD3^+CD69^+$ cells). The patient's T cells showed a severe surface TCR expression defect, with partial defects in parents and some family members compatible with Mendelian inheritance. The patient's lymphocytes lacked intracellular CD247, and a final diagnosis of CD247 deficiency was reached by using molecular analyses (Fig E1).

Before hematopoietic stem cell transplantation (HSCT), she received antiviral treatment: ganciclovir, foscarnet, and CMV hyperimmunoglobulin for 17 months because of CMV antigenemia and ribavirin for 5 months because of recurring pneumonia associated with type 3 parainfluenza.

At 19 months of age, maternal haploidentical HSCT was performed after fully HLA-compatible donor screening failed within and outside her family. She received 14×10^6 $CD34^+$ cells/kg after protocol D nonmyeloablative conditioning in inborn errors according to the European Society for Blood and Marrow Transplantation 2011 guidelines for graft-versus-host disease (GvHD) prophylaxis (150 mg/m^2 fludarabine, 42 g/m^2 treosulfan, 10 mg/kg thiotepa, and 3 mg/kg/d cyclosporine).

The first week after HSCT, she had fever with CMV reactivation, severe oral and genital mucositis, and veno-occlusive disease and received foscarnet and defibrotide. Myeloid and platelet engraftment were detected at 11 and 16 days after HSCT, respectively. However, she had pneumonia with type 3 parainfluenza and rhinovirus, hypertension caused by renal failure, and biopsy-proved grade 2 skin acute GvHD afterward. Cyclosporine was stopped because of persistent high blood pressure. Because of ongoing acute GvHD despite steroid and mycophenolate mofetil administration, mesenchymal stem cells (2.6×10^6/kg) were infused at 32 and 49 days. Thereafter, infections regressed, CMV disappeared, and foscarnet was stopped. Blood pressure returned to normal levels, antihypertensive drugs were thus discontinued, and the patient was discharged at 83 days after HSCT. At 94 days, she was readmitted with urine flow reduction. Peritoneal dialysis was performed for 15 days because of 6.7 mg/dL creatinine and 119.6 mg/dL blood urea nitrogen. Renal functions and urine flow reached normal levels, and she was discharged, but a renal biopsy was compatible with tubulointerstitial nephropathy.

Six months after HSCT, she was readmitted with pneumonia. Her thorax computed tomographic scan revealed paratracheal, aortopulmonary, subcranial, and bilateral hilar microlymphadenopathies and bilateral nonspecific consolidations. Antimicrobial agents and antireflux treatment were started on determination of gastroesophageal reflux disease (GERD) with pH monitoring. At 7 months after HSCT, she had BCGitis, and therefore isoniazid, rifampin, and clofazimine were started. A month later, she was readmitted with pneumonia.

One year after HSCT, she presented with respiratory problems and hypoxemia. No bacteria, respiratory tract viruses, CMV, or EBV antigenemia were detected. Immune system evaluation revealed normal cellular and humoral parameters: total lymphocyte count, 6,100/mm^3; total neutrophil count, 8,500/mm^3; total eosinophil count, 1,100/mm^3; IgG, 1.300 mg/dL; IgA, 84.5 mg/dL; IgM, 181 mg/dL; 61% $CD3^+CD16^-CD56^-$ cells (normal range, 55% to 79%); 18% $CD3^-CD16^+CD56^+$ cells (normal range, 5% to 28%); 20% $CD3^+CD4^+$ cells (normal range, 26% to 49%); 41% $CD3^+CD8^+$ (normal range, 9% to 35%); 16% $CD19^+$ and $CD20^+$ (normal range, 11% to 30%); 21% HLA-DR (normal range, 18% to 38%); and 31% RTE cells, with a reasonable donor chimerism (97%). However, her lung radiographs showed bilateral perihilar infiltration, and a thoracic computed tomographic scan revealed widespread soft tissue densities, atelectasis, pleural thickenings, air-trapped areas in the lungs, and decreased volume in left lung. Bronchoscopic examination did not confirm any significant pathology, microorganism, or mycobacteria. Cytological investigation excluded GvHD. A biopsy performed on GERD findings, reduced food intake, and weight loss did not support such a diagnosis, and she did not respond to GERD treatment. Pulmonary hypertension and left ventricular hypertrophy were detected on cardiologic evaluation. She was treated with oxygen, salbutamol, intravenous steroids, wide-spectrum antibiotics, and antimycobacterial agents. However, her respiratory difficulty and bronchospastic attacks did not respond to any treatment modality. At 13 months after HSCT, she died of respiratory failure despite mechanical ventilation and administration of extracorporeal membrane oxygenation in the intensive care unit.

The work described here was carried out over a 6-month period (corresponding to 10-16 months of age), during which 3 blood samples were available for analysis. Age-matched control samples were obtained during the clinical work-up of a diverse group of children (17-24 months of age) admitted to the hospital in Istanbul for a variety of reasons, including respiratory tract infections, urinary tract infections, and gastroenteritis. PBMCs deficient in CD3δ or CD3γ were frozen samples from previously described patients.[E1,E2]

The study was conducted according to the principles expressed in the Declaration of Helsinki and approved by the Institutional Research Ethics Committees of the various hospitals involved. All participants or their guardians provided informed consent for the collection of samples and subsequent analyses.

REFERENCES

E1. Gil J, Busto EM, Garcillán B, Chean C, García-Rodríguez MC, Díaz-Alderete A, et al. A leaky mutation in CD3D differentially affects αβ and γδ T cells and leads to a Tαβ-Tγδ+B+NK+ human SCID. J Clin Invest 2011;121:3872-6.

E2. Recio MJ, Moreno-Pelayo MA, Kiliç SS, Guardo AC, Sanal O, Allende LM, et al. Differential biological role of CD3 chains revealed by human immunodeficiencies. J Immunol 2007;178:2556-64.

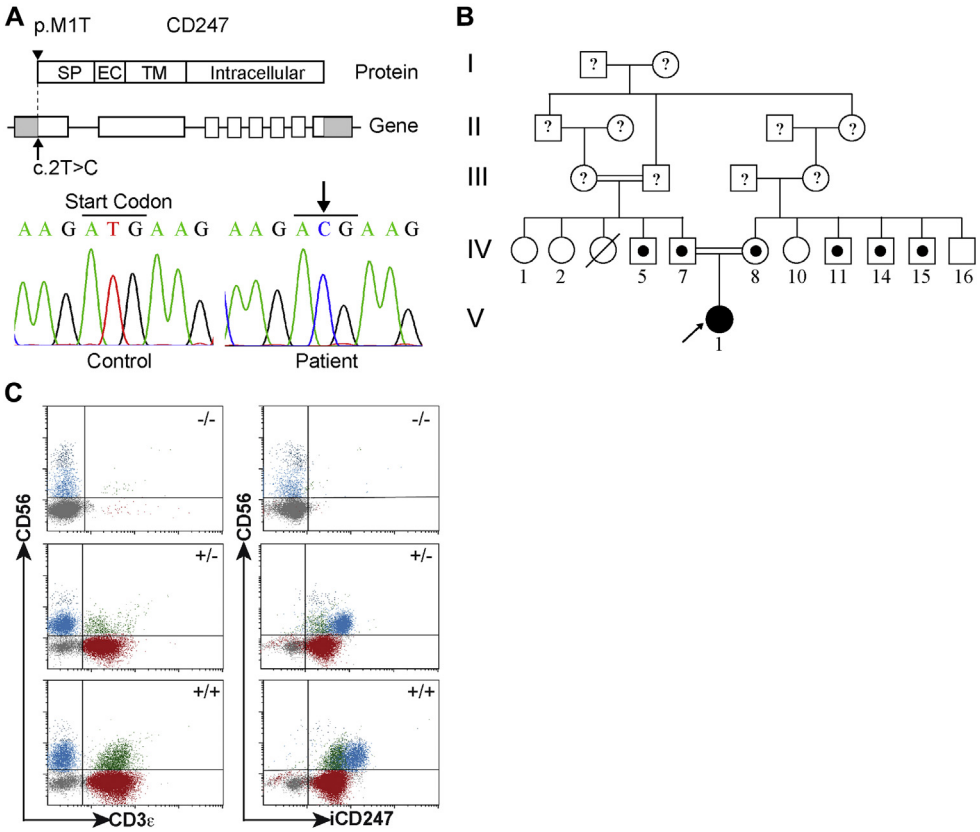

FIG E1. Genetic and phenotypic characterization of CD247 deficiency. **A,** The index patient inherited a CD247 mutation affecting the start codon that is shown within the CD247 protein (p.M1T or p.0) and gene (c.2T>C, g.147T>C) structure, as well as in the comparative chromatograms *(arrows)*. *EC*, Extracellular region; *SP*, signal peptide; *TM*, transmembrane region. **B,** Genetic pedigree. *Circles* indicate female subjects, and *squares* indicate male subjects (*slashes* indicate deaths). *Dotted* and *full symbols* indicate heterozygosity and homozygosity for the mutation, respectively. *Empty symbols* and *symbols marked with ?* indicate noncarrier and unknown mutation status, respectively. Only tested subjects are numbered. **C,** PBMCs from the CD247$^{-/-}$ patient, a relative heterozygous for the CD247 initiation codon mutation (+/−) and a family member homozygous for nonmutant CD247 sequence (+/+) were stained with directly labeled mAbs specific for CD3ε and CD56. The cells were then fixed, permeabilized, blocked with mouse serum, and stained with a directly labelled mAb specific for the cytoplasmic tail of CD247. The flow cytometric data were analyzed by using the Kaluza program (Beckman Coulter, Fullerton, Calif). *Red*, CD3ε^{+}CD56^{-} T cells; *green*, CD3ε^{+}CD56^{+} T cells; *light blue*, CD3ε^{-}CD56^{dim} NK cells; *dark blue*, CD3ε^{-}CD56^{bright} NK cells; *gray*, non-NK/non-T cells.

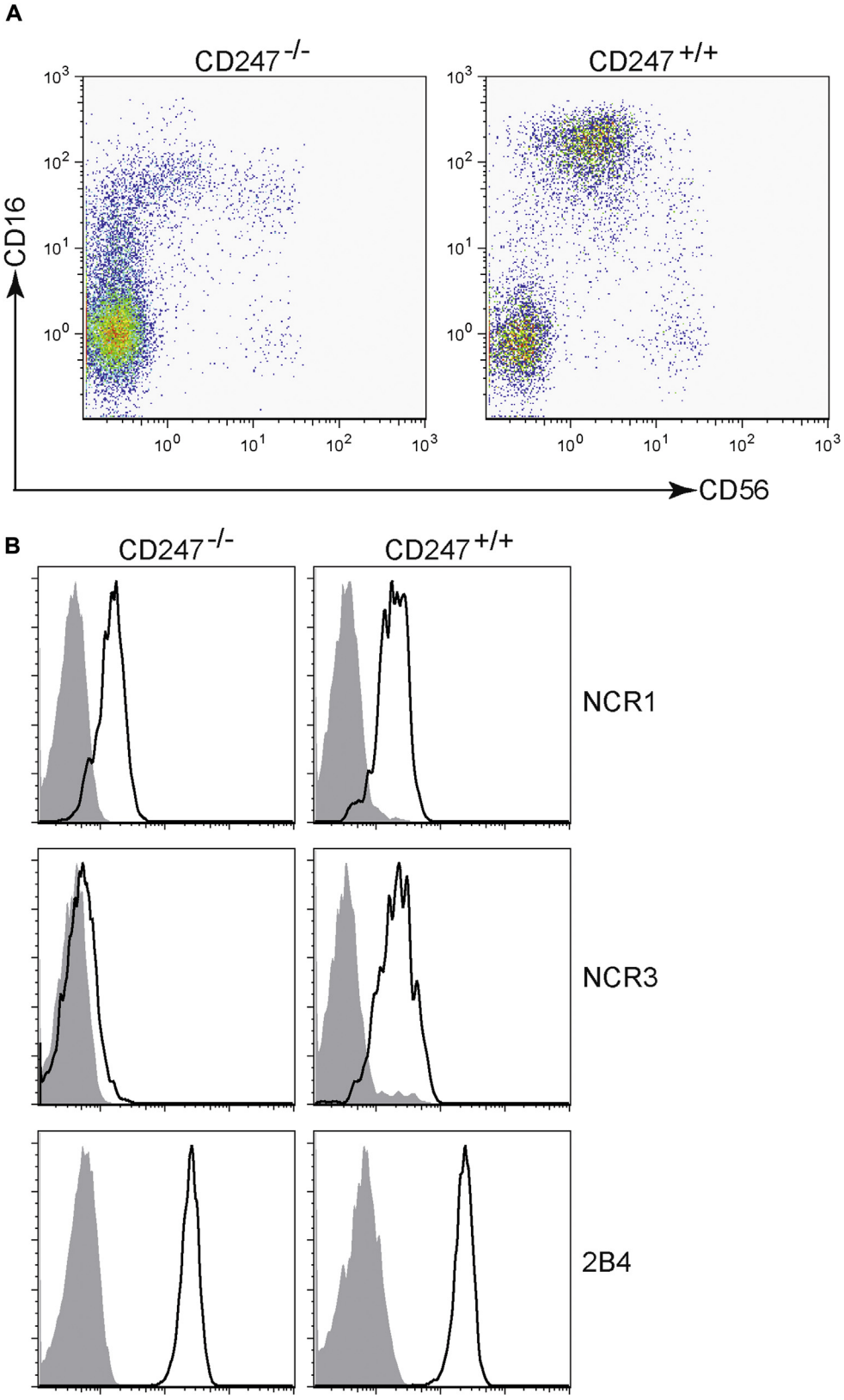

FIG E2. A, Representative dot plots showing staining for CD56 and CD16 on $CD3^-$ lymphocytes of the $CD247^{-/-}$ patient and a healthy control subject. **B,** Overlay histograms showing levels of NCR1, NCR3, and 2B4 expression on $CD3^-CD56^{dim}$ NK cells in the $CD247^{-/-}$ patient and a healthy control subject. *Shaded gray plots*, Isotype control staining; *solid black line*, NCR1, NCR3, or 2B4 staining.

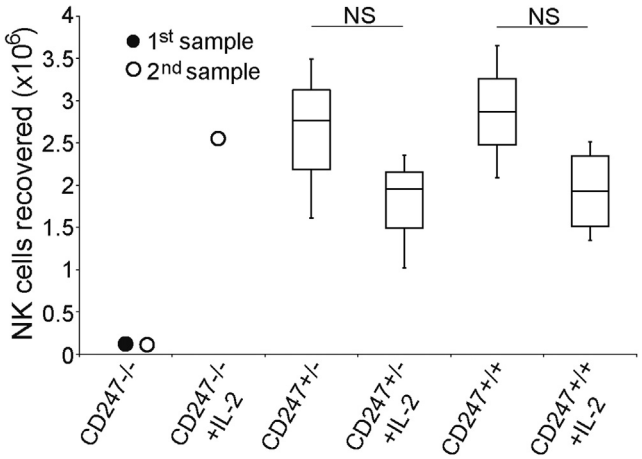

FIG E3. Deficient expansion of NK cells of the CD247$^{-/-}$ patient during *in vitro* culture can be remedied by addition of IL-2. PBMCs were purified by means of centrifugation on Ficoll-Hypaque and then placed in culture in RPMI 1640 medium with 10% AB^{-} human serum and irradiated (40 Gy) feeder cells (RPMI 8866, Daudi, and 221/AEH cells) in the presence or absence of 50 IU/mL rIL-2. After 7 days of culture, half the medium was removed and replaced with fresh medium (with or without IL-2). On day 10, the cells were harvested and counted, and aliquots of the cultures were stained with directly labeled mAbs specific for CD3 and CD56.