Check for updates

Clinical Letter

Persistent contact dermatitis following use of laurel oil

DOI: 10.1111/ddg.14693

Dear Editors,

A 53-year-old patient presented to our clinic with severely itchy erythematous papules and vesicles on her knees and thighs that had existed for eleven days (Figure 1a, b). She reported that 14 days earlier she had applied bay oil to both knees due to knee pain. This oil was acquired in southern Europe. No details of the ingredients were found on the label of the bottle (only inscription: Laurel Oil). The patient was known to have hypertension, but she did not take any regular medication. There was no history of other allergies, atopic dermatitis, allergic rhinoconjunctivitis or bronchial asthma. Total IgE was increased by 400 kU/l (reference range <100 kU/l).

Topical anti-inflammatory local therapy with class IV steroids was initiated with a suspected clinical diagnosis of allergic contact eczema. Despite this treatment, further lesions appeared in the areas of the trunk that were under pressure (Figure 1c), so that systemic prednisolone administration was initiated for five days, starting at 50 mg/d.

After eight days the patient's skin condition had improved and she was discharged. Gradual reduction of the prednisolone dose on an outpatient basis resulted in further deterioration of the findings. Complete healing of the skin changes was achieved after renewed topical steroid therapy over several weeks.

Histology revealed an acute eczematous reaction with acanthosis and spongiosis of the epithelium, a marked subepithelial edema and a band-like lymphohistiocytic infiltrate with sporadic eosinophilic granulocytes and extravasated erythrocytes (Figure 2a, b).

After healing, a patch test was carried out with the following series of tests from the German Contact Allergy Group (DKG): standard (DKG test series 1), topical preparations/excipients (18), preservatives (38), plant ingredients (15) as well as other fragrances and essential oils (44) in accordance with the recommendations of the current German S3 guideline [1, 2]. After 72 hours, there were three positive reactions to Compositae mix and sesquiterpene lactone mix, two positive reactions to parthenolide (feverfew) and ylang-ylang oil, as well as single positive reactions to Tanacetum vulgare (tansy) and lemongrass oil. However, bay leaf oil (from test series 44) was negative (Table 1, Figure 3a, b). The self-applied oil was not tested at the patient's request, for fear of reactivating the eczema.

Contact allergies to essential oils of laurel (Laurus nobilis) (leaves or seeds) are rare. The sesquiterpene lactone laurenobiolide is known to trigger a reaction to laurel. Many plants contain sesquiterpene lactones with antimicrobial, insecticidal and fungicidal properties that are useful in medicine or could be useful in future [3, 4]. Sesquiterpene lactones (e.g. custunolide) are strong contact allergens that can also trigger severe eczema. This can occur following contact with certain plants (especially Frullania; scale moss) and members of the Compositae (Asteraceae) family (e.g. lettuce,

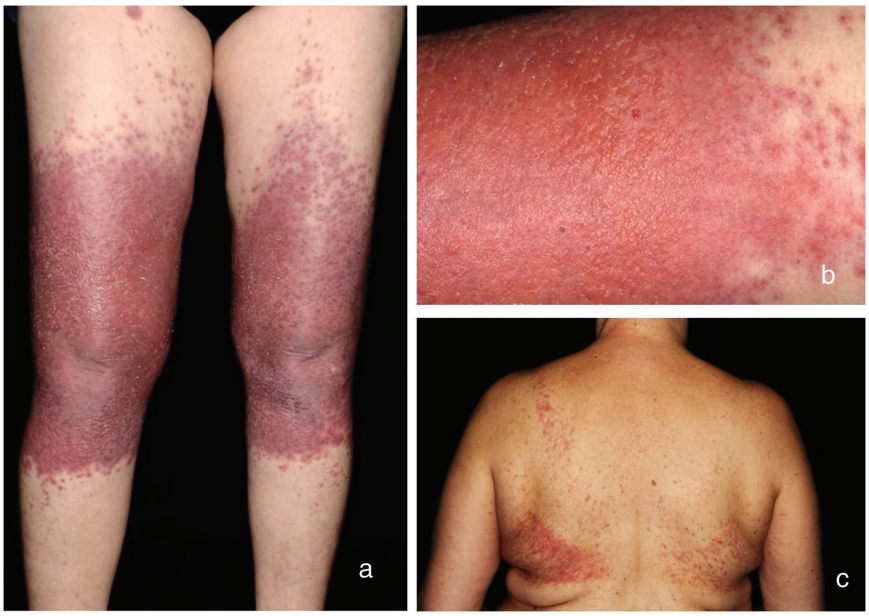

Figure 1 Clinical findings. Erythematous and partially livid large plaques and vesicles, as well as solitary papules in the marginal area, on the knees and ventral thighs (a, b). Foci on areas of the trunk exposed to pressure (c).

© 2022 The Authors. Journal der Deutschen Dermatologischen Gesellschaft published by John Wiley & Sons Ltd on behalf of Deutsche Dermatologische Gesellschaft.

This is an open access article under the terms of the Creative Commons Attribution-NonCommercial License, which permits use, distribution and reproduction in any medium, provided the original work is properly cited and is not used for commercial purposes.

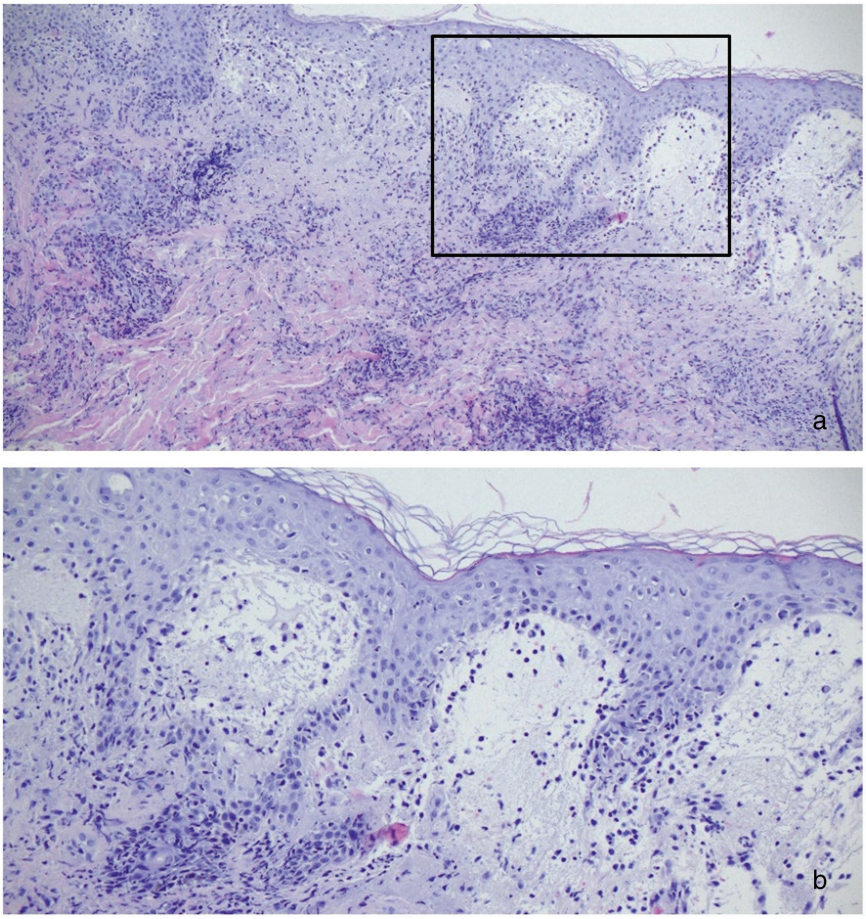

Figure 2 Histological findings of the skin biopsy from the left thigh (a). Excerpt from 2a: Eczematous reaction with acanthosis and spongiosis of the epithelium, subepidermal edema (b).

Table 1 Positive findings in the epicutaneous test (test series of the German Contact Allergy Group (DKG) standard series (DKG test series 1), topical preparations/ingredients (18), preservatives (38), plant ingredients (15), other fragrances and essential oils (44), as well as negative findings for bay leaf oil. Numbers in parentheses refer to corresponding test fields in Figure 3.

Allergen	Severity of reaction after 72 h
Compositae Mix II *(1)*	+++
Sesquiterpene lactone mix *(4)*	+++
Parthenolide (feverfew) *(3)*	++
Ylang-ylang oil *(not illustrated)*	++
Tanacetum vulgare (tansy) *(2)*	+
Lemongrass oil *(5)*	+
Bay leaf oil *(6)*	Ø

artichokes, chamomile; cross-reactions are independent of the biological degree of relationship) [5–8]. Topical agents containing laurel oil can therefore be responsible for sensitization to sesquiterpene lactones or plants containing sesquiterpene lactones. In the evaluation of patch test data from the German Information Association of Dermatological Clinics (IVDK) on contact sensitization to plants of the Compositae family from 2007 to 2016, around 2 % of those tested in the control group and around 9 % in the group of florists showed positive reactions to the sesquiterpene lactone mix [9]. In addition, a retrospective multicenter analysis by Forkel et al. showed an increased risk of sensitization to Compositae Mix II (among others) in a small number of patients (n = 1690) with atopic diathesis [10].

A total of ten cases of allergic contact dermatitis to laurel oil or essential oils with demonstrable sensitization to laurel oil have been described to date, including the case presented here [11–18]. In 7/10 cases the symptoms occurred in female patients; the median age of onset was 49.3 years (range 26–63 years).

 © 2022 The Authors. Journal der Deutschen Dermatologischen Gesellschaft published by John Wiley & Sons Ltd on behalf of Deutsche Dermatologische Gesellschaft.

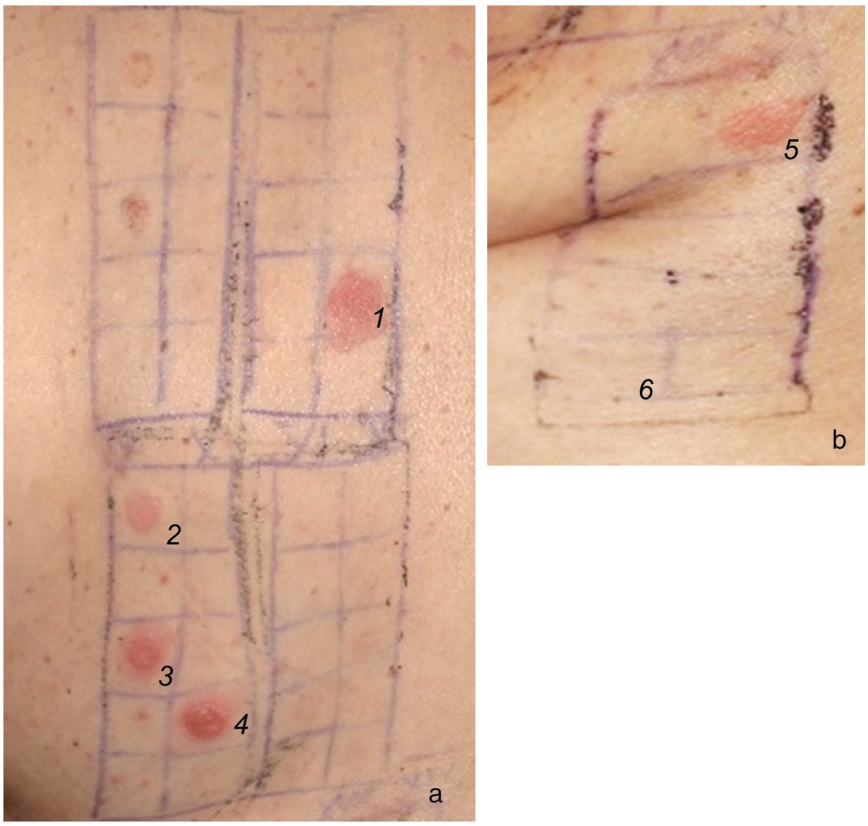

Figure 3 Findings of patch testing, selection. Compositae mix II (1), Tanacetum vulgare (tansy) (2), parthenolide (feverfew) (3), sesquiterpene lactone mix (4) (a). Lemongrass oil (5), bay leaf oil (6) (b).

Six of the affected patients had used bay oil specifically as a natural remedy; four used it for joint or muscle pain. In the other four cases, bay oil was used as a massage oil or as an ingredient in a commercial cosmetic oil. The clinical presentations were varied and ranged from localized/generalized contact dermatitis to erythema multiforme-like symptoms. One patient suffered from aerogenic contact dermatitis after two years of intensive use of essential oils (including lavender, jasmine and rosewood) in the form of aroma lamps, poultices and baths with severe eczema of the scalp, face, neck and hands [12]. A previous sensitization was only clearly traceable from the medical history in 4/10 cases.

Figure 4 shows the epidemiological and clinical properties as well as the distribution of selected information regarding medical history, therapy and course of the cases with type IV allergy to laurel oil described in the literature.

Systemic steroid administration was necessary to treat the skin changes in 9/10 patients; this was primary in three cases, and after previous unsuccessful topical steroid therapy in six cases. In one patient with localized contact dermatitis, topical therapy with hydrocortisone in combination with systemic antihistamines was effective [17].

In 5/10 cases there were comments about recurrence in the further clinical course, while in 4/10 cases there were repeated recurrences on the initially affected skin areas after eating or direct contact with herbs or spices. In the case of the patient who fell ill after intensive use of aromatherapy, his apartment needed to be renovated in order to prevent recurrence [12]. In this case, the patch test was positive for the oils used as well as bay, eucalyptus and bitter orange blossom oils. In the other cases, cross-sensitizations were traceable in the patch tests for plants/essential oils or sesquiterpene lactones that were tested. The patients who had relapses presented clinically with pronounced contact dermatitis (generalized or scattered) or airborne contact dermatitis. Our female patient reported repeated redness and itching of the former areas of eczema following contact with bay leaves.

Overall, the cases presented show that the use of bay oil can be associated with a significant risk of type IV sensitization with cross-sensitization.

The location of the bay laurel cultivation seems to have an effect on the contents of the plants (especially 1,8-cineole), which could result in various potentials for sensitization [19].

The reason for the lack of reaction to bay leaf oil in our female patient's DKG test series with the patch test is unclear. It is possible that the amount of the specific (in this case mainly sensitizing) sesquiterpene lactone of the purchased oil was insufficient in the oil of the test series. Analysis of

© 2022 The Authors. Journal der Deutschen Dermatologischen Gesellschaft published by John Wiley & Sons Ltd on behalf of Deutsche Dermatologische Gesellschaft.

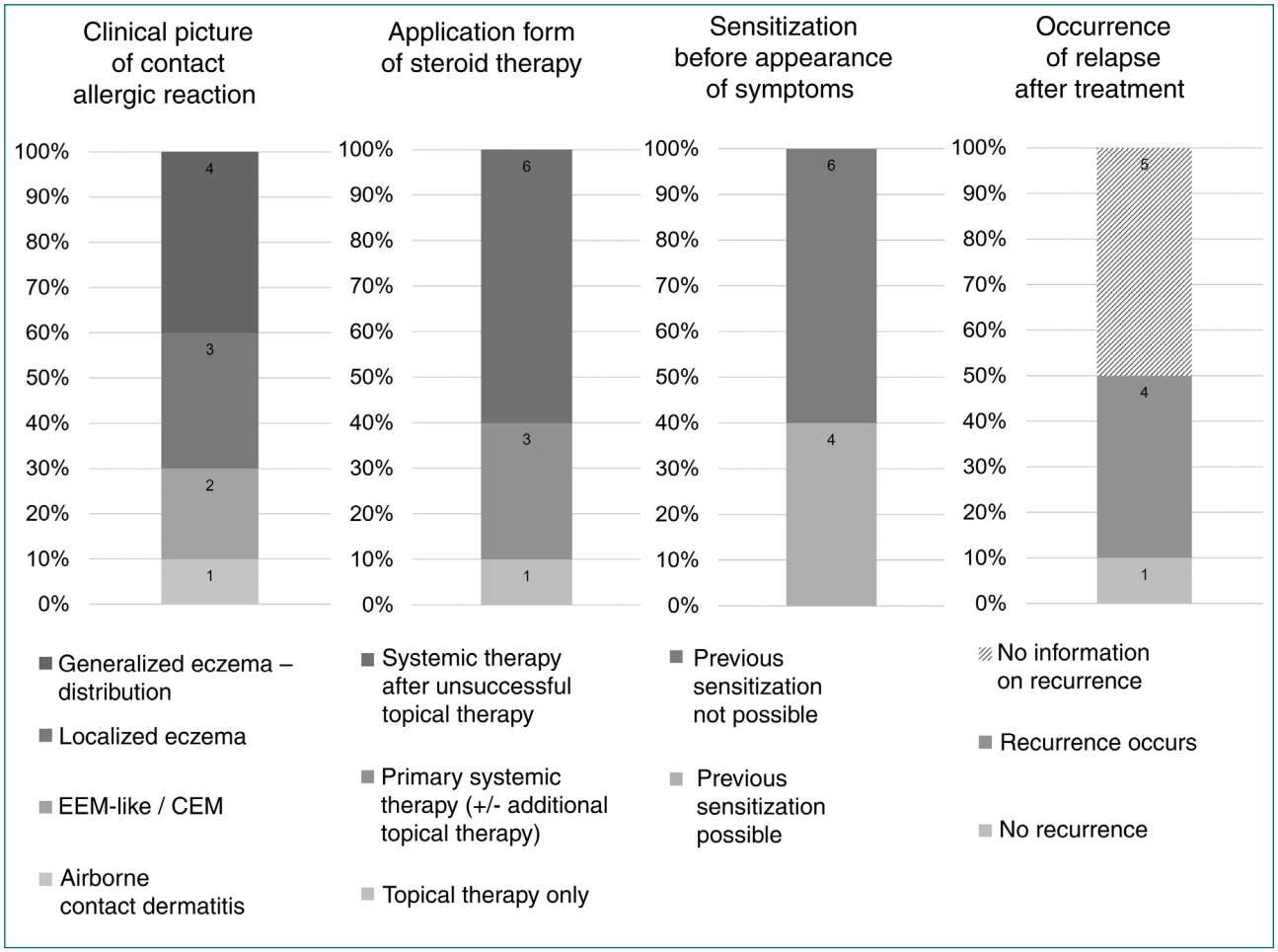

Figure 4 Type IV allergies to laurel oil (as referring to bay leaf as well as bay oil) reported cases 1995–2020: n = 10, median age: 49.3 years (26–63 years), females: 7, males: 3, intentional naturopathic use: 6, unintentional use: 4. Diagrams: clinical picture, treatment conducted, previous sensitization and occurrence of relapses.

the sesquiterpene lactones contained in both oils could help to clarify this. The affected skin areas were not exposed to sunlight to any relevant degree, so that a phototoxic or photoallergic reaction can be ruled out as the cause of the skin changes. The strong reaction to the sesquiterpene lactone mix as well as strong cross-reactions to test substances of the Compositae family (Compositae mix, feverfew, tansy) also suggests a clear sensitization to the sesquiterpene lactones contained in the oil that was purchased.

Contact dermatitis caused by oils from plants containing sesquiterpene lactones (e.g. laurel oil) often requires treatment with systemic steroids, since topical steroid therapy alone is usually insufficient.

Acknowledgement

Open access funding enabled and organized by Projekt DEAL.

Conflicts of interest

None.

Laura Parlow, Daniel Humme, Franziska C. Ghoreschi, Elsbeth Oestmann, Margitta Worm

Klinik für Dermatologie, Venerologie und Allergologie, Charité – Universitätsmedizin Berlin

Correspondence to

Dr. Laura Parlow
Clinic for Dermatology, Venereology and Allergology
Charité University Hospital, Berlin

Charitéplatz 1
10117 Berlin

E-mail: laura.parlow@charite de

© 2022 The Authors. Journal der Deutschen Dermatologischen Gesellschaft published by John Wiley & Sons Ltd on behalf of Deutsche Dermatologische Gesellschaft. | JDDG | 1610-0379/2022/00

References

1 Mahler V, Nast A, Bauer A et al. S3 guidelines: Epicutaneous patch testing with contact allergens and drugs - Short version, Part 1. J Dtsch Dermatol Ges 2019; 17: 1076–93.

2 Mahler V, Nast A, Bauer A et al. S3 Guidelines: Epicutaneous patch testing with contact allergens and drugs - Short version, Part 2. J Dtsch Dermatol Ges 2019; 17: 1187–207.

3 Saab AM, Guerrini A, Zeino M et al. Laurus nobilis L. Seed extract reveals collateral sensitivity in multidrug-resistant p-glycoprotein-expressing tumor cells. Nutr Cancer 2015; 67: 664–75.

4 Loizzo MR, Tundis R, Menichini F et al. Cytotoxic activity of essential oils from labiatae and lauraceae families against in vitro human tumor models. Anticancer Res 2007; 27: 3293–9.

5 Asakawa Y, Benezra C, Ducombs G et al. Cross-sensitization between Frullania and laurus nobilis: the allergen laurel. Arch Dermatol 1974; 110: 957.

6 Fousserau J, Claude Meller J, Benezra C. Contact allergy to Frullania and Laurus nobilis: cross-sensitization and chemical structure of the allergens. Contact Dermatitis 1975; 1: 223–30.

7 Stampf JL, Schlewer G, Ducombs G et al. Allergic contact dermatitis due to sesquiterpene lactones. Br J Dermatol 1978; 99: 163–9.

8 Paulsen E. Systemic allergic dermatitis caused by sesquiterpene lactones. Contact Dermatitis 2017; 76: 1–10.

9 Bauer A, Geier J, Schreiber S et al. Contact sensitization to plants of the Compositae family: Data of the Information Network of Departments of Dermatology (IVDK) from 2007 to 2016. Contact Dermatitis 2019; 80: 222–7.

10 Forkel S, Cevik N, Schill T et al. Atopic skin diathesis rather than atopic dermatitis is associated with specific contact allergies. J Dtsch Dermatol Ges 2021; 19: 231–40.

11 Hausen BM. Laurel allergy: cause, effect and consequences of external use of a so-called natural remedy. German Med Wochenschr 1985; 110: 634–8.

12 Schaller M, Korting HC. Allergy airborne contact dermatitis from essential oils used in aromatherapy. Clin Exp Dermatol 1995; 20: 143–5.

13 Ozden MG, Oztas P, Oztas MO, et al. Allergic contact dermatitis from Laurus nobilis (laurel) oil. Contact Dermatitis 2001; 45: 178.

14 Adişen E, Önder M. Allergic contact dermatitis from Laurus nobilis oil induced by massage. Contact Dermatitis 2007; 56: 360–1.

15 Athanasiadis GI, Pfab F, Klein A et al. Erythema multiforme due to contact with laurel oil. Contact Dermatitis 2007; 57: 116–8.

16 Uzuncakmak TK, Karadag AS, Izol B et al. Erythema multiforme like allergic contact dermatitis associated with laurel oil: a rare presentation. Dermatol Online J 2015; 21.

17 Brás S, Mendes-Bastos P, Amaro C et al. Allergic contact dermatitis caused by laurel leaf oil. Contact Dermatitis 2015; 72 (6): 417–9.

18 Staseviciene D, Chomiciene A, Malinauskiene L et al. Allergic contact dermatitis caused by laurel fruit oil. J Eur Acad Dermatol Venereol 2018; 32: e428–9.

19 Ozcan M, Chalchat JC. Effect of different locations on the chemical composition of essential oils of laurel (Laurus nobilis L.) leaves growing wild in Turkey. J Med Food 2005; 8: 408–11.

© 2022 The Authors. Journal der Deutschen Dermatologischen Gesellschaft published by John Wiley & Sons Ltd on behalf of Deutsche Dermatologische Gesellschaft. | JDDG | 1610-0379/2022/00

WILEY

Janssen-Sponsored Satellite Symposium at the 30th EADV Virtual Congress 2021

The art of joint forces: crafting psoriatic arthritis care for dermatologists

This virtual satellite symposium will focus on the necessity for practicing dermatologists to understand the burden of psoriatic arthritis in patients with psoriasis. It will emphasize how important it is that dermatologists detect early signals of psoriatic arthritis in patients with psoriasis and also understand why targeting IL-23 directly can be effective in treating and potentially also preventing the development of psoriatic arthritis for their psoriasis patients

janssen Immunology

PHARMACEUTICAL COMPANIES OF Johnson & Johnson

CP-255722