Nasal Inflammation in *Parietaria*-Allergic Patients Is Associated With Pollen Exposure

M Gelardi,[1] G Ciprandi,[2] S Buttafava,[3] N Quaranta,[1] S Valentina,[1] C Incorvaia,[4] F Frati,[3] and the Italian Parietaria Study Group
[1]*Section of Otolaryngology, Department of Neuroscience and Sensory Organs, University of Bari, Italy*
[2]*IRCCS-AOU San Martino, Genoa, Italy*
[3]*Medical and Scientific Department, Stallergènes, Milan, Italy*
[4]*Allergy/Pulmonary rehabilitation, ICP Hospital, Milan, Italy*

Key words: *Parietaria* pollen. Allergic rhinitis. Nasal cytology. Inflammation.

Palabras clave: Polen de parietaria. Rinitis alérgica. Citología nasal. Inflamación.

Allergic rhinitis (AR) is characterized by IgE-mediated reactivity that leads to inflammation of the nasal mucosa by a typical cellular pattern consisting of eosinophils, lymphocytes, and mast cells.

Several allergens can cause AR, although pollens are the most common source. Each type of pollen has a specific pollination season and biological properties that affect proinflammatory activity [1]. Allergic inflammation is closely related to pollen exposure [2].

The weed *Parietaria officinalis* is found throughout the Mediterranean area; it is a common source of sensitization, and its pollination period is long [3]. In southern Italy, many physicians consider *Parietaria* pollen to be a perennial allergen.

The aim of this study was to confirm the relationship between exposure to pollen and inflammatory events in a group of AR patients allergic only to *Parietaria* by assessing inflammatory cells monthly over a 1-year period. Our study population comprised 20 patients (11 males and 9 females, median age 35 years) with AR due to *Parietaria* pollen who were seen consecutively at the Rhinoallergology Outpatient Clinic of the Department of Otorhinolaryngology of the University of Bari, Italy in 2011.

The inclusion criteria were a confirmed diagnosis of AR according to the Allergic Rhinitis and Its Impact on Asthma guidelines [6] and monosensitization to *Parietaria* pollen. Nasal cytology was performed monthly during the study. The pollen count for the whole of 2011 was recorded.

Patients underwent the following procedures:

Skin prick test: Allergy was assessed by performing a skin prick test with a panel of the most common aeroallergens according to the recommendations of the European Academy of Allergy and Clinical Immunology [4]. The patient was considered to have *Parietaria*-induced AR if the nasal symptoms were consistent with sensitization.

Nasal cytology: The procedure was performed by scraping the middle part of the inferior turbinate with a Rhino-Probe (Arlington Scientific). The sample was smeared on a slide, fixed by air-drying, and colored using May-Grünwald Giemsa staining. Coloration quality and cell distribution were examined using microscopy (original magnification, x400); cell types were identified, and intracellular components were studied at x1000 in immersion. The mean number per 50 fields was calculated and reported as previously described [5].

Parietaria pollen count: We recorded 52 mean weekly *Parietaria* pollen concentration values and peaks (grains/m^3 of air) in Bari, Italy between January 1, 2011 and December 31, 2011.

The *Parietaria* pollen season started on the 98th day of the year and ended on the 289th day. We observed 2 peaks: the first was between April and May, and the second between late August and early September. The Figure shows the trend for the pollen season in 2011.

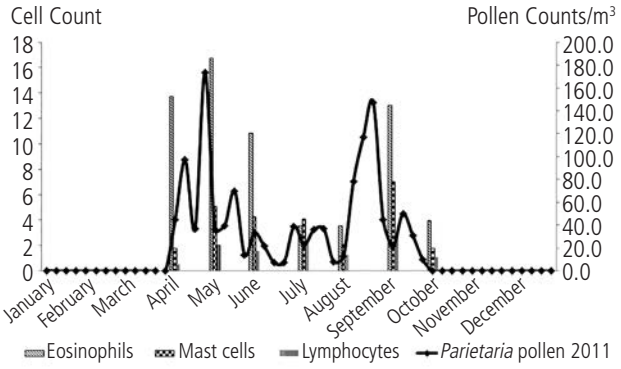

Figure. *Parietaria* pollen count and inflammatory cells (assessed monthly) during 2011.

Inflammatory cells appeared from April to October; the nasal infiltrate was present throughout the pollen season. Again, we observed 2 peaks: the first, and more intense, occurred during the first 3 months (April-June); the second was in September.

Eosinophils were the most frequent inflammatory cells detected in nasal mucosa. Mast cells and lymphocytes were less common. The trend can be seen in the Figure.

Nasal inflammation is indispensable for the development of symptoms in patients with AR. Severity of inflammation is typically dependent on the pollen species [1], and it has been reported that minimal persistent inflammation may also occur in patients with pollen allergy [2]. The most common allergic disorder, pollen allergy (also known as hay fever) affects up to 25% of the general population [6]. *Parietaria* allergy is very frequent in the Mediterranean area [7], and many physicians believe that the *Parietaria* pollen season may last the whole year, thus potentially affecting clinical practice (especially when programming allergen immunotherapy). In fact, most prescriptions for *Parietaria*-allergic patients involve perennial treatment.

© 2014 Esmon Publicidad

In the present study, we addressed this relevant issue by monitoring inflammation over a whole year and by measuring the pollen count. We analyzed 3 types of inflammatory cells, namely, eosinophils, lymphocytes, and mast cells, since these are the most commonly involved in allergic inflammation.

Eosinophils are the main effector cells in allergic inflammation; consequently, if no eosinophils are identified in nasal cytology samples, allergic inflammation can be ruled out. Moreover, the degree of eosinophilic infiltration is closely associated with symptom severity [1].

Lymphocytes play a key role in orchestrating allergic inflammation, since allergy is characterized by polarization of T_H2 cells. In fact, production of IgE and eosinophilic inflammation are controlled by T_H2-dependent cytokines such as IL-4 and IL-13.

Mast cells are involved in the early phase reaction; when activated by allergen exposure, they release the mediators responsible for the onset of symptoms.

The first relevant finding of our study was that the pollen season lasted for about 6 months during 2011. While this is a long season, it is not perennial. Of note, this trend was also observed in other years (data not shown). In addition, pollen was identified in waves, with peaks and absences. The second relevant finding was that inflammation was observed throughout the season and involved mainly eosinophilic infiltrate. The trend for allergic inflammation accurately mirrors that of the pollen season, with 2 main peaks: spring and September.

Our findings are important for clinical practice. Even though *Parietaria* allergy lasts 6 months, inflammation lasts only 4 months. Knowledge of the seasonality of nasal inflammation will enable us to explore innovative administration schedules for allergen immunotherapy in the near future. Indeed, further studies should be conducted to investigate whether patients with *Parietaria* allergy should undergo a single pre–coseasonal course, as is the case in other pollen species [8].

The main limitation of our study is its lack of clinical data. Therefore, further assessment of symptoms is mandatory in order to confirm the clinical value of this research.

In conclusion, our findings show that the *Parietaria* pollen season in Bari lasts about 6 months and that the duration of allergic inflammation is closely associated with the duration of the pollen season.

Acknowledgments

We thank all the members of the Italian *Parietaria* Study Group: Salvatore Barberi, Rachele Boccardo, Carlo Cavaliere, Concetta De Luca, Giuseppe Di Cara, Ignazio La Mantia, Massimo Landi, Simonetta Masieri, Lejla Pintaldi, and Luisa Ricciardi.

Funding

The authors declare that no funding was received for this study.

Conflicts of Interest

Serena Buttafava and Franco Frati are employees of Stallergenes Italia.

Giorgio Ciprandi and Cristoforo Incorvaia are scientific consultants for Stallergenes Italia.

References

1. Gelardi M, Maselli del Giudice A, Candreva T, Fiorella ML, Allen M, Klersy K, Marseglia GL, Ciprandi G Nasal resistance and allergic inflammation depend on allergen type. Int Arch Allergy Immunol. 2006;141:384-9.
2. Ricca V, Landi M, Ferrero P, Bairo A, Tazzer C, Canonica GW, Ciprandi G Minimal persistent inflammation is present also in patients with seasonal allergic rhinitis J Allergy Clin Immunol. 2000;105:54-7.
3. D'Amato G, Cecchi L, Bonini S, Nunes C, Annesi-Maesano I, Beherendt H, Liccardi G, Popov T, van Cauwenberge P. Allergenic pollen and pollen allergy in Europe. Allergy. 2007;62:976-90.
4. Dreborg S (Ed.). EAACI Subcommittee on Skin Tests. Skin tests used in type I allergy testing. Position Paper. Allergy. 1989;44:S22-31.
5. Gelardi M, Fiorella ML, Russo C, Fiorella R, Ciprandi G. Role of nasal cytology Int J Immunopathol Pharm. 2010;23:45-9.
6. Bousquet J, Khaltaev N, Cruz AA, Denburg J, Fokkens WJ, Togias A, Zuberbier T, Baena-Cagnani CE, Canonica GW, van Weel C, Agache I, Aït-Khaled N, Bachert C, Blaiss MS, Bonini S, Boulet LP, Bousquet PJ, Camargos P, Carlsen KH, Chen Y, Custovic A, Dahl R, Demoly P, Douagui H, Durham SR, van Wijk RG, Kalayci O, Kaliner MA, Kim YY, Kowalski ML, Kuna P, Le LT, Lemiere C, Li J, Lockey RF, Mavale-Manuel S, Meltzer EO, Mohammad Y, Mullol J, Naclerio R, O'Hehir RE, Ohta K, Ouedraogo S, Palkonen S, Papadopoulos N, Passalacqua G, Pawankar R, Popov TA, Rabe KF, Rosado-Pinto J, Scadding GK, Simons FE, Toskala E, Valovirta E, van Cauwenberge P, Wang DY, Wickman M, Yawn BP, Yorgancioglu A, Yusuf OM, Zar H, Annesi-Maesano I, Bateman ED, Ben Kheder A, Boakye DA, Bouchard J, Burney P, Busse WW, Chan-Yeung M, Chavannes NH, Chuchalin A, Dolen WK, Emuzyte R, Grouse L, Humbert M, Jackson C, Johnston SL, Keith PK, Kemp JP, Klossek JM, Larenas-Linnemann D, Lipworth B, Malo JL, Marshall GD, Naspitz C, Nekam K, Niggemann B, Nizankowska-Mogilnicka E, Okamoto Y, Orru MP, Potter P, Price D, Stoloff SW, Vandenplas O, Viegi G, Williams D; World Health Organization; GA(2)LEN; AllerGen. Allergic Rhinitis and its Impact on Asthma (ARIA) 2008 Update (in collaboration with the World Health Organization, GA2LEN and AllerGen). Allergy. 2008;63(Suppl. 86):8-160.
7. D'Amato G, Gentili M, Russo M, Mistrello G, Saggese M, Liccardi G, Falagiani P. Detection of *Parietaria* judaica airborne allergenic activity: comparison between immunochemical and morphological methods including clinical evaluation. Clin Exp Allergy. 1994;24:566-74.
8. Ciprandi G, Incorvaia C, Puccinelli P, Soffia S, Scurati S, Frati F. Polysensitization as a challenge for the allergist: the suggestions provided by the Polysensitization Impact on Allergen Immunotherapy studies. Expert Opin Biol Ther. 2011;11:715-22.

Manuscript received June 28, 2013; accepted for publication July 16, 2013.

Franco Frati
Medical and Scientific Department, Stallergenes Italy
Viale Certosa 2, Milan 20155, Italy
E-mail: ffrati@stallergenes.it

 © 2014 Esmon Publicidad

Diagnosis and Natural History of Food Protein–Induced Enterocolitis Syndrome in Children From a Tertiary Hospital in Central Spain

M Ruiz-García, C Escudero Díez, S Sánchez García, P Rodríguez del Río, MD Ibáñez
Allergy Department, Hospital Infantil Universitario Niño Jesús, Madrid, Spain

Key words: Food protein–induced enterocolitis syndrome. FPIES. Food allergy. Oral food challenge. Cow's milk allergy. Fish allergy.

Palabras clave: Síndrome de enterocolitis inducido por proteínas de alimentos. Enterocolitis por alimentos. Alergia a alimentos. Provocación oral con alimento. Alergia a leche de vaca. Alergia a pescado.

Food protein–induced enterocolitis syndrome (FPIES) is an uncommon and potentially severe non–IgE-mediated gastrointestinal food allergy characterized by delayed profuse vomiting and diarrhea that can progress to dehydration and shock [1]. The pathophysiology, prevalence, natural history, and diagnosis of FPIES remain poorly understood, and the few data available in the literature comprise single case reports or small case series [2-6]. One recently published large case series did not report patient outcome [7].

We performed a retrospective study covering a 12-year period (1999-2011) by screening the hospital medical record database for diagnosis and outcome of FPIES. Sixteen children were referred to our outpatient clinic for a food allergy work-up. The symptoms observed following exposure to the culprit food were consistent with FPIES [1], namely, repeated and delayed (1-3 hours) vomiting and/or diarrhea with (out) lethargy and no other explanation for the symptoms. The food allergy workup was performed according to the recommendations of the Spanish Society of Allergy and Clinical Immunology [8].

The study population comprised 10 boys and 6 girls aged between 11 months and 12 years (mean [SD], 50.6 [37.4] months) at the time of the study. All patients had symptoms the first time they ingested the offending food. Vomiting was recorded in 16 patients (100%), diarrhea in 9 (56%), lethargy in 4 (25%), irritability in 3 (19%), pallor in 3 (19%), and dehydration in 1 (6%) (Table). In all cases, the time between ingestion and onset of acute symptoms was over 2 hours. Before diagnosis, 14 patients (87.5%) had had more than 1 reaction (range, 1-4), and 5 (31%) had required emergency care because of dehydration and/or lethargy. Five had negative screening results for celiac disease, and 2 underwent intestinal biopsy. Fifteen (93.7%) children reacted to only 1 food protein.

Table. Food Protein–Induced Enterocolitis Syndrome: Clinical and Developmental Characteristics of the Study Population

Patient No./ Age at Time of Study, mo	Age at Diagnosis, mo	Culprit Food/ No. of Reactions Prior to Diagnosis	Diagnostic Symptoms by CH/OFC	Age at Evaluation, mo	
				Positive OFC	Negative OFC
1/11	6	Milk/2	V, D, L/NP	[a]	[a]
2/17	3	Milk/1	V, I/NP	13	
3/48	14	Milk/2	V, D, L/V		24
4/29	6	Milk/2	V, D/V	12	24
5/40	1	Milk/2	V, D/V, L	12, 22	36
6/43	2	Milk/3	V, D, I/D, L	13	24
7/39	1	Milk/2	V, D/NP	14, 22	36
8/24	6	Soy milk/1	V, D/V		14
9/60	30	Fish/3	V/NP	36	
10/108	Legume: 12 Fish: 20	Legume/1 Fish/3	V/V, P	Legume: 28, 48 Fish: 36, 84	Legume: 72
11/96	13	Fish/2	V, D/V, P, Dh	36, 60, 72	
12/144	7	Fish/3	V, L, Dh/NP	16, 24, 48, 60, 108	144
13/38	8	Fish/2	V, L/NP	18	24
14/30	6	Rice/2	V, P/D	12	24
15/72	7	Wheat/2	V, D, P/V	22, 48	
16/11	7	Chicken/2	V, P/NP	11[b]	[a]

Abbreviations: CH, clinical history; D, diarrhea; Dh, dehydration; I, irritability; L, lethargy; NP, not performed; OFC, oral food challenge; P, pallor; V, vomiting.
[a]Follow-up OFC not performed.
[b]Accidental exposure.

© 2014 Esmon Publicidad

Cow's milk was the trigger in 7 children (44%), with a mean age at diagnosis of 4.7 (4.6) months (range, 1-14 months); fish (sole, whiff, hake) was the main trigger in 5 (31%) patients, with a mean age at diagnosis of 15.6 (9.6) months (range, 7-30 months). Soymilk, rice, wheat, legume (lentil), and chicken were the trigger in 5 patients (Table).

Skin prick test and serum specific IgE results were negative in all cases except patient 6, whose serum specific IgE was 0.56 kU_A/L for cow's milk and <0.35 kU_A/L for cow's milk protein at diagnosis; he tolerated milk at 24 months. He had never experienced an immediate reaction to milk, even during a positive oral food challenge (OFC) at 13 months. Seven patients were diagnosed with FPIES based on clinical symptoms and 9 based on OFC. The median latency period between food intake and reaction was 2 hours (range, 50 minutes-4 hours), and symptoms were similar to those recorded at the first clinical visit.

Patients were followed at our clinic every 6-12 months (mean 8.2 [2.4] months) until tolerance was achieved. OFC was performed to confirm tolerance after the causal protein was removed from the diet. The mean time between the last FPIES reaction (clinical symptoms or diagnostic OFC) and the next OFC was 10.17 (2.32) months for cow's milk and 13.67 (7.40) months for solid foods. The mean age of resolution for all tolerated foods was 42.2 (39.13) months (range, 14-144 months). Five patients tolerated cow's milk with a mean age of 28 (6.57) months (range, 24-36 months), and 2 tolerated fish with a mean age of 84 (84.85) months (range, 24-144 months). The mean age at resolution for solid foods (fish, rice, legume) was 66.25 (56.95) months (range, 24-144 months); for milk (cow's and soy) the mean age at resolution was 26.33 (8.43) months (range, 14-36 months) (P=.017).

At the time of the study, 7 patients did not tolerate the trigger (mean age, 30.5 [25.25] months). Five patients had a positive OFC result: 1 patient to cow's milk (age 13 months), 1 patient to wheat (twice, at age 22 months and 4 years), and 3 patients to fish (age 3, 6, and 7 years). Patient 11 was treated in the intensive care unit for severe dehydration, hypotension, and loss of consciousness after the last fish OFC. Two patients did not undergo food challenge because they were too young (patients 1 and 16).

FPIES is often misdiagnosed and thus carries a risk of repeated reactions and additional and often unnecessary procedures. FPIES is a potentially severe illness, and the differential diagnosis must distinguish between IgE-mediated allergy, anaphylaxis, and sepsis [9,10]. There are no laboratory tests to identify which foods cause FPIES. All those patients who did not undergo the diagnostic OFC had a positive follow-up OFC, demonstrating that the clinical history is a good tool for early diagnosis.

Although the symptoms that appear during an OFC are usually mild, severe reactions may occur. Therefore, physician-supervised OFC should be used to monitor the development of tolerance; however, in our opinion, OFC is not necessary for diagnosis in patients with clear symptoms of FPIES.

The most frequent cause of FPIES in our series was cow's milk. This finding is consistent with the results obtained from other groups, including the largest series to date [7] and a Mediterranean population [6]. For solid foods, the most frequent eliciting food was fish, as in previous reports from Italy [6] and Spain [3]; other studies reported cereals as the most frequent solid food cause of FPIES [4,5,10]. The higher number of cases of FPIES caused by fish in our population can be explained by nutritional habits. Therefore, fish should always be considered a potential risk for FPIES, especially in Mediterranean populations.

According to previously published findings, the age at which patients in our population present symptoms and the age at which they achieved tolerance for cow's milk were significantly lower than the age at which they tolerated solid foods [6]. This may be because cow's milk is introduced earlier in the diet, but also because FPIES caused by solid food lasts longer. Therefore, we suggest performing follow-up OFC with cow's milk at 24 months or older and with solid food, specifically fish, even later, since the chances of tolerance before are low.

FPIES is a potentially severe disease. The clinical history is the main tool for early diagnosis, but clinician-supervised OFC is necessary for the follow-up of food tolerance. Cow's milk is the most common cause of FPIES in our population, followed by fish, which is tolerated later. This is the first published series of cases of FPIES caused by different foods in a Spanish population.

Funding

The authors declare that no funding was received for the present study.

Conflicts of Interest

The authors declare that they have no conflicts of interest.

References

1. Sicherer SH. Food protein-induced enterocolitis syndrome: case presentations and management lessons. J Allergy Clin Immunol. 2005;115:149-56.
2. Katz Y, Goldberg MR, Rajuan N, Cohen A, Leshno M. The prevalence and natural course of food protein–induced enterocolitis syndrome to cow's milk: a large-scale, prospective population-based study. J Allergy Clin Immunol. 2011;127:647-53.
3. Zapatero Remón L, Alonso Lebrero E, Martín Fernández E, Martínez Molero MI. Food-protein-induced enterocolitis syndrome caused by fish. Allergol Immunopathol. 2005;33:312-6.
4. Mehr S, Kakakios A, Frith K, Kemp AS. Food protein-induced enterocolitis syndrome: 16-year experience. Pediatrics. 2009;123;e459.
5. Nowak-Wegrzyn A, Sampson HA, Wood RA, Scott SH. Food protein-induced enterocolitis syndrome caused by solid food proteins. Pediatrics. 2003;111:829.
6. Sopo SM, Giorgio V, Dello Iacono I, Novembre E, Mori F, Onesimo R. A multicentre retrospective study of 66 Italian children with food protein-induced enterocolitis syndrome: different management for different phenotypes. Clin Exp Allergy. 2012;42:1257-65.

 © 2014 Esmon Publicidad

7. Ruffner MA, Ruymann S, Cianferoni A, Brown-Whitehorn T. Food protein-induced enterocolitis syndrome: insights from review of a large referral population. J Allergy Clin Immunol Pract. 2013;1:343-9.
8. Ibáñez MD, Alonso E, Blanco C, Cisteró A, Cuesta J, Fernández-Rivas M, Florido JF, García B, Laffond E, Matín F, Nieto A, Rico A, Rodríguez J. Comité de Alergia a alimentos. Metodología diagnóstica en alergia a alimentos. Alergol Inmunol Clin. 1999;14:50-62.
9. Coates RW, Weaver KR, Lloyd R, Ceccacci N, Greenberg MR. Food protein-induced enterocolitis syndrome as a cause for infant hypotension. West J Emerg Med. 2011;12:512-4.
10. Järvinen KM, Nowak-Węgrzyn A. Food Protein-Induced Enterocolitis Syndrome (FPIES): Current Management Strategies and Review of the Literature. J Allergy Clin Immunol Pract. 2013;1:317-22

Manuscript received July 15, 2013; accepted for publication July 18, 2013.

María Dolores Paloma Ibáñez Sandín
Servicio de Alergología
Hospital Infantil Universitario Niño Jesús
Avda. Menéndez Pelayo, 65
28009 Madrid, Spain
E-mail: mibanezs@salud.madrid.org

Chronic Urticaria in a Celiac Patient: Role of Food Allergy

E Heffler,[1,2] E Bruna,[1] G Rolla[2]
[1]*Allergy Outpatients' Clinic, ASL-TO3, Ospedale Civile "Edoardo Agnelli," Pinerolo (TO), Italy*
[2]*Allergy and Clinical Immunology, Department of Medical Sciences, University of Torino, Torino, Italy*

Key words: Chronic urticaria. Food allergy. Buckwheat. Celiac disease.

Palabras clave: Urticaria crónica. Alergia alimentaria. Trigo sarraceno. Enfermedad celíaca.

We present the case of a 37-year-old woman who was referred to our allergy outpatient clinic with an 18-month history of chronic urticaria. She was not taking medication, and her clinical history revealed celiac disease diagnosed about 3 years previously. The disease was very well controlled with a strict gluten-free diet, in which the patient consumed foods containing rice, soybean, and buckwheat flours.

No apparent correlation was found between ingestion of specific foods or drugs and the appearance of hives, which were present almost every day. Urticaria was controlled with levocetirizine dihydrochloride 5 mg/d but reappeared when she stopped taking the medication.

Physical examination was unremarkable except for a few hives on her back, abdomen, and lower limbs.

We performed a skin prick test with a standard panel of 6 common inhalant and 13 food allergens (including rice and soybean) and prick-by-prick test with buckwheat flour (as described elsewhere [1]). The results of the skin prick test were positive for house dust mites (*Dermatophagoides pteronyssinus* and *Dermatophagoides farinae*) and grass pollen; the results of the prick-by-prick test were positive for buckwheat flour (12-mm [histamine control, 7 mm]).

The patient was advised to avoid buckwheat-containing foods for at least 2 weeks and to try to reintroduce them into her diet after 2 weeks. She was also advised to take levocetirizine dihydrochloride 5 mg/d if needed.

We also assessed specific IgE to buckwheat (ImmunoCAP, Phadia), complete blood count, determination of C3 and C4 levels, erythrocyte sedimentation rate, C-reactive protein levels, and antibody titers (antithyroid, antinuclear, and anti-DNA).

One month after the allergy workup the patient attended our outpatient clinic for a checkup and reported that her urticaria disappeared when she avoided buckwheat-containing foods and reappeared when she tried to reintroduce them into her diet. She now avoids buckwheat, her urticaria has resolved completely, and she no longer needs to take levocetirizine dihydrochloride.

Specific IgE testing for buckwheat was positive (68 kU_A/L). The results of all other determinations were normal.

Chronic urticaria is a complex disease in which food allergy very rarely has a causative role. IgE-mediated food allergy is far more likely to present with acute urticaria as part of a

© 2014 Esmon Publicidad

generalized reaction. The pathogenesis of chronic urticaria is still not completely clear [2], although the disease has been associated with comorbid conditions (eg, systemic autoimmune disorders [including celiac disease], thyroid disorders, and chronic infections) and aggravating factors (physical stimuli [eg, heat, pressure, and dermographism], anti-inflammatory medication [eg, nonsteroidal anti-inflammatory drugs], and other drugs [eg, angiotensin-converting enzyme inhibitors]) [3].

In the present case, food allergy to buckwheat was the only trigger of urticaria that had a chronic course. The patient was eating buckwheat-containing foods almost every day, since buckwheat is a common supplement to cereal grains consumed by celiac patients. No comorbid conditions other than celiac disease or aggravating factors were found.

Buckwheat allergy is considered rare in Europe, although recent reports show that its prevalence is increasing, mostly because it is more often used as an ingredient in foods that are not supposed to contain it, thus making it a hidden allergen [1,4].

In a previous report, we identified 3 distinct patterns of clinical and laboratory characteristics of buckwheat-allergic patients, suggesting that specific allergens could be more frequently associated with clinical manifestations of varying severity [4]. The characteristics were a 16-kDa band in patients with predominantly gastrointestinal symptoms who were cosensitized to grass and wheat flour, a 25-kDa band in patients with predominantly cutaneous symptoms and a low frequency of cosensitization, and a 40-kDa band in patients with anaphylaxis and a low frequency of cosensitization. Unfortunately, since we did not perform immunoblotting, we were unable to assign this patient to one of these groups.

In conclusion, we report a case of chronic urticaria in a patient with celiac disease and allergy to buckwheat (one of the permitted flours for celiac patients). Our findings show that, even if IgE-mediated food allergy is a rare occurrence, it should be investigated in patients with chronic urticaria, particularly in groups with specific dietary restrictions, such as patients with celiac disease. Two recent reports showed that other food allergens (*Anisakis simplex* [5] and peach lipid transfer protein [6]) may cause chronic urticaria in specific cases.

Funding

The authors declare that no funding was received for the present study.

Conflicts of Interest

The authors declare that they have no conflicts of interest.

References

1. Heffler E, Guida G, Badiu I, Nebiolo F, Rolla G. Anaphylaxis after eating Italian pizza containing buckwheat as the food hidden allergen. J Investig Allergol Clin Immunol. 2007;17(4):261-3.
2. Papadopoulos NG, Agache I, Bavbek S, Bilo BM, Braido F, Cardona V, Custovic A, Demonchy J, Demoly P, Eigenmann P, Gayraud J, Grattan C, Heffler E, Hellings PW, Jutel M, Knol E, Lötvall J, Muraro A, Poulsen LK, Roberts G, Schmid-Grendelmeier P, Skevaki C, Triggiani M, Vanree R, Werfel T, Flood B, Palkonen S, Savli R, Allegri P, Annesi-Maesano I, Annunziato F, Antolin-Amerigo D, Apfelbacher C, Blanca M, Bogacka E, Bonadonna P, Bonini M, Boyman O, Brockow K, Burney P, Buters J, Butiene I, Calderon M, Cardell LO, Caubet JC, Celenk S, Cichocka-Jarosz E, Cingi C, Couto M, Dejong N, Del Giacco S, Douladiris N, Fassio F, Fauquert JL, Fernandez J, Rivas MF, Ferrer M, Flohr C, Gardner J, Genuneit J, Gevaert P, Groblewska A, Hamelmann E, Hoffmann HJ, Hoffmann-Sommergruber K, Hovhannisyan L, Hox V, Jahnsen FL, Kalayci O, Kalpaklioglu AF, Kleine-Tebbe J, Konstantinou G, Kurowski M, Lau S, Lauener R, Lauerma A, Logan K, Magnan A, Makowska J, Makrinioti H, Mangina P, Manole F, Mari A, Mazon A, Mills C, Mingomataj E, Niggemann B, Nilsson G, Ollert M, O'Mahony L, O'Neil S, Pala G, Papi A, Passalacqua G, Perkin M, Pfaar O, Pitsios C, Quirce S, Raap U, Raulf-Heimsoth M, Rhyner C, Robson-Ansley P, Alves RR, Roje Z, Rondon C, Rudzeviciene O, Ruëff F, Rukhadze M, Rumi G, Sackesen C, Santos AF, Santucci A, Scharf C, Schmidt-Weber C, Schnyder B, Schwarze J, Senna G, Sergejeva S, Seys S, Siracusa A, Skypala I, Sokolowska M, Spertini F, Spiewak R, Sprikkelman A, Sturm G, Swoboda I, Terreehorst I, Toskala E, Traidl-Hoffmann C, Venter C, Vlieg-Boerstra B, Whitacker P, Worm M, Xepapadaki P, Akdis CA. Research needs in allergy: an EAACI position paper, in collaboration with EFA. Clin Transl Allergy. 2012;2:21.
3. Zuberbier T, Asero R, Bindslev-Jensen C, Canonica GW, Church MK, Giménez-Arnau A, Grattan CE, Kapp A, Merk HF, Rogala B, Saini S, Sánchez-Borges M, Schmid-Grendelmeier P, Schünemann H, Staubach P, Vena GA, Wedi B, Maurer M; Dermatology Section of the European Academy of Allergology and Clinical Immunology; Global Allergy and Asthma European Network; European Dermatology Forum; World Allergy Organization. EAACI/GA2LEN/EDF/WAO guideline: definition, classification and diagnosis of urticaria. Allergy. 2009;64:1417-26.
4. Heffler E, Nebiolo F, Asero R, Guida G, Badiu I, Pizzimenti S, Marchese C, Amato S, Mistrello G, Canaletti F, Rolla G. Clinical manifestations, co-sensitizations, and immunoblotting profiles of buckwheat-allergic patients. Allergy. 2011;66:264-70.
5. Daschner A, Vega de la Osada F, Pascual CY. Allergy and parasites reevaluated: wide-scale induction of chronic urticaria by the ubiquitous fish-nematode Anisakis simplex in an endemic region. Allergol Immunopathol (Madr). 2005;33(1):31-7.
6. Asero R. Chronic urticaria caused by allergy to peach lipid transfer protein. J Investig Allergol Clin Immunol. 2013;23(3):208-9.

Manuscript received July 8, 2013; accepted for publication September 17, 2013.

Enrico Heffler
Allergologia – ASL-TO3
Ospedale Civile "Edoardo Agnelli"
Via Brigata Cagliari 39
10064 – Torino (Italy)
E-mail: enrico_heffler@yahoo.it

 © 2014 Esmon Publicidad

A Case of Wheat-Dependent Exercise-Induced Anaphylaxis After Specific Oral Immunotherapy

T Kusunoki,[1] K Mukaida,[1,2] A Hayashi,[1] F Nozaki,[1] I Hiejima,[1] T Kumada,[1] T Miyajima,[1] T Fujii[1]
[1]*Department of Pediatrics, Shiga Medical Center for Children, Shiga, Japan*
[2]*Kumiko Allergy Clinic, Kyoto, Japan*

Key words: Anaphylaxis. Food allergy. Oral immunotherapy.

Palabras clave: Anafilaxia. Alergia alimentaria. Inmunoterapia oral.

Specific oral immunotherapy (SOIT) has been attracting attention as a potentially novel approach in patients with food allergy [1]. SOIT involves oral administration of the offending food, starting at very low doses and increasing gradually until the patient can tolerate the usual daily intake. However, since the safety of SOIT has not been well established, this approach is not currently recommended for use in clinical practice [2]. Additionally, uncertainty about whether SOIT induces complete tolerance or only transient desensitization [1,3] means that patients must be closely monitored after desensitization. We report the case of a patient with wheat allergy who experienced 2 episodes of wheat-dependent exercise-induced anaphylaxis (WDEIA) after apparently successful desensitization.

The patient was a 7-year-old boy who experienced his first anaphylactic reaction 30 minutes after ingesting food containing wheat when he was 6 months old. The results of an ImmunoCAP test (Phadia) performed at 7 months of age were positive to wheat (54.1 kU_A/L). This value increased to 88.9 kU_A/L at 11 months of age. Although the results for egg white and soybean were also positive (9.43 kU_A/L and 7.56 kU_A/L, respectively), the patient tolerated both foods. He was diagnosed as having wheat allergy, and his parents were advised to eliminate wheat from his diet. Subsequent repeated ImmunoCAP testing showed that levels of IgE to wheat had gradually decreased. The ImmunoCAP results for wheat and ω-5-gliadin at 7 years of age were 0.83 kU_A/L and negative, respectively. However, the patient experienced 3 anaphylactic reactions following inadvertent ingestion of wheat. Symptoms included massive hives, angioedema, cough, wheeze, and breathing difficulty. The patient was referred to our clinic for wheat-specific oral immunotherapy. After admission, he was challenged with 0.3 g of noodles made from wheat flour, and, within 30 minutes, multiple hives appeared on his body, confirming that he was still allergic to wheat. Oral immunotherapy was then started at an initial dose of 0.1 g of noodles twice a day, which was increased 1.5-fold twice a week, and then 1.1-fold at each ingestion. The objective was to enable the patient to safely ingest 100 g of noodles. During the procedure, he developed localized hives at 2.7 g and 22 g, although the symptoms were not severe. During his stay in hospital (4 months), he did not perform strenuous exercise, but tolerated activities of daily living. At the end of his stay, he was able to eat 100 g of noodles. Further challenges with portions of other wheat-containing foods, such as bread, macaroni au gratin, and wheat-containing curry, elicited no symptoms. He was discharged and followed up in the outpatient clinic, with regular intake of wheat-containing products at home. Since he experienced no reactions during the following month, wheat was introduced to his school lunch menu.

Two months later, he developed massive hives, cough, wheezing, and breathing difficulty while playing soccer after eating wheat-containing foods at school. He was taken immediately to the emergency room, where he received intramuscular adrenaline and was kept under observation until the following day. Given the suspicion of WDEIA, he was advised not to exercise within 2 hours after eating wheat-containing foods and not to eat wheat-containing foods if he planned to exercise within 2 hours of eating. However, he experienced a similar anaphylactic reaction while running around at home after eating wheat-containing bread for breakfast. He was treated with an adrenaline autoinjector (Epipen) by his mother and taken to hospital. Strict avoidance of exercise after wheat-containing foods was again recommended, and he has since had no further episodes of anaphylaxis. Exercise without prior ingestion of wheat did not provoke symptoms. An exercise challenge after an intake of wheat was not performed because informed consent was not obtained.

The patient experienced 2 episodes of WDEIA, even though his ImmunoCAP values for wheat decreased and he had completed the desensitization protocol. The pathophysiology of WDEIA is not well understood; however, several working hypotheses have been put forward, including increased tissue activity, epitope recognition, altered gastrointestinal permeability, and autonomic aberrations [4]. Our findings suggest that, while SOIT can suppress allergic reaction induced by simple ingestion of wheat, it does not alter the additional mechanisms that induce WDEIA. Wheat and shellfish are the 2 main causes of food-dependent, exercise-induced anaphylaxis (FDEIA) [5], although a myriad of other food allergens have been associated with this condition [4]. A similar case of WDEIA during SOIT has been reported [6]. Consequently, patients with wheat allergy should be closely monitored for WDEIA, even after apparently successful desensitization with SOIT. Our experience indicates that a decreased ImmunoCAP value for wheat does not guarantee safety. While the ImmunoCAP level of ω-5-gliadin has proven useful for diagnosing WDEIA in adults, this is not necessarily so in children [7], as shown in the case we report. FDEIA has been reported after successful desensitization in a patient with milk allergy [8]. Although SOIT is a promising option for treatment of food allergy in the future, many unanswered questions remain, particularly concerning the stability of the effect. Thus, the possibility of FDEIA should be borne in mind, and careful follow-up is required after apparently successful desensitization.

Funding

The authors declare that no funding was received for the present study.

© 2014 Esmon Publicidad

Conflicts of Interest

The authors declare that they have no conflicts of interest.

References

1. Berin MC, Mayer L. Can we produce true tolerance in patients with food allergy? J Allergy Clin Immunol. 2013;131:13-22.
2. Burks AW, Jones SM, Boyce JA, Sicherer SH, Wood RA, Assa'ad A, Sampson HA. NIAID-sponsored 2010 guidelines for managing food allergy: applications in the pediatric population. Pediatrics. 2011;128:955-85.
3. Burks AW, Jones SM, Wood RA, Fleischer DM, Sicherer SH, Lindblad RW, Stablein D, Henning AK, Vickery BP, Liu AH, Scurlock AM, Shreffler WG, Plaut M, Sampson HA. Oral immunotherapy for treatment of egg allergy in children. New Engl J Med. 2012;367:233-43.
4. Du Toit GD. Food-dependent exercise-induced anaphylaxis in childhood. Pediatr Allergy Immunol. 2007;18:455-63.
5. Aihara Y, Takahashi Y, Kotoyori T, Mitsuda T, Ito R, Aihara M, Ikezawa Z, Yokota S. Frequency of food-dependent, exercise-induced anaphylaxis in Japanese junior-high-school students. J Allergy Clin Immunol. 2001;108:1035-9.
6. Calvani M, Sopo SM. Exercise-induced anaphylaxis caused by wheat during specific oral tolerance induction. Ann Allergy Asthma Immunol. 2007;98:98-9.
7. Morita E, Matsuo H, Chinuki Y, Takahashi H, Dahlström J, Tanaka A. Food-dependent exercise-induced anaphylaxis–importance of omega-5 gliadin and HMW-glutenin as causative antigens for wheat-dependent exercise-induced anaphylaxis. Allergol Int. 2009;58:493-8.
8. Caminiti L, Passalacqua G, Vita D, Ruggeri P, Barberio G, Pajno GB. Food-exercise-induced anaphylaxis in a boy successfully desensitized to cow milk. Allergy. 2007;62:335-6.

Manuscript received July 14, 2013; accepted for publication September 17, 2013.

Takashi Kusunoki
Department of Pediatrics
Shiga Medical Center for Children
5-7-30 Moriyama, Moriyama, Shiga 524-0022, Japan
E-mail: kusutaka@gamma.ocn.ne.jp

Allergy to Boxwood

F Carballada,[1] M Prat,[1] R Núñez,[1] J Martín,[1] A Ledesma,[2] M Lombardero,[2] M Boquete[1]
[1]*Allergy Unit, Hospital Universitario Lucus Augusti, Lugo, Spain*
[2]*R&D Department, ALK-Abelló SA, Madrid, Spain*

Key words: Boxwood. Wood allergy. IgE-immunodetection. Rhinoconjunctivitis. New allergens.

Palabras clave: Boj. Alergia a madera. Inmunodetección de IgE. Rinoconjuntivitis. Nuevos alérgenos.

Boxwood (*Buxus sempervirens*) is a shrub that grows throughout Europe [1]. Its hardness makes it extremely useful, not just for ornamental purposes, but also for the manufacture of items such as agricultural implements, kitchen utensils, and even musical instruments (eg, Galician bagpipes). Wood allergy is relatively common, especially among people who work in the wood industry, and is the subject of several publications [2-4]. Boxwood allergy, however, has seldom been reported [5], and, to our knowledge, there are no reports of IgE-mediated allergy triggered by exposure to this wood.

We present a case of allergic reaction to boxwood in which sensitization was demonstrated by skin testing and IgE-immunodetection.

The patient was a 52-year-old man with rhinoconjunctivitis and persistent mild asthma (sensitization to house dust mites) who was taking symptomatic treatment (inhaled long-acting bronchodilators and corticosteroids). He smoked 20 cigarettes a day between the ages of 20 and 49 years, and had been a moderate alcohol drinker since age 20. For the last 2 years, he had experienced immediate and late reactions that manifested as rhinoconjunctivitis and cough when working with boxwood. He reported no urticaria or dermatitis on contact with boxwood. The symptoms began after he inhaled microparticles produced by a lathe he had bought 2 years previously for his woodwork hobby.

He associated the onset of symptoms with boxwood, because they did not occur when he worked with other woods (ie, beech, apple, cherry, birch, oak, walnut, and chestnut). He stopped working with boxwood for a few months and experienced no respiratory symptoms in his workshop.

Skin prick tests with a series of airborne allergens commonly found in our setting (ALK-Abelló SA) were positive for dust mites. Skin tests with a series of wood extracts (cherry, sapele, pine, chestnut, beech, iroko, medium-density fiberboard, bubinga, obeche, southern yellow pine, and okoume; Diater Laboratories SA) proved negative, except for boxwood extract (wheal size 10×10 mm). This extract was prepared at 10% (wt/vol) in phosphate-buffered saline by magnetic stirring for 90 minutes at 5ºC. After filtration through a 0.22-µm membrane, the extract was freeze-dried before being reconstituted with phosphate buffer in one-fifth of the original volume. For the skin test, the extract was mixed with glycerol in equal parts.

 © 2014 Esmon Publicidad

The boxwood extract was tested in 5 atopic and 5 nonatopic patients, yielding negative results in all cases. The patient refused to undergo challenge tests.

The results of serum IgE determination (ImmunoCAP, Thermo Fisher Scientific) were as follows: total, 1101 kU_A/L; *Dermatophagoides pteronyssinus*, 31.8 kU_A/L; *Lepidoglyphus destructor*, 2.2 kU_A/L; birch pollen, 1.09 kU_A/L; latex, 1.57 kU_A/L; MUXF3, 1.04 kU_A/L; rBet v1, rBet v4, and rPru p 3, negative; recombinant latex allergens (Hev b 1, 3, 5, 6, 8, 9, and 11), negative.

The Figure shows the result of IgE-immunodetection with the boxwood extract, which was separated by molecular weight into its protein components using SDS-PAGE under nonreducing conditions. The proteins were then transferred to nitrocellulose membranes, which were sequentially incubated with the patient's serum, a monoclonal antihuman IgE antibody (HE-2, ALK-Abelló SA) and a peroxidase-conjugated antimouse IgG antibody (RAM-HRP, DAKO). Proteins capable of binding IgE were detected using chemiluminescence (ECL, GE Healthcare). Several different reactive bands capable of binding IgE from the patient's serum are apparent. The bands binding IgE most strongly correspond to molecular weights of approximately 18, 25, and 50 kDa (Lane 1).

Inhibition of IgE with the glycoprotein bromelain (Figure, Lane 2) shows the same pattern as no inhibition (Figure, Lane 1), suggesting that the boxwood protein bands binding the patient's IgE contain no MUXF3 carbohydrate determinants (MUXF3 is the sugar found in bromelain).

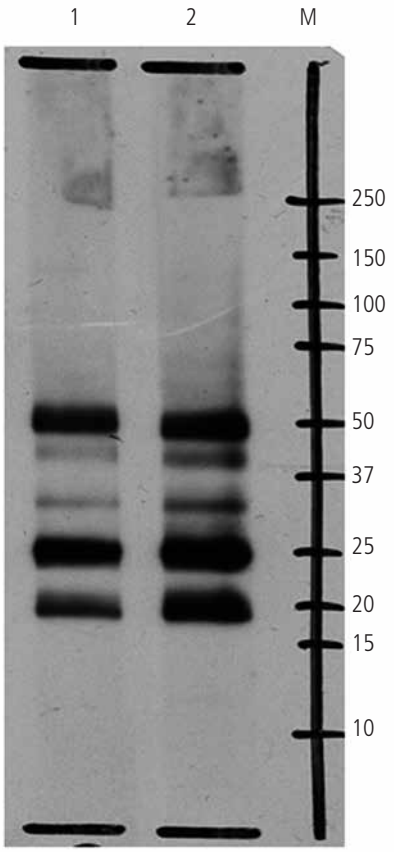

Figure. IgE immunodetection with boxwood extract. The protein components in the boxwood extract were separated by SDS-PAGE. Lane 1, patient's serum; Lane 2, patient's serum preincubated with bromelain. M indicates molecular weight markers (kDa).

Wood allergy is a relatively common condition, especially as an occupational disease. In the case of boxwood, however, despite its widespread use in our setting, we were only able to find 1 article on contact dermatitis [5]. To our knowledge, no data have been reported on the underlying immunological mechanism associated with exposure to boxwood.

We report the case of an atopic patient whose hobby involved working with boxwood. His symptoms (first nasal and conjunctival, then bronchial) developed 2 years after he began working with the wood. He did not report contact urticaria or dermatitis and is currently unaffected by either.

The patient reported no symptoms on exposure to other woods, and skin tests with commercial extracts of various woods proved negative. Boxwood allergy was confirmed based on the patient's medical history, the skin test result with boxwood extract, and IgE-immunodetection, which revealed specific IgE against components of the boxwood extract in the patient's serum. The bands binding most strongly to IgE had molecular weights of approximately 18, 25, and 50 kDa.

The specialist literature contains case reports demonstrating cross-reactivity between latex and wood [6-7]. In the case we report, the presence of IgE against whole latex extract but not against single latex allergens might be explained by the combination of cross-reactive carbohydrate determinants (CCD) and alcohol consumption, as demonstrated in other studies [8-9].

A high prevalence of IgE against CCDs has been described in wood-sensitized workers [10]. As the patient had IgE against MUXF3 (a fairly ubiquitous CCD that can be found in the glycoprotein bromelain), the IgE-immunodetection result could have been attributable to carbohydrate cross-reactivity. To rule out this possibility, the patient's serum was preincubated with bromelain before IgE-immunodetection was carried out with the nitrocellulose strip containing boxwood extract. Since bromelain did not inhibit IgE binding to boxwood proteins, we can conclude that this was a case of primary sensitization to boxwood proteins rather than CCD cross-reactivity.

In conclusion, boxwood allergy should be taken into account when investigating the cause of allergy in patients exposed to this wood at work or because of a hobby.

Acknowledgments

The authors wish to thank María José Gómez and María del Mar Pérez Orozco for their help with the skin tests and Nuria Álvarez and Lourdes Chico for preparing the boxwood extract and performing IgE-immunodetection.

Funding

The authors declare that no funding was received for the present study.

Conflicts of Interest

Amalia Ledesma and Manuel Lombardero are employees of ALK-Abelló, SA. The remaining authors declare that they have no conflicts of interest.

© 2014 Esmon Publicidad

References

1. Tena D. Formaciones estables xerotermófilas de Buxus sempervirens en pendientes rocosas (Berberidion p.p.). In: VV.AA., Bases ecológicas preliminares para la conservación de los tipos de hábitat de interés comunitario en España. Ministerio de Medio Ambiente y Medio Rural y Marino. Madrid, 2009.
2. Bohadana AB, Massin N, Wild P, Toamain JP, Engel S, Goutet P. Symptoms, airway responsiveness, and exposure to dust in beech and oak wood workers. Occup Environ Med. 2000;57:268-73.
3. Quirce S, Hinojosa M, Marañón F, Ferrer A, Fernández-Caldas E, Sastre J. Identification of obeche wood (Triplochiton scleroxylon) allergens associated with occupational asthma. J Allergy Clin Immunol. 2000;106:400-1.
4. Eire MA, Pineda F, Losada SV, de la Cuesta CG, Villalva MM. Occupational rhinitis and asthma due to cedroarana (Cedrelinga catenaeformis Ducke) wood dust allergy. J Investig Allergol Clin Immunol. 2006;16:385-7.
5. van Neer FJ, van Ginkel CJ. Allergic contact dermatitis from a boxwood recorder. Contact Dermatitis. 1997;36:305.
6. Venturini M, Gastaminza G, Kespohl S, Bernedo N, Garmendia M, Raulf-Heimsoth, M, Muñoz D, Ansotegui IJ. Cross-reactivity between obeche wood (Triplochiton scleroxylon) and natural rubber latex. Allergy. 2004;59(2):225-8.
7. Wrangsjö K, Lundberg M, Meding B, Ahman M, Karlberg AT, van Hage-Hamsten M. Cross-reacting allergens in natural rubber latex and jelutong. Allergy. 1999;54:1331-2.
8. Coutinho V, Vidal C, Garrido M, Gude F, Lojo S, Linneberg A, Gonzalez-Quintela A. Interference of cross-reactive carbohydrates in the determination of specific IgE in alcohol drinkers and strategies to minimize it: the example of latex. Ann Allergy Asthma Immunol. 2008;101:394-401.
9. Carballada FJ, González-Quintela A, Núñez-Orjales R, Vizcaino L, Boquete M. Double (honeybee and wasp) immunoglobulin E reactivity in patients allergic to Hymenoptera venom: the role of cross-reactive carbohydrates and alcohol consumption. J Investig Allergol Clin Immunol. 2010;20:484-9.
10. Kespohl S, Schlünssen V, Jacobsen G, Schaumburg I, Maryska S, Meurer U, Brüning T, Sigsgaard T, Raulf-Heimsoth M. Impact of cross-reactive carbohydrate determinants on wood dust sensitization. Clin Exp Allergy. 2010;40:1099-106.

Manuscript received July 19, 2013; accepted for publication September 17, 2013.

Francisco Javier Carballada González
Unidad de Alergia HULA
Ulises Romero, s/n
27003 Lugo, Spain
E-mail: francisco.carballada.gonzalez@sergas.es

High Baseline Blood Histamine Levels and Lack of Cross-reactivity in a Patient With Ranitidine-Induced Anaphylaxis

M Makris,[1] X Aggelides,[1] C Chliva,[1] A Katoulis,[1] K Papamichael,[2] E Tiligada[1,2]
[1]*Allergy Unit "D. Kalogeromitros", 2nd Dpt. of Dermatology and Venereology, ¨Attikon¨ University Hospital, University of Athens, Greece*
[2]*Department of Pharmacology, Medical School, University of Athens, Greece*

Key words: Anaphylaxis. Ranitidine. Drug allergy. Drug challenge. Histamine.

Palabras clave: Anafilaxia. Ranitidina. Alergia a medicamentos. Provocación con medicamentos. Histamina.

Ranitidine is a commonly prescribed H_2-receptor (H_2R) antagonist mainly used for the prevention and treatment of gastroesophageal diseases caused or aggravated by gastric acid. Reports of immediate hypersensitivity reactions to the drug are scarce [1,2]. We report a case of anaphylaxis to intravenous ranitidine administration.

A 16-year-old girl was admitted to the hospital for surgical repair of an anterior cruciate ligament injury. During induction of general anesthesia, she developed anaphylactic shock with marked hypotension, bronchoconstriction, and facial angioedema. After intensive treatment with repeated administration of adrenaline and excessive fluid replacement, the patient's vital signs stabilized and she was transferred to the intensive care unit for 48 hours.

Upon discharge the patient was referred to the "D. Kalogeromitros" Allergy Unit for allergological investigation. The detailed personal and family medical history revealed no atopy, previous surgery, or drug allergies. All the drugs received preoperatively and intraoperatively were classified into 3 categories for testing: β-lactams (cefoxitin), general anesthetics (propofol, midazolam, *cis*-atracurium), and others (ranitidine, ondansetron, and metoclopramide). Both in vitro (ImmunoCap, ThermoFisher Scientific) and in vivo tests (skin prick tests [SPTs], and intradermal [ID] tests) to β-lactams were negative. Skin tests to general anesthetics, latex, ondansetron, and metoclopramide were also negative. By contrast, ranitidine (Lumaren 25mg/mL, Elpen) yielded positive SPT (full strength) and ID (1/1,000 and 1/100 dilutions) results. SPT and ID tests to pure ranitidine (Sigma-Aldrich Co) at the same concentrations were also positive. The 1/10 ranitidine dilution was not tested as it produced an irritant reaction in 4 out of 5 unexposed individuals. Possible cross-reactivity between H_2R antagonists was evaluated with SPT and ID tests of nonirritant preparations of cimetidine (Tagamet 200 mg/2mL, Vianex) and famotidine (Peptan 20 mg, Vianex). The results were all negative. Neither the patient nor her parents recalled previous ranitidine intake, although this possibility cannot be completely ruled out.

 © 2014 Esmon Publicidad

After obtaining written informed consent and ensuring that resuscitation equipment was readily available, we performed a challenge with intravenous cefoxitin; there were no adverse reactions. Due to a lack of standardization of skin tests to ranitidine and the rare occurrence of allergic reactions to H_2R antagonists, we decided to perform a single-blind, placebo-controlled, graded oral challenge to ranitidine hydrochloride (Zantac tablet 150 mg, GlaxoSmithKline), with both the parents' and the patient's full consent. The challenge was performed in a tertiary hospital under the care of highly trained and experienced staff. Ranitidine was administered in 6 steps, starting from 0.15 mg (1:1000 of a full dose) up to a single dose of 150 mg. Almost 60 minutes after the final step, the patient developed moderate urticarial lesions on the abdomen accompanied by shivering and a vague sense of weakness. Serum tryptase levels, measured before the challenge and at 30 and 150 minutes after the reaction, showed no significant changes (4.0, 3.9, and 4.53 μg/mL respectively; normal values, <11.4 μg/mL). The mildness of the reaction after a full dose of ranitidine was inconsistent with the acute onset and severe reaction of the reported episode. Therefore, a second, this time intravenous, graded challenge was agreed on and scheduled for a week later. The patient was challenged with injectable ranitidine hydrochloride (Zantac injectable solution 25 mg/mL, GlaxoSmithKline) with an even lower starting dose of 1/10 000 the therapeutic dose (0.005 mg) and 30-minute between-dose intervals. Five minutes after receiving the sixth dose (25 mg), the patient developed diffuse urticaria, back pain, headache, and tachycardia. Antihistamines and corticosteroids were administered and the symptoms fully remitted within 60 minutes. The challenge was considered positive and was therefore interrupted. Serum tryptase levels were increased 30 and 150 minutes after the onset of the reaction (7 and 6.8 μg/mL respectively). Possible cross-reactivity with other H_2R antagonists was assessed by open challenges with oral famotidine (Peptan tablet 20 mg, Vianex) and injectable cimetidine (Tagamet injectable solution 200 mg/2 mL, Vianex). The results were negative in both cases.

Histamine levels in both serum and whole peripheral blood were determined fluorometrically in duplicate before each challenge, 30 minutes after the reaction to intravenously administered ranitidine, and upon completion of the uneventful oral challenge with cimetidine [3]. Serum histamine levels were increased—from 4.3 ng/mL to 17.1 ng/mL—after the positive challenge with ranitidine, but they remained low after the negative challenge with cimetidine (Table). Interestingly, the patient's baseline whole blood histamine levels were higher than those in 5 healthy volunteers (mean [SD] level of 18.6 [7.2] ng/mL). By contrast, baseline serum histamine levels in the symptom-free period were comparable to those of the volunteers (mean [SD] level of 8.5 [2.0] ng/mL). Moreover, increased monocytes were observed in the patient's baseline blood cell count (15.1% vs normal values of 2%-10%), although post-challenge measurements were not performed. The high baseline histamine levels in the patient's whole blood but not in serum were attributed to the increased histamine content of the blood cell fraction, which, together with the increased blood monocyte counts and increased serum histamine levels after the challenge with ranitidine, provides a rationale for the future investigation of monocyte involvement in responses such as the one in our patient [4].

Since reports of ranitidine-induced immediate hypersensitivity reactions are increasing in the literature [5,6], further elucidation of the underlying mechanism is important. Although the specificity and sensitivity of skin tests in diagnosing ranitidine-induced anaphylaxis have not been fully established, the high frequency of positive results and the reports of serum specific IgE detection indicate an IgE-mediated mechanism [1,7].

So far, only a few cases of cross-reactivity between H_2R antagonists have been demonstrated by skin testing [5,8], and just 1 case has been confirmed by challenge testing, the gold standard of clinical diagnosis [5]. Failure to demonstrate cross-reactivity with other H_2R antagonists may be due to ligand-specific signaling [9]. Skin testing followed by carefully monitored challenges to alternatives is recommended if an H_2R antagonist suspected of triggering a hypersensitivity reaction must be substituted by another member of the same family [10]. Cimetidine would be the safest alternative in such a case [8]. Considering the recent concept of the immunomodulatory role of histamine [4], the potential contribution of a tentative histamine-related etiological mechanism mediating selective hypersensitivity to ranitidine highlights the need for further investigation. New knowledge on the hitherto poorly defined mechanisms underlying drug hypersensitivity reactions will eventually lead to valuable diagnostic, prognostic, and therapeutic tools.

Table. Histamine Levels in Peripheral Whole Blood and Serum Samples

Drug	Whole Blood Histamine (ng/mL)	Serum Histamine (ng/mL)
Baseline (symptom-free)	86.5	4.3
Ranitidine 25 mg/mL intravenous	52.7	17.1
Cimetidine 100 mg/mL intravenous	32.3	6.9

Funding

This work was supported by the Greek Ministry of Health (grant 70/4/8309) and was part of the EU FP7 COST Action BM0806: Recent advances in histamine receptor H_4R research.

Conflicts of Interest

The authors declare that they have no conflicts of interest.

References

1. Koh YI, Park HS, Choi IS. Ranitidine-induced anaphylaxis: detection of serum specific IgE antibody. Allergy. 2006;61:269-70.
2. Lazaro M, Compaired JA, De La Hoz B, Igea JM, Marcos C, Dávila I, Losada E. Anaphylactic reaction to ranitidine. Allergy. 1993; 48:385-7.
3. Kyriakidis K, Zampeli E, Tiligada E. Histamine levels in whole peripheral blood from women with ductal breast cancer: a pilot study. Inflamm Res. 2009;58(S1):73-4.

© 2014 Esmon Publicidad

4. Tiligada E. Is histamine the missing link in chronic inflammation? J Leukoc Biol. 2012;92:4-6.
5. Song WJ, Kim MH, Lee SM, Kwon YE, Kim SH, Cho SH, Min KU, Kim YY, Chang YS. Two cases of H2-receptor antagonist hypersensitivity and cross-reactivity. Allergy Asthma Immunol Res. 2011;3:128-31.
6. Aouam K, Bouida W, Ben Fredj N, Chaabane A, Boubaker H, Boukef R, Boughattas NA, Nouira S. Severe ranitidine-induced anaphylaxis: a case report and literature review. J Clin Pharm Ther. 2012;37:494-6.
7. Jin HJ, Kim JE, Ye YM, Chang YS, Park HS. Ranitidine-induced anaphylaxis with detection of serum specific IgE to ranitidine and human serum albumin conjugates. Ann Allergy Asthma Immunol. 2012;108:210-2.
8. Kim Y, Park CK, Park DJ, Wi JO, Han ER, Koh YI. A Case of Famotidine-Induced Anaphylaxis. J Investig Allergol Clin Immunol. 2010;20:166-9.
9. Reher TM, Neumann D, Buschauer A, Seifert R. Incomplete activation of human eosinophils via the histamine H4-receptor: evidence for ligand-specific receptor conformations. Biochem Pharmacol. 2012;84:192-203.
10. Demirkan K, Bozkurt B, Karakaya G, Kalyoncu AF. Anaphylactic reaction to drugs commonly used for gastrointestinal system diseases: 3 case reports and review of the literature. J Investig Allergol Clin Immunol. 2006;16:203-9.

Manuscript received July 31, 2013; accepted for publication, September 17, 2013.

Xenophon Aggelides
Allergy Unit, ¨Attikon¨ University Hospital,
1, Rimini str, Haidari, PC 12462
Athens, Greece
E-mail: zenossag@yahoo.gr

Dysphagia in a Boy Treated With Oral Immunotherapy for Cow's Milk Allergy

C García Rodríguez,[1] E Gómez Torrijos,[1] F De la Roca Pinzón,[1] J Borja Segade,[1] R García Rodríguez,[1] F Feo Brito,[1] J Rodríguez-Sánchez[2]
[1]*Allergy Section, Hospital General Universitario, Ciudad Real, Spain*
[2]*Digestive Section, Hospital Gutierrez Ortega, Valdepeñas, Ciudad Real, Spain*

Key words: Oral immunotherapy. Dysphagia. Milk allergy. Eosinophilic esophagitis. Anaphylaxis.

Palabras clave: Inmunoterapia oral. Disfagia. Alergia a leche. Esofagitis eosinofílica. Anafilaxia.

In recent decades, several authors have described their experience with oral immunotherapy (OIT) in children allergic to cow's milk (CM) [1-2]. Although allergic reactions during OIT are frequent, few cases of late complications due to these innovative therapeutic procedures have been reported [3].

We report the case of a 14-year-old boy allergic to CM protein. When the boy was 10 years old, skin prick tests (SPTs) with commercial extracts (ALK-Abelló) produced a wheal measuring 10x4 mm for CM, 18x15 mm for α-lactalbumin, 15x10 mm for β-lactoglobulin, and 7x4 mm for casein (histamine, 4x4 mm). Milk and casein specific IgE (sIgE) levels (Phadia InmunoCAP) were 15 kU/L and 11.1 kU/L, respectively, and the peripheral blood eosinophil count was 700 cells/µL. At the time, the patient underwent an OIT protocol with CM. After an induction phase of 9 weeks, he achieved tolerance to a dose of 250 mL of milk taken once a day. One year later, the patient had to reduce milk intake to 125 cc a day and finally to 75 cc due to poor tolerance with higher doses (oral itching, nausea, and epigastric pain).

At the age of 13 years, 25 months after achieving tolerance to the maximum dose, the patient began with food impaction, dysphagia, and choking episodes once or twice a week, which were resolved by drinking liquids. Taking into account these symptoms and the history of the patient, proton-pump inhibitor (PPI) treatment was prescribed at a dose of 40 mg per day. The patient became asymptomatic 2 months after starting this treatment. At this time, the first endoscopy was performed, showing linear furrows in distal and medial esophageal mucosa and 30 eosinophils per high-power field (hpf) in the proximal and distal esophagus. Since these findings fulfilled the 2011 consensus criteria for eosinophilic esophagitis (EoE), oral fluticasone (400 mcg/24 h) was added to the PPIs, and CM was excluded from the diet [4]. Nevertheless, the patient continued to consume small amounts of CM, present in other food. In the following 2 months, he had 2 episodes of facial erythema and itching, and an anaphylactic episode after consuming small amounts of CM hidden in several dishes in a restaurant (omelette, sandwich with mayonnaise,

 © 2014 Esmon Publicidad

fried squid, rice, and fish). The presence of milk in the food consumed was confirmed by the chef.

The study performed at this time included a positive SPT to CM (wheal, 5x5 mm) and a negative SPT to fish, seafood, eggs, legumes, nuts, and anisakis. Milk and casein sIgE levels showed figures of 12.6 kU/L and 10.7 kU/L, respectively. SIgE was negative to rice, squid, and anisakis. Oral challenges with eggs, rice, and cephalopods were negative. Peripheral blood eosinophils were 600 cells/µL and serum tryptase levels were normal.

Given these results, we suspected that the reactions were caused by traces of CM. A strict milk avoidance diet was indicated and oral fluticasone was withdrawn but PPIs maintained.

A second endoscopy was performed 2 months after strict milk avoidance. Macroscopically, the esophageal mucosa was normal, and proximal and distal mucosal biopsies revealed 10-12 eosinophils/hpf. Since the number of eosinophils in the esophageal tract had been reduced, we decided to maintain treatment with PPIs and to perform a repeat endoscopy 5 months later.

A third endoscopy showed a normal esophageal mucosa with no eosinophils in the biopsy samples. Peripheral blood eosinophils showed similar figures throughout the process. PPI treatment was discontinued and the patient is still asymptomatic, a year later.

We have reported the case of a teenage patient allergic to CM who achieved tolerance of milk with an OIT protocol but developed EoE after 2 years of a maintenance phase with regular milk intake. This is the second case of eosinophilic esophagitis in 25 patients who have undergone OIT so far in our allergy department. The course was similar in both patients, with partial loss of tolerance after starting the maintenance phase, possibly suggesting that this late complication is more common in patients with worse outcomes after OIT.

The patient presented with typical symptoms seen in teenagers with EoE (dysphagia and choking) and the diagnosis was confirmed by endoscopy and esophageal tract biopsies. In compliance with guidelines on EoE management, PPI treatment was started 2 months before the first endoscopy to exclude gastroesophageal reflux disease and/or PPI-responsive esophageal eosinophilia [4-6]. Due to the favorable clinical course and the persistent histological remission after exclusion of CM from the diet, we suspected that CM proteins might be responsible for the EoE [7]. Tolerance to milk disappeared in a few weeks after exclusion of regular milk intake and the patient developed anaphylaxis following the ingestion of small amounts of milk hidden in other foods.

Recently, Sánchez García et al [8] reported on 3 patients with CM protein allergy treated with OIT who developed typical symptoms of EoE between 3 and 14 months after achieving tolerance of a dose of 200 mL of milk taken once a day. EoE was confirmed by esophageal biopsies and the clinical picture resolved after CM avoidance. Ridolo et al [9] described the case of an 11-year-old boy who developed EoE after OIT for egg allergy and achieved histologic remission after egg withdrawal. Hofmann et al [10], in turn, reported on a patient who developed EoE while being treated with OIT for peanut allergy. The EoE resolved after a peanut-free diet. Our case is similar to previous reports, except that EoE developed somewhat later (>2 years after completion of the protocol). What is also particularly striking in our patient is the rapid loss of CM tolerance after elimination of regular milk intake.

We conclude that EoE is a possible late complication in food-allergic patients treated with OIT. It is important that both patients and doctors are aware of this possibility and that patients are monitored long term. A strict elimination diet with the implicated food should be prescribed to resolve the EoE and avoid the risk of severe reactions due to the possible disappearance of tolerance after eliminating regular intake of the offending food.

Acknowledgments

The case described was awarded in the 2012 contest promoted by the Spanish Society of Allergy and Clinical Immunology (SEAIC) for clinical cases reported by medical residents. October 2012, Spain.

Funding

The authors declare that no funding was received for this study.

Conflicts of Interest

The authors declare that they have no conflicts of interest.

References

1. Longo G, Barbi E, Berti I, Meneghetti R, Pittalis A, Ronfani L, Ventura A. Specific oral tolerance induction in children with very severe cow's milk-induced reactions. J Allergy Clin Immunol. 2008 Feb;121(2):343-7
2. Rodríguez del Río P, Sánchez-García S, Escudero C, Pastor-Vargas C, Sánchez Hernández JJ, Pérez-Rangel I, Ibáñez MD.Allergy to goat's and sheep's milk in a population of cow's milk-allergic children treated with oral immunotherapy. Pediatr Allergy Immunol. 2012 Mar; 23(2):128-32.
3. Keet CA, Frischmeyer-Guerrerio PA, Thyagarajan A, Schroeder JT, Hamilton RG, Boden S, Steele P, Driggers S, Burks AW, Wood RA. The safety and efficacy of sublingual and oral immunotherapy for milk allergy.J Allergy Clin Immunol. 2012 Feb;129(2):448-55.
4. Liacouras CA, Furuta GT, Hirano I, Atkins D, Attwood SE, Bonis PA, Burks AW, Chehade M, Collins MH, Dellon ES, Dohil R, Falk GW, Gonsalves N, Gupta SK, Katzka DA, Lucendo AJ, Markowitz JE, Noel RJ, Odze RD, Putnam PE, Richter JE, Romero Y, Ruchelli E, Sampson HA, Schoepfer A, Shaheen NJ, Sicherer SH, Spechler S, Spergel JM, Straumann A, Wershil BK, Rothenberg ME, Aceves SS. Eosinophilic esophagitis: updated consensus recommendations for children and adults. J Allergy Clin Immunol. 2011 Jul;128(1):3-20.
5. AJ Lucendo Villarin, MR Avila Castellano. Esofagitis eosinofílica. Diagnóstico, tratamiento y seguimiento. J Investig Allergol Clin Immunol. 2011; vol. 21, supplement 4:12-55.
6. Lucendo Villarín AJ. Eosinophilic esophagitis: clinical manifestations, diagnosis, and treatment. Rev Esp Enferm Dig. 2009 Jan;101(1):49-59.

© 2014 Esmon Publicidad

7. Henderson CJ, Abonia JP, King EC, Putnam PE, Collins MH, Franciosi JP, Rothenberg ME. Comparative dietary therapy effectiveness in remission of pediatric eosinophilic esophagitis. J Allergy Clin Immunol. 2012 Jun;129(6):1570-8.
8. Sánchez-García S, Rodríguez Del Río P, Escudero C, Martínez-Gómez MJ, Ibáñez MD. Possible eosinophilic esophagitis induced by milk oral immunotherapy. J Allergy Clin Immunol. 2012 Apr;129(4):1155-7.
9. Ridolo E, De Angelis GL, Dall'aglio P. Eosinophilic esophagitis after specific oral tolerance induction for egg protein. Ann Allergy Asthma Immunol. 2011 Jan;106(1):73-4.
10. Hofmann AM, Scurlock AM, Jones SM, Palmer KP, Lokhnygina Y, Steele PH, Kamilaris J, Burks AW. Safety of a peanut oral immunotherapy protocol in children with peanut allergy. J Allergy Clin Immunol. 2009 Aug;124(2):286-91, 291.

Manuscript received May 6, 2013; accepted for publication, September 18, 2013.

Carmen García Rodríguez
Sección de Alergología
Hospital General Universitario de Ciudad Real
C/ Obispo Rafael Torija s.n.
13005-Ciudad Real, Spain
E-mail: carmengr.rodriguez@gmail.com

Analysis of Changes in First Allergy Consultations Over a Period of 5 Years

L Ferré-Ybarz,[1] R Salinas Argente,[2] C Gómez Galán,[1] S Nevot Falcó,[1] J Franquesa Rabat,[3] J Trapé Pujol,[3] P Oliveras Alsina,[4] M Pons Serra[5]
[1]*Althaia, Allergy Service Hospital Sant Joan de Déu, Manresa, Spain*
[2]*Director Banc de Sang i Teixits Catalunya Central i Vallès Occidental, Spain*
[3]*Althaia, Biological Diagnosis Department, Hospital Sant Joan de Déu, Manresa, Spain*
[4]*Althaia, Management Control Unit, Centre Hospitalari, Manresa, Spain*
[5]*Althaia, Care Director, Hospital Sant Joan de Déu, Manresa, Spain*

Key words: Allergic diseases.Waiting list.

Palabras clave: Enfermedades alérgicas. Lista de espera.

Hospital Sant Joan de Déu in Manresa forms part of the Althaia Foundation healthcare network and provides allergy care service for central Catalonia. Population growth due in part to immigration and increased life expectancy, together with an increased prevalence of allergic diseases, has contributed to longer waiting lists at our allergy department in recent years. The aim of this paper was to analyze whether the increase in demand for care over a 5-year study period affected the reasons for allergy consultations. The study forms part of the department's strategic plan (SP) for 2005-2010 [1].

We analyzed and compared waiting lists for first allergy consultation visits and specific reasons for consultation in 2005 and 2010. Patients were divided into 4 groups according to their presenting complaint: *1*) respiratory allergy (rhinitis and/or bronchial asthma), *2*) food allergy, *3*) drug allergy, and *4*) skin allergy (urticaria, angioedema, atopic or contact dermatitis). Data were obtained from allergy department records and information provided by the Althaia Foundation's department of management and biological diagnosis. Population data were extracted from the IDESCAT census database of the Catalan Government.

According to official census data, in 2005 the population in the area served by the allergy department consisted of 238 486 inhabitants. The average waiting time for a first appointment was 10 months (300 days). There were 1519 first allergy visits in 2005. Broken down by groups, there were 881 visits in Group 1 (respiratory allergy), 379 visits in Group 2 (food allergy), 212 visits in Group 3 (drug allergy), and 273 visits in Group 4 (skin allergy).

In 2010, the population in the same area was 259 079 inhabitants (an increase of 20 593 people). However, the 2010 reference area also included the areas originally covered by Hospital d'Igualada (111 000 inhabitants) and Hospital Nostra Senyora de Meritxell de Andorra (84 082 people); these areas

 © 2014 Esmon Publicidad

are now covered by our allergy department through strategic partnerships defined in the SP. Thus, the total population attended was about 453 161 people. The overall waiting period for a first appointment was 4.5 months (165 days). There were 3018 first consultations: 1962 for respiratory allergy, 905 for food allergy, 482 for drug allergy, and 513 for skin allergy.

The mean number of specific IgE determinations requested per patient was 3.4 in 2005 compared with 4.27 in 2010.

The prevalence of allergic diseases has increased in recent years and with it the number of allergy consultations [2]. According to IDESCAT, there was a 7.95% increase (20 593 inhabitants) in the population of central Catalonia between 2005 and 2010 [3]. This was due in part to a rise in the immigrant population, which currently represents 13.27% of the census population (9.23% in 2005). Apart from this population increase, in 2009 our allergy department also started to provide care, for the reference populations originally covered by Hospital d'Igualada and Hospital Nostra Senyora de Meritxell d'Andorra

The increased activity did not reflect a significant change in reasons for allergy consultations. There was a slight increase in the percentage of food allergy studies (from 21.72% in 2005 to 23.43% in 2010), possibly due to the increased number of pollen-polysensitized individuals in our area, who also have plant food allergies. A study with longer and more detailed follow-up of these patients would be necessary. The Alergológica 2005 study (a national clinical and epidemiologic project that described the profile of patients treated in a Spanish sample of allergology departments) also showed a slight increase in consultations for food allergy with respect to data from the same study in 1992 [4].

There was a slight reduction in the number of drug allergy consultations (15.64% in 2005 vs 13.28% in 2010), most probably due to improvements in the patient referral process.

We did not detect a significant increase in the percentage of respiratory allergy consultations, although the number of patients sensitized to at least 1 allergen was probably higher in 2010 than in 2005. The number of specific IgE determinations per patient rose from 3.4 in 2005 to 4.27 in 2010, primarily due to an increase in the number of patients presenting specific IgE antibodies to aeroallergens. In other words, even though there was not a significant increase in the percentage of patients with rhinitis and asthma in 2010, improvements in patient screening probably led to a greater number of positive tests. The application of referral criteria as part of the department's SP improved the quality of first consultations, which probably influenced the higher percentage of positive test results in 2010 [5]. According to the Alergológica 2005 study, there was a reduction in the number of consultations for bronchial asthma and a stable rate for rhinitis in the period 1992-2005 [4]; these observations are consistent with our findings. The division of patients into groups based on the reason for allergy consultation may have biased our results since patients may consult for multiple reasons [6,7].

In conclusion, the increased demand for allergy testing has not led to a significant change in reasons for consultation. There was a slight increase in consultations for food allergy and probably a greater number of patients with positive tests, although this needs to be analyzed in more detail.

Funding

The authors declare that no funding was received for this study.

Conflicts of Interest

The authors declare that they have no conflicts of interest.

References

1. Ferré-Ybarz L. Salinas Argente R, Nevot Falcó S, Gómez Galán C, Franquesa Rabat J, Trapé Pujol J, Oliveras Alsina P, Pons Serra M, Corbella Virós X. Allergy medical care network: a new model of care for specialties. Allergol Immunopathol (Madr). 2014 Jan 29. pii: S0301-0546(13)00288-7. doi: 10.1016/j.aller.2013.09.015. [Epub ahead of print].
2. Gaig P, Muñoz-Lejarazu D, Lleonart R, García-Abujeta JL, Caballero T, Rodriguez A, Echechípia S, Martinez C, Domínguez FJ, Gonzalo MA, Olona M. Prevalencia de alergia en la población adulta española. Alergol Inmunol Clin. 2004; 19 (2): 68-74.
3. IDESCAT: Banc d'estadístiques de municipis i comarques. Indicadors demogràfics. Barcelona, Generalitat de Catalunya. Available from http://www.idescat.net/.
4. Alergológica 2005. Factores epidemiológicos, clínicos y sociodemográficos de las enfermedades alérgicas en España en 2005. Sociedad Española de Alergología e Inmunología Clínica. Luzán S.A. Ediciones.
5. Ferré-Ybarz L, Tella Ruz R, Ranea Arroyo S, Guspí Bori R, Nevot Falcó S. Estudio preliminar del desplazamiento del alergólogo a centros de atención primaria. Alergol e Inmunol Clin. 2005, 290 (5): 224-229.
6. Sirvent S, Tordesillas L, Villalba M, Díaz-Perales A, Cuesta-Herranz J, Salcedo G, Rodriguez R. Pollen and plant food profilin allergens show equivalent IgE reactivity. Ann Allergy Asthma Immunol. 2011;May 106 (5):429-435
7. Bolibar B, Prados A, Gervás J, Juncosa S, Carrillo E. Sistemas de clasificación en grupos de iso-consumo (case-mix) en atención ambulatoria. Perspectivas para nuestra atención primaria. Aten Primaria. 1996;17 (vol 17 núm 1):74-83.

Manuscript received July 5, 2013; accepted for submission, September 19, 2013.

Laia Ferré-Ybarz
Servei d'Al·lergia
Althaia. Xarxa Assistencial i Universitària de Manresa
Hospital Sant Joan de Déu
08243 Manresa, Spain
E-mail: lferre@althaia.cat

© 2014 Esmon Publicidad

Immediate Hypersensitivity to Heparins: A Cross-reactivity Study

P González,[1] Mª Luz de la Sen,[2] I Venegas,[1] A Ramón,[1] V Soriano,[1] B Cueva,[1] J Fernández[1]
[1]*Allergy Unit, Hospital General de Alicante, Alicante, Spain*
[2]*Immunology Service, Hospital General de Alicante, Alicante, Spain*

Key words: Heparin allergy. Fondaparinux. Low-molecular-weight heparins.

Palabras clave: Alergia heparina. Fondaparinux. Heparinas bajo peso molecular.

Heparins are widely used for treatment and prophylaxis of thromboembolic disorders. They comprise a spectrum of agents, including unfractionated heparin (UFH), low-molecular-weight heparins (LMWHs), heparinoids, and pentasaccharides. The most common hypersensitivity reactions to heparins are delayed-type erythematous plaques that occur after subcutaneous application [1]. Immediate-type reactions to heparin compounds, which probably involve an IgE-mediated pathomechanism, seem to be uncommon and very few cases have been published [2-6].

A 33-year-old man was referred to our allergy unit with a suspected drug allergy. Six months earlier, he had undergone tibial surgery and 3 days after the procedure he developed generalized urticaria and facial edema. He was receiving ibuprofen and subcutaneous bemiparin. Ibuprofen was stopped and antihistamines were prescribed, but the urticaria reappeared each morning 15 to 20 minutes after bemiparin administration for 2 weeks. Bemiparin was therefore changed to another LMWH, enoxaparin. A few minutes after receiving the first dose of subcutaneous enoxaparin, the patient developed hypotension, tachycardia, dyspnea, and worsening of urticaria that required treatment in the emergency room. Enoxaparin treatment was stopped and the urticaria resolved in less than 24 hours.

The patient had a previous history of mild rhinitis and sensitization to Chenopodiaceae plants. Skin prick tests (SPTs) and intracutaneous tests (ICTs) with UFH and various types of LMWHs (enoxaparin, bemiparin, dalteparin, nadroparin, tinzaparin), fondaparinux, and lepirudin (hirudin) were performed as previous described [1-2].

The SPTs were negative for all the compounds tested. The ICTs (1/100 dilution) were positive for all the LMWHs and negative for fondaparinux and lepirudin. The ICT with UFH was also negative (up to a 1/10 dilution).

A basophil activation test was performed with the BASOTEST kit (Orpegen). After in vitro allergen-specific stimulation, activated basophils express CD63, which can be detected using monoclonal antibodies anti-CD63-FITC and anti IgE-PE. Enoxaparin, bemiparin, dalteparin, UFH, fondaparinux, and lepirudin were used at 2 dilutions (1/40 and 1/160) and the percentage of basophils expressing CD63 was measured using a FACSCanto flow cytometer (Becton Dickinson).

The BASOTEST was positive for enoxaparin, bemiparin, dalteparin, and UFH and negative for fondaparinux and lepirudin [Figure].

To identify an alternative drug and after obtaining informed consent, we performed a provocation test with fondaparinux and lepirudin, both of which were tolerated. Because of the discordance between the skin test results and the BASOTEST results for UFH, we also performed a provocation test with intravenous UFH under careful supervision. The drug was tolerated well at full doses.

Although heparins are commonly used drugs, allergic reactions are rare. The most common reactions involve cell-mediated hypersensitivity with clinical manifestations of erythematous plaques and sometimes maculopapular exanthemas [1]. Immediate-type hypersensitivity reports are extremely rare [2-6] and not all describe an allergy study. Moreover, diagnosis is sometimes challenging, as patients may be taking concomitant medication. This was the case with our patient, in whom nonsteroidal anti-inflammatory drug intolerance was initially suspected.

In our patient, the immediate onset of cutaneous symptoms after administration of bemiparin and of anaphylaxis after enoxaparin administration, together with the positive skin test and BASOTEST results, strongly suggested an IgE-mediated reaction to these compounds.

Although the sensitivity and specificity of skin tests have yet to be determined in immediate-type reactions to heparins, our case supports previous findings that suggest that intradermal testing with diluted drugs may be a useful tool in the diagnosis of these reactions [1-3].

We found that the BASOTEST was positive to all LMW heparins tested. Caballero et al [7] also reported on 2 patients with heparin-induced acute urticaria in which the BASOTEST had a good correlation with clinical findings, and suggested using this in vitro diagnostic technique to study possible sensitization to heparins to avoid the risks associated with challenge tests.



Figure. Flow cytometric analysis of activated basophils. Activated basophils are expressed as the percentage of CD63+ cells in the upper right quadrant. Plots correspond to the percentage of activated basophils after incubation with buffer alone (negative control), anti-IgE (positive control), and 1/40 dilution of different heparins.

 © 2014 Esmon Publicidad

In our patient, the BASOTEST was strongly positive for UFH, even though the patient tolerated the administration of the drug. One possible explanation for this discordance may be depolymerization of UFH, with generation of low LMWH during the incubation of basophils in the BASOTEST.

The pattern of cross-reactivity between the different heparins has not been well established. Cross-reactivity may be extensive in cell-mediated reactions to UFH and LMWH [8-10]. Information regarding immediate reactions is sparser. Harr et al [2] described a patient with immediate sensitization to dalteparin with extensive cross-reactivity to other LMWHs and to the glycosaminoglycan danaparoid. The patient, however, tolerated UFH, the pentasaccharide fondaparinux, and lepirudin (hirudin). Other authors have reported cross-reactivity between UFH and LMWH [3,6].

Our patient showed cross-sensitization between all the LMWHs tested, but he tolerated UFH, fondaparinux, and lepirudin. Perhaps different cross-reactive patterns are possible, as documented in previously reported cases of anaphylaxis to anticoagulants [2,3].

In some patients sensitized to heparins, fondaparinux seems to be an alternative due to its lower allergic potential and lack of cross-reactivity, probably because of its full synthetic structure, ultra-low molecular weight, and different allergenic epitope [10]. Nevertheless, an allergy study should be performed before administration. Hirudins may be another alternative.

In conclusion, skin tests and the BASOTEST may help to study immediate sensitization to heparins, determine cross-reactivity between the different compounds, and most importantly, find a safe alternative for patients sensitized to heparins.

Funding

The authors declare that no funding was received for this study.

Conflict of Interest

The authors declare that they have no conflicts of interest.

References

1. Bircher AJ, Harr T, Hohestein L, Tsakiris DA. Hypersensitivity reactions to anticoagulant drugs: diagnosis and management options. Allergy. 2006; 61:1432-40.
2. Harr T, Scherer K, Tsakiris D, Bircher AJ. Immediate type hypersensitivity to low molecular weigh heparins and tolerance of unfractioned heparin and fondaparinux. Allergy. 2006; 61:787-8.
3. Berkun Y, Haviv YS, Schwartz LB, Shalit M. Heparin-induced recurrent anaphylaxis. Clin Exp Allergy. 2004;34:1916-18
4. Patriarca G, Rossi M, Schiavino D, Schinco G, Fais G, Varano C, Schiavello R. Rush desensitization in heparin hypersensitivity: a case report. Allergy. 1994;49: 292-4.
5. Kavut AB, Koca E. Successful desensitization with un-fractionated heparin in a patient with heparin allergy and tolerance to fondaparinux. Asian Pac J Allergy Immunol. 2012; 30:162-6.
6. Tiu A, Pang J-M, Martin R, Officer N. Allergic reactions to enoxaparin and heparin: a case report and review of the literature. NZMJ. 2004;117:1-3.
7. Caballero MR, Fernandez-Benitez M. Allergy to heparin: A new in vitro diagnostic technique. Allergol et Immunopathol. 2003; 31 (6):324-8.
8. Maetzke J, Hinrichs R, Staib G, Scharffetter-Kochanek K. Fondaparinux as a novel therapeutic alternative in a patient with heparin allergy. Allergy. 2004; 59: 237-8.
9. Koch P. Delayed-type hypersensitivity skin reactions due to heparins and heparinoids. Tolerance of recombinant hirudins and of the new synthetic anticoagulant fondaparinux. Contact Dermatitis. 2003; 49: 276-280.
10. Grims RH, Weger W, Reiter H, Arbab E, Kranke B, Aberer W. Delayed type hypersensitivity to low molecular weight heparins and heparinoids: cross-reactivity does not depend on molecular weigh. Br J Dermatol. 2007; 157: 514-7.

Manuscript received May 17, 2013; accepted for publication, September 25, 2013.

Purificación González Delgado
Servicio Alergia
Hospital General Alicante
C/Pintor Baeza 12
03001 Alicante, Spain
E-mail: gonzalez__pur@gva.es

© 2014 Esmon Publicidad

Occupational Allergic Rhinoconjunctivitis Induced by *Matricaria chamomilla* With Tolerance of Chamomile Tea

P Benito,[1*] R Rodríguez-Perez,[2*] F García,[1] S Juste,[1] I Moneo,[2] ML Caballero[2]

[1]*Department of Allergology, Hospital Universitario, Burgos, Spain*
[2]*Department of Immunology, Hospital Carlos III, Madrid, Spain*
[*]*These authors contributed equally to this article.*

Key words: Allergy. *Matricaria chamomilla*. Occupational allergic rhinoconjunctivitis. Occupational exposure.

Palabras clave: Alergia. *Matricaria chamomilla*. Rinoconjuntivitis alérgica ocupacional. Exposición ocupacional.

Matricaria chamomilla, Compositae (German chamomile), has traditionally been used for medicinal purposess for its antioxidant, antimicrobial, and anti-inflammatory properties, as well as for its antispasmodic and anxiolytic effects [1]. Chamomile has been described as an elicitor of type-IV delayed and anaphylactic reactions after ingestion of tea [2-6].

There have been reports of occupational asthma and rhinitis caused by inhalation exposure to chamomile dust, but they do not specify whether or not those affected tolerated drinking chamomile tea [7,8]. We describe a case of occupational allergic rhinoconjunctivitis induced by *M chamomilla* in a patient who tolerated ingestion of chamomile tea.

A 47-year-old woman in charge of packing herbal teas at a herbalist's for 10 years reported episodes of intense rhinorrhea, sneezing, nasal and ocular itching, conjunctival erythema, and watery eyes for 3 years. The symptoms disappeared during weekends and holidays, suggesting occupational exposure. So far the patient has tolerated ingestion of chamomile and peppermint tea.

The patient had a normal respiratory function test, with a forced expiratory volume in the first second (FEV_1) of 120%. The bronchodilator test was negative.

Skin prick tests (Bial-Aristegui) and ImmunoCAP (Phadia) were positive for chamomile pollen (*M chamomilla*) (16.4 kU/L), peppermint (*Mentha piperita*) (0.59 kU/L), fennel (*Foeniculum vulgare*) (0.50 kU/L), and tea plant (*Camellia sinensis*) (0.24 kU/L); pollen mixtures of weed (wheal, 22x21 mm), grasses (6x14 mm) and trees (10x12 mm); and *Artemisia* species (20x21 mm, 7.47 kU/L), *Aster* species (15x10 mm), rue (*Solidago virgaurea*) (12x9 mm, 2.65 kU/L), grama (*Cynodon dactylon*) (0.53 kU/L), and ryegrass (*Lolium perenne*) (0.5 kU/L). The diameter of wheals corresponding to controls were 5 mm for histamine and 0 mm for glycerol saline.

Prick-to-prick tests performed with extracts from herbs handled by the patient were positive for chamomile (22x21 mm), peppermint (10x16 mm), and fennel (4x6 mm). Nasal provocation tests were performed with chamomile and peppermint extracts. The patient showed an immediate response consisting of hydrorrhea, sneezing fits, and a 60% decrease in peak nasal inspiratory flow (PNIF), with 1:1000 wt/vol chamomile extract.

Crushed dried chamomile flowers handled by the patient (10 g) were extracted with phosphate buffered saline (PBS) (350 mL) (4°C/72 h). After centrifugation (4500 g/30 min) the supernatant was freeze-dried and the pellet was recovered or defatted with acetone (1:10 wt/vol, 4°C/1 h) followed by acetone/methanol (8:1 vol/vol, 4ºC/1 h), and extracted with PBS (4°C/2 h). After centrifugation, the supernatant was dialyzed and freeze-dried.

The extracts (15 µg) were analyzed by SDS-PAGE and electro-transferred onto a polyvinylidene difluoride membrane (Sequiblot, Bio-Rad) for IgE immunoblotting with the patient's serum.

SDS-PAGE revealed no recognizable protein bands, but a diffuse smear in all extracts (Figure A). IgE immunoblotting showed that the patient's serum detected allergens from 175 to 25 kDa in the 3 extracts (Figure B).

Digestion of the chamomile extracts with simulated gastric fluid (12.8 µg/µL pepsin A [Sigma] in 50 mM HCl, 37ºC/30 min) eliminated the detection (Figure 1C), possibly explaining why the patient tolerated the ingestion of chamomile tea.

Allergen Mat c 1 (17 kDa) is the only allergen described in chamomile (www.allergome.org). Furthermore, a smear of 50 to 23 kDa has been reported [5]. These IgE detections were found in cases of anaphylaxis after ingestion of chamomile tea, so the allergens should be pepsin-resistant, although this experiment was not performed.

The case reported here is the first to describe occupational allergic rhinoconjunctivitis induced by inhalation of chamomile dried flowers in a patient who tolerated ingestion of chamomile tea.

Funding

Financial support was provided by Hospital Carlos III within the training program for resident physicians (MIR system).

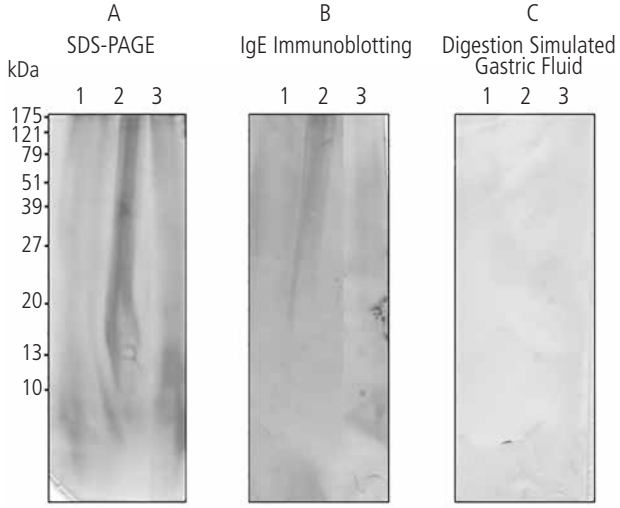

Figure. Analysis of extracts prepared with chamomile flowers handled by the patient. A, SDS-PAGE and Coomassie staining. Lanes: (1) supernatant obtained after phosphate buffered saline (PBS) extraction; (2) pellet obtained after PBS extraction; and (3), defatted extract. B, IgE immunoblotting performed with the patient's serum. C, Performed after digestion of the extracts with simulated gastric fluid.

 © 2014 Esmon Publicidad

Conflicts of Interest

The authors declare that they have no conflicts of interest.

References

1. McKay DL, Blumberg JB. A review of the bioactivity and potential health benefits of chamomile tea (Matricaria recutita L.) Phytother Res. 2006;20:519-30.
2. Pereira F, Santos R, Pereira A. Contact dermatitis from chamomile tea. Contact Dermatitis. 1997;36:307.
3. Rodriguez-Serna M, Sanchez-Motilla JM, Ramon R, Aliaga A. Allergic and systemic contact dermatitis from Matricaria chamomilla tea. Contact Dermatitis. 1998;39:192-3.
4. Subiza J, Subiza JL, Hinojosa M, Garcia R, Jerez M, Valdivieso R, Subiza E. Anaphylactic reaction after the ingestion of chamomile tea: A study of cross-reactivity with other composite pollens. J Allergy Clin Immunol. 1989;84:353-8.
5. Reider N, Sepp N, Fritsch P, Weinlich G, Jensen-Jarolim E. Anaphylaxis to chamomile: clinical features and allergen cross-reactivity. Clin Exp Allergy. 2000;30:1436-43.
6. Andres C, Chen WC, Ollert M, Mempel M, Darsow U, Ring J. Anaphylactic reaction to chamomile tea. Allergol Int. 2009;58:135-6.
7. Abramson MJ, Sim MR, Fritschi L, Vincent T, Benke G, Rolland JM. Respiratory disorders and allergies in tea packers. Occup Med. 2001; 51: 259-65.
8. Vandenplas O, Pirson F, D'Alpaos V, Vander Borght T, Thimpont J, Pilette C. Occupational asthma caused by chamomile. Allergy. 2008;63:1090-2.

Manuscript received August 12, 2013; accepted for publication, October 22, 2013.

María Luisa Caballero
Immunology Department
Hospital Carlos III
C/ Sinesio Delgado, 10
28029 Madrid, Spain
E-mail: mlcsoto@hotmail.com

© 2014 Esmon Publicidad